

Effectiveness of the Digging through Thrombus Technique by Using an Aspiration Catheter and Stent Retriever for Cerebral Venous Thrombosis

Rio HIGAKI,¹ Shinya YAMAGUCHI,¹ Hironori HARUYAMA,¹ Masato OSAKI,²
Shuji ARAKAWA,² and Tetsuro SAYAMA¹

¹Department of Neurosurgery, Steel Memorial Yawata Hospital, Kita-Kyushu, Fukuoka, Japan

²Department of Cerebrovascular Disease, Steel Memorial Yawata Hospital, Kita-Kyushu, Fukuoka, Japan

Abstract

Cerebral venous thrombosis (CVT) is a rare cause of stroke, and the first-line treatment is systemic anticoagulation. Patients unresponsive to standard therapy for CVT present with rapid neurological deterioration and require endovascular treatment. We encountered two patients with severe CVT who underwent endovascular treatment. In our cases, the thrombus was too hard and extensive to pass through using currently existing techniques. We performed the “digging through thrombus technique” using an aspiration catheter and stent retriever and achieved rapid sinus recanalization and favorable outcomes.

Keywords: Cerebral venous thrombosis, mechanical thrombectomy, stent retriever, aspiration catheter, combined technique

Introduction

Cerebral venous thrombosis (CVT) is a rare cause of stroke. Its clinical presentation varies from a mild headache to dramatic manifestations such as death.¹⁻³⁾ The goals of CVT management are to prevent the progression of venous thrombosis, re-establish venous blood flow, and manage the etiology of any prothrombotic state to prevent CVT recurrence.²⁾ Systemic anticoagulation is generally accepted as the principal therapy. However, there remains a subgroup of patients who experience rapidly progressive neurological deterioration before effective anticoagulation is observed.⁴⁾ These patients require rapid and aggressive therapy such as endovascular treatment; however, the efficacy and safety of additional endovascular treatment vary per study because most published data come from case reports or small case series. Furthermore, it remains difficult to achieve recanalization using existing techniques because of the property and quantity of the thrombus. In such cases, we conducted the “digging through thrombus technique,” wherein we repeatedly advanced an aspiration catheter over a stent retriever, while the stent retriever

captured the thrombus into the aspiration catheter (Fig. 1). Our technique is off-label usage; however, we used this technique for patients who showed progressive symptoms and required rapid recanalization. These participants and their families provided written informed consent, and the treatment design was approved by Steel Memorial Yawata Hospital Ethical Review Board (No. 21-55). Our technique enabled us to dig extensive and hard thrombi and achieve recanalization of the occluded sinus. Here we described our technique using previous reports.

Case Report

Case 1

A 67-year-old man was admitted to our hospital with a 1-week history of headache, which progressed to seizures and confusion. He was diagnosed with CVT by computed tomography venography (CTV), which demonstrated occlusion of the superior sagittal sinus (SSS), left transverse sinus (TS), and left cortical veins. Magnetic resonance imaging (MRI) demonstrated edema within the left frontal lobe. The examination for coagulation disorders, infections, de-

Received October 22, 2021; Accepted March 23, 2022

Copyright © 2022 The Japan Neurosurgical Society

This work is licensed under a Creative Commons Attribution-NonCommercial-NoDerivatives International License.

hydration, malignancies, and collagen vascular disease was normal; hence, the causes of his CVT were unknown. Systemic heparin administration was initiated immediately

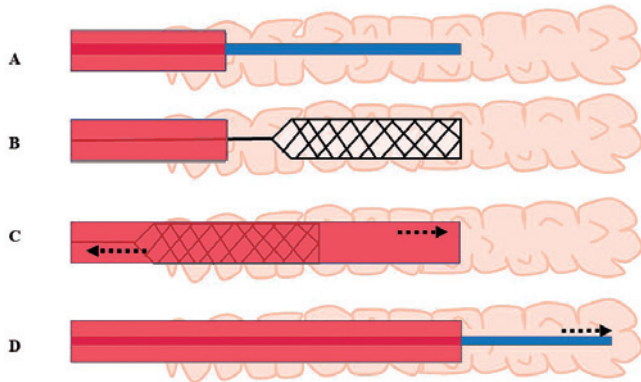


Fig. 1 Schema of our technique. **A.** A microcatheter and an aspiration catheter are navigated into the thrombus as distal as possible. **B.** A stent retriever is deployed from the microcatheter capturing the thrombus. **C.** Under continuous aspiration, the aspiration catheter is pushed forward while the stent retriever is pulled into the aspiration catheter. **D.** The microcatheter is navigated into the thrombus more distally through the advanced aspiration catheter.

upon diagnosis. However, he experienced repeated seizures despite anticonvulsant administration. MRI demonstrated a progression of the edema; thus, we conducted endovascular treatment. Digital subtraction angiography (DSA) demonstrated occlusion of the SSS, left TS, sigmoid sinus, and cortical veins (Fig. 2A). A right femoral venous access was obtained, and a 6-Fr guiding sheath was introduced into the right internal jugular vein. Intravenous heparin was continuously administered at 14400 U/day after diagnosis of CVT and was added during the endovascular procedure to maintain an activated clotting time over 200. A Penumbra 5MAX ACE68 (Penumbra, Alameda, CA, USA) was introduced over a Marksman microcatheter (eV3 Covidien, Irvine, CA, USA) and Traxcess 14 Guidewire (MicroVention, Inc., Tustin, CA, USA) system. We attempted to advance the system into the SSS; however, the Traxcess, Marksman, and 5MAX ACE68 could not gain sufficient entry because of the hard thrombus. The Marksman was navigated into the thrombus as distal as possible over the Traxcess, and a Trevo XP ProVue stent retriever 6 × 25 mm (Stryker, Kalamazoo, MI, USA) was deployed from the Marksman allowing capture of the thrombus using the Trevo retriever (Fig. 2B). Under continuous aspiration, the 5MAX ACE68 was pushed forward while the Trevo retriever and thrombus were then pulled into the 5MAX ACE

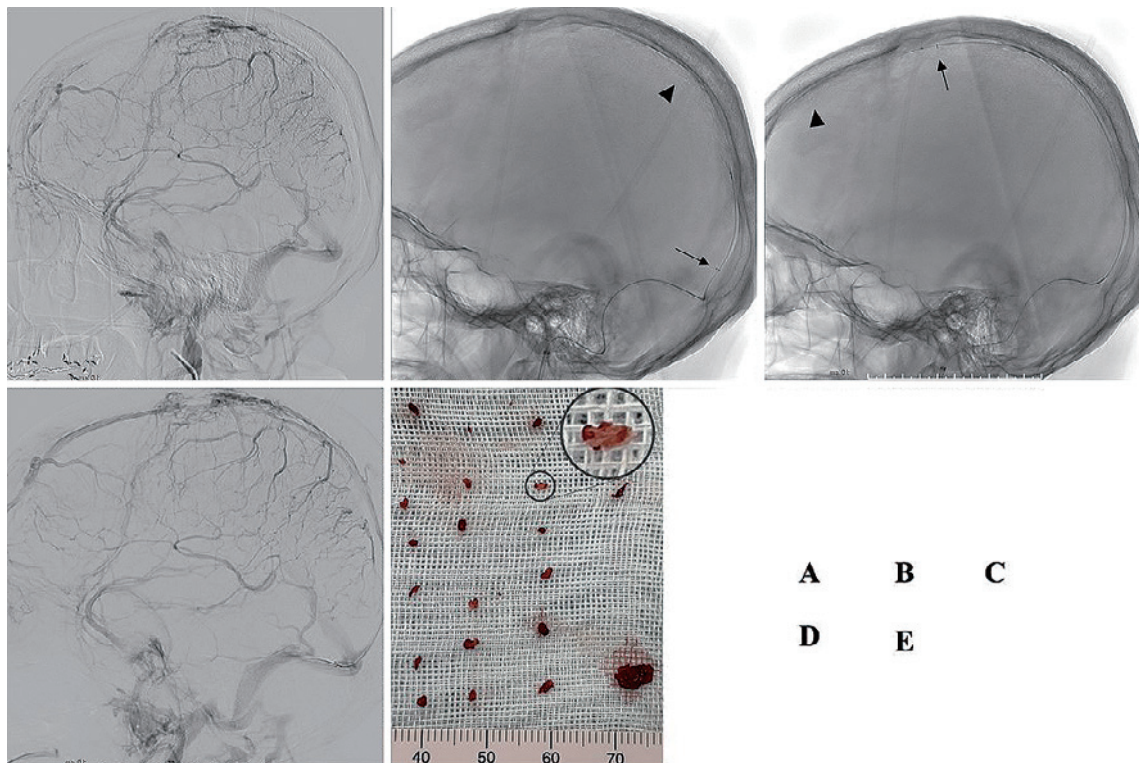


Fig. 2 Treatment of case 1. **A.** Pre-treatment left carotid angiography reveals occlusion of the SSS. **B.** A stent retriever is deployed in the proximal thrombosed segment of the SSS (arrowhead), and an aspiration catheter is positioned in the proximal segment of the SSS (arrow). **C.** The stent retriever and aspiration catheter are advanced into the anterior segment of the SSS. **D.** Final angiography reveals the recanalization of the SSS. **E.** Massive white thrombus is eliminated. SSS: superior sagittal sinus.

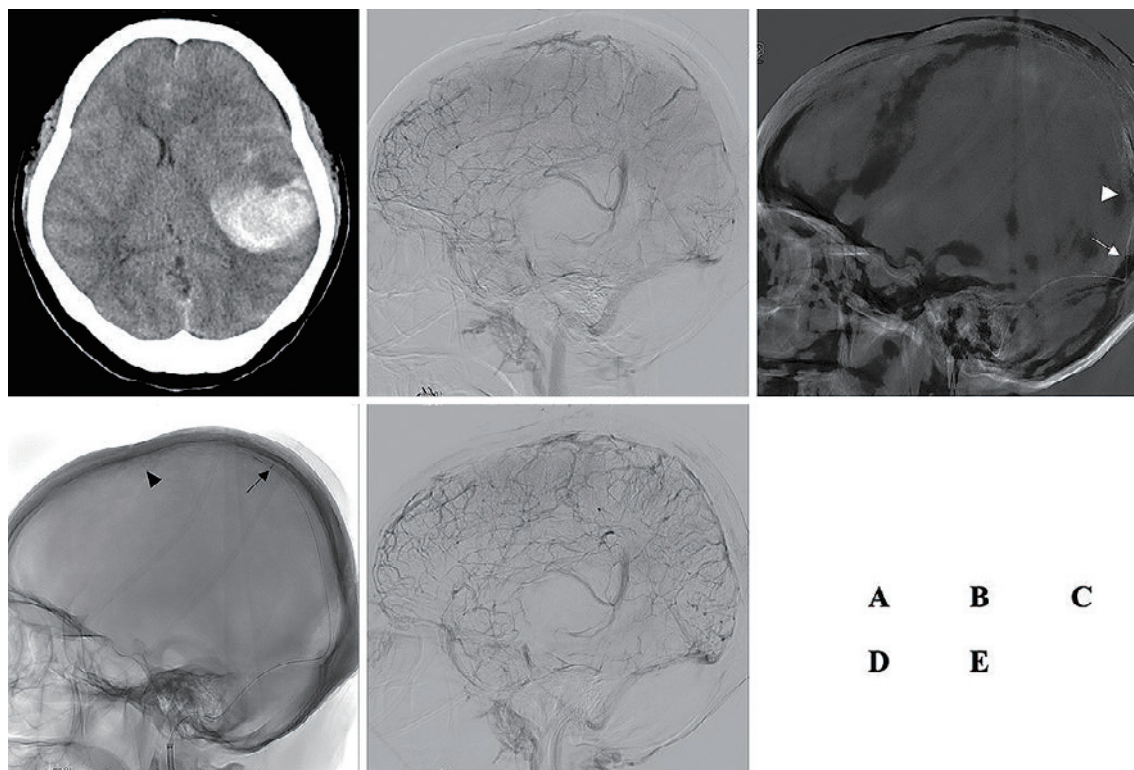


Fig. 3 Treatment of case 2. **A.** Pre-treatment plain CT showed a massive hematoma within the left temporal lobe causing a midline shift. **B–E.** Angiography during thrombectomy. **B.** Pre-treatment left carotid angiography reveals occlusion of the SSS partially straight sinus. **C.** A stent retriever is deployed in the proximal thrombosed segment of the SSS (arrowhead), and an aspiration catheter is positioned in the confluence (arrow). **D.** The stent retriever and aspiration catheter are advanced into the middle of the SSS. **E.** Final angiography reveals the recanalization of the posterior two-thirds of the SSS and antegrade venous flow of the SSS. CT: computed tomography; SSS: superior sagittal sinus.

68, which advanced the 5MAX ACE68 distally. This manipulation allowed the Marksman and Traxcess to be navigated coaxially into the thrombus more distally through the advanced 5MAX ACE68 at the next pass. We repeated this technique from the proximal to the distal segment of the occluded SSS (Fig. 2C). After the third manipulation, aspiration catheter arrived to the non-occluded SSS. A bolus dose of 60,000 U of urokinase was administered into the SSS through the aspiration catheter. As the final manipulation, balloon angioplasty was added to improve partial stenosis segment, and we achieved recanalization of the SSS (Fig. 2D). Massive hard thrombi were eliminated using this technique (Fig. 2E). After the endovascular treatment, the patient was maintained on systemic heparin administration and converted to oral rivaroxaban. His headache gradually improved, and seizures were controlled with anticonvulsant therapy. Postprocedural CTV demonstrated recanalization of the SSS, left TS, sigmoid sinus, and cortical veins. MRI demonstrated improvement of the left temporal edema. Twenty-one days after the endovascular treatment, the patient was discharged from our hospital neurologically stable and seizure-free (modified Rankin scale, mRS 0). For 2 years, the patient had no recurrence

of CVT.

Case 2

A 37-year-old woman was admitted to a previous hospital with a 1-week history of headache and loss of consciousness. She took a contraceptive for dysmenorrhea. She was diagnosed with CVT by MRI/magnetic resonance venography, which demonstrated occlusion of the SSS, straight sinus, left TS, and sigmoid sinus with edema on the left cerebral hemisphere. On the day of admission, she was stuporous, and CT demonstrated a massive hematoma within the left temporal lobe causing a midline shift (Fig. 3 A). The patient was transferred to our hospital for further management. We immediately performed endovascular treatment followed by surgical hematoma evacuation. DSA demonstrated occlusion of the SSS, left TS, sigmoid sinus, and partially straight sinus (Fig. 3B). A right femoral venous access was inserted, and a 6-Fr guiding sheath was introduced into the right internal jugular vein. A bolus dose of 3,000 U of heparin followed by 1,000 U of heparin was intravenously administered during the procedure. A 5MAX ACE68 was introduced over a Trevo Pro 18 (Stryker, Kalamazoo, CA, USA) and the Traxcess system into the ve-

nous confluence. First, a Trevo XP ProVue stent retriever 6 × 25 mm was deployed within the thrombus of the left TS and retracted under continuous aspiration, resulting in partial recanalization of the left TS. We then attempted to advance the system into the SSS; however, the Traxcess and Trevo Pro could not pass through the hard thrombus. Thus, the Trevo Pro 18 was navigated into the thrombus as distal as possible over the Traxcess, and a Trevo stent retriever was deployed from the Trevo Pro 18 capturing the thrombus (Fig. 3C). The Trevo retriever and thrombus were then pulled into the 5MAX ACE68 while the 5MAX ACE68 was pushed forward, which advanced the 5MAX ACE68 distally. In the next pass, the Trevo Pro and Traxcess were navigated coaxially into the thrombus more distally through the advanced 5MAX ACE68. We repeated this technique from the proximal to the distal segment of the occluded SSS (Fig. 3D). We achieved recanalization of the posterior two-thirds of the SSS and confirmed an antegrade venous flow of the SSS (Fig. 3E). We did not administer a thrombolytic agent to this patient because of the intracerebral hematoma. We ended the procedure at this point because she became comatose and the anisocoria appeared. We judged that the objective of the procedure was achieved as the cerebral venous drainage tract was secured. Subsequently, we conducted surgical hematoma evacuation. After endovascular and surgical treatment, the patient was maintained on systemic heparin infusion and was converted to oral edoxaban. Postprocedural CTV demonstrated recanalization of the SSS, straight sinus, left TS, and sigmoid sinus, and the cerebral edema was improved as shown on MRI. Her conditions were improved clinically, except for mild cognitive impairment and right hemiparesis. Twenty-eight days after endovascular treatment, the patient was transferred to a rehabilitation hospital, and after 56 days, she was discharged with slight motor aphasia and no paresis. Ninety days after endovascular treatment, she displayed significant recovery (mRS 2) and has not had a recurrence of CVT for 17 months until the present.

Discussion

We detailed our “digging through thrombus technique” performed in patients requiring endovascular treatment with hard and extensive thrombus. This technique allowed recanalization of the occluded sinus and achieved favorable outcomes. Major guidelines recommend anticoagulation with systemic heparin administration as the first-line treatment for CVT regardless of the presence of intracerebral hemorrhage.^{2,5} However, there remains a subgroup of patients presenting with clinical deterioration despite adequate heparinization, in which endovascular treatment is considered to achieve rapid sinus recanalization and prevent permanent disability or death. Additionally, in a randomized clinical trial of patients with severe CVT, the endovascular treatment decreased the frequency of seizures

compared to systemic anticoagulation,⁵ which indicates that rapid venous drainage reperfusion can decrease the chance of refractory epilepsy. Various endovascular techniques including intrasinus thrombolysis, such as direct urokinase or tissue plasminogen activator infusion, mechanical thrombectomy, such as balloon angioplasty, aspiration catheter and/or stent retriever, and rheolytic thrombectomy, such as AngioJet, for severe CVT have been reported recently^{4,6}; however, no specific endovascular technique has been established. Literature on the experience of surgeons using endovascular treatment is promising; however, these are limited to case series and uncontrolled trials.⁵

Systematic reviews of CVT treated with endovascular treatment by Siddiqui et al.⁴ and Ilyas et al.⁶ reported 185 cases from 42 studies and 235 cases from 17 studies, respectively. These reviews were summarized mainly at pre-clot retrieval treatment era; therefore, intrasinus thrombolysis was performed in 71%⁴ and 87.6%⁶ of cases, respectively. Siddiqui et al.⁴ reported that AngioJet was used in 40% of cases, and Ilyas et al.⁶ reported that balloon-assisted thrombectomy and AngioJet were performed in 23.8% and 25.5% of cases, respectively. In the reviews by Siddiqui et al.⁴ and Ilyas et al.,⁶ complete recanalization rates of CVT were 74% and 69%, respectively. Siddiqui et al.⁴ reported a favorable outcome of 84% and mortality rate of 12%, whereas Ilyas et al.⁶ reported a neurological intact of 34.7% and mortality rate of 14.3%. Mechanical thrombectomy can achieve more rapid recanalization and increase the surface of the thrombus exposed to thrombolysis,⁷ resulting in reduced hemorrhagic complications by decreasing the amount of thrombolytic required.⁸ Combined techniques using a stent retriever and aspiration catheter have been recently reported and are summarized in Table 1.⁸⁻¹¹ Including our two cases, we were able to confirm in detail six cases of CVT treated with a combined technique of aspiration catheter and stent retriever. All six cases showed from somnolence to coma status before treatment. Four of six patients showed complete recanalization of occluded sinus, and one patient showed complete recanalization of occluded SSS and partial recanalization of occluded left TS. Five of six patients showed mRS 0-2 at 90 days, and one patient was able to ambulate with assistance at 11 days after treatment. Mokin et al.⁹ reported that another patient with CVT treated with a combined technique showed good recanalization. Compared to cases reported in systematic reviews,^{4,6} combined technique was shown to have the potential to achieve good outcomes for patients with CVT. For the treatment of remaining mural thrombus after recanalization of occluded SSS in our case 1, we used a thrombolytic agent and balloon angioplasty. In contrast, we did not use these techniques for emergent treatment of intracerebral hemorrhage in our case 2. Canhao et al.¹² suggested a relationship between intrasinus thrombolysis and intracerebral hemor-

Table 1 Summary of cases of central venous thrombosis treated with combined thrombectomy

Case	Author (year)	Age/sex	Symptom	Targeted sinus	Aspiration catheter	Stent retriever	Technique	Angiographical outcome	mRS at 90 days
1	Raychev et al. (2014) ¹⁰⁾	27y/M	Generalized seizure	SSS	5MAX ACE	Solitaire FR	Solitaire is pulled into positioned 5MAX ACE	Complete recanalization	1
2	Mascitelli et al. (2016) ¹¹⁾	17y/M	Somnolence	SSS	5MAX ACE	Trevo	5MAX ACE is passed back and forth with stent anchor	Complete recanalization	– (left foot weakness at 11 days)
3	Mokin et al. (2015) ⁹⁾	30y/M	NIHSS >20	SSS	5MAX ACE	Solitaire FR	Solitaire is pulled into positioned 5MAX ACE	Partial recanalization	2
5	Taniguchi et al. (2017) ⁸⁾	42y/F	Somnolence	Straight sinus	5MAX ACE	Solitaire FR	Withdraw unit of Solitaire and 5MAX Penumbra	Complete recanalization	0
6	Present case	67y/M	Uncontrollable seizure	SSS	5MAX ACE	Trevo	Repeat advancement of 5MAX ACE into thrombus by stent anchor	Complete recanalization	0
7	Present case	27y/M	Deteriorate from stuporous to coma due to ICH	SSS	5MAX ACE	Trevo	Repeat advancement of 5MAX ACE into thrombus by stent anchor	SSS complete recanalization, transverse partial recanalization	2

Abbreviations: M: male; F: female; NIHSS: National Institutes of Health Stroke Scale; ICH: intracranial hemorrhage; SSS: superior sagittal sinus

rhage. Considering that case 2 showed a good outcome without thrombolytic therapy or balloon angioplasty, if recanalization of CVT was achieved by a combined technique, an added endovascular treatment may not be needed for the remaining mural thrombus.

Regarding the method of combined technique, Raychev et al.¹⁰⁾ and Mokin et al.⁹⁾ kept an aspiration catheter stationary at the proximal thrombosed segment and withdrew a deployed stent retriever into the aspiration catheter from the proximal to the distal aspect of the thrombus under continuous aspiration. Mascitelli et al.¹¹⁾ reported a “stent anchor with mobile aspiration technique,” in which a stent retriever was anchored within a thrombosed segment while an aspiration catheter was passed back and forth in the lesion. Taniguchi et al.⁸⁾ navigated an aspiration catheter by stent anchor and achieved recanalization of the straight sinus at one pass. In our cases, the thrombus was too extensive and hard for the existing techniques to achieve recanalization of the occluded sinus. Therefore, a Trevo retriever was deployed and anchored within the proximal thrombosed segment allowing a 5MAX ACE68 to advance over the stent retriever during continuous aspiration. Then, a microcatheter was navigated more distally into the thrombus through the repositioned 5MAX ACE68. With this technique, we achieved recanalization of the occluded sinus and obtained good outcomes. We termed this technique “digging through thrombus technique” because

an aspiration catheter digs a tunnel within the thrombus while disrupting and aspirating the thrombus. Owing to the shorter distance between the aspiration catheter and the stent retriever compared to the other techniques, our technique can obtain more effective support from the aspiration catheter to deliver the micro guidewire and microcatheter coaxially. In addition, the shorter distance might provide lower chances of failure in aspirating the disrupted thrombus resulting in a reduced risk of thrombus migration. Our technique does not require retraction of the entire system during the procedure basically, which enabled us to reduce the procedural time. In case 2, the aspiration catheter was occluded by a thrombus and retracted from the body once. At that time, we quickly navigated the aspiration catheter into the same position. In our technique, we used a Trevo retriever in expectation of an effective cut and retrieval of the hard thrombus because it is designed specifically to integrate and remove thrombus through their large cells, tubular design, and high integration radial force.

However, it is important to note that in our technique, pulmonary embolism might occur at a risk similar to that of other combined techniques if the thrombus is not aspirated by the aspiration catheter. Additionally, we paid attention to not migrate the microcatheter or guidewire to the cortical vein to avoid venous perforation. We advanced the catheter into the occluded sinus carefully with refer-

ring biplane fluoroscopy.

Balloon angioplasty, including a sliding balloon technique, was reported to achieve a rapid recanalization and increase the surface of the thrombus exposed to thrombolysis, especially in a case that had a long thrombosed lesion.¹³⁾ Philips et al.¹⁴⁾ described the first use of wire in conjunction with microsnare for the treatment of CVT with good result. However, these techniques require that the system passes through the thrombosed segment, which was difficult in our cases. It was difficult to adequately insert the microcatheter or balloon alone into the long sinus occlusion with hard thrombus in our cases. In our technique, the coaxial aspiration catheter became a backup for microcatheter insertion to the occluded sinus, and the opened stent retriever support aspiration catheter was the back up for jacking up the occluded sinus. In addition, compared to the microsnare technique, our technique can eliminate more massive thrombi by a single manipulation.

The current therapy for cerebral veins or sinus thrombosis is initiated with heparin. Thereafter, oral anticoagulation with vitamin K antagonists for at least 3 months is recommended. Geisbüsch et al.¹⁵⁾ reported that a factor Xa inhibitor showed a clinical benefit similar to vitamin K antagonist in the treatment of CVT, and we prescribed factor Xa inhibitor for both cases to prevent hemorrhage. No recurrence, or side effect, has occurred as of the present.

The combined use of an aspiration catheter and stent retriever is a technique that has the potential to achieve good outcomes for patients with CVT. Our technique is very effective even in cases with extensive and hard thrombi that are difficult to treat using existing techniques.

Acknowledgments

We would like to thank Taisuke Kitamura, Mio Yokoi, and Takako Maruyama at the Department of Cerebrovascular Disease, Steel Memorial Yawata Hospital, Fukuoka, Japan, for their contributions to this research. We would also like to thank Editage (www.editage.com) for English language editing.

Conflicts of Interest Disclosure

The authors have no conflict of interest to declare.

References

1) Ferro JM, Canhão P, Stam J, Boussier MG, Barinagarrementeria F: Prognosis of cerebral vein and dural sinus thrombosis: results of the International Study on Cerebral Vein and Dural Sinus

Thrombosis (ISCVT). *Stroke* 35: 664-670, 2004

- 2) Lee SK, Mokin M, Hetts SW, et al.: Current endovascular strategies for cerebral venous thrombosis: report of the SNIS Standards and Guidelines Committee. *J Neurointerv Surg* 10: 803-810, 2018
- 3) Kimber J: Cerebral venous sinus thrombosis. *QJM* 95: 137-142, 2002
- 4) Siddiqui FM, Dandapat S, Banerjee C, et al.: Mechanical thrombectomy in cerebral venous thrombosis: systematic review of 185 cases. *Stroke* 46: 1263-1268, 2015
- 5) Coutinho JM, Zuurbier SM, Boussier MG, et al.: Effect of endovascular treatment with medical management vs standard care on severe cerebral venous thrombosis: the TO-ACT randomized clinical trial. *JAMA Neurol* 77: 966-973, 2020
- 6) Ilyas A, Chen CJ, Raper DM, et al.: Endovascular mechanical thrombectomy for cerebral venous sinus thrombosis: a systematic review. *J Neurointerv Surg* 9: 1086-1092, 2017
- 7) Stam J, Majoie CBLM, van Delden OM, van Lienden KP, Reekers JA: Endovascular thrombectomy and thrombolysis for severe cerebral sinus thrombosis: a prospective study. *Stroke* 39: 1487-1490, 2008
- 8) Taniguchi S, Harada K, Kajihara M, Fukuyama K: Combined use of stent-retriever and aspiration thrombectomy for cerebral venous sinus thrombosis involving the straight sinus: a case report. *Interv Neuroradiol* 23: 605-608, 2017
- 9) Mokin M, Lopes DK, Binning MJ, et al.: Endovascular treatment of cerebral venous thrombosis: contemporary multicenter experience. *Interv Neuroradiol* 21: 520-526, 2015
- 10) Raychev R, Tateshima S, Rastogi S, et al.: Successful treatment of extensive cerebral venous sinus thrombosis using a combined approach with Penumbra aspiration system and solitaire FR retrieval device. *J Neurointerv Surg* 6: e32, 2014
- 11) Mascitelli JR, Pain M, Zazour HK, Baxter P, Ghatan S, Mocco J: Sinus thrombectomy for purulent cerebral venous sinus thrombosis utilizing a novel combination of the Trevo stent retriever and the Penumbra ACE aspiration catheter: the stent anchor with mobile aspiration technique. *J Neurointerv Surg* 8: e24, 2016
- 12) Canhao P, Falcao F, Ferro JM: Thrombolytics for cerebral sinus thrombosis: a systematic review. *Cerebrovasc Dis* 15: 159-166, 2003
- 13) Morimoto M, Hattori I, Sugawara M, et al.: Sliding balloon technique to treat acute severe sinus thrombosis: a technical case report. *JNET* 5: 112-117, 2011
- 14) Philips MF, Gagley LJ, Sinson GP, et al.: Endovascular thrombolysis for symptomatic cerebral thrombosis. *JNIS* 90: 65-71, 1999
- 15) Geisbüsch C, Richter D, Herweh C, Ringleb P, Nagel S: Novel factor Xa inhibitor for the treatment of cerebral venous and sinus thrombosis: first experience in 7 patients. *Stroke* 45: 2469-2471, 2014

Corresponding author: Rio Higaki, MD

Department of Neurosurgery, Steel Memorial Yawata Hospital, 1-1-1 Harunomachi, Yahatahigashi-ku, Kita-Kyushu, Fukuoka 805-8508, Japan.

e-mail: higaki.r@ns.yawata-mhp.or.jp