



Oncology

Urothelial carcinoma arising from a bladder diverticulum containing multiple stones: A case report

M. Moussa^a, M. Abou Chakra^{b,*}^a Urology Department, Zahraa University Hospital, Beirut, Lebanon^b Faculty of Medical Sciences, Department of Urology, Lebanese University, Beirut, Lebanon

ARTICLE INFO

Keywords:

Urothelial carcinoma
Bladder
Diverticulum
Stones

Introduction

Bladder diverticulum is mucosal outpouching of the bladder without a muscle layer. The lack of a muscle layer in bladder diverticulum results in a loss of contractility, which results in urine stasis in the diverticulum. Chronic irritation of Intradiverticular urine may cause chronic inflammation or infection or malignant neoplastic change.¹ The incidence of Intradiverticular neoplasms was reported to be between 0.8% and 10% in most studies.² The main clinical presentation is painless gross hematuria for diverticular tumor. The most common histological subtype of diverticulum tumors is transitional cell carcinoma (TCC) and squamous cell carcinoma (SCC).

Case report

A 77-year old man heavy smoker known to have hypertension, diabetes type 2 and BPH on medical treatment presented with frank hematuria. History goes back to few years ago when the patient complains of recurrent hematuria that was not investigated. Examination revealed normal pulse, blood pressure, respiratory rate and temperature, Oxygen saturations were 93% on room air. Examination of the heart, chest and abdomen was normal except for palpable suprapubic hard mass. Initial blood tests included a white blood cell count of $6 \times 10^9/L$, Hb level 9.9g/dl, urine analysis shows numerous RBC.

A multiphasic computed tomography scan showed a large diverticulum with a tumor (8.2*5 cm) within it with no enlarged lymph nodes with narrow diverticular neck and multiple stones within the diverticulum (Fig. 1A and B).

The patient underwent cystoscopy under anesthesia. A large bulging

on the left lateral wall of the bladder was identified and the junction between the bladder and diverticulum cannot be crossed so biopsy not taken. The cystoscopy also showed moderate bladder trabeculation and no other diverticuli. In a second procedure after discussing the treatment plan with the patient and his family and with the difficulty to reliably predict stage and grade preoperatively a decision to do partial cystectomy with bilateral pelvic lymph node dissection is made (Fig. 2). The pathology revealed high grade papillary urothelial carcinoma with no muscularis propria identified and negative lymph node (Fig. 3). After 6 months, patient underwent cystoscopy for control that was free of tumor recurrence.

Discussion

Neoplasms arising in urinary bladder diverticula are uncommon, but not rare. 0.8% and 10% of patients with vesical diverticula show neoplasm development within the diverticula.² Most malignant tumors in vesical diverticula are of transitional type (about 78%), followed by squamous cell carcinoma (17%), a combination of transitional and squamous cell types (2%), and adenocarcinoma (2%).³ Painless hematuria is the cardinal symptom for diverticular tumors, as in ordinary bladder tumors.² Bladder tumors arising within a diverticulum are difficult to diagnose, bladder diverticulum neoplasms are characterized by early transmural invasion and a tendency for higher histopathological grades, which make prompt diagnosis and treatment crucial. Filling defects caused by these tumors are not always visualized. Cross-sectional imaging methods, including ultrasonography, CT and magnetic resonance imaging (MRI) have to be used singly or in combination, in neoplasms of the lower urinary tract.⁴ Cystoscopy is a reliable

* Corresponding author.

E-mail addresses: mohamadamoussa@hotmail.com (M. Moussa), mohamedabouchakra@hotmail.com (M. Abou Chakra).

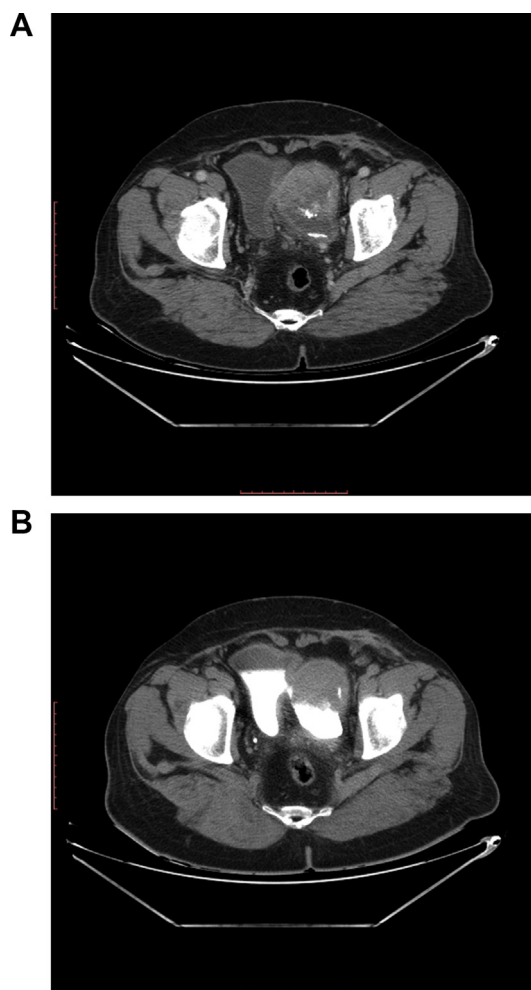


Fig. 1. A: multiphase computed tomography scan shows a large bladder diverticulum with a tumor (8.2*5) with multiple stones. B: CT urogram shows small diverticular communication within the bladder lumen.

method for diagnosing most bladder neoplasms, certain diverticula are inaccessible or may be missed, particularly those with a narrow orifice or orifice obstructed by the tumor as seen in our case. The pathophysiology of tumor occurrence was suggested to be long-term urinary stasis with chronic infection and inflammation leading to the development of dysplasia, leukoplakia and squamous cell metaplasia in approximately 80% of all diverticula.¹ Bladder diverticulum neoplasms have a poor prognosis because the diagnosis is late and associated with early invasion, which results from the anatomy of the diverticulum that lack muscular fibers.² The transurethral approach for the treatment of diverticular tumors is often difficult and inappropriate due to the narrow diverticular neck and the risk of bladder perforation. According to Baniel et al. superficial Intradiverticular tumors may be treated conservatively, but when dealing with invasive bladder diverticula tumors (T1), disease management should probably be aggressive (radical cystectomy versus diverticulectomy), although the small number of cases precludes a clear recommendation of cystectomy versus local resection.⁵ Micic and Ilic reported a 13 patients treated with surgical excision and noted a cancer-specific survival of 46%.³ Cheng et al. corroborated this result and indicated that neoplasms originating in a bladder diverticulum are characterized by a high incidence of local recurrence. Appropriate screening intervals must be determined. Only a few case reports of bladder diverticulum with stones and TCC have been reported as in our case, this relation is not well known.

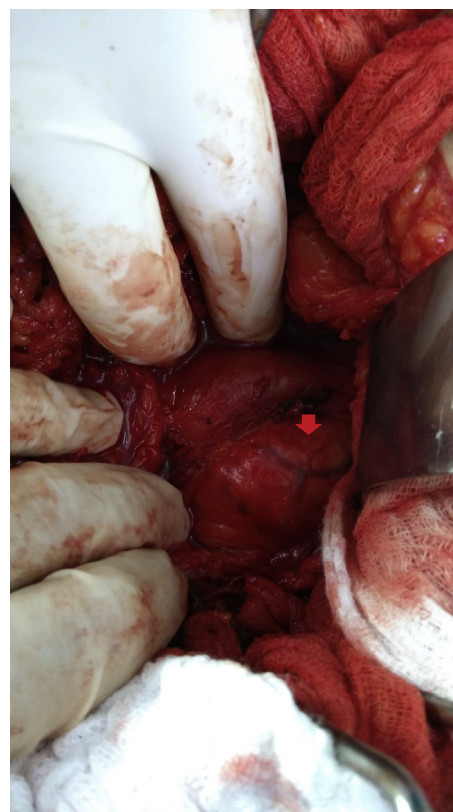


Fig. 2. During partial cystectomy, red arrow: bladder diverticulum. (For interpretation of the references to colour in this figure legend, the reader is referred to the Web version of this article.)

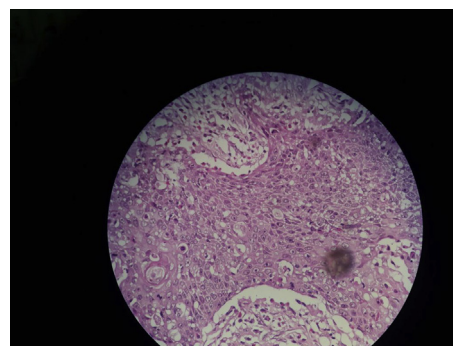


Fig. 3. High Grade Papillary Urothelial Carcinoma within the bladder diverticulum.

Conclusion

Neoplasms within bladder diverticula present diagnostic difficulties. Imaging plays an important role in identifying bladder diverticula. A conservative bladder-sparing treatment can be achieved and subsequently followed by vigilant cystoscopy.

Appendix A. Supplementary data

Supplementary data related to this article can be found at <https://doi.org/10.1016/j.eucr.2018.07.013>.

References

- Chen HE, Lin YC, Cheng YH. Urothelial carcinoma arising within bladder diverticulum-Report of a case and review of the literature. *Urol Sci.* 2016;27:177–180.

2. Melekos MD, Asbach HW, Barbalias GA. Vesical diverticula: etiology, diagnosis tumorigenesis and treatment. Analysis of 74 cases. *Urology*. 1987;30:453–457.
3. Micic S, Ilic V. Incidence of neoplasm in vesical diverticula. *J Urol*. 1983;129:734–735.
4. Dondalski M, White EM, Ghahremani GG, Patel SK. Carcinoma arising in urinary bladder diverticula: imaging findings in six patients. *AJR (Am J Roentgenol)*. 1993;161(4):817–820.
5. Baniel J, Vishina T. Primary transitional cell carcinoma in vesical diverticula. *Urology*. 1997;50:697–699.