



My Way

A Simple Alternative: A Minimal-Touch Technique for Placing Breast Implants

Vanessa Molinar, MD; Karan Chopra, MD[®]; and Joe Gyskiewicz, MD, FACS

Aesthetic Surgery Journal Open Forum 2020, 1–3

© 2020 The Aesthetic Society.

This is an Open Access article distributed under the terms of the Creative Commons Attribution Non-Commercial License (<http://creativecommons.org/licenses/by-nc/4.0/>), which permits non-commercial re-use, distribution, and reproduction in any medium, provided the original work is properly cited. For commercial re-use, please contact journals.permissions@oup.com
DOI: 10.1093/asjof/ojaa015
www.asjopenforum.com

OXFORD
UNIVERSITY PRESS

Abstract

This is a single-surgeon experience detailing the senior author's (J.G.) minimal-touch technique for placement of breast implants. Adams et al. 14-point plan has been incorporated into the technique, and the implant box paper cover sheet is used as a barrier between the patient and the implant near the incision during placement. Over a period of ten years, the senior author reports a less than 1% development in capsular contracture using this technique and no implant fractures. These findings elucidate the importance of describing this alternative technique to other barriers currently on the market.

Level of Evidence: 4

Editorial Decision date: April 10, 2020; online publish-ahead-of-print April 15, 2020.



Capsular contracture remains the leading cause of revisional breast surgery in both cosmetic breast augmentation and breast reconstruction.¹ The leading hypothesis for etiology of capsular contracture supported in the literature is bacteria-related subclinical infections.²⁻⁵ In an attempt to prevent the development of capsular contracture, surgeons have widely adopted the “no touch” technique (Adams et al³ 14-point plan), antibiotic irrigation of the pocket, placing implants in a submuscular position, and utilization of the Keller funnel (Keller Medica, Stuart, FL) to limit skin contact.^{2,3}

The Keller Funnel is an FDA approved class I device composed of a vinyl sleeve with a hydrophilic inner coating. Multiple studies aimed to assess its ability to decrease skin-to-implant contact and thus preventing the development of capsular contracture. Newman and Davison⁶ have reported their experience with the Keller funnel and demonstrated a 10% incidence of capsular contraction without the use of the Keller funnel and 1.3% in patients with the funnel, with an overall reduction in the incidence by 87%.

The existing body of evidence supports the use of an additional barrier to decrease the skin-to-implant contact. The senior author (J.G.) has developed a simple reproducible technique using the packaged implant cover as an alternative option to the Keller funnel in 2431 breast augmentations over the last 10 years. There are no articles in the literature describing simple alternative techniques to the Keller funnel.

Dr Molinar is a Resident, Department of Surgery, Division of Plastic Surgery, Mayo Clinic, Rochester, MN. Dr Chopra is a Resident, Department of Surgery, Division of Plastic Surgery, The Johns Hopkins University School of Medicine, Baltimore, MD. Dr Gyskiewicz is a Plastic Surgeon, Cleft Palate Craniofacial Clinics, University of Minnesota, School of Dentistry, Burnsville, MN.

Corresponding Author:

Dr Joe Gyskiewicz, Cleft Palate Craniofacial Clinics, University of Minnesota, School of Dentistry, 303 E. Nicollet Blvd. #330, Burnsville, MN 55337, USA.

E-mail: drjoe@tcplasticsurgery.com

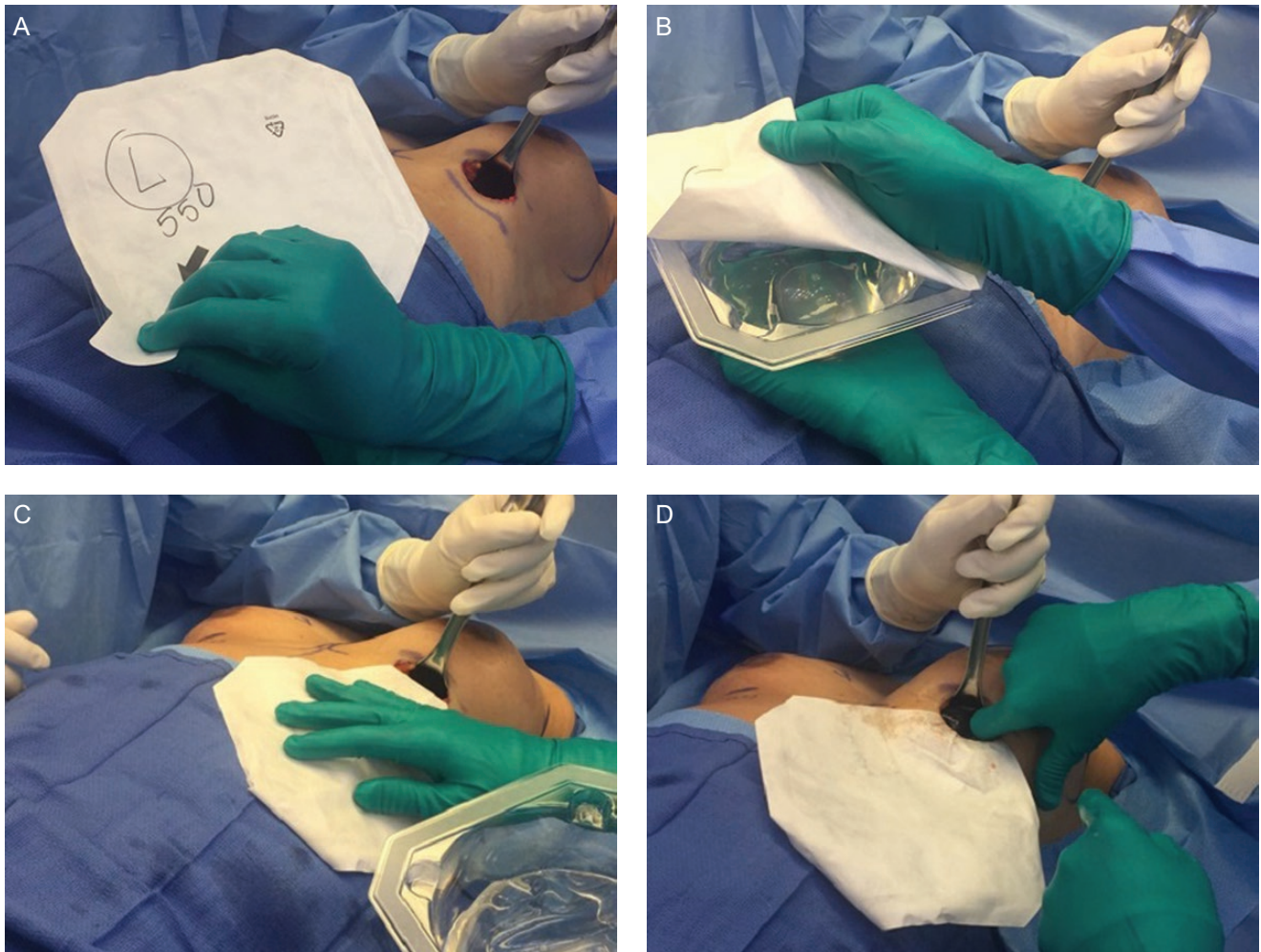


Figure 1. (A) A 36-year-old female undergoing primary breast augmentation for micromastia. The implant plastic container is partially opened, the antibiotic solution is placed into the implant plastic container, and the paper is saved for the following step. (B) Paper cover preserved. (C) Implant container cover placed over patient's chest and tucked into pocket. A small amount of antibiotic solution is poured over the cover for lubrication. (D) Assistant retracts (lifting pocket after implant seals incision creating negative pressure), and the implant is placed into the pocket while avoiding contact with the skin.

MY EXPERIENCE

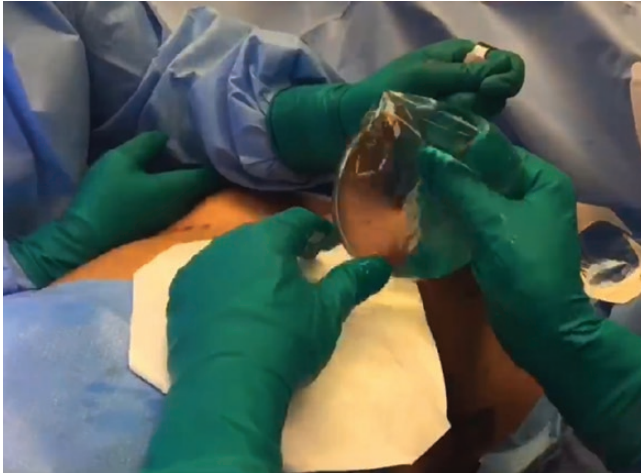
The surgical technique was standardized as follows: Adams et al's³ 14-point plan is utilized as a standard for aseptic technique. After the pocket dissection and irrigation with an antibiotic solution, including 80 mg Gentamycin, 1 g Ancef, and 50,000 units Bacitracin in 1 liter of saline, gloves are exchanged, and the implant box is opened. The paper cover of the implant box is detached and placed on top of the patient's chest and into the pocket so that no contact is made between the implant and the skin (Figure 1A and B) (Video 1). The assistant performs retraction using a Richardson's retractor, and the implant is placed in the dissected pocket (Figure 1C and D). The access incision is closed using standard layered closure techniques.

Advantages of Technique

This technique is sterile and obviates the need for an additional cost to surgery as the cover is included in the box for the implant.

OUTCOMES

A total of 2431 breast augmentations were performed over 10 years, using the above-described technique to minimize skin-to-implant touch. There were 21 patients (<1%) who developed capsular contracture, 7 of which were grade III-IV capsular contracture, 14 patients (3%) developed grade 1-2 capsular contracture. Of the 7 patients who developed grade III-IV capsular contracture, 1



Video 1. Watch now at <http://academic.oup.com/asjof/article-lookup/doi/10.1093/asjof/ojaa015>

was through the IMF incision and the rest were through axillary incisions. Five patients required complete capsulectomy, with a 0.2% reoperative rate for treatment of capsular contracture. There were 9 hematomas, 1 post-operative infection, 0 seroma, and 31 implant exchanges (for size change). There were no cases of implant fracture with this technique.

Our goal was to demonstrate a low incidence of capsular contracture and infection utilizing the implant box cover to prevent skin-to-implant contact as an alternative to the Keller funnel to overcome known shortcomings: (1) funnel implant delivery devices are associated with added cost and (2) use of a single funnel on both breasts transfers biocontamination from the initial incision to the opposite pocket. The results of this technique confirm that our rates of capsular contracture (<1%) are comparable to those reported in the literature, ranging from 5% to 50%.

CONCLUSIONS

There are limitations to this report, as we did not compare our outcomes to cases where a Keller funnel is used. Other limitations include lack of control group and inability

to demonstrate stress to implant from Richardson retractor objectively. The goal of this article is not to disprove the efficacy or suggest a replacement to the Keller funnel, but to offer an alternative approach of minimizing the amount of skin contact to the implant. Some may even suggest that this approach is inferior to the Keller funnel; however, we must be able to improvise and have an armamentarium of options should one day, a Keller funnel not be available in the operating suites. There is beauty in simplicity and, in a field where outcomes and options are of the utmost importance, we show that a simple and cost-effective item can provide acceptable outcomes.

Disclosures

J.G. is a paid consultant for Mentor (commercial pursuit breast implant patent #62736271). The other authors declared no potential conflicts of interest with respect to the research, authorship, and publication of this article.

Funding

The authors received no financial support for the research, authorship, and publication of this article.

REFERENCES

1. Moyer HR, Ghazi B, Saunders N, Losken A. Contamination in smooth gel breast implant placement: testing a funnel versus digital insertion technique in a cadaver model. *Aesthet Surg J.* 2012;32(2):194-199.
2. Adams WP Jr. Capsular contracture: what is it? What causes it? How can it be prevented and managed? *Clin Plast Surg.* 2009;36(1):119-126, vii.
3. Adams WP Jr, Culbertson EJ, Deva AK, et al. Macrot textured breast implants with defined steps to minimize bacterial contamination around the device: experience in 42,000 implants. *Plast Reconstr Surg.* 2017;140(3):427-431.
4. Wan D, Rohrich RJ. Modern primary breast augmentation: best recommendations for best results. *Plast Reconstr Surg.* 2018;142(6):933e-946e.
5. Flugstad NA, Pozner JN, Baxter RA, et al. Does implant insertion with a funnel decrease capsular contracture? A preliminary report. *Aesthet Surg J.* 2016;36(5):550-556.
6. Newman AN, Davison SP. Effect of keller funnel on the rate of capsular contracture in periareolar breast augmentation. *Plast Reconstr Surg Glob Open.* 2018;6(6):e1834.