

Contents lists available at [ScienceDirect](https://www.sciencedirect.com)

## International Journal of Surgery Case Reports

journal homepage: [www.casereports.com](http://www.casereports.com)

## Unusual Richter's Hernia: Impacted foreign body leading to incarceration and perforation – A rare clinical entity

Suhail Khuroo<sup>a,\*</sup>, Ajaz Ahmed Wani<sup>a</sup>, Ishmeet Kaur<sup>b</sup>, Avinash Razdan<sup>b</sup>, Geetanjali Gupta<sup>b</sup><sup>a</sup> Department of Surgical Gastroenterology, Shri Mata Vaishno Devi Narayana Super-Specialty Hospital, Kakryal, Jammu and Kashmir, 182320, India<sup>b</sup> Department of Radiodiagnosis, Shri Mata Vaishno Devi Narayana Super-Specialty Hospital, Kakryal, Jammu and Kashmir, 182320, India

## ARTICLE INFO

## Article history:

Received 1 January 2021

Received in revised form 18 January 2021

Accepted 18 January 2021

Available online 29 January 2021

## Keywords:

Richter's hernia  
Incarcerated hernia  
Foreign body  
Unusual hernia  
Case report

## ABSTRACT

**INTRODUCTION & IMPORTANCE:** Richter's hernia is a clinically deceiving entity as is particularly associated with high morbidity and mortality which can be abated by timely diagnosis and surgery. Direct inguinal hernias having a wide neck have lesser chances of incarceration and strangulation when compared to indirect inguinal hernias. The knowledge about this type of hernia is especially important in the context of laparoscopy as majority of the laparoscopic port site hernias are characteristically Richter's type in configuration. The objective of this report is to highlight the unusual presentation of the case and sine quo non of prompt diagnosis and timely surgery remains the cornerstone of management.

**CASE PRESENTATION:** We report a case of Richter's hernia incarcerated due to an impacted foreign body (match stick) through a direct inguinal hernia. Patient presented with a painful, non-expansile, tender swelling in left groin. Patient was diagnosed with a complicated inguinal hernia and underwent exploration with resection of involved bowel segment and primary repair of hernia.

**CLINICAL DISCUSSION:** Richter's hernia is a rare abdominal wall hernia specifically known for its unusual and delayed presentation leading to high rates of morbidity and mortality. Direct inguinal hernias are less prone to complications like obstruction, strangulation and incarceration owing to presence of a wide neck. Clinical suspicion, prompt radiological diagnosis and timely surgery can lead to an uneventful recovery. **CONCLUSION:** Surgery is the only treatment, but timely surgery remains the golden opportunity. Critical in repair is the evaluation of intestinal viability.

© 2021 The Author(s). Published by Elsevier Ltd on behalf of IJS Publishing Group Ltd. This is an open access article under the CC BY-NC-ND license (<http://creativecommons.org/licenses/by-nc-nd/4.0/>).

## 1. Introduction

Groin hernias comprise majority of hernias accounting for seventy-five percent of abdominal wall hernias [1]. Inguinal hernias comprise of 95% of the groin hernias while the remaining 5% are femoral hernias [2]. Two-thirds of the inguinal hernias comprise of indirect hernia in which abdominal contents protrude through deep inguinal ring and the remaining are direct inguinal hernias occurring medial to inferior epigastric vessels within the Hassalbach's triangle.

Richter's hernia is characterised by entrapment and strangulation of a circumference of a bowel loop wall through a potential hernial defect in the abdominal wall. It is an unusual clinical condition with an exceptional clinical course more often leading to mis-diagnosis. Owing to the high complication and mortality rates

[3], precise and prompt pre-operative diagnosis and surgical intervention are obligatory.

The work has been reported in line with the SCARE criteria.

Agha RA, Franchi T, Sohrabi C, Mathew G, for the SCARE Guideline: Updating Consensus Surgical CAse REport (SCARE) Guidelines, International Journal of Surgery 2020; 84:226-230 [4].

## 2. Historical background

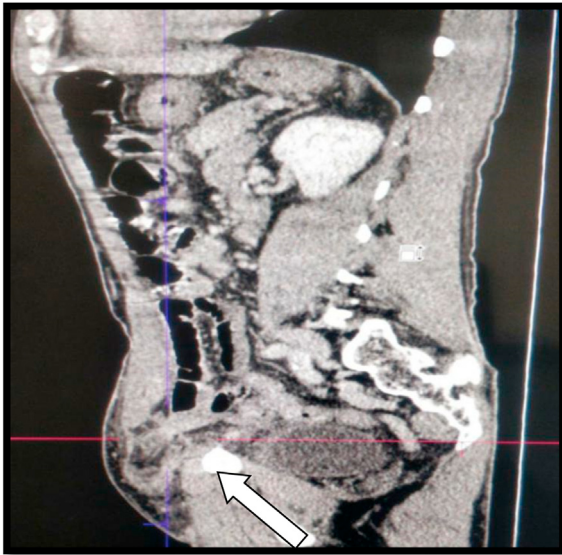
Fabricius Hildanus in 1598 originally reported the first case of a Richter's hernia. However, August Gottlob Richter gave the first technical explanation of this particular hernial type in 1778, describing it as "the small rupture." In 1887, an outstanding outline on the topic was delivered by Sir Frederick Treves and proposed the title "Richter's hernia."

## 3. Case history

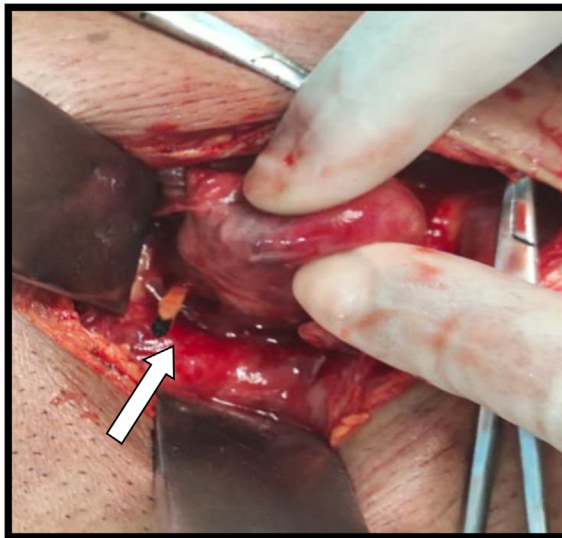
A 72 year old gentleman with no known co-morbidities or significant drug or allergy history presented to ED with complaints of pain and swelling over his left groin over a period of previ-

\* Corresponding author at: 201-Dhanwantri Bhawan, Shri Mata Vaishno Devi Narayana Super-Specialty Hospital, Kakryal, Katra, Jammu and Kashmir, 182320, India.

E-mail address: [skhuroo@gmail.com](mailto:skhuroo@gmail.com) (S. Khuroo).

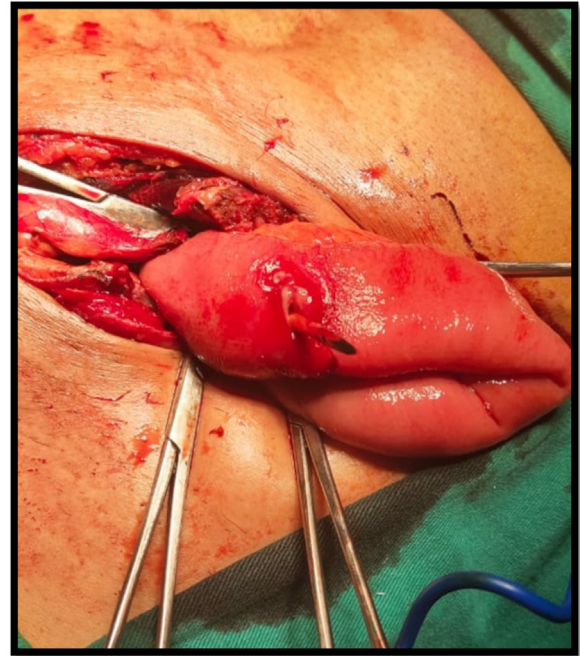


**Image 1.** CT scan depicting a bowel loop (Arrow) herniating into inguinal hernia.



**Image 2.** Hernial sac with impacted foreign body (Match stick).

ous few days. The pain was not associated with change in size of the swelling, abdominal distension, constipation or any fever. Patient was examined and evaluated. An abdominal US showed left inguinal hernia with a bowel loop. A CECT abdomen was performed which revealed a loop of small bowel herniating through the hernia defect (**Image 1**). The patient was informed about the risks and outcomes of the surgery. The patient accepting the proposed treatment, surgery was performed by Consultants in department of Surgical Gastroenterology. After initial stabilisation patient underwent urgent surgery via a groin incision under spinal anaesthesia. Intraoperative findings confirmed a tense direct hernial sac filled with purulent exudate and an impacted foreign body (match stick) perforating the hernial sac (**Image 2**). On exploration of hernial sac a segment of ileum was delivered with a perforation on the anti-mesenteric border with the impacted foreign body (**Image 3**). Resection anastomosis of the ileal segment was done along with Bassini's tissue type hernia repair. Patient was managed with IV antibiotics (Amoxy-clavulanate 1.2 g BD), analgesics (Paracetamol 1 g TDS) and antiemetic (Ondansetron 4 mg BD) in post opera-



**Image 3.** Perforation over anti-mesenteric side due to impacted foreign body.

tive period. Antibiotics were later changed according to culture (*Streptococcus pneumonia*). Patient resumed full oral diet from POD 3. Abdominal and subcutaneous vacuum drains were removed on POD 5 and patient was discharged on POD 6. Patient had an uneventful recovery. No post operative complications were noted. Patient was followed up in OPD for suture removal.

#### 4. Discussion

Indirect inguinal hernias hold a higher risk of obstruction, incarceration and strangulation than its direct counterpart. Two studies compared the rates of incarceration in indirect and direct inguinal hernia and found incidence of about 34.1% versus 16.7% and 32.6% versus 10.3% in indirect versus direct hernia respectively [5].

In a Richter's hernia, the antimesenteric border of intestine usually protrudes into the hernial sac but never involves the entire circumference of the bowel. The hernial sac usually contains a segment of the distal ileum [6], though any part of the gastrointestinal tract may be involved including stomach [7], part of colon or the appendix [8,9]. Richter's hernia are commonly encountered in the femoral ring (36–88%), inguinal canal (12–36%) and incisional hernia (4–25%) [10,11]. Less often umbilical [12], supra-vesical [13], spigelian [14], obturator [15], triangle of Petit [16], Morgagni [17], sacral foramen [18], internal [19] or post-traumatic diaphragmatic hernias [20] have been reported.

The occurrence of a taut constricting ring is a pre-condition for strangulation and compromised blood flow ultimately leading to ischemia and gangrene of the incarcerated bowel segment [21]. Richter's hernias are predisposed to early gangrenous changes as compared to ordinary strangulated ones. Horbach [22] reported 45 Richter's hernias among 146 strangulated hernias and out of these 45 cases found necrosis of the bowel wall in 31 cases (69%).

The liberal use of minimally invasive abdominal surgery has led to a novel potential site for formation of Richter's hernias. Since the foremost report of a laparoscopic port site hernia by Bourke in 1977 [23], analogous case reports have increasingly been published [24–26]. The size and sites of laparoscopic trocars, especially 10–20 mm size, idyllically fulfil the environment for development of a Richter's hernia at these sites.

Ingestion of foreign bodies is not an unusual event and occurs more frequently in adults with psychiatric conditions, impaired mental ability, alcohol insobriety, imprisoned inmates and patients with dentures [27]. Mostly these ingested foreign bodies pass unexpectedly with masterly inactivity [28]. Nonetheless only a few cases can lead to impaction or intestinal perforation [29,30]. Pointed objects like toothpicks, paper clips and animal or fish bones seem to have a more chances of causing perforation [27–29]. Ingested foreign bodies tend to obstruct, get impacted or perforate gastrointestinal tract at sites of angulations or constrictions [28,29]. Foreign bodies leading to perforation of herniated viscera are exceptionally rare and only a few cases have been reported in the literature. Akhtar et al. [30] reported 3 cases of swallowed chicken bones causing gut perforation, out of which 2 were associated with abdominal hernias. Brantigan et al. [31] reported a case of Richter hernia with an abscess cavity containing a chicken bone. Hartin et al. reported a case of a 10 year old girl with an incarcerated indirect inguinal Richter hernia with perforation secondary to a lollipop stick [32]

Radiological investigations which can be useful to diagnose the condition include an abdominal ultrasound and a CT scan [33]. An Ultrasound can recognize the involved bowel wall component, and assess its perfusion and wall edema and compare with the circumferential non-pathological part. A CT scan can reveal the hernial sac contents and differentiate from abdominal mass or abscess [34].

The management is centered upon timely surgical intervention. Critical in repair is the assessment of intestinal viability. Richter's hernias without evident signs of perforation or strangulation can be treated as usual uncomplicated hernias. In contrast to uncomplicated hernias primary attempts at reducing the hernia contents ought to be avoided as the hernial sac contents need to be examined by direct inspection for viability. Perforated hernias usually need exploratory laparotomy to manage the affected bowel accurately. A diagnostic laparoscopy is an acceptable option to assess the bowel, accompanied with laparoscopic hernia repair especially in obese patients considering the affected portion of bowel is not unhealthy or ischemic [35]. The key point in management of such patients ought to be to avoid spillage of contaminated hernia contents into the peritoneal cavity and lessen the systemic toxin load produced by the herniated gangrenous tissues.

## 5. Conclusion

Richter's hernia is a rare clinical entity. Direct inguinal hernias have a less likelihood of obstruction and incarceration. Complicated hernias are particularly associated with high morbidity and mortality unless managed with timely diagnosis and surgery. Richter's hernia has gained importance in the context of laparoscopy with majority of port site hernias being Richter's type of hernia. Surgery remains the only treatment, but timely surgery is the crux to avoid undesirable morbidity and mortality.

## Conflicts of interest

The authors declare no competing interests.

## Funding

No funding received for the work reported.

## Ethical approval

Ethical approval has been taken with regards to publication and maintaining the non-disclosure of identity of patient.

## Consent

Written informed consent was obtained from the patient for publication of this case report and accompanying images.

A copy of the written consent is available for review by the Editor-in-Chief of this journal on request.

## Author contribution

1. Dr Suhail Khuroo - Conceptualised the case report and drafted the manuscript.
2. Dr Ajaz Wani - Literature review and drafting of manuscript.
3. Dr Ishmeet Kaur - Literature review and radiology images.
4. Dr Avinash Razdan - Review of literature and drafting of discussion.
5. Dr Geetanjali Gupta - Review of literature and supervision.

## Registration of research studies

Not applicable.

## Guarantor

Dr JP Singh.  
Clinical Director.  
SMVDNSH, Kakryal.

## Provenance and peer review

Not commissioned, externally peer-reviewed.

## References

- [1] C.M. Beauchamp, B.M. Ever, K.L. Mattox, Sabiston Textbook of Surgery: The Biological Basis of Modern Surgical Practice, vol. 2, 19th ed., Saunders, Philadelphia, 2012, p. 1114.
- [2] A. McIntosh, A. Hutchinson, A. Roberts, H. Withers, Evidence-based management of groin hernia in primary care—a systematic review, *Fam. Pract.* 17 (October (5)) (2000) 442–447.
- [3] C.H. Kang, C.Y. Tsai, Richter's femoral hernia manifested by a progressive ileus, *Formos J. Surg.* 47 (2014) 193–196.
- [4] R.A. Agha, T. Franchi, C. Sohrabi, G. Mathew, for the SCARE Group, The SCARE 2020 Guideline: Updating Consensus Surgical Case Report (SCAR) Guidelines, *Int. J. Surg.* 84 (2020) 226–230.
- [5] H. Kulacoglu, B. Kulah, S. Hatipoglu, F. Coskun, Incarcerated direct inguinal hernias: a three-year series at a large volume teaching hospital, *Hernia* 4 (3) (2000) 145–147.
- [6] W.A. Tito, W.C. Allen, Richter and littre hernia, in: J.B. Nyhus, R.E. Condon (Eds.), *Hernia*, 3rd ed., Lippincott, Philadelphia, 1989, pp. 305–310.
- [7] G. Giokas, C.P. Karakousis, Richter hernia of the stomach, *J. Surg. Oncol.* 69 (September (1)) (1998) 51–53.
- [8] M. Duari, Strangulated femoral hernia: a Richter's type containing caecum and base of appendix, *Postgrad. Med. J.* 42 (1966) 726–728.
- [9] G.J. Newerla, E.F. Connolly, Gangrenous appendicitis in femoral hernia of Richter's type, *Am. J. Surg.* 61 (1943) 154–156.
- [10] C. Frankau, Strangulated hernias: a review of 1487 cases, *Br. J. Surg.* 19 (1931) 176–191.
- [11] R.W. Gillespie, W.N. Glas, G.H. Mertz, M. Musselman, Richter's hernia: its etiology, recognition and management, *Arch. Surg.* 73 (1956) 590–594.
- [12] H.C. Folimer, Umbilical Richter's hernia, *Rocky Med. J.* 63 (1966) 61–62.
- [13] W.M. Keynes, Richter's hernia, *Surg. Gynecol. Obstet.* 103 (1956) 496–500.
- [14] J. Naylor, Combination of Spigelian and Richter's hernia: a case report, *Am. Surg.* 44 (1978) 750–752.
- [15] M.D. Cook, C.D. Yarrington, Strangulated Richter's hernia of the obturator canal: report of two cases, *Am. Pract. Dig. Treat.* 13 (1962) 115.
- [16] D.G. Millard, Richter's hernia through the inferior lumbar triangle of Petit: a radiographic demonstration, *Br. J. Radiol.* 32 (1959) 693.
- [17] F.M. Kimmelstiel, L.O. Holgersen, C. Hilfer, Retrosternal (Morgagni) hernia with small bowel obstruction secondary to a Richter's incarceration, *J. Pediatr. Surg.* 22 (1987) 998–1000.
- [18] T.W. Botsford, Richter hernia in a sacral foramen: new site for Richter hernia, *Arch. Surg.* 112 (1977) 304–305.
- [19] B. Fiirgaard, A. Agertoft, Internal Richter's hernia due to congenital peritoneal defect: case report, *Acta Chir. Scand.* 154 (1988) 537.

- [20] M.E. Baker, R. Ungerlaider, C. Cooper, N.R. Dunnick, Computed tomography of a traumatic, diaphragmatic Richter's hernia: findings mimicking an abscess, *J. Comput. Tomogr.* 12 (1) (1988) 42–44.
- [21] F. Pualwuan, Operative aspects of Richter's hernia, *Surg. Gynecol. Obstet.* 106 (1958) 358–362.
- [22] J.M. Horbach, Invagination for Richter-type strangulated hernias, *Trop. Doct.* 16 (4) (1986) 163–168.
- [23] J.B. Bourke, Small-intestinal obstruction from a Richter's hernia at the site of insertion of a laparoscope, *Br. Med. J.* 2 (November (6099)) (1977) 1393–1394.
- [24] P. Kiilholma, J. Makinen, Incarcerated Richter's hernia after laparoscopy: a case report, *Eur. J. Obstet. Gynecol. Reprod. Biol.* 28 (1988) 75–77.
- [25] M.E. Wegener, D. Cheung, C. Crans, D. Chung, Small bowel obstruction secondary to incarcerated Richter's hernia from laparoscopic hernia repair, *J. Laparoendosc. Surg.* 3 (1993) 173–176.
- [26] A.G. Radcliffe, Richter's herniation of the small bowel through the trocar site following laparoscopic surgery, *J. Laparoendosc. Surg.* 3 (1993) 520–522.
- [27] N.G. Velitchkov, G.I. Grigorov, J.E. Losanoff, K.T. Kjossev, Ingested foreign bodies of the gastrointestinal tract: retrospective analysis of 542 cases, *World J. Surg.* 20 (8) (1996) 1001–1005.
- [28] S.O. Ikenberry, T.L. Jue, M.A. Anderson, V. Appalaneni, S. Banerjee, T. Ben-Menachem, et al., Management of ingested foreign bodies and food impactions, *Gastrointest. Endosc.* 73 (6) (2011) 1085–1091.
- [29] B.K. Goh, P.K. Chow, H.M. Quah, H.S. Ong, K.W. Eu, L.L. Ooi, et al., Perforation of the gastrointestinal tract secondary to ingestion of foreign bodies, *World J. Surg.* 30 (3) (2006) 372–377.
- [30] S. Akhtar, N. McElvanna, K.R. Gardiner, S.T. Irwin, Bowel perforation caused by swallowed chicken bones—a case series, *Ulster Med. J.* 76 (1) (2007) 37–38.
- [31] C.O. Brantigan, Chicken bone hernia: an unusual presentation of a Richter's hernia, *Am. Surg.* 41 (September (9)) (1975) 584–586.
- [32] C.W. Hartin Jr., M.G. Caty, K.D. Bass, Laparoscopy for perforated Richter hernia with incarcerated foreign body, *J. Pediatr. Surg.* 46 (7) (2011) 1449–1451.
- [33] M.R. Middlebrook, F. Eftekhari, Sonographic findings in Richter's hernia, *Gastrointest. Radiol.* 17 (1992) 229–230.
- [34] F. Lassandro, F. Iasiello, N.L. Pizza, T. Valente, M.L. Stefano, R. Grassi, et al., Abdominal hernias: radiological features, *World J. Gastrointest. Endosc.* 3 (2011) 110–117.
- [35] J.C. Boughhey, J.M. Nottingham, Richter's hernia in laparoscopic era: four case reports and review of literature, *Surg. Laparosc. Endosc. Percutan. Tech.* 13 (February (1)) (2003) 55–58.

#### Open Access

This article is published Open Access at [sciencedirect.com](https://www.sciencedirect.com). It is distributed under the [IJSCR Supplemental terms and conditions](#), which permits unrestricted non commercial use, distribution, and reproduction in any medium, provided the original authors and source are credited.