

Facial Masculinization Surgery Using Polyetheretherketone Alloplasty: Statistical Shape Modeling–based Implant Designs

Hylke van der Wel, MSc*

Bram J. Merema, BSc*

Joep Kraeima, PhD*

Rutger H. Schepers, MD, DMD,
PhD*†

Johan Jansma, MD, DMD, PhD*†

Summary: The face is the initial feature used to judge gender in public spaces; it is also a source of significant gender dysphoria. Surgical techniques are available for non-cisgender male patients who desire a more masculine face by augmenting certain features to change the bony framework of the skull. Augmentation using virtually designed patient-specific polyetheretherketone implants has now become a more widely applied method in maxillofacial surgery. When designing implants for augmentation, a three-dimensional (3D) reference or template is very useful. Hence, a 3D statistical shape model was developed of a male skull shape from information from a population of 40 male patients containing the mean shape and principal components of shape variation. By overlaying the template and the patient's 3D skull model, this method identified the regions of gender dimorphism in this case to be the orbital ridge, zygomatic regions, and frontal bossing area. Based on the 3D template overlay, polyetheretherketone augmentation implants were virtually designed in close consultation with a patient to augment the aforementioned regions. The virtual statistical shape modeling template offered an objective reference, and the possibility to fully involve the patient in the treatment planning. (*Plast Reconstr Surg Glob Open* 2024; 12:e6012; doi: 10.1097/GOX.0000000000006012; Published online 30 July 2024.)

STATISTICAL SHAPE MODEL–BASED FACIAL MASCULINIZATION SURGERY USING PEEK IMPLANTS

The face is a source of significant gender dysphoria for many transgender patients because it is the initial visible feature used to judge gender in public spaces.^{1,2} Despite the reported importance of harmonizing the face with gender identity, a recent review did not find literature reporting outcomes of facial masculinization surgery.³ Regarding surgical techniques, a review of the literature to guide facial masculinization surgery reported that, besides soft-tissue surgery, bony framework altering procedures

are advised for the forehead, maxilla, nose, lips, mandible, chin, and cervical region to achieve a masculine face.⁴ The latter procedures include augmentation of the supra-orbital ridge, augmentation of the maxilla toward the zygoma, augmentation of the mandibular angle, and genioplasty or augmentation of the chin.^{4,5}

Virtually designed patient-specific implants are an established method for skull augmentations.⁶ This is a patient-specific approach with preoperative assessments and consultations with the patient before surgery. When virtually designing the implant shape, it is very useful to have some sort of planning template. Although the above-described augmentation regions are known, as are the patient's preferences through elaborate consultations, it is still difficult, from our experience, to design skeletal shape changes in these regions without a reference or planning template.

We set out to develop a new method of designing facial implants for gender-affirming augmentation of the bony framework, based on a non-cisgender male patient who attended our outpatient clinic and who had

From the *Department of Oral and Maxillofacial Surgery, University of Groningen, University Medical Centre Groningen, Groningen, the Netherlands; and †Department of Oral and Maxillofacial Surgery, Expertcenter for Orthofacial Surgery, Martini Hospital Groningen, Groningen, the Netherlands.

Received for publication September 11, 2023; accepted June 3, 2024.

Copyright © 2024 The Authors. Published by Wolters Kluwer Health, Inc. on behalf of The American Society of Plastic Surgeons. This is an open-access article distributed under the terms of the [Creative Commons Attribution-Non Commercial-No Derivatives License 4.0 \(CCBY-NC-ND\)](https://creativecommons.org/licenses/by-nc-nd/4.0/), where it is permissible to download and share the work provided it is properly cited. The work cannot be changed in any way or used commercially without permission from the journal.

DOI: 10.1097/GOX.0000000000006012

Disclosure statements are at the end of this article, following the correspondence information.

Related Digital Media are available in the full-text version of the article on www.PRSGlobalOpen.com.

a strong wish for facial gender-affirming surgery. The aim of our work was to develop a method to design a patient-specific template that we could use to augment the skull in such a way that the resulting shape was a harmonious masculine structure. Reference information for the patient-specific template was collected by obtaining a dataset of 40 male skull shapes from the radiology archive of the hospital. In addition, as this patient had a brother, and on request of the patient, we also included a CBCT scan of the skull of the patient's brother. Subsequently, we studied the shape variation of these skulls using a method called statistical shape modeling with an algorithm implemented in MATLAB.⁷ (<https://nl.mathworks.com/matlabcentral/fileexchange/41396-nonrigidicp>⁸). The created statistical shape model (SSM) could be seen as a statistical description of the mean male skull shape and its principal components of variation. In order to decide on the region and amount of augmentation for our patient, we first scaled, superimposed, and compared our patient's skull with the mean of our training population, and with the model of the brother's skull. The resulting information was valuable for consultations with the patient because we now knew how it related to the mean male skull shape as well as to the brother's skull shape. In comparison, the patient's brother had more outspoken male characteristics such as prominent frontal bossing and a more square jawline. In consultation with the patient, it was decided to average the skull shape of the collected population of 40 men with the brother's skull at a 1:1 ratio. Then, the resulting SSM was fitted to our patient's skull shape to plan a patient-specific augmentation. (See figure, Supplemental Digital Content 1, which displays how the virtually designed template is placed over the patient's skull to design implants for the areas that are going to be augmented, <http://links.lww.com/PRSGO/D377>.)

Using the template as a reference, three facial implants were designed and milled out of PEEK (KLS Martin, Tuttlingen, Germany). [See figure, Supplemental Digital Content 2, which displays the digitally designed and three dimensional (3D)-milled PEEK implants on an anatomical model of the patient, <http://links.lww.com/PRSGO/D378>.] Earlier in the design process, it was already decided to also place a chin-implant on the mandible. This chin augmentation implant was based on the brother's mandible. Using a bi-coronal approach for the frontal implant and an intraoral approach for both zygoma implants and the chin-implant, the implants were placed and fixated with titanium miniscrews. The result at the follow-up consultation 4 months after surgery was satisfactory for the patient (Fig. 1).

DISCUSSION

In comparison with a surgical augmentation approach using, for example, hydroxyapatite granules, the presented method does not involve decision-making and planning during the peroperative phase but during the preoperative phase. The first advantage is that this can reduce the operating time. Also, importantly, it can improve the

Takeaways

Question: How can the design procedure of alloplastic implants for facial masculinization surgery be improved to provide a more personalized and patient-centric approach.

Findings: Using statistical shape modeling with a dataset of male skull shapes, we designed patient-specific polyetheretherketone implants for a non-cisgender male patient, effectively tailoring the surgery to individual anatomical variations.

Meaning: Our study introduces an innovative, patient-centric approach to facial masculinization surgery by designing customized implants based on the statistical shape modeling of male skull shape data.

amount of patient involvement in the process. By showing the design virtually, or possibly printing the models and presenting them during a preoperative consultation, and sharing considerations such as proper template selection, the patient is fully involved in his own surgery. Lastly, the computer-aided-design has as an advantage over preoperative sculpting in that more objective information can be incorporated in the design and final result. In this case, as the patient had a brother, a CBCT scan of the brother was incorporated.

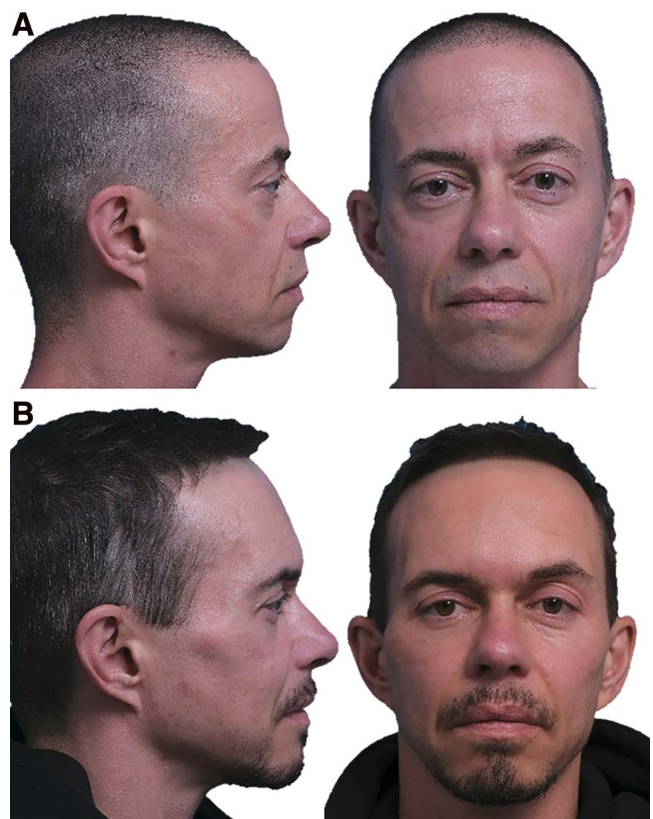


Fig. 1. Patient photographs. A, Preoperative images (lateral and frontal views). B, Four months postoperative images (lateral and frontal views).

The current preoperative workflow was time-consuming and labor-intensive because the described methodology had to be developed. Therefore, for future applications, we might work on increasing the availability of a large database of 3D skull models in statistical shape modeling. After the initial calculation of the SSM, one could work toward a design by manipulating the results during outpatient clinic consultations. In an optimized workflow, the computer-aided design shown in this study might reduce the total preoperative planning time.

The novelty in the presented case mostly lies with the statistical shape modeling–based design. Although PEEK implants for the face have been used for some time, the design of implants following the contour of the skull and augmenting the face remains a difficult task even for experienced designers. Previous authors have explored artificial intelligence–based design of facial implants, such as cranioplasties and orbital implants.^{9,10} For the design of facial onlay implants, the presented method is a novel idea.

The focus of this work was altering the bony framework, not the soft-tissue projection, which is, eventually, the most important clinical outcome. Currently, the relation between changes in the skull's bone structure and ensuing soft tissue remains a topic of study, and to our knowledge, no reliable virtual simulation methods are available other than for orthognathic surgery. From our experience in orthognathic surgery simulations, patients place a high value on preoperative simulations. For alloplastic implant surgery, careful communication with the patient about the expected soft-tissue results is necessary, especially because the final results are partly unpredictable. Three-dimensional virtual images of the precise regions that will be augmented, and consultation with the patient with 3D printed anatomical models can give the patient a better understanding. It is important the patient understands that changes to the skull will not be visible one-on-one on the soft-tissue level. A more advanced soft-tissue prediction model for alloplastic augmentation of the face could have great advantages for this type of surgery.

Hylke van der Wel, MSc
 Hanzeplein 1
 Groningen, the Netherlands
 E-mail: H.van.der.wel@umcg.nl

DISCLOSURE

The authors have no financial interest to declare in relation to the content of this article.

PATIENT CONSENT

The patient provided written consent for the use of his image.

REFERENCES

1. Louis M, Travieso R, Oles N, et al. Narrative review of facial gender surgery: approaches and techniques for the frontal sinus and upper third of the face. *Ann Transl Med.* 2021;9:606.
2. Berli JU, Capitán L, Simon D, et al. Facial gender confirmation surgery—review of the literature and recommendations for version 8 of the WPATHStandards of care. *Int J Transgend.* 2017;18:264–270.
3. Oles N, Darrach H, Landford W, et al. Gender affirming surgery: a comprehensive, systematic review of all peer-reviewed literature and methods of assessing patient-centered outcomes (part 1: breast/chest, face, and voice). *Ann Surg.* 2022;275:e52–e66.
4. Sayegh F, Ludwig DC, Ascha M, et al. Facial masculinization surgery and its role in the treatment of gender dysphoria. *J Craniofac Surg.* 2019;30:1339–1346.
5. Deschamps-Braly JC. Facial gender confirmation surgery: facial feminization surgery and facial masculinization surgery. *Clin Plast Surg.* 2018;45:323–331.
6. Honigsmann P, Sharma N, Okolo B, et al. Patient-specific surgical implants made of 3D printed PEEK: material, technology, and scope of surgical application. *Biomed Res Int.* 2018;2018:4520636.
7. Cootes TF, Taylor CJ, Cooper DH, et al. Active shape models—their training and application. *Comput Vis Image Und.* 1995;61:38–59.
8. nonrigidICP [computer program]. Mathworks; 2018.
9. Li J, Ellis D, Pepe A, et al. Back to the roots: reconstructing large and complex cranial defects using an image-based statistical shape model. *J Med Syst.* 2024;48:55.
10. Memon AR, Li J, Egger J, et al. A review on patient-specific facial and cranial implant design using artificial intelligence (AI) techniques. *Expert Rev Med Devices.* 2021;18:985–994.