



Contents lists available at ScienceDirect

Saudi Journal of Biological Sciences

journal homepage: www.sciencedirect.com



Effect of Shuangjinlian mixture on oral ulcer model in rat

Mingsan Miao^{a,*}, Mengfan Peng^a, Zetian Xing^b, Dandan Liu^a^a Department of Pharmacology, Henan University of Chinese Medicine, Zhengzhou, Henan, China^b Henan Tai Long Pharmaceutical Limited by Share Ltd, Zhengzhou, Henan, China

ARTICLE INFO

Article history:

Received 10 August 2018

Revised 12 February 2019

Accepted 12 February 2019

Available online 16 February 2019

Keywords:

Oral ulcer

Shuangjinlian mixture

Proprietary Chinese medicine

Rat model

Anti-inflammatory

ABSTRACT

Objective: To observe the effect of common clinical drug Shuangjin Lian mixture on rats with oral ulcer and discuss its mechanism.**Methods:** Sodium carboxymethyl cellulose caused leukocyte aggregation in rats, observed the anti-inflammatory effect of Shuangjin mixture. 3 mm * 3 mm size ulcer surface in the oral cavity of rats was caused by 90% phenol solution, to observe the therapeutic effect and anti-inflammatory effect of Shuangjinlian mixture on rats with oral ulcers.**Result:** The low, middle and high dose Shuangjinlian mixture can inhibits the accumulation of white blood cells caused by sodium carboxymethyl cellulose in rats significantly ($P < 0.01$). And reduce the degree of edema and hyperaemia around the ulcer tissue significantly ($P < 0.01$), improve the ulcer healing probability, and reduce the level of TNF- α , VEGF levels and increase IL-2 level in the serum of rats with oral ulcers significantly ($P < 0.01$). Pathological examination showed that the lesion of ulcer tissue in each treatment group was obviously alleviated.**Conclusion:** Shuangjinlian mixture had anti-inflammatory effect and was effective for the prevention and treatment of oral ulcer in rats.© 2019 The Authors. Production and hosting by Elsevier B.V. on behalf of King Saud University. This is an open access article under the CC BY-NC-ND license (<http://creativecommons.org/licenses/by-nc-nd/4.0/>).

1. Introduction

Oral ulcer is an oral mucosal diseases with high incidence, the main feature is periodic onset with burning pain, and ulcer tissue is susceptible to infection, leading to inflammation and tissue necrosis (Zhao and Yang, 2014). Many studies believe that there are many causes leading to oral ulcer, such as immune disorders, drug stimulation and bacterial infection, etc. (Liu, 2016). Shuangjinlian mixture is mainly composed of forsythia, baicalin, honeysuckle, bupleurum and lotus flowers, and using the sucrose as auxiliary material. It has the effect of heat-clearing and detoxifying and cold-pungent diaphoresis. It is used to treat fever, pain and cough caused by wind cold in clinical. In recent years, clinical studies have found that Shuangjinlian mixture can also be used for the treatment of oral ulcer with definite curative effect. In order to verify the curative effect of Shuangjinlian mixture on oral ulcer,

and to explore its mechanism, and provided experimental basis for the new clinical application of Shuangjinlian mixture. We use sodium carboxymethyl cellulose cause leukocyte aggregation in rats, observed the anti-inflammatory effect of Shuangjin mixture. And 90% phenol solution cause oral ulcers in rats to observe the anti-inflammatory effect and its effect on rat model of oral ulcer of Shuangjinlian mixture.

2. Experimental materials

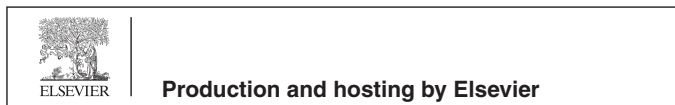2.1. Drugs and reagents

Shuangjin lian mixture was supplied by Henan Tailong pharmaceutical Co. LTD., batch number: Z20050424; Kouyanqing granule was supplied by Guangzhou baiyunshan hutchison whampoa Chinese medicine Co. LTD., batch number: Z20027059; Physiological saline provided by Henan colleen pharmaceutical Co. LTD, batch number: C217030105-2; Formaldehyde solution was supplied by Yantai chemical industry co. LTD, batch number: 20170201; Tumor necrosis factor alpha (TNF- α) ELISA test kit, Vascular endothelial growth factor (VEGF) ELISA test kit, and interleukin-2 (IL-2) ELISA test kit, provided by Suzhou Calvin biotechnology co. LTD, batch number: E20170301A. Sodium carboxymethyl cellulose, provided

* Corresponding author.

E-mail address: miaomingsan@163.com (M. Miao).

Peer review under responsibility of King Saud University.



by Tianjin hengxing chemical reagent manufacturing co. LTD, batch number: 20110728.

2.2. Animals

Wistar rats, SPF level, half male and half female, weighing 180–220 g, produced by the experimental animal center of Shandong Province. The certificate number: 37009200005249; Laboratory Certificate No. SYXK (Henan 2015-005). Breeding conditions: temperature 20–25 °C, relative humidity 40–60%, natural light, conventional breeding.

2.3. Instruments

Digital vernier calipers, Shanghai baogong tool Co. LTD; Fluorescence microscope and imaging system BX61, Japan's Olympus corporation; FA(N)/JA(N) series electronic balance, Shanghai minqiao precision instruments Co. LTD; KDC-160HR high-speed freezing centrifuge, The company of science and technology innovation Co. LTD; 680-type enzyme marker, BIO-RAD Co. LTD; HWS12 thermostatic water bath pot, Shanghai yiheng science instruments Co., Ltd; Adjustable shifter, Shanghai remberg analysis instrument Co. LTD.

3. Experimental methods

3.1. Experimental methods (Yao et al., 2014; Miao and Zhu, 2007; Yin and Yan, 2017; Li et al., 2014; Lim et al., 2016)

Sixty rats were randomly divided into five groups of 12 rats in each group. High, medium and low doses of Shuangjinlian mixture (20,10,5 ml/kg), Kouyanqing granule (2 g/kg) and 0.9% sodium chloride injection of the same volume (2 ml/100 g) were administered once a day for 3 consecutive days. After the second day of administration, the rats in each group lost about 2 cm * 2 cm of hair on their backs, and 5 ml of air was injected under the skin, forming an airbag. At 1 h after administered on the 3rd day, 1.5% sodium carboxymethyl cellulose was injected into the subcutaneous air sac, 5 ml each. After 3 h and 7.5 h of injected sodium carboxymethyl cellulose, 0.1 ml of the fluid in the air sac was extracted, and 20 times was diluted with 0.9% sodium chloride injection. The number of white blood cells was observed under the light microscope and calculated.

Seventy two rats were made up by half male and half female, weighing 180–220 g. Twelve rats were randomly selected as blank group, and the remaining 60 rats were replicated in oral ulcer models and randomly divided into model group, Kouyanqing granule group, high-, middle-, and low-dose Shuangjinlian mixture groups. Except for the blank control group, 60 SD rats were given a model of oral ulcer, place a small cotton ball at one end of the glass tube with a diameter of 3 mm. And then making the cotton ball dip into a solution of 900 g/L phenol, burning rats with 60 s on the left cheek. After 24 h, all rats had ulcers of 3 mm in diameter on the oral mucosa. The blank control group of rats were dipped in saline with a tampon tube and placed 60 s in the left cheek of the rat. The model rats were randomly divided into 5 groups, Kouyanqing granule group (2 g/kg), high, middle, and high dose Shuangjinlian mixture groups (20, 10, 5 ml/kg) were orally administrated. In addition, 3 min was applied to the oral ulceration of rats with the corresponding concentration of 0.3 ml. The model group and blank control group give the same volume of physiological saline. And 3 min was applied to the oral ulceration of rats with the physiological saline of 0.3 ml. Take the medicine one time a day for five days. Two hours after the last administration, blood was taken from the eyeball. After separation of serum, repackaging, and

–40 °C cryopreservation, determination of biochemical indicators. The hyperemia diameter of each group of rats with oral ulcer was measured with a vernier caliper, and the degree of oral ulcer was evaluated according to the evaluation criteria. The tissues of oral ulcer of each group were taken, with 4% formaldehyde fixed, paraffin embedding, section, and hematin-eHong (HE) staining, and the morphology of oral ulcer tissue in rats was observed under the microscope.

3.2. Integration standard

The maximum diameter of ulcer tissue was observed 5 d after treatment: <1 mm, judgement healing, ≥1 mm, judgement not healing. Edema and the degree of hyperemia around ulcer: I degrees: hyperemia diameter <1 mm; II degrees: hyperemia diameter 1–2 mm; III degrees: hyperemia diameter 2–3 mm; IV degrees: hyperemia diameter >3 mm.

3.3. Statistics processing method

The data were analyzed by SPSS 19.0 for windows statistical software, all data are expressed by mean ± standard ($\bar{x} \pm s$) deviation. A single factor variance analysis was used for each group, among the groups, the least significant difference (LSD) method was used to test the variance homogeneity and the Games-Howell method was used to test the heterogeneity of variance, ranked data using Ridit test.

4. Experimental results

4.1. Experimental study on anti-inflammation of Shuangjinlian mixture

As we can see from Table 1: Compared with saline group, the number of white blood cells in the air sac was significantly reduced at 3 h and 7.5 h in Kouyanqing granule group, high-, middle-, and low-dose Shuangjinlian mixture groups.

4.2. The effect of morphological, edema and hyperemia of Shuangjinlian mixture of oral ulcer model in rat

After the model was made, the mucous membrane of the ulcer is pitted and generally round. The mucous membrane edge is neat, the surface is yellow and white, covered with pseudomembrane. The surrounding hyperemia edema, appear obvious oral ulcer. No such condition occurred in the blank control group.

As we can see from Table 2: By Ridit test, compared with the blank group, the oral ulcer tissue in the model group showed significant edema and hyperemia ($P < 0.01$), indicating that the

Table 1

Effects of Shuangjin mixture on leukocyte migration in rats induced by sodium carboxymethyl cellulose.

Group	Number	3 h White blood cell count ($\times 10^3/\text{mm}^3$)	7.5 h White blood cell count ($\times 10^3/\text{mm}^3$)
Saline	12	9.34 ± 0.24	30.54 ± 1.25
Kouyanqing granule	12	7.06 ± 0.43**	20.43 ± 1.35**
High dose Shuangjinlian mixture	12	4.82 ± 0.37**	18.35 ± 0.37**
Middle dose Shuangjinlian mixture	12	5.56 ± 0.38**	23.47 ± 0.37**
Low dose Shuangjinlian mixture	12	6.18 ± 0.32**	23.28 ± 0.47**

** Compared with saline group, $P < 0.01$.

Table 2
The effect of edema and hyperemia of Shuangjinlian mixture of oral ulcer model in rat.

Group	n	I	II	III	IV	P
Blank control	12	12	0	0	0	
Model	12	0	0	6	6	##
Kouyanqing granule	12	7	5	0	0	**
High dose Shuangjinlian mixture	12	6	8	0	0	**
Middle dose Shuangjinlian mixture	12	4	7	1	0	**
Low dose Shuangjinlian mixture	12	4	6	2	0	**

Note: I degrees: hyperemia diameter <1 mm; II degrees: hyperemia diameter 1–2 mm; III degrees: hyperemia diameter 2–3 mm; IV degrees: hyperemia diameter >3 mm.

Compared with blank group, $P < 0.01$.

** Compared with model group, $P < 0.01$.

animal models were reproduced successfully. Compared with the model group, low-, middle- and high dose Shuangjinlian mixture groups and Kouyanqing granule group all could improve the hyperemia and edema of the oral ulcer tissue in rats significantly ($P < 0.01$).

4.3. The effect on the degree of healing of ulcer area

As can be seen from Table 3: Compared with the blank control group, the healing rate was 0% in model group, indicating that the model was successful. Compared with the model group, the healing rate of low, middle and high dose Shuangjinlian mixture groups and Kouyanqing granule group increased significantly.

4.4. The effect on the levels of TNF- α , VEGF and IL-2 in the serum of oral ulcer model in rat

As we can see from Table 4: Compared with the blank control group, the levels of TNF- α and VEGF in the serum were increased, and the level of IL-2 in the serum was decreased significantly in model group ($P < 0.01$), indicating that the animal models were reproduced successfully. Compared with the model group, low-, middle- and high dose Shuangjinlian mixture groups and Kouyanqing granule group could decrease the levels of TNF- α and VEGF in the serum, and increased level of IL-2 in the serum ($P < 0.01$).

4.5. The effect of pathological changes in the ulcer organization on rat model of oral ulcer

As we can see from Fig. 1: The oral mucosa epithelium was complete, and the lower part was loose connective tissue in the blank control group. In the model group, the oral mucosa was broken, the squamous epithelium was broken off, the surface was covered with necrotic tissue, and the mucosa was infiltrated by a large number of inflammatory cells. Compared with the model group, the lesion was significantly reduced, the infiltration of inflammatory cells was significantly reduced, and some of them were replaced by new granulation tissue. After the ulcer healed, the squamous epithelium was complete and thickened, and the mucosa was closer to the loose connective tissue in low, middle

Table 3
The effect on the degree of healing of ulcer area and the level of TNF- α .

Group	n	Heal number	Heal rate (%)
Blank control	12	12	100
Model	12	0	0
Kouyanqing granule	12	9	75.0
High dose Shuangjinlian mixture	12	7	58.3
Middle dose Shuangjinlian mixture	12	6	50.0
Low dose Shuangjinlian mixture	12	5	41.7

Note: <1 mm, judgement healing; ≥ 1 mm, judgement not healing.

and high dose Shuangjinlian mixture groups and Kouyanqing granule group. The results showed that the Shuangjinlian mixture could improve the pathological structure of oral ulcer induced by phenol.

As we can see from Table 5: By Ridit test, compared with the blank control group, the oral mucosa was damaged, the squamous epithelium was broken off and the surface covered necrotic tissue. The mucosa was infiltrated by a large number of inflammatory cells in the model group, with significant pathological changes ($P < 0.01$). Compared with the model group, the histopathological tissues of oral mucosa were significantly improved in low, middle and high dose Shuangjinlian mixture groups and Kouyanqing granule group ($P < 0.01$).

5. Discussion

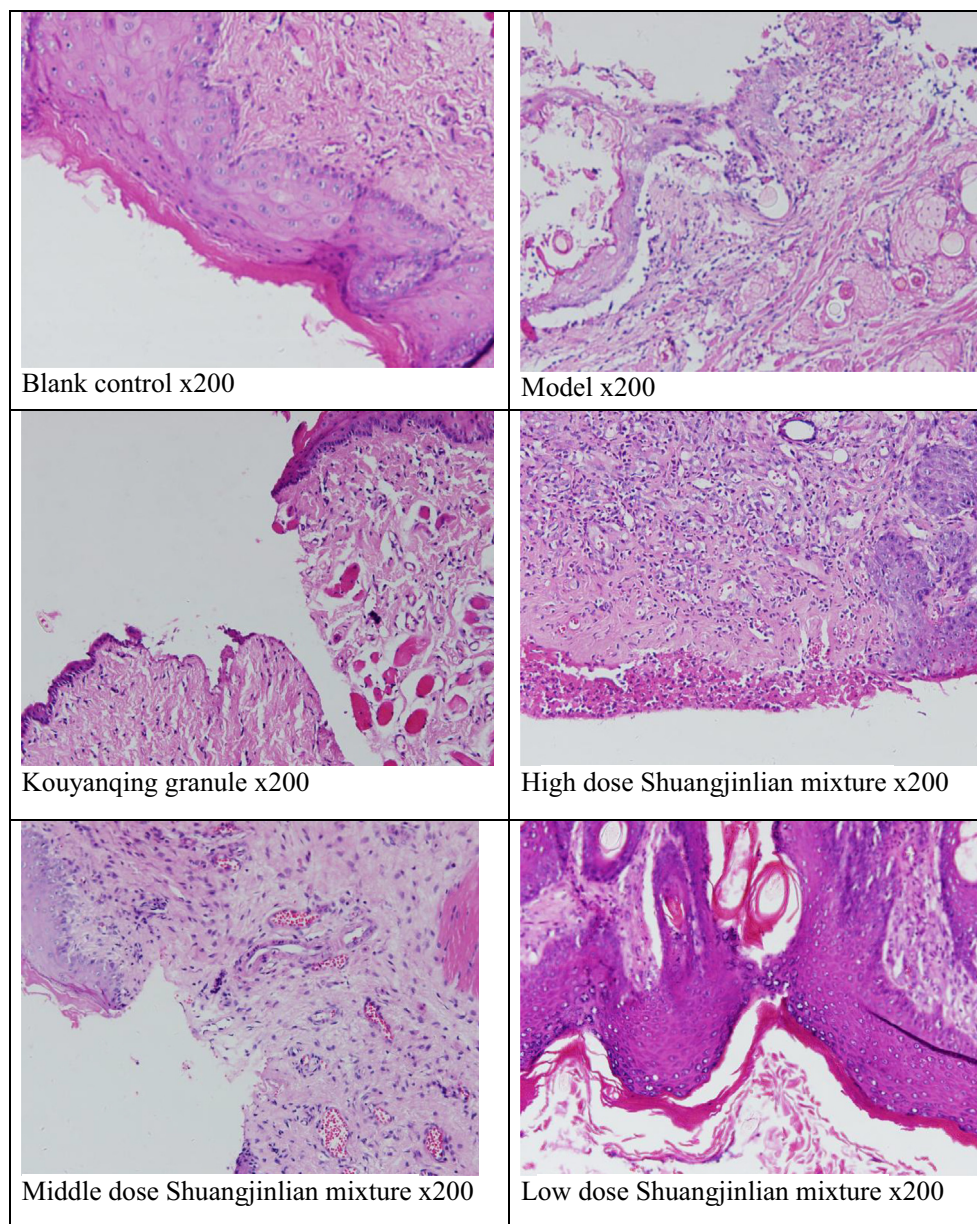
Oral ulcer is a common oral mucosal disease, it has the characteristics of periodic and very painful. Once localized ulceration, can continue to infect, cause ulcer local tissue inflammation and necrosis, make the course prolonged, increase patient suffering (Yang and Yuan, 2017). Traditional Chinese medicine believes that the maladjustment of the viscera causes the oral cavity to be damaged by real fire or false fire, which can burn the blood and corrode the muscle film, and finally occur the Oral ulcer (Ma and Qiu, 2017; Wang et al., 2016a,b; Hong et al., 2015).

VEGF is a molecule that promotes the growth of vascular endothelial cells and protein infiltration. It is involved in the physiological and pathological processes of microvessels and can promote wound healing (Shun et al., 2014). Normal people have low levels of VEGF in plasma and tissues, and only maintain normal physiological functions. TNF- α and other inflammatory factors can increase the permeability of vascular endothelial cells, promote lymphocyte activation, and induce IL-2 self-secretion. IL-2 plays a regulatory role in immune response and inflammatory response (Lei and Yang, 2016; Wang et al., 2016a,b). In this study, phenol was used to replicate the model of oral ulcer in rats, the local edema and degree of congestion of oral ulcer mucosa, pathological changes and the level of TNF- α were observed. The ulcer condition can be directly reflected by local edema, the degree of hyperemia and ulcer healing. Histopathological and cytokine examinations can reflect the healing of canker sores and the infiltration of local inflammatory cells in the oral ulcer (Shokouhsadat et al., 2016; Gao et al., 2017; Ge et al., 2017; Peng et al., 2017). This model is easy to operate and can be used as a screening model for drug and anti-inflammatory drugs that promote the healing of oral mucosa (Wang et al., 2018; Khan et al., 2018; Golezar et al., 2017).

The following conclusions can be drawn from the study of the effects of Shuangjinlian mixture on acute pharyngitis in rats. low, middle and high dose Shuangjinlian mixture. The low, middle and high dose Shuangjinlian mixture can reduce the degree of edema and hyperaemia around the ulcer tissue significantly,

Table 4The effect on the levels of TNF- α , VEGF and IL-2 in the serum of oral ulcer model in rat.

Group	n	TNF- α (pg/ml)	VEGF	IL-2(pg/ml)
Blank control	12	165.95 \pm 13.40	5.52 \pm 1.34	57.12 \pm 6.23
Model	12	303.12 \pm 12.96 ^{##}	13.07 \pm 1.24 ^{##}	28.21 \pm 1.25 ^{##}
Kouyanqing granule	12	206.95 \pm 14.10 ^{**}	7.12 \pm 0.78 ^{**}	38.15 \pm 2.16 ^{**}
High dose Shuangjinlian mixture	12	209.45 \pm 20.83 ^{**}	8.64 \pm 0.94 ^{**}	44.25 \pm 3.62 ^{**}
Middle dose Shuangjinlian mixture	12	239.95 \pm 20.16 ^{**}	8.74 \pm 1.06 ^{**}	46.21 \pm 3.45 ^{**}
Low dose Shuangjinlian mixture	12	253.87 \pm 11.70 ^{**}	8.96 \pm 1.13 ^{**}	45.92 \pm 3.18 ^{**}

^{##} Compared with blank group, $P < 0.01$.^{**} Compared with model group, $P < 0.01$.**Fig. 1.** The effect of pathological changes in the ulcer organization on rat model of oral ulcer.

improve the ulcer healing probability, and reduce the level of TNF- α in the serum of rats with oral ulcers significantly. Through the analysis of the experimental results, the mechanism of Shuangjinlian mixture in the treatment of oral ulcer is related to reducing

inflammation, enhancing the function of body defense, and promoting the healing of ulcer surface. The above studies have found the new use of Shuangjinlian mixture, which provides experimental support for clinical application.

Table 5
The effect of pathological changes in the ulcer organization of oral ulcer rat model.

Group	n	–	+	++	+++	P
Model control	12	0	0	0	12	##
Kouyanqing granule	12	5	7	0	0	**
High dose Shuangjinlian mixture	12	6	6	0	0	**
Middle dose Shuangjinlian mixture	12	3	9	0	0	**
Low dose Shuangjinlian mixture	12	1	8	3	0	**

– Oral mucosa is covered with squamous epithelium and tissue. + The oral mucosa is covered with squamous epithelium and the squamous epithelium is organized by the union. ++ The oral mucosa is covered with squamous epithelium, there is a hole in the ulcer. +++ The oral mucosa was covered with squamous epithelium and was banned by the organization. #Compared with blank control group $P < 0.05$; *Compared with model group $P < 0.05$.

Compared with blank control group $P < 0.01$.

** Compared with model group $P < 0.01$.

Acknowledgement

This research was financially supported by the Foundation item of National and international cooperation bases (2016–151) and Henan province production and research projects (142107000039).

References

- Gao, W., Wang, Y., Basavanagoud, B., Jamil, M.K., 2017. Characteristics studies of molecular structures in drugs. *Saudi Pharm. J.* 25 (4), 580–586.
- Ge, S., Liu, Z., Furuta, Y., Peng, W., 2017. Adsorption characteristics of sulfur solution by acticarbon against drinking-water toxicosis. *Saudi J. Biol. Sci.* 24 (6), 1355–1360.
- Golezar, E., Mahduni, H., Nazari, A., 2017. Different antioxidant activity measurements of the aerial parts of *Ferulago angulata*, traditional food additives in Iran. *Indian J. Pharm. Sci.* 79 (6), 900–906.
- Shokouhsadat, H., Omid, S., Reza, S.M., Gholamreza, A., Dawood, H., Zohreh, F., 2016. The most common herbs to cure the most common oral disease: stomatitis recurrent aphthous ulcer (RAU). *Iran. Red Crescent Med. J.* 18 (2).
- Hong, S., Lei, Z., Jing, G., 2015. Traditional Chinese medicine treatment of oral ulcer. *J. Nanjing Univ. Chinese Med.* 31 (3), 218–219+230.
- Khan, A., Jan, G., Khan, A., Jan, F.G., Danish, M., 2018. Evaluation of antioxidant and antimicrobial activities of *Bergenia Ciliata* Sternb (Rhizome) crude extract and fractions. *Pakistan J. Pharm. Sci.* 31 (1), 31–35.
- Lei, J.B., Yang, L., 2016. Effects of Yangyin Liyan decoction combined with Yulin powder on chronic pharyngitis with Yin deficiency and lung dryness and its effect on serum inflammatory factors. *J. Mod. Integr. Tradit. Chinese Western Med.* 25 (27), 3041–3044.
- Li, X.X., Dou, J.Y., Liu, J.G., Guan, J.Y., Wu, L.Y., Li, K., 2014. The therapeutic effect of Yangyinshengji membrane on experimental oral ulcers in rats. *J. Central South Univ. (Med. Sci.)* 20 (4), 474–476.

- Liu, J.M., 2016. The clinical diagnosis and treatment of oral ulcer. *Gen. J. Stomatol.* 3 (1), 135–136.
- Ma, P., Qiu, L.L., 2017. The application of “Bu Zhong Xie Huo Fang” in the treatment of recurrent oral ulcer. *Tradit. Chinese Med. Sci. Technol.* 24 (3), 381–382.
- Miao, M.S., Zhu, P.F., 2007. *Animal Model of Common Medicine Research*. People's Health Press, Beijing, p. 32.
- Peng, W., Ge, S., Ebadi, A.G., Hisoriev, H., Esfahani, M.J., 2017. Syngas production by catalytic co-gasification of coal-biomass blends in a circulating fluidized bed gasifier. *J. Clean. Prod.* 168, 1513–1517.
- Shun, Q., Shun, Z.R., Zhang, Q.H., Di, Wang, Yue, J.H., 2014. Effect of moxibustion on vascular endothelial cell and expression of vascular endothelial growth factor in rats with cutaneous wound. *Chinese Acupuncture Moxibustion* 34 (7), 679–684.
- Wang, J.H., Wei, Z.H., Du, Y.H., 2016a. Study on the medical name and etiology and pathogenesis of oral ulcer. *J. Liaoning Univ. Tradit. Chinese Med.* 18 (12), 181–183.
- Wang, L., Ge, S., Liu, Z., Zhou, Y., Yang, X., Yang, W., Li, D., Peng, W., 2018. Properties of antibacterial bioboard from bamboo macromolecule by hot press. *Saudi J. Biol. Sci.* 25 (3), 465–468.
- Wang, L.L., Li, H.B., Miao, M.S., 2016b. Effect of total glucosides of *Verbena officinalis* L. on rat model for chronic nonbacterial prostatitis. *China Med. Herald.* 13 (16), 4–7.
- Yang, W.T., Yuan, H.X., 2017. Treatment of recurrent oral ulcers by Chinese medicine. *J. Pract. Int. Med.* 31 (6), 89–91.
- Yao, C., Shen, M., Yuan, S.M., 2014. Establishment animal model of oral ulcer. *Shanxi Tradit. Chinese Med.* 30 (4), 46–47.
- Yin, C., Yan, Y.Z., 2017. Therapeutic effect of extract of *Artemisia Artemisia* on oral ulcer in rats. *J. Central South Univ. (Med. Ed.)* 42 (7), 824–830.
- Lim, Y.S., Kwon, S.K., Park, J.H., Cho, C.G., Park, S.W., Kim, W.K., 2016. Enhanced mucosal healing with curcumin in animal oral ulcer model. *Laryngoscope* 126 (2), E68–E73.
- Zhao, R.Z., Yang, X.L., 2014. Clinical study on the combination of Chinese and Western medicine in the treatment of oral ulcer. *J. Hebei Med.* 20 (7), 1198–1199.