




Since January 2020 Elsevier has created a COVID-19 resource centre with free information in English and Mandarin on the novel coronavirus COVID-19. The COVID-19 resource centre is hosted on Elsevier Connect, the company's public news and information website.

Elsevier hereby grants permission to make all its COVID-19-related research that is available on the COVID-19 resource centre - including this research content - immediately available in PubMed Central and other publicly funded repositories, such as the WHO COVID database with rights for unrestricted research re-use and analyses in any form or by any means with acknowledgement of the original source. These permissions are granted for free by Elsevier for as long as the COVID-19 resource centre remains active.



Available online at
ScienceDirect
 www.sciencedirect.com

Elsevier Masson France
EM|consulte
 www.em-consulte.com/en



Letter to the editor

Multisystem inflammatory syndrome with erythema multiforme-like rash in an adult after mRNA COVID-19 vaccination



ARTICLE INFO

Keywords:
 COVID-19
 Vaccine
 Erythema multiforme
 Multisystem Inflammatory Syndrome
 Kawasaki disease

Adverse reactions, especially cutaneous reactions, to coronavirus disease 2019 (COVID-19) vaccination are generally minor and self-limiting, and they should not discourage vaccination [1]. However, in a registry-based study of collected cases of cutaneous side effects of messenger RNA (mRNA) COVID-19 vaccines (Pfizer/BioNTech and Moderna), vaccine reactions, which were similar to SARS-CoV-2 infection reactions, were observed. The reactions to infection with SARS-CoV-2 may suggest a host-immune response to the virus that is also seen after vaccination [2]. Herein we describe a case of multisystem inflammatory syndrome with erythema multiforme (EM)-like rash in an adult following Pfizer/BioNTech COVID-19 vaccination.

A 62-year-old man was admitted to our dermatology department on June 11, 2021, with a 5-day history of fever and acute onset of generalized polymorphous rash. The patient had been taking verapamil since 2019 for paroxysmal supraventricular tachycardia. He had not begun any new medications, and there was no change in his current medications. He denied any history of recent illness before hospital admission and had no known COVID-19 exposure. However, he reported receiving the first dose of the Pfizer/BioNTech COVID-19 vaccine on May 25th, 2021, eleven days

prior to the onset of the skin rash. On physical examination, he was weak and febrile (39°C) for 5 days. He had generalized erythematous targetoid macules and papules with tiny pustules on the trunk and swollen lips with erosions on the lips and oral mucosa (Fig. 1a–c), together with erythema and edema of palms and soles. There was no genital involvement. He had no cervical, axillar, or inguinal lymphadenopathy and no conjunctival injection. Laboratory studies showed neutrophilia (10,000/mm³), lymphopenia (220/mm³), and normal red blood cell, peripheral eosinophil and platelet counts. There was marked inflammatory syndrome, with elevated C-reactive protein (155 mg/L, *n* < 5) and hyperferritinemia (2023 ng/mL, *n* < 400). Liver function tests were abnormal, with an alanine aminotransferase level of 142 IU/L (*n* < 50) and aspartate aminotransferase level of 59 IU/L (*n* < 50). A reverse transcription polymerase chain reaction test for SARS-CoV-2 performed on nasopharyngeal swabs was negative. The results from viral testing were negative for human immunodeficiency virus, Epstein-Barr virus, cytomegalovirus, hepatitis B virus, hepatitis C virus, and parvovirus B19. Blood and urinary cultures remained negative. Skin biopsies of the trunk lesions showed spongiotic dermatitis with neutrophilic epidermal pustules, superficial dermal edema, and mild perivascular infiltrate of lymphocytes with neutrophils and scattered eosinophils. Intraepidermal dyskeratotic cells were not observed.

The history of no current use of medication in the patient along with the clinical, laboratory and histopathological findings made the diagnoses of acute generalized exanthematous pustulosis, drug reaction with eosinophilia and systemic symptoms or EM major unlikely. With other etiologies having been excluded, a diagnosis was made of Kawasaki-like multisystem inflammatory syndrome (MIS) that was temporally associated with the first dose of the Pfizer/BioNTech COVID-19 vaccination. Electrocardiography and echocardiography showed no evidence of cardiac abnormalities or coronary artery aneurysm. However, it was decided to start treatment with 2 g/kg intravenous immunoglobulin as a single infusion

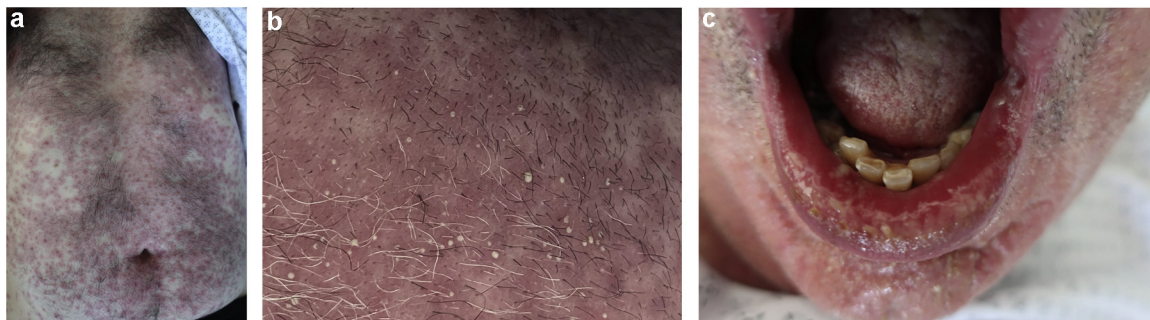


Fig. 1. Clinical features: a: erythematous targetoid macules and papules with tiny pustules on the trunk; b: close-up view showing micropustular lesions on the trunk; c: erythema, swelling and erosions of lips.

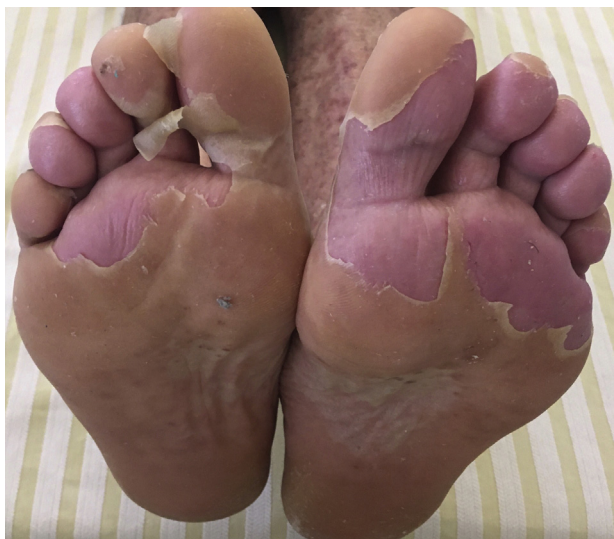

Fig. 2. Plantar desquamation after treatment with intravenous immunoglobulin.

as well as oral aspirin at a dosage of 160 mg/day. Over the following 3 days, an improvement was seen in the patient's general state with apyrexia. Striking periungual and palmoplantar desquamation was also observed (Fig. 2). The patient returned home on Day 7, and as a precaution, he did not receive a second dose of the Pfizer/BioNTech COVID-19 vaccine.

Kawasaki disease (KD) is an acute, febrile, multisystem vasculitis of unknown origin that occurs mainly in children but seldom in adults. Diagnosis is clinical and requires the presence of fever for at least 5 days, plus the presence of at least four of the five diagnostic criteria for Kawasaki disease (polymorphous exanthema, peripheral extremity changes including edema and erythema of hands/feet, mucosal changes involving the lips and oral cavity, cervical lymphadenopathy, and bilateral conjunctival injection), and lack of an alternative explanation. The incidence of specific diagnostic criteria is roughly similar in adults and in children. However, cheilitis, meningitis and thrombocytosis are observed in a larger percentage of children, while arthralgia, adenopathy and liver function abnormalities are more common in adults [3]. Atypical or incomplete forms of KD are well recognized and may be very challenging to diagnose [4]. Incomplete KD is diagnosed in cases involving fever with 2 or 3 of the clinical criteria. Diffuse erythematous maculopapular eruption is the most common form of polymorphous rash. However, KD may uncommonly present with various cutaneous presentations, such as urticarial exanthem, scarlatiniform rash, erythroderma, EM-like rash, or micropustular eruption [5–7]. In our patient, EM was also considered in the differential diagnosis because of the presence of targetoid lesions with oral mucosal involvement and recently reported cases of EM occurring after COVID-19 vaccination [8–10]. However, EM was not retained as the final diagnosis due to the presence of micropustular lesions on the trunk, the presence of a severe hyperinflammatory state, and the absence of necrotic keratinocytes, which are commonly seen in EM biopsies. Furthermore, the patient's clinical features and biochemical markers were consistent with the definition of MIS. According to the Brighton Collaboration case definition of the term MIS, this patient had a probable diagnosis of MIS that was temporally associated with the first dose of the Pfizer/BioNTech COVID-19 vaccine [11]. Although there have been reports of patients developing KD after receiving vaccines such as rotavirus vaccine, the causal effects of vaccines on KD remain elusive and have not been established [12,13]. Interestingly, there have been several recent clinical reports of development of MIS

in children (MIS-C) and adults (MIS-A) associated with COVID-19 infection [14,15]. Of note, both MIS-C and MIS-A share certain clinical and laboratory findings with KD. Because of overlapping clinical manifestations and the lack of a specific diagnostic test for either MIS or KD, distinguishing the two conditions in an individual patient can be challenging [16]. Although most experts favor the assumption that MIS is a novel entity with respect to KD, some authors lean towards the hypothesis that MIS is on the KD spectrum, with some of the differences in phenotypic severity being due to the magnitude or kinetics of the immune response [17]. Moreover, suspected cases of MIS have recently been reported following COVID-19 vaccination (MIS-V) [18,19]. To date, the exact incidence, prevalence and pathophysiology of MIS-V remain unclear. Theories of dysregulation of the immune system, cytokine storm, and/or hyper-reactivity of the immune system due to vaccination have been suggested [18]. However, subclinical COVID-19 infection around the time of vaccination leading to MIS, which is misattributed to vaccination, is also a possible etiology [20].

Although it is impossible to establish a causative effect based on an individual case report, this case should be reported. In the time of the COVID-19 pandemic with a mass COVID-19 vaccination campaign, this report could alert health professionals to the possibility that the onset of MIS may be a rare and severe side effect of mRNA COVID-19 vaccination, especially given the potential complications and therapeutic implications.

Funding source

No funding sources to declare.

Disclosure of Interest

The authors declare that they have no competing interest.

References

- [1] Polack FP, Thomas SJ, Kitchin N, Absalon J, Gurtman A, Lockhart S, et al. Safety and efficacy of the BNT162b2 mRNA covid-19 vaccine. *N Engl J Med* 2020;383:2603–15.
- [2] McMahon DE, Amerson E, Rosenbach M, Lipoff JB, Moustafa D, Tyagi A, et al. Cutaneous reactions reported after Moderna and Pfizer COVID-19 vaccination: a registry-based study of 414 cases. *J Am Acad Dermatol* 2021;85:46–55.
- [3] Seve P, Stankovic K, Smail A, Durand DV, Marchand G, Broussolle C. Adult Kawasaki disease: report of two cases and literature review. *Semin Arthritis Rheum* 2005;34:785–92.
- [4] Rife E, Gedalia A. Kawasaki disease: an update. *Curr Rheumatol Rep* 2020;22:75.
- [5] Bayers S, Shulman ST, Paller AS. Kawasaki disease: part I, diagnosis, clinical features, and pathogenesis. *J Am Acad Dermatol* 2013;69:501e1–11.
- [6] Shwe S, Kraus CN, Linden KG, Rojek NW. Erythema multiforme in a child with Kawasaki disease. *JAAD Case Rep* 2019;5:386–8.
- [7] Kimura T, Miyazawa H, Watanabe K, Moriya T. Small pustules in Kawasaki disease. A clinicopathological study of four patients. *Am J Dermatopathol* 1988;10:218–23.
- [8] Bujan Bonino C, Moreiras Arias N, Lopez-Pardo Rico M, Pita da Veiga Seijo G, Roson Lopez E, Suarez Penaranda JM, et al. Atypical erythema multiforme related to BNT162b2 (Pfizer-BioNTech) COVID-19 vaccine. *Int J Dermatol* 2021;60:e466–7. <http://dx.doi.org/10.1111/ijd.15894>.
- [9] Borg L, Mercieca L, Mintoff D, Micallef D, Pisani D, Betts A, et al. Pfizer-BioNTech SARS-CoV-2 mRNA vaccine-associated erythema multiforme. *J Eur Acad Dermatol Venereol* 2022;36:e22–4. <http://dx.doi.org/10.1111/jdv.17682>.
- [10] Saibene AM, Alliata A, Cozzi AT, Ottavi A, Spagnolini S, Pipolo C, et al. Erythema multiforme major following SARS-CoV-2 vaccine. *Clin Case Rep* 2021;9:e04947.
- [11] Vogel TP, Top KA, Karatzios C, Hilmers DC, Tapia LI, Mocerri P, et al. Multisystem inflammatory syndrome in children and adults (MIS-C/A): case definition & guidelines for data collection, analysis, and presentation of immunization safety data. *Vaccine* 2021;39:3037–49.
- [12] Mellone NG, Silva MT, Paglia MDG, Lopes LC, Barberato-Filho S, Del Fiol FS, et al. Kawasaki disease and the use of the rotavirus vaccine in children: A systematic review and meta-analysis. *Front Pharmacol* 2019;10:1075.
- [13] Murata K, Onoyama S, Yamamura K, Mizuno Y, Furuno K, Matsubara K, et al. Kawasaki disease and vaccination: prospective case-control and case-crossover studies among infants in Japan. *Vaccines* 2021;9:839.
- [14] Feldstein LR, Rose EB, Horwitz SM, Collins JP, Newhams MM, Son MBF, et al. Multisystem inflammatory syndrome in U.S. children and adolescents. *N Engl J Med* 2020;383:334–46.

- [15] Sokolovsky S, Soni P, Hoffman T, Kahn P, Scheers-Masters J. COVID-19 associated Kawasaki-like multisystem inflammatory disease in an adult. *Am J Emerg Med* 2021;39:253e1–2.
- [16] Lee MS, Liu YC, Tsai CC, Hsu JH, Wu JR. Similarities and differences between COVID-19 related multisystem inflammatory syndrome in children and Kawasaki disease. *Front Pediatr* 2021;9:640118.
- [17] Matucci-Cerinic C, Caorsi R, Consolaro A, Rosina S, Civino A, Ravelli A. Multisystem inflammatory syndrome in children: Unique disease or part of Kawasaki disease spectrum? *Front Pediatr* 2021;9:680813.
- [18] Nune A, Iyengar KP, Goddard C, Ahmed AE. Multisystem inflammatory syndrome in an adult following SARS-CoV-2 vaccine (MIS-V). *BMJ Case Rep* 2021;14:e243888.
- [19] Salzman MB, Huang C-W, O'Brien CM, Castillo RD. Multisystem inflammatory syndrome after SARS-CoV-2 infection and COVID-19 vaccination. *Emerg Infect Dis* 2021;27:1944–8.
- [20] Iyengar KP, Nune A, Ish P, Botchu R, Shashidhara MK, Jain VK. Multisystem inflammatory syndrome after SARS-CoV-2 vaccination (MIS-V), to interpret with caution. *Postgrad Med J* 2021, <http://dx.doi.org/10.1136/postgradmedj-2021-140869>.

M. Lefeuve
I. Kerneuzet
L. Darrieux
G. Safa*

*Dermatology Department, Centre Hospitalier de
Saint-Brieuc 10, rue Marcel Proust, 22000,
Saint-Brieuc, France*

* Corresponding author.

E-mail address: gilles.safa@armorsante.bzh (G. Safa)

Received 24 August 2021

Accepted 1st February 2022

Available online 11 February 2022