

Unusual Case of Cerebral Venous Thrombosis in Patient with Crohn's Disease

Inha Kim^a Kyung-Hyun Min^a Minju Yeo^a Ji Seon Kim^b
Sung Hyun Lee^b Sang Soo Lee^b Kyeong Seob Shin^c Sei Jin Youn^d
Dong Ick Shin^b

^aNeurology, Chungbuk National University Hospital, ^bDepartment of Neurology, and Departments of ^cLaboratory Medicine and ^dInternal Medicine, Chungbuk National University Hospital, Chungbuk National University College of Medicine, Cheongju, Korea

Key Words

Crohn's disease · Cerebral venous thrombosis · Disease activity

Abstract

The development of cerebral venous thrombosis (CVT) as a secondary complication of Crohn's disease (CD) seems to be rare, but it is generally accepted that the disease activity of CD contributes to the establishment of a hypercoagulable state. Here, we describe a case of CVT that developed outside the active phase of CD. A 17-year-old male visited the emergency room because of a sudden onset of right-sided weakness and right-sided hypesthesia. He had been diagnosed with CD 1 year before and was on a maintenance regimen of mesalazine and azathioprine. He did not exhibit any symptoms indicating a CD flare-up (bloody stools, abdominal pain, complications, or weight loss). A brain MRI scan revealed an acute infarction of the left frontal cortex and a cortical subarachnoid hemorrhage. Additionally, a magnetic resonance venography revealed a segmental filling defect in the superior sagittal sinus and also the non-visualizability of some bilateral cortical veins. The characteristics of the present case suggest that the risk of CVT is most likely related to CD per se rather than disease activity associated with CD.

© 2015 S. Karger AG, Basel

Introduction

Inflammatory bowel disease (IBD) is a group of inflammatory conditions of the colon and small intestine [1]. An estimated 1.3~6.4% of patients with IBD experience cerebral venous thrombosis (CVT) at some point during the course of the disease [2]. CVT tends to occur in young patients, and those who have both CVT and IBD are significantly younger than those with CVT without IBD [3]. Crohn's disease (CD) is a major type of IBD. Although many studies have shown that disease activity associated with CD contributes to a hypercoagulable state that aids in the development of CVT [4], the underlying mechanisms remain unclear. This case report describes the case of a 17-year-old male in whom CVT occurred during a nonactive phase of CD.

Case Report

A 17-year-old male visited the emergency room following the acute onset of right-side weakness and hypesthesia. He had no history of or risk factors for stroke, and the only noteworthy disease in his medical history was CD, which had been diagnosed 1 year earlier when he developed recurrent diarrhea and hematochezia. Initially, only mesalazine was prescribed for 3 months. Subsequently, azathioprine was added for about 9 months. During that time, he had no symptoms indicative of CD activity such as an increased frequency of bloody stools, abdominal pain and weight loss. The CD had been managed effectively in the emergency room.

On physical examination, the patient was normotensive, and a systemic review revealed a headache of moderate severity. A neurological examination revealed dysarthria and right-sided hemiplegia and hypesthesia. A blood test revealed chronic anemia (Hb level 9.0 g/dl; the total iron-binding capacity and red cell width were normal). His blood, sputum and stool cultures were negative; a rectal examination did not reveal melena or diarrhea; an electrocardiography demonstrated a normal sinus rhythm. A brain MRI revealed an acute infarction of the left frontal cortex and a cortical subarachnoid hemorrhage (fig. 1). CVT was suspected because of his young age and the fact that he did not have any risk factors for stroke. The infarction in a nonarterial location, the cortical hemorrhage as well as the acute neurological deficits were illustrative. We confirmed the diagnosis via brain magnetic resonance venography, which revealed a segmental filling defect in the superior sagittal sinus and non-visualizability of some cortical veins bilaterally (fig. 2). On admission, an anticoagulant (heparin) was administered intravenously to treat the CVT. A gastroenterologist was consulted in the context of the CD activity level; no evidence of escalating disease activity (such as an increased frequency of liquid stools, abdominal pain or weight loss) was noted. The CD Activity Index (CDAI), which is widely used to quantify CD symptoms and the extent of disease activity in CD patients [5], was used to estimate his CD activity. The CDAI score was 106, indicating that the CD was in remission [6]. The patient was also assessed for inherited and acquired thrombophilic disorders; the factor V Leiden mutation and prothrombin gene polymorphism were negative. Laboratory findings were negative in terms of protein C and S deficiencies, hyperhomocysteinemia, vasculitis, and markers of other autoimmune diseases (including thyroid function tests, fluorescent antinuclear antibody, rheumatoid arthritis factor, anti-thrombin III antibody and anti-phospholipid antibody) [6].

With anticoagulation, the patient regained his independence with only mild hemiparesis 3 months after admission. He was discharged on warfarin.

Discussion

Although CVT is a rare complication in CD patients, the CVT is sometimes very serious, leading to mortality [7]. The pathophysiology of thrombosis in IBD patients is not yet fully understood. However, it has been suggested that CVT is associated with several coagulation problems that develop during an IBD flare-up; these include thrombocytosis, increased levels of fibrinogen, fibrinopeptide A, factors V and VIII, the antithrombin factor III deficiency as well as a deficiency of free protein S [8]. The inflammation associated with IBD may promote the release of prothrombotic acute-phase reactants including factor VIII, the von Willebrand factor, lipoprotein A and fibrinogen while simultaneously reducing the levels of naturally occurring anticoagulant factors such as antithrombin, protein C, protein S, and tissue factor pathway inhibitors [9]. However, the details of this process remain to be described. Thus, it is difficult to predict whether CVT will develop in a CD patient. This is important because, once CVT occurs, the patient deteriorates quickly and complications of the disease may become irreversible. In addition, the sequelae of CVT typically trigger a need for lifelong rehabilitation at enormous medical costs, and it might be impossible to modify the CD disease activity. It is also important to consider any psychological problems associated with medical disorders, especially in young patients.

The most commonly used treatment strategy known to improve outcomes is anticoagulation with intravenous heparin or subcutaneous low-molecular-weight heparin until the patient is stabilized, followed by oral anticoagulation [10]. However, achieving therapeutic anticoagulation with warfarin was difficult due to a presumed drug interaction with azathioprine and active gastrointestinal bleeding [11, 12].

Jackson et al. [13] reported that thromboembolic phenomena were related to IBD activity only in IBD patients with CD, whereas Katsanos et al. [3] found active disease in 78.4% of IBD patients and quiescent disease in the other 21.6%.

The characteristics of our case suggest that the risk of CVT is most likely related to CD per se rather than to disease activity associated with CD; gastroenterologists treating CD patients should be aware of this risk. Unfortunately, no single cause of the hypercoagulable state in CD patients has yet been identified. Further research is necessary to clearly characterize the mechanism or mechanisms and to establish guidelines for clinicians who treat CD patients with CVT.

Acknowledgement

This work was supported by a research grant of Chungbuk National University in 2013.

References

- 1 Baumgart DC, Sandborn WJ: Inflammatory bowel disease: clinical aspects and established and evolving therapies. *Lancet* 2007;369:1641–1657.
- 2 Andersohn F, Waring M, Garbe E: Risk of ischemic stroke in patients with Crohn's disease: a population-based nested case-control study. *Inflamm Bowel Dis* 2010;16:1387–1392.
- 3 Katsanos AH, Katsanos KH, Kosmidou M, et al: Cerebral sinus venous thrombosis in inflammatory bowel diseases. *QJM* 2013;106:401–413.
- 4 Srirajaskanthan R, Winter M, Muller AF: Venous thrombosis in inflammatory bowel disease. *Eur J Gastroenterol Hepatol* 2005;17:697–700.
- 5 Sandborn WJ, Feagan BG, Hanauer SB, et al: A review of activity indices and efficacy endpoints for clinical trials of medical therapy in adults with Crohn's disease. *Gastroenterology* 2002;122:512–530.

Kim et al.: Unusual Case of Cerebral Venous Thrombosis in Patient with Crohn's Disease

- 6 Ye BD, Yang SK, Shin SJ, et al: Guidelines for the management of Crohn's disease (in Korean). *Korean J Gastroenterol* 2012;59:141.
- 7 Borhani Haghghi A, Edgell RC, Cruz-Flores S, et al: Mortality of cerebral venous-sinus thrombosis in a large national sample. *Stroke* 2012;43:262–264.
- 8 Saposnik G, Barinagarrementeria F, Brown RD Jr, et al: Diagnosis and management of cerebral venous thrombosis: a statement for healthcare professionals from the American Heart Association/American Stroke Association. *Stroke* 2011;42:1158–1192.
- 9 Stadnicki A: Involvement of coagulation and hemostasis in inflammatory bowel diseases. *Curr Vasc Pharmacol* 2012;10:659–669.
- 10 Lansberg MG, O'Donnell MJ, Khatri P, et al: Antithrombotic and thrombolytic therapy for ischemic stroke: antithrombotic therapy and prevention of thrombosis, 9th ed: American college of chest physicians evidence-based clinical practice guidelines. *Chest* 2012;141:e601S-36S.
- 11 Vazquez SR, Rondina MT, Pendleton RC: Azathioprine-induced warfarin resistance. *Ann Pharmacother* 2008;42:1118–1123.
- 12 Kwon Y, Ryan J, Cho K, Cho Y: A case of cerebral venous sinus thrombosis associated with Crohn's disease: dilemma in management. *Gastroenterol Rep (Oxf)* 2014, Epub ahead of print.
- 13 Jackson LM, O'Gorman PJ, O'Connell J, et al: Thrombosis in inflammatory bowel disease: clinical setting, procoagulant profile and factor V Leiden. *QJM* 1997;90:183–188.

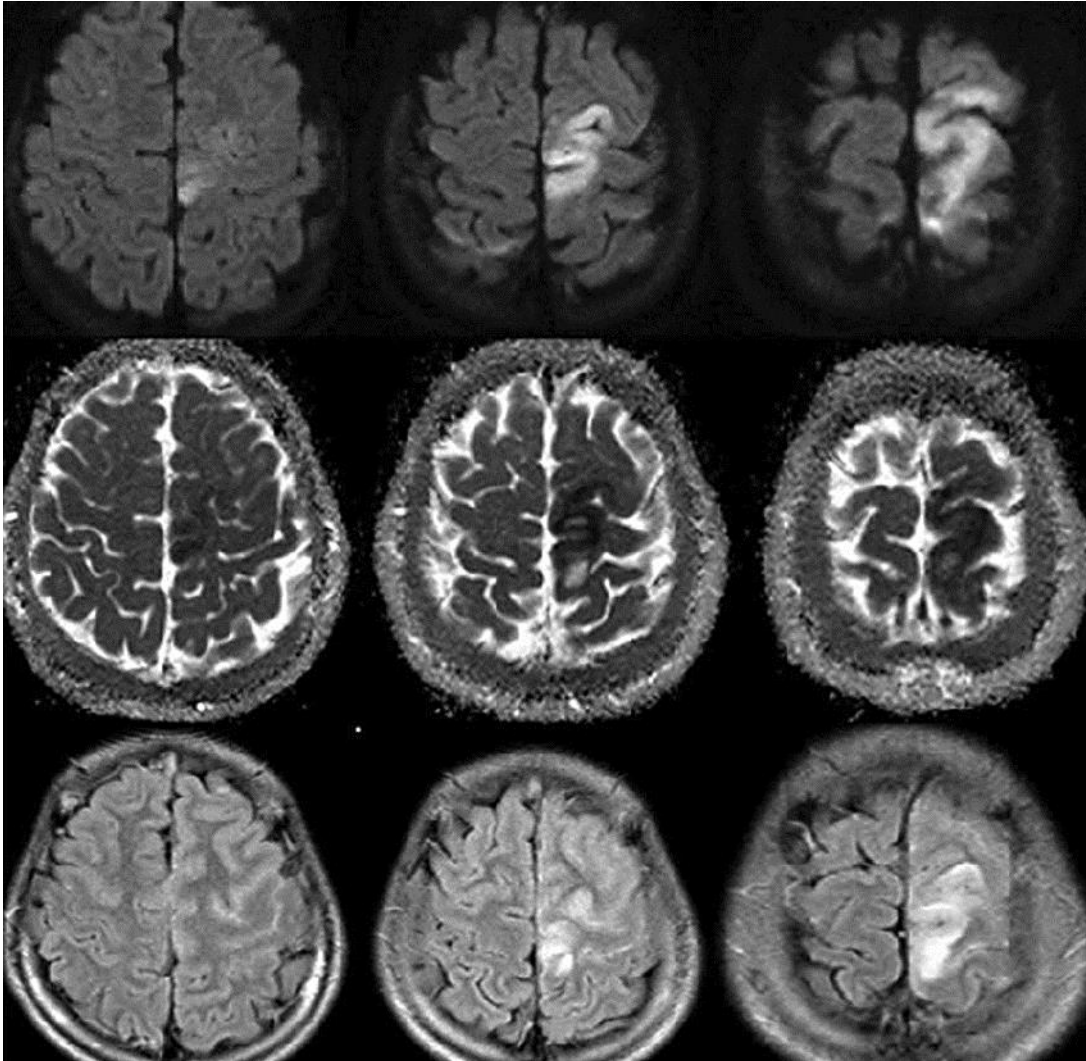


Fig. 1. Diffusion-weighted imaging and apparent diffusion coefficient images showing the restriction of diffusion in the left frontal cortex, and fluid-attenuated inversion recovery images revealing a cortical subarachnoid hemorrhage.

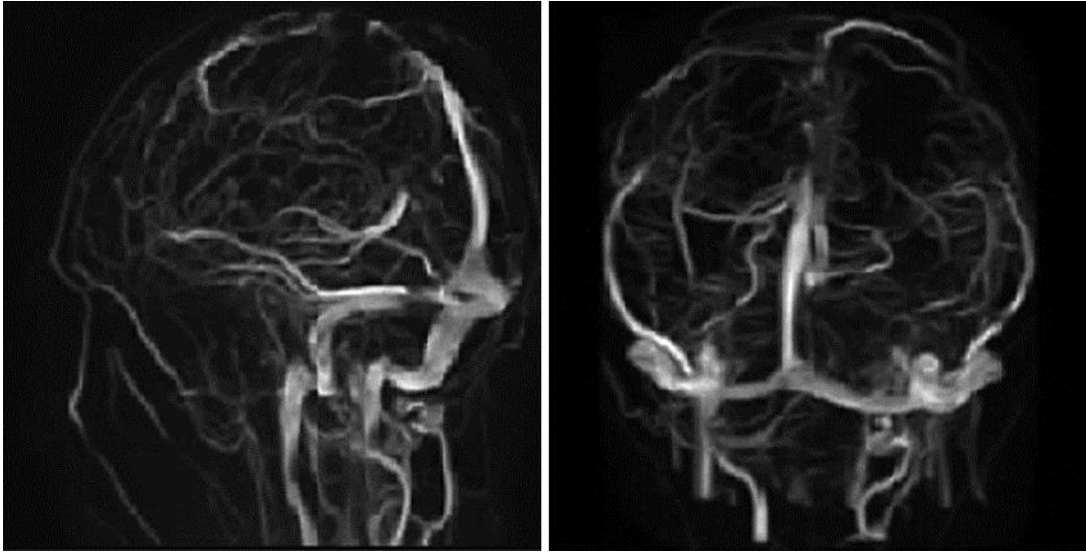


Fig. 2. The magnetic resonance venography shows a segmental filling defect in the superior sagittal sinus and the non-visualizability of some bilateral cortical veins.