



# Usefulness of MRI findings in differentiating between septic arthritis and transient synovitis of hip joint in children: A systematic review and meta-analysis

Mosab Adam <sup>\*,1</sup>, Basil Ibrahim <sup>1</sup>, Reem Khidir, Esra Elmahdi, Sara Ahmed, Almegdad Ahmed

MBBS University of Khartoum, Faculty of Medicine University of Khartoum, Sudan

## ARTICLE INFO

### Keywords:

MRI  
Septic arthritis  
Transient synovitis  
Pediatric  
Hip Joint

## ABSTRACT

**Purpose:** Septic arthritis (SA) of the hip joint is a serious infection which can lead to more irreversible complications. Differentiating Septic arthritis from Transient synovitis (which is the most common cause of painful hip in children) is difficult and very important to prevent serious complications which can occur with Septic arthritis. The aim of this study was to find out the MRI findings which can differentiate between these two conditions. **Methods:** Systematic literature search was conducted according to the PRISMA guidelines on MEDLINE(PubMed), Google Scholar, ScienceDirect, and world Health Organization Virtual Health Library, up to April 2022. Studies that compared MRI findings between Septic Arthritis and Transient Synovitis of hip joint in children were included. The pooled sensitivity and specificity estimates of these findings were calculated using MetaDTA version 2.0.

**Results:** Six studies were included in qualitative analysis and five were included in quantitative analysis. Pooled sensitivity and specificity of synovial enhancement were 94.2 % (95 % CI, 45.2–99.7 %) and 60.6 % (95% CI, 6–97.4 %) respectively. Soft tissue changes had pooled sensitivity and specificity of 75 % (95% CI, 57.5–86.9 %) and 69.9 % (95 % CI, 46.5–86.2 %) respectively. Pooled sensitivity and specificity of femoral head changes were 41.5 % (95 % CI, 15.9–72.7 %) and 87.3 % (95 % CI, 75.5–93.8 %) respectively. Bone marrow changes had pooled sensitivity and specificity of 70 % (95 % CI, 26.8–93.7 %) and 99.9 % (95 % CI, 28.7–100 %) respectively. **Conclusion:** MRI findings especially bone marrow changes were found to be useful in differentiating septic arthritis from transient synovitis among children presented with painful hip after exclusion of other causes.

## 1. Introduction

Irritable hip is a common complaint in pediatric outpatient clinics with many different underlying causes, that differ in their disease course and seriousness of their outcomes. Septic arthritis (SA) is a debilitating disease with serious outcomes that affects lower limb joints more than upper ones, with the hip joint being the most affected [1]. However, early diagnosis and adequate management of septic arthritis can control it and prevent further complications. It has been reported that starting treatment within four days of the onset of symptoms is associated with a better prognosis than a delay of five days [2]. That is why ruling out other differentials and starting treatment early on is very important. A common differential diagnosis of septic arthritis is transient Synovitis

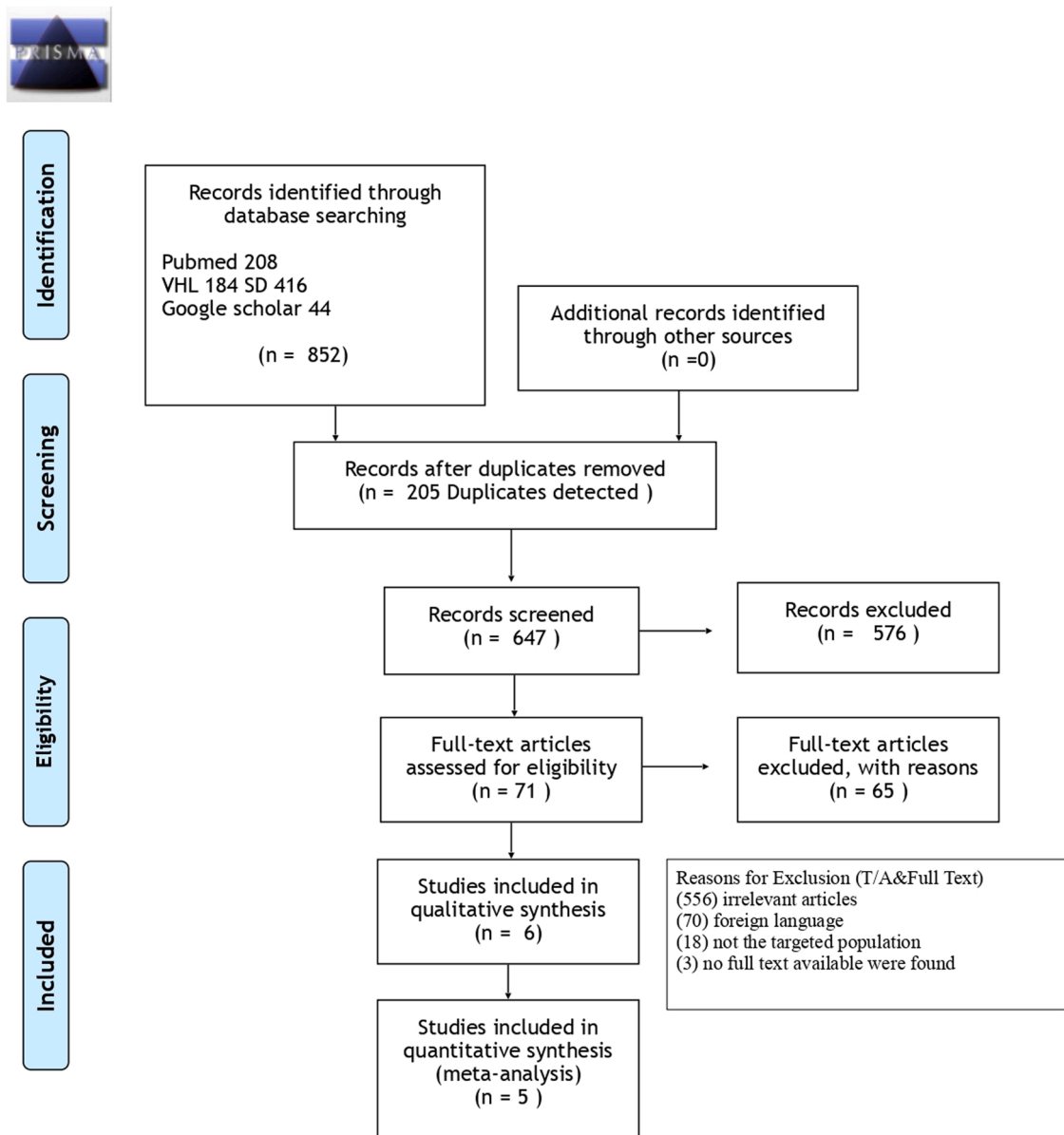
(TS), which is a benign inflammatory condition that can mimic septic arthritis presentation making it difficult to differentiate between these two conditions [3].

A clinical prediction algorithm was developed by Kocher et al., in which four clinical variables were used to help in the diagnosis of septic arthritis. However, this algorithm was found to be of a limited predictive value [4]. To lessen the burden of this diagnostic challenge, radiological methods can be with value to make a quicker and more accurate diagnosis. MRI findings can help in the diagnosis of septic arthritis, early detection of complications and aid in early management of this condition which can prevent serious complications. Several studies have focused on differentiating septic arthritis from transient synovitis of hip joint in children [2,4–7]. However, utilizing MRI findings to

\* Corresponding author.

E-mail addresses: [musaabhusien@gmail.com](mailto:musaabhusien@gmail.com) (M. Adam), [basilabubakr.34@gmail.com](mailto:basilabubakr.34@gmail.com) (B. Ibrahim), [reemjkhidir@gmail.com](mailto:reemjkhidir@gmail.com) (R. Khidir), [elmahdie753@gmail.com](mailto:elmahdie753@gmail.com) (E. Elmahdi), [sarah.mi.salih@gmail.com](mailto:sarah.mi.salih@gmail.com) (S. Ahmed), [almegdadshaeaf@gmail.com](mailto:almegdadshaeaf@gmail.com) (A. Ahmed).

<sup>1</sup> 1 and 2 in authors section contributed equally to this study.



From: Moher D, Liberati A, Tetzlaff J, Altman DG, The PRISMA Group (2009). Preferred Reporting Items for Systematic Reviews and Meta-Analyses: The PRISMA Statement. PLoS Med 6(7): e1000097. doi:10.1371/journal.pmed1000097

For more information, visit [www.prisma-statement.org](http://www.prisma-statement.org).

Fig. 1. PRISMA flow diagram demonstrating the study selection process.

differentiate between these two conditions have not previously been well established in the literature, especially in systematic review or meta-analysis field [8,9]. Nowadays MRI has become increasingly important in diagnosing musculoskeletal infections because of its high sensitivity in the detection of bone marrow alterations, soft-tissue lesions, synovial enhancement, as well as joint effusions [10, 11–12]. Previously, it has been reported that a hip affected by sepsis shows decreased perfusion in the femoral head which leads to femoral head and bone marrow changes, whereas a hip affected by transient synovitis does not [13]. On the other hand it has been shown that joint effusion would occur with most of septic arthritis and transient synovitis patients and the difference in the grade of joint effusion between the two patient

groups was not significant [13,14]. However contralateral hip joint effusion is found to be more frequent in transient synovitis than in septic arthritis [14,15].

This study focused on the usefulness of MRI findings as means of diagnostic investigation to differentiate between septic arthritis and transient synovitis of hip joint amongst children.

## 2. Methods

### 2.1. Search strategy and inclusion criteria

A systematic literature search according to Preferred Reporting Items

**Table 1**  
Descriptive summary of the studies included in the review.

Study	Year	Country	Study design	Q/A Score	Index Test	Reference Test for SA	MRI findings in SA	MRI findings in TS	No. of SA Patients	No. of TS Patients	Age range
Mahmoud et al	2017	Egypt	Analytic Cross sectional	5/8	MRI	Culture and Sensitivity	JE (100 %), SE (100 %), ST (75 %), BM edema (100 %), Soft tissue edema (56 %)	JE (100 %)	Total [16] Women [6] Men [10]	Total [9] Women [6] Men [3]	1 month to 12 years
Kang et al	2019	Korea	Analytic cross sectional	5/8	MRI	Joint fluid and Blood culture, Histological Findings for debris and Joint Capsules	Symmetrical JE (100 %), Contralateral JE (25 %), SE (82 %), ST (68 %), BM edema (18 %), Soft tissue edema (68 %), FH changes (32 %)	Symmetrical JE (100 %), Contralateral JE (49 %), SE (76 %), ST (43 %), BM edema (3 %), Soft tissue edema (30 %), FH changes (16 %)	Total [28] Women [9] Men [19]	Total [37] Women [11] Men [26]	< 16 years
Yang et al	2006	Korea	Analytic cross sectional	5/8	MRI	1\Arthrotomy (12 patients,2 of them by culture and 10 by Histological findings). 2\ Joint Aspiration in 6 patients(2 by culture and 4 by purulent synovial fluid)	Symmetrical JE (100 %), Contralateral JE (17 %), SE (83 %), ST(83 %), BM changes (56 %), Soft tissue changes (89 %), FH changes (22 %)	Symmetrical JE(100 %), Contralateral JE (63 %), SE (78 %), ST (55 %), BM changes (0.00 %), Soft tissue changes (3 %), FH changes (6 %)	Total [18] Women [8] Men [10]	Total [49] Women [13] Men [36]	SA (1 month to 15 years) TS (113 years)
Kwack et al	2007	Korea	Analytic cross sectional	5/8	MRI	Arthrocentesis (by culture In 8 patients and purulent fluid in one patient)	JE (100 %), ST (57 %), BM edema (43 %), Soft tissue edema (71 %), FH changes (86%)	JE(100 %), ST(45 %), Soft tissue edema (36 %), FH changes (18 %)	Total [7] <sup>a</sup> Women [3] Men[4]	Total [11] Women [5] Men[6]	SA (10 months48 years) TS (12 months9 years)
Lee et al	1999	Korea	Analytic Cross sectional	5/8	MRI	1/Arthrocentesis and culture. 2/Blood culture. 3/Arthrotomy	JE (100 %), Soft tissue changes (88.9 %), BM changes (88.9 %)	JE (100 %), Soft tissue changes (71.4 %)	Total [9] Women [3] Men[6]	Total [14] Women [2] Men [12]	SA (7 months –19 years) TS (4–11 years)
Kim et al	2011	Korea	Diagnostic Test Accuracy	8/10	MRI	1/Arthrocentesis and synovial fluid culture. 2/Blood culture +purulent aspiration.	FH pefusion change: early decreased enhancement on Dynamic contrast enhanced MRI in the affected hip than the normal one (85.7 %) <sup>b</sup>	FH pefusion change: early decreased enhancement on Dynamic contrast enhanced MRI in the affected hip than the normal one (27.3 %) <sup>b</sup>	Total [7] <sup>c</sup>	Total [11] <sup>c</sup>	N/A

SA=Septic arthritis. TS=Transient synovitis. JE=JOINT EFFUSION. ST=SYNOVIAL THICKENING. SE= SYNOVIAL ENHANCEMENT.BM=BONE MARROW. FH=FER-MORAL HEAD. N/A=NOT AVAILABLE. Q/A=Quality Assessment.

<sup>a</sup> Total Number was 9 however 2 patients were adult hence they have been excluded.

<sup>b</sup> The number of pediatrics patients was not clear, this percentage represents all patients included in the study.

<sup>c</sup> This number includes all patients included in the study, the number of pediatrics patients was not clear.

for Systematic Reviews and Meta-Analyses (PRISMA) statement [16] was conducted on the electronic databases MEDLINE (PubMed), Google Scholar, ScienceDirect, and WHO Virtual health library (VHL) up until the 15th of April 2022 without limitations of sex, race, geographical area, or publication date.

The keywords terms used for the search were; "transient synovitis", "septic arthritis", "acute hip", "hip", "hip joint", "magnetic resonance" and "MRI". We also examined the referenced articles in the identified articles in the search to ensure maximum coverage. The studies retrieved were transferred into Rayyan software (QCRI, Doha, Qatar) where duplicates were deleted, then initial titles/abstracts screening of all articles retrieved from this search were screened for potential inclusion [17]. The inclusion criteria were cohort and cross-sectional studies that demonstrated a comparison between septic arthritis and transient synovitis radiological findings in hip joint with the use of MRI as the tool for assessment in pediatric patients. Whereas case-controls, case reports, editorials, reviews, abstracts, and studies without sufficient data of interest were excluded. Furthermore, full-texts of studies classed as

relevant were reviewed for inclusion according to the determined eligibility criteria.

All steps were executed by two independent reviewers, any conflict between the two was further brought for group discussion in order to resolve it.

## 2.2. Quality assessment and data extraction

Quality assessment of the included studies was done using the Joanna Briggs Institute (JBI) critical appraisal checklists by two independent reviewers to assess the methodological quality of studies and the possibility of bias in study design, data analysis and conduct. The quality assessment tool consisted of eight and ten questions for cross-sectional and diagnostic test accuracy studies respectively. Using Yes, No, Unclear, and Not applicable reply to each question, values are assigned representing the extent to which they met the criteria. The mean score of two authors was taken for final decision and studies with a score yes, greater than or equal to five out of eight or eight out of ten

**Table 2**  
MRI sequences and specifications.

Study	MRI sequence	Use of Fat-suppression technique	Section thickness	Matrix size	Field view
Kang et al	1/Axial T1 weighted TSE (TR/TE 450_778/11_14ms) 2/Axial T2 weighted TSE (TR/TE,2500_4500/60_108ms) 3/Coronal T2 weighted TSE (TR/TE,2291_2978/60_80ms) 4/Contrast enhanced T1 weighted sequence in axial, coronal or sagittal planes.	-Axial T2 weighted TSE -Coronal T2 weighted TSE -Contrast enhanced T1 weighted sequence	3.5mm	192 × 192 and 512 × 512	160_400mm
Kwack et al.	1/T1 weighted TSE (TR/TE, 400_800/9_14ms) 2/T2 weighted fast spin echo (TR/TE, 3,500_4000/65_75ms). 3/Gadolinium enhanced T1 weighted spin-echo (TR/TE, 400_800/9_14ms)	-T2 weighted fast spin-echo. -Gadolinium T1 weighted spin-echo	0.2.5 mm	256 × 256	180_340mm
Lee et al	1/T1 weighted TSE (TR/TE, 400_600/10_12ms). 2/T2 weighted fast spin-echo (TR/TE, 2,500_3500/96_108ms). 3/Gadolinium enhanced T1 weighted spin-echo (TR/TE, 400_650/10_12ms)	-T2 weighted fast spin-echo. -Gadolinium T1 weighted spin-echo	3.7mm	255 × 192	180_340mm
Mahm-oud et al	N/A	N/A	N/A	N/A	N/A
Yang et al	1/T1-weighted spin-echo (TR/TE, 400750/920 ms) 2/T2 weighted fast spin echo (TR/TE, 2300_4000/81_99ms). 3/Contrast enhanced T1 weighted spin-echo (TR/TE, 400_650/9_19ms)	-T2 weighted fast spin-echo. -Contrast enhanced T1 weighted spin-ech	2.4.4 mm	224_1024 × 192_256	175_330mm

TSE=Turbo spin-echo, TR=Repetition Time, TE=Echo Time, MS=millisecond, MM=millimeter, N/A=Not Available

**Table 3**  
Study level outcomes for synovial enhancement.

Author	Year	TP	FN	FP	TN	Sensitivity	Specificity
kang et al.	2019	23	5	28	9	23/28 %	9/37 %
Mahmoud et al.	2017	16	0	0	9	16/16 %	9/9 %
Yang et al.	2006	15	3	38	11	15/18 %	11/49 %

TP, true positive; FN, false negative; FP, false positive; TN, true negative.

**Table 4**  
Study level outcomes for soft tissue changes.

Author	Year	TP	FN	FP	TN	Sensitivity	Specificity
kang et al.	2019	19	9	11	26	19/28 %	26/37 %
kwack et al.	2007	5	2	4	7	5/7 %	7/11 %
Lee et al.	1999	8	1	10	4	8/9 %	4/14 %
Mahmoud et al.	2017	9	7	0	9	9/16 %	9/9 %
Yang et al.	2006	16	2	14	35	16/18 %	35/49 %

TP, true positive; FN, false negative; FP, false positive; TN, true negative.

**Table 5**  
Study level outcomes for femoral head changes.

Author	Year	TP	FN	FP	TN	Sensitivity	Specificity
kang et al.	2019	9	19	6	31	9/28 %	31/37 %
kwack et al.	2007	6	1	2	9	6/7 %	9/11 %
Yang et al.	2006	4	14	3	46	4/18 %	46/49 %

TP, true positive; FN, false negative; FP, false positive; TN, true negative.

**Table 6**  
Study level outcomes for bone marrow.

Author	Year	TP	FN	FP	TN	Sensitivity	Specificity
kang et al.	2019	5	23	1	36	5/28 %	36/37 %
kwack et al.	2007	3	4	0	11	3/7 %	11/11 %
Lee et al.	1999	8	1	0	14	8/9 %	14/14 %
Mahmoud et al.	2017	16	0	0	9	16/16 %	9/9 %
Yang et al.	2006	10	8	0	49	10/18 %	49/49 %

TP, true positive; FN, false negative; FP, false positive; TN, true negative.

were included in the study [18].

The relevant data were extracted using a standardized form. For all included studies the collected information consisted of the (demographic characteristics) first author’s surname, publication year, country, study design, SA and TS sample size, true positive, false positive, false negative, and true negative, septic arthritis findings on MRI and transient synovitis findings on MRI.

### 2.3. Statistical analysis

The data analyses of estimates of sensitivity, specificity, were calculated based on true positive, false positive, false negative, and true negative, using random-effects model. The pooled estimates of sensitivity and specificity were graphically demonstrated by hierarchical summary receiver operating characteristic (HSROC) and Forest Plot. The meta-analysis was performed by using MetaDTA: Diagnostic Test Accuracy Meta-Analysis Version 2.0 [19].

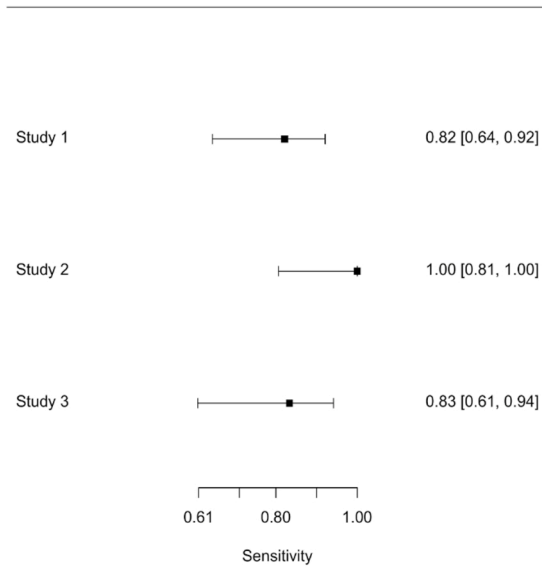
## 3. Results

### 3.1. Literature search and study characteristics

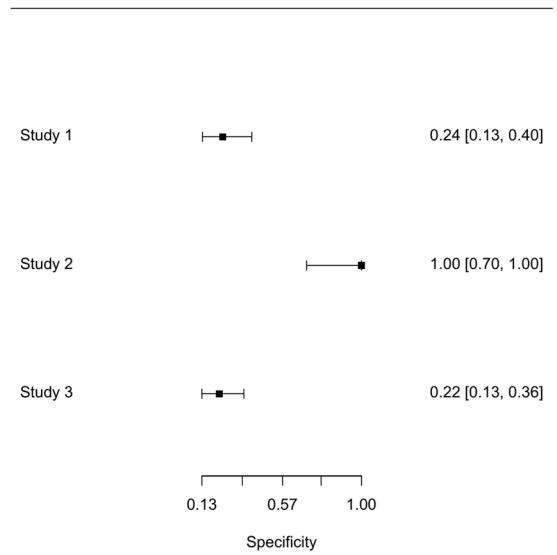
A detailed flow diagram with the study selection process and reasons for exclusion is shown in Fig. 1. Based on our search strategy, the systematic literature search identified 852 (articles/records). After the 205 duplicates were deleted, we screened 647 titles and abstracts, of them 576 records were excluded for not containing any relevant data of interest or having a different study design than the desired. The remaining 71 records were screened through full-text reading for eligibility. Finally, six studies were included in our systematic review [10,13,14,15, 20,21].

The studies included in the review were published between 1999 and 2019. The age range of participants varied across the studies, participants included in the studies were 1 months to 48 years of age. However, the analyses were carried on data of children under 18 years of age. The overall number of patients with Septic arthritis was 78 (29 females and 49 males) and the overall number of patients with Transient synovitis is 120 (36 females and 84 males). Details of the information extracted from the selected studies and the quality score of each study are summarized in Table 1.

Forest plot of sensitivity



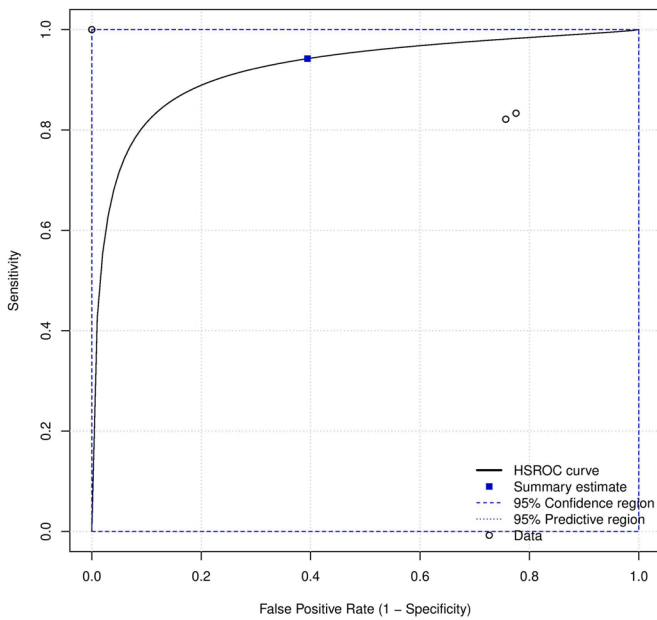
Forest plot of specificity



A

B

Random Effects Meta-Analysis



C

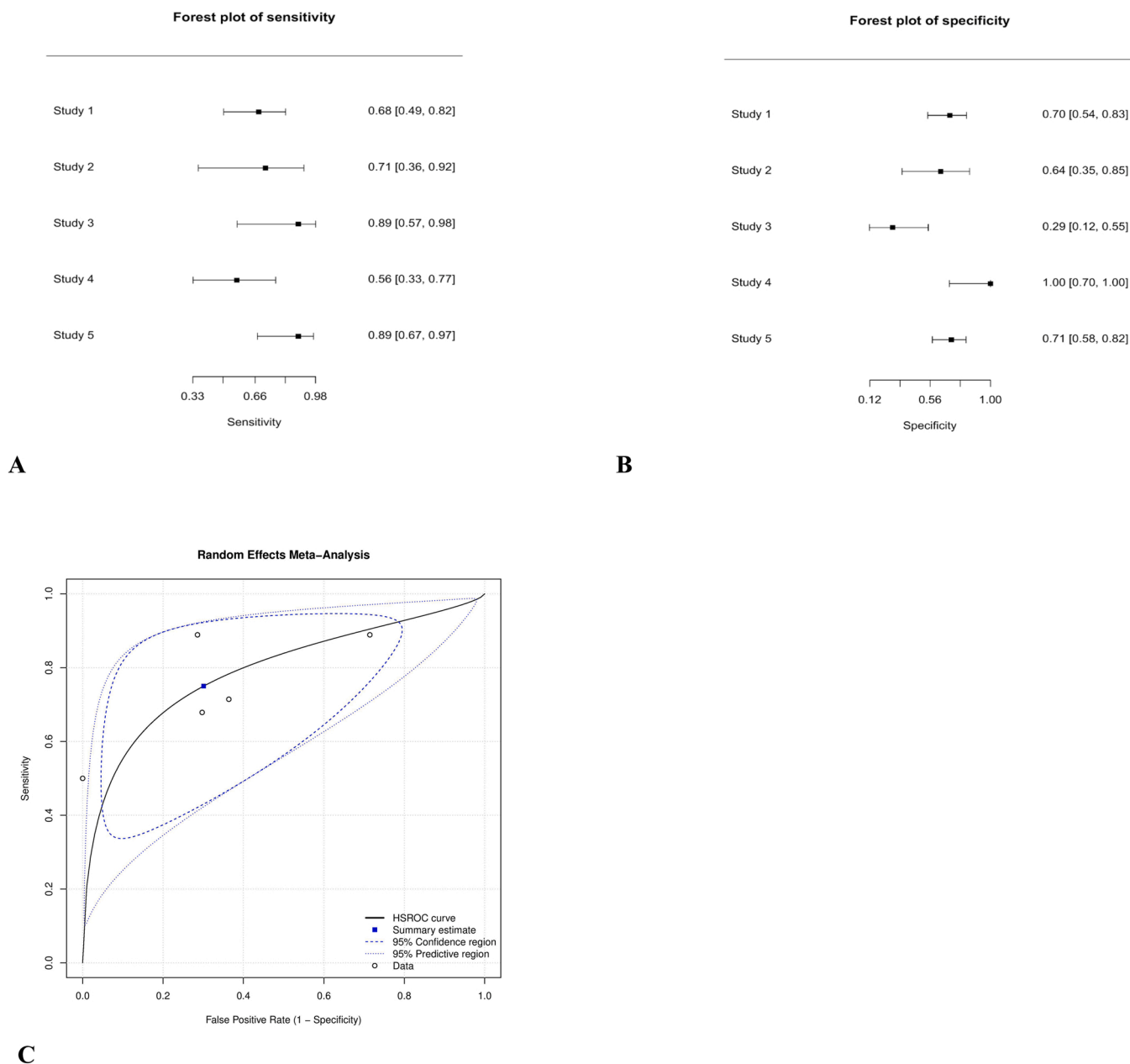
Fig. 2. Showing the forest plots of sensitivity (A) and specificity (B) of synovial enhancement on MRI in differentiating between SA and TS, each circle represents individual study point estimates, horizontal lines indicate 95 % CI. Study 1: Kang et al. [16]. Study 2: Mahmoud et al. [14]. Study 3: Yang et al. [15]. (C): HSROC curve for diagnostic accuracy of MRI finding of synovial enhancement. Summary estimate is demonstrated. HSROC: Hierarchical Summary Receiver Operating Characteristic.

3.2. Meta-analysis

The overall frequency of Septic arthritis was 39 % (78 patients with septic arthritis/198 total number of patients with septic arthritis and transient synovitis). There were sufficient data on four main MRI findings deduced from these studies where light was shed upon to assess

their likelihood for diagnosing septic arthritis rather than transient synovitis. Details about the MRI sequences used in the included studies are provided in Table 2.

The MRI finding of synovial enhancement showed a sensitivity and specificity ranges of 82–100 % and 22 %– 100 %, respectively, sensitivity and specificity ranges for Soft tissue changes were 50–89 % and



**Fig. 3.** Showing the forest plots of sensitivity (A) and specificity (B) of soft tissue changes on MRI in differentiating between SA and TS, each circle represents individual study point estimates, horizontal lines indicate 95 % CI. Study 1: Kang et al. [17]. Study 2: Kwak et al. [17]. Study 3: Lee et al. [18]. Study 4: Mahmoud et al. [14]. Study 5 Yang et al. [15]. (C): HSROC curve for diagnostic accuracy of MRI finding of soft tissue changes. Summary estimate is demonstrated.

29–100 %, respectively, that of femoral head changes finding showed sensitivity and specificity ranges of 22–86 % and 81–94 %, respectively, while sensitivity and specificity ranges for the finding of bone marrow changes were 17–100 % and 97–100 %, respectively. These findings are summarized in Tables 3–6.

Pooled sensitivity and specificity for the MRI finding of synovial enhancement were 94.2 % (95 % CI, 45.2–99.7 %) and 60.6 % (95 % CI, 6–97.4 %) respectively. Soft tissue changes had pooled sensitivity and specificity of 75 % (95 % CI, 57.5–86.9 %) and 69.9 % (95 % CI, 46.5–86.2 %) respectively. That of Femoral head changes were 41.5 % (95 % CI, 15.9–72.7 %) and 87.3 % (95 % CI, 75.5–93.8 %) respectively. While those of Bone marrow changes were 70 % (95 % CI, 26.8–93.7 %) and 99.9 % (95 % CI, 28.7–100 %) respectively. Forest plots and HSROC curves of the four main findings are shown in Figs. 2–5.

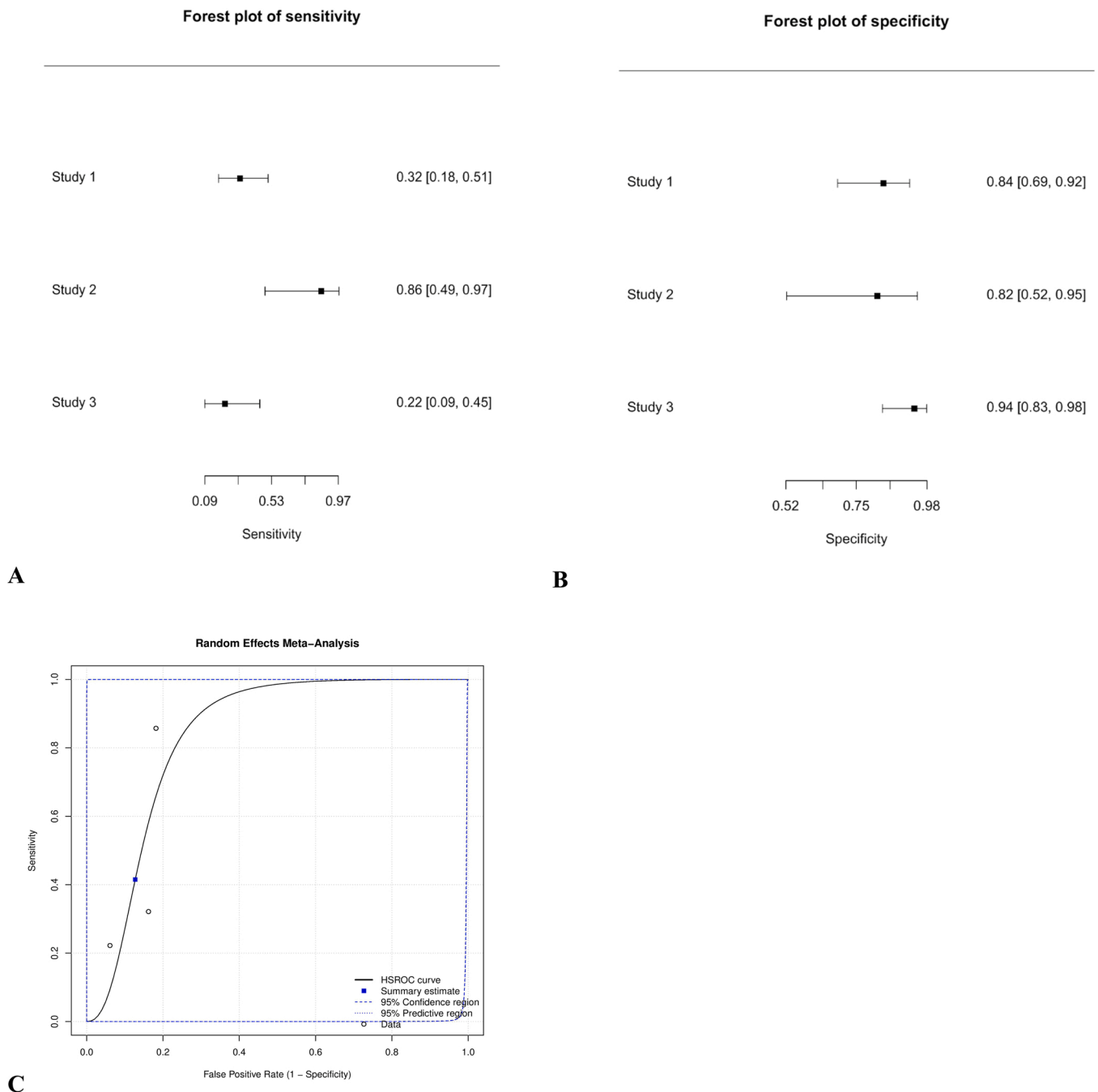
HSROC curve for the four main findings were deduced from the data given, revealing point estimates at the upper left corner on the Receiver

Operating Characteristic (ROC) curve. As a general rule, the closer the curve to the 45-degree diagonal line of roc space the less accurate it becomes. ROC curve of these named findings peak toward the ideal left upper corner of roc space from these findings we can claim that these findings are of low-moderate to high-moderate accuracy with wide interval, with the difference between confidence region and predictive region reflecting the level of heterogeneity, the wider the space between them the higher the heterogeneity.

HSROC: Hierarchical Summary Receiver Operating Characteristic.  
 HSROC: Hierarchical Summary Receiver Operating Characteristic.

**4. Discussion**

The clinical presentations of septic arthritis and transient synovitis are similar to each other, transient synovitis resolves gradually after several days with no serious complications [11]. However Septic



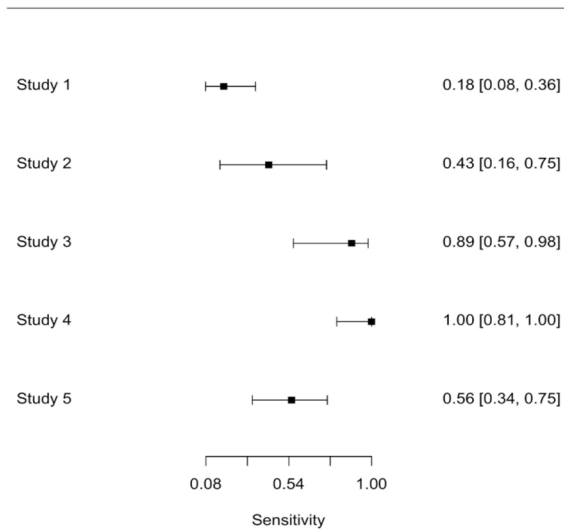
**Fig. 4.** Showing the forest plots of sensitivity (A) and specificity (B) of femoral head changes on MRI in differentiating between SA and TS, each circle represents individual study point estimates, horizontal lines indicate 95 % CI. Study 1: Kang et al. [16]. Study 2: Kwak et al. [17]. Study 3: Yang et al. [15]. (C): HSROC curve for diagnostic accuracy of MRI finding of femoral head changes. Summary estimate is demonstrated. HSROC: Hierarchical Summary Receiver Operating Characteristic.

Arthritis can lead to devastating consequences like osteonecrosis, growth arrest, and sepsis. Although transient synovitis is the most common disease in child with painful hip, based on clinical, laboratory, and radiographic findings, the differentiation between them is very important [22,23]. The aim of this study was to find out the MRI findings which can differentiate between these two conditions.

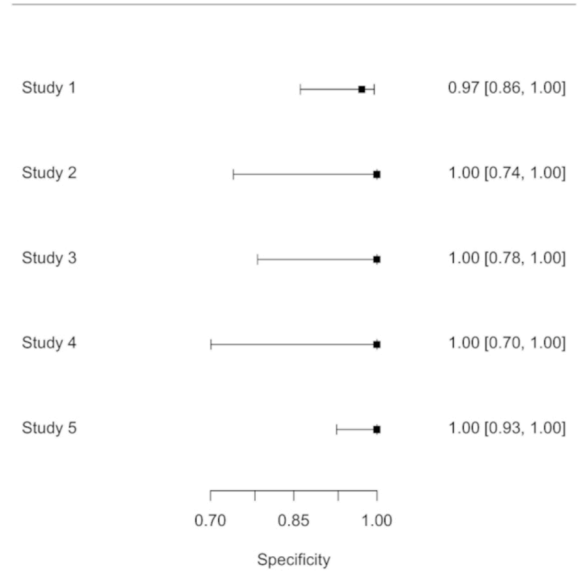
According to our findings, bone marrow changes on MRI were found to be the most specific finding for SA followed by femoral head changes. These MRI findings are more likely to occur with septic arthritis, because destructive enzymes in the infected fluid destroy the articular and epiphyseal cartilages also accumulation of pus in the joint increases the intra-articular pressure and reduce the blood flow to the epiphysis which results in osteonecrosis [10]. Also it is stated that in the literature MRI is

very effective in detecting conditions which affect bone marrow in comparison to other imaging modalities [24,25]. The most sensitive MRI finding for SA was Synovial enhancement this may be explained by the fact that the most common rout for bacterial entry to the joints is the hematogenous spread of microorganism, and this occurs through synovial vasculature which is the primary site of blood supply to any joint. So, increased vascularity of the synovium as in hip joint along with the lack of a basement membrane helps in bacterial entry and this may also explain the early presentation of this radio-logical finding [26–28]. Femoral head changes showed the lowest sensitivity for SA, these changes need time to occur and the variation between patient’s presentation time and MR imaging time among studies included in this meta-analysis may explain this result.

Forest plot of sensitivity



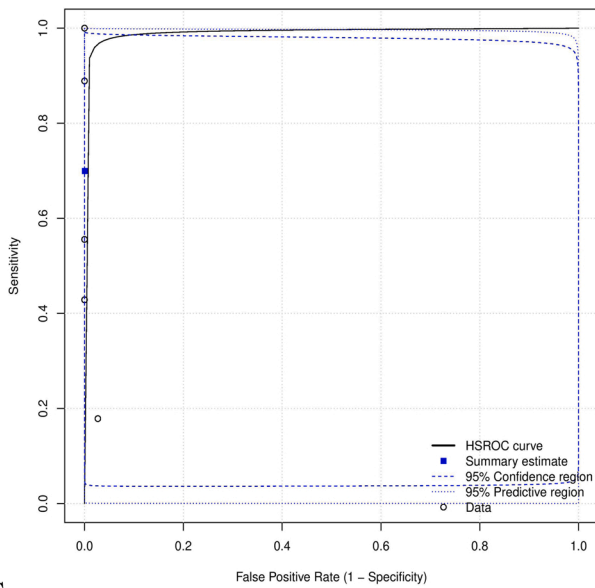
Forest plot of specificity



A

B

Random Effects Meta-Analysis



C

Fig. 5. Showing the forest plots of sensitivity (A) and specificity (B) of bone marrow changes on MRI in differentiating between SA and TS, each circle represents individual study point estimates, horizontal lines indicate 95 % CI. Study 1: Kang et al. [16]. Study 2: Kwak et al. [17]. Study 3: Lee et al. [18]. Study 4 Mahmoud et al. [14]. Study 5: Yang et al. [15]. (C): HSROC curve for diagnostic accuracy of MRI finding of bone marrow changes. Summary estimate is demonstrated.

These results are only applicable after exclusion of other conditions of the hip joint, to help in the differentiation between septic arthritis and transient synovitis in children who present with inflammatory warning signs (fever, limping, high white blood cells, high ESR or high CRP).

Kocher et al. used retrospective data to develop a clinical prediction algorithm for differentiating the two conditions [5]. After that many studies discussed the radiological findings that may help in differentiation between these two diseases.

Ultrasound-guided aspiration helps in identifying effusions suggestive of septic arthritis [29]. However, this procedure is invasive, requires local anesthesia and may introduce microorganism to the joints [30].

Ultrasound is very effective in the detection of hip joint effusion and synovial changes. However, it is not useful alone in differentiation of transient synovitis from septic arthritis and it is not effective in ruling out concomitant soft tissue infection or osteomyelitis [6,7,31,32]. Laine et al. in their study evaluated the importance of ultrasound in children with suspected hip SA and concluded that MRI could be done when there is no joint effusion or for those who fail to respond to treatment [33].

Although MRI takes more time, expensive, less accessible, and requires sedation in children, it can assess the status of the bones and soft tissues [2,34–37]. A study was done by Merlini et al. in 2015 showed that patients with Septic arthritis at presentation may get bone marrow



enhancement on MRI suggestive of secondary osteomyelitis, infants with isolated septic arthritis and reduced blood flow to the femoral head are at risk to develop osteomyelitis and should be treated accordingly. In children more than one year this enhancement pattern was not observed, and subsequent osteomyelitis was rare [38].

Previous studies also showed that more changes in soft tissues and bone marrow are associated with SA rather than transient synovitis [39, 40, 41].

Furthermore, Kang et al. have mentioned that MRI findings can change with time, and divided children in their study into short-term group (symptoms duration  $\leq 2$  days) and long-term group (symptoms duration  $> 2$  days). Children that did not have changes in the adjacent soft tissue on MRI were considered as Transient Synovitis patients. This may be justified by prolonged septic arthritis is most likely associated with signal changes in the adjacent soft tissues [15]. This makes the possibility of transient synovitis high if there are no changes on an MRI in the surrounding soft tissues.

Moreover, White et al. in their study classified soft tissue signaling changes into grade 1 (slight increase in signal compared with normal soft tissue), grade 2 (moderate increase in signal), or grade 3 (marked increase in signal). They found that in pelvic musculoskeletal infections there were marked alteration in tissue signal on MRI (grade 2 or 3) near to the symptomatic hip in comparison to transient synovitis. However, this difference did not reach statistical significance ( $p = 0.10$ ). Children with pelvic musculoskeletal infections had a mean ESR value of 45.5, while that of transient synovitis was 12.2. based on this, combining the MRI findings with the clinical presentation of the child and laboratory results may help in diagnosing serious diseases which need early intervention [39].

## 5. Conclusion

Although there were few studies included in this review, bone marrow and femoral head changes were found to be more specific to septic arthritis patients than transient synovitis. However, more studies are needed in this area to be established.

## 6. Limitations

The findings of this review are limited by Lack of enough studies, especially diagnostic test accuracy studies which assess the usefulness of MRI in differentiating between Septic arthritis and transient synovitis as well as the number of children included in the studies was small.

## CRediT authorship contribution statement

**Mosab Adam:** Conceptualization; Data curation; Formal analysis; acquisition; Methodology; Supervision ;Roles/Writing - original draft; Writing - review & editing. **Basil Ibrahim:** Conceptualization; Data curation; Formal analysis; acquisition; Methodology; Supervision; Roles/Writing - original draft; Writing - review & editing.

## Ethics approval and consent to participate

Not applicable.

## Funding

This research did not receive any specific grant from funding agencies in the public, commercial, or not-for-profit sectors.

## Consent for publication

Not applicable.

## Note

-Submission of this study will be solely to European journal of Radiology Open.

## Declaration of Competing Interest

The authors declare that they have no known competing financial interests or personal relationships that could have appeared to influence the work reported in this paper.

## Data availability

The datasets used during the current study are available from the corresponding author on reasonable request.

## Acknowledgments

The authors would like to thank Sagad Omer and Alfatih Hasabo for his support regarding technical issues.

## References

- [1] M. Tai, K. Goh, K. Kadir, M. Zakaria, J. Yap, K. Tan, Predictors of functional outcome in patients with stroke thrombolysis in a tertiary hospital in Malaysia, *Singap. Med. J.* 60 (5) (2019) 236–240, <https://doi.org/10.11622/smedj.2018150>.
- [2] M. Zamzam, The role of ultrasound in differentiating septic arthritis from transient synovitis of the hip in children, *J. Pediatr. Orthop. B* 15 (6) (2006), 418422, <https://doi.org/10.1097/01.bpb.0000228388.32184.7f>.
- [3] D. Sucato, R. Schwend, R. Gillespie, Septic arthritis of the hip in children, *J. Am. Acad. Orthop. Surg.* 5 (5) (1997) 249–260, <https://doi.org/10.5435/00124635-199709000-00003>.
- [4] S. Luhmann, A. Jones, M. Schootman, J. Gordon, P. Schoenecker, J. Luhmann, Differentiation between septic arthritis and transient synovitis of the hip in children with clinical prediction algorithms, *J. Bone Jt. Surg.* 86 (5) (2004) 956–962, <https://doi.org/10.2106/00004623-200405000-00011>.
- [5] M. Kocher, D. ZURAKOWSKI, J. KASSER, Differentiating between septic arthritis and transient synovitis of the hip in children, *J. Bone Jt. Surg.* 81 (12) (1999) 1662–1670.
- [6] M. Miralles, G. Gonzalez, J.R. Pulpeiro, et al., Sonography of the painful hip in children: 500 consecutive cases, *AJR* 152 (1989) 579–582.
- [7] G.J. Marchal, M.T. Van Holsbeeck, M. Raes, et al., Transient synovitis of the hip in children: role of US, *Radiology* 162 (1897) 825–828.
- [8] J.M. Mazur, G. Ross, J. Cummings, et al., Usefulness of magnetic resonance imaging for the diagnosis of acute musculoskeletal infections in children, *Pediatr. Orthop.* 15 (1995) 144–147.
- [9] J.S. Lee, J.B. Na, J.J. Yoo, et al., MR findings of transient synovitis of the hip, *J. Korean Radio. Soc.* 42 (2000) 353–358.
- [10] S. Lee, K. Suh, Y. Kim, H. Ryeom, Y. Kim, J. Lee, et al., Septic arthritis versus transient synovitis at MR imaging: preliminary assessment with signal intensity alterations in bone marrow, *Radiology* 211 (2) (1999) 459–465, <https://doi.org/10.1148/radiology.211.2.r99ma47459>.
- [11] K.L. Hopkins, K.C. Li, G. Bergman, Gadolinium DTPA-enhanced magnetic resonance imaging of musculoskeletal infectious processes, *Skelet. Radiol.* 24 (1995) 325–330.
- [12] G. Ranner, F. Ebner, R. Fotter, W. Linhart, E. Justich, Magnetic resonance imaging in children with acute hip pain, *Pediatr. Radiol.* 20 (1989) 67–71.
- [13] K. Kwack, J. Cho, J. Lee, J. Cho, K. Oh, S. Kim, Septic arthritis versus transient synovitis of the hip: gadolinium-enhanced MRI finding of decreased perfusion at the femoral epiphysis, *Am. J. Roentgenol.* 189 (2) (2007) 437–445, <https://doi.org/10.2214/AJR.07.2080>.
- [14] W. Yang, S. Im, G. Lim, H. Chun, N. Jung, M. Sung, et al., MR imaging of transient synovitis: differentiation from septic arthritis, *Pediatr. Radiol.* 36 (11) (2006) 1154–1158, <https://doi.org/10.1007/s00247-006-0289-9>.
- [15] M. Kang, J. Jeon, S. Park, Differential MRI findings of transient synovitis of the hip in children when septic arthritis is suspected according to symptom duration, *J. Pediatr. Orthop. B* 29 (3) (2020) 297–303, <https://doi.org/10.1097/BPB.0000000000000671>.
- [16] A. Liberati, D. Altman, J. Tetzlaff, C. Mulrow, P. Gotzsche, J. Ioannidis, M. Clarke, P. Devereaux, J. Kleijnen, D. Moher, The PRISMA statement for reporting systematic reviews and meta-analyses of studies that evaluate healthcare interventions: explanation and elaboration, *BMJ* 339 (1) (2009), <https://doi.org/10.1136/bmj.b2700> (b2700-b2700).
- [17] M. Ouzzani, H. Hammady, Z. Fedorowicz, A. Elmagarmid, Rayyana web and mobile app for systematic reviews, *Syst. Rev.* 5 (1) (2016).
- [18] Jbi.global, 2021. critical-appraisal-tools - Critical Appraisal Tools | Joanna Briggs Institute. [online] Available at: <<https://jbi.global/critical-appraisal-tools/>> [Accessed 7 March 2021].

- [19] MetaDTA: Diagnostic Test Accuracy Meta-analysis [Internet]. Crsu.shinyapps.io. 2021 [cited 30 March 2021]. Available from: ([https://crsu.shinyapps.io/dta\\_ma/](https://crsu.shinyapps.io/dta_ma/)).
- [20] M. Abd-Elhamid, M. Solyman, A. Shiha, K. Zaky, Usefulness of MRI in differentiating between septic arthritis and transient synovitis in the hip joint, *Sohag Med. J.* 21 (3) (2017) 405–411, <https://doi.org/10.21608/smj.2017.41255>.
- [21] E. Kim, K. Kwack, J. Cho, D. Lee, S. Yoon, Usefulness of dynamic contrast-enhanced MRI in differentiating between septic arthritis and transient synovitis in the hip joint, *Am. J. Roentgenol.* 198 (2) (2012) 428–433, <https://doi.org/10.2214/AJR.11.6937>.
- [22] A. Spock, Transient synovitis of the hip joint in children, *Pediatrics* 24 (1959), 10421049.
- [23] Illingworth CM. Recurrences of transient synovitis of the hip. *Archives of Disease in Childhood.* 1983 Aug;58(8):620-623. DOI: 10.1136/adc.58.8.620. PMID: 6614977; PMCID: PMC1628337.
- [24] S.G. Moore, G.S. Bisset 3rd, M.J. Siegel, et al., Pediatric musculoskeletal MR imaging, *Radiology* 179 (345–360) (1991) 25.
- [25] D.M. Deely, M.E. Schweitzer, MR imaging of bone marrow disorders, *Radio. Clin. North Am.* 35 (1997) 193–212.
- [26] L.S. Wilkinson, J.G. Worrall, H.D. Sinclair, J.C.W. Edwards, Immunohistological reassessment of accessory cell populations in normal and diseased human synovium, *Br. J. Rheumatol.* 29 (4) (1990) 259–263.
- [27] O. FitzGerald, B. Bresnihan, Synovial membrane cellularity and vascularity, *Ann. Rheum. Dis.* 54 (6) (1995) 511–515.
- [28] I Swarup, S LaValva, R Shah, WN Sankar, Septic Arthritis of the Hip in Children: A Critical Analysis Review, *JBJS Rev* 8 (2) (2020), e0103, <https://doi.org/10.2106/JBJS.RVW.19.00103>.
- [29] U. Kesteris, H. Wingstrand, L. Forsberg, N. Egund, The effect of arthrocentesis in transient synovitis of the hip in the child: a longitudinal sonographic study, *J. Pediatr. Orthop.* (1996) 24–29.
- [30] Arthrocentesis: hip - WikEM [Internet]. Wikem.org. Available from: (<https://wikem.org/wiki/Arthrocentesis:hip>).
- [31] F. McGoldrick, T. Bourke, N. Blake, et al., Accuracy of sonography in transient synovitis, *J. Pediatr. Orthop.* 10 (1990) 501–503, 21.
- [32] J.K. Zawin, F.A. Hoffer, F.F. Rand, et al., Joint effusion in children with an irritable hip: US diagnosis and aspiration, *Radiology* 187 (1993) 459–463.
- [33] J.C. Laine, J.R. Denning, A.I. Riccio, C. Jo, J.M. Joglar, R.L. Wimberly, The use of ultrasound in the management of septic arthritis of the hip, *J. Pediatr. Orthop. B* 24 (2015) 95–98.
- [34] S. Kang, T. Sanghera, J. Mangwani, J. Paterson, M. Ramachandran, The management of septic arthritis in children, *J. Bone Jt. Surg. Br. Vol.* (9) (2009) 1127–1133, <https://doi.org/10.1302/0301-620X.91B9.22530>.
- [35] B. Karmazyn, R. Loder, M. Kleiman, K. Buckwalter, A. Siddiqui, J. Ying, K. Applegate, The role of pelvic magnetic resonance in evaluating nonhip sources of infection in children with acute nontraumatic hip pain, *J. Pediatr. Orthop.* 27 (2) (2007), 158164, <https://doi.org/10.1097/01.bpb.0000248563.18595.6b>.
- [36] O. Gafur, L. Copley, S. Hollmig, R. Browne, L. Thornton, S. Crawford, The impact of the current epidemiology of pediatric musculoskeletal infection on evaluation and treatment guidelines, *J. Pediatr. Orthop.* 28 (7) (2008) 777–785, <https://doi.org/10.1097/BPO.0b013e318186eb4b>.
- [37] J. Mazur, G. Ross, J. Cummings, A. Hahn, W. McCluskey, Usefulness of magnetic resonance imaging for the diagnosis of acute musculoskeletal infections in children, *J. Pediatr. Orthop.* 15 (2) (1995) 144–147.
- [38] L. Merlini, M. Anoooshravani, D. Ceroni, Concomitant septic arthritis and osteomyelitis of the hip in young children; a new pathophysiological hypothesis suggested by MRI enhancement pattern, *BMC Med. Imaging* 15 (1) (2015), <https://doi.org/10.1186/s12880-015-0057-0>.
- [39] P. White, Magnetic resonance imaging as the primary imaging modality in children presenting with acute non-traumatic hip pain, *Emerg. Med. J.* 18 (1) (2001) 2529, <https://doi.org/10.1136/emj.18.1.25>.
- [40] J.C. Nguyen, P.H. Yi, K.M. Woo, H.G. Rosas, Detection of pediatric musculoskeletal pathology using the fluid-sensitive sequence, *Pediatr. Radiol.* (2018), <https://doi.org/10.1007/s00247-018-4256-z>.
- [41] E. Kirkhus, B. Flato, O. Riise, T. Reisetser, H.J. Smith, Differences in MRI findings between subgroups of recent-onset childhood arthritis, *Pediatr. Radiol.* 41 (2011) 432–440.