

Original Article

Sarcocystis cruzi in Egyptian slaughtered cattle (*Bos taurus*): epidemiology, morphology and molecular description of the findings

Elshahawy, I. S.^{1*}; Mohammed, E.¹; Gomaa, A.² and Fawaz, M.¹

¹Department of Parasitology, Faculty of Veterinary Medicine, South Valley University, Qena, Egypt; ²BSc in Veterinary Medicine, Department of Parasitology, Faculty of Veterinary Medicine, South Valley University, Qena, Egypt

*Correspondence: I. S. Elshahawy, Department of Parasitology, Faculty of Veterinary Medicine, South Valley University, Qena, Egypt. E-mail: ismail-saad@vet.svu.edu.eg

 10.22099/IJVR.2022.43498.6363

(Received 11 Apr 2022; revised version 22 Sept 2022; accepted 24 Sept 2022)

This is an open access article under the CC BY-NC-ND license (<http://creativecommons.org/licenses/by-nc-nd/4.0/>)

Abstract

Background: *Sarcocystis* spp. are one of the most common foodborne tissue cyst-forming coccidia with a public health and veterinary concern. **Aims:** The existing study aimed to rectify the epidemiological profile of *Sarcocystis* spp. infection in the cattle carcasses as well as to explore the structure and phylogenetic features of *Sarcocystis* spp. isolates. **Methods:** A total of 292 cattle carcasses were checked for the existence of sarcocysts using light microscopy (LM) via muscle squash (MS) and peptic digestion (PD) analysis from January 2020 to December 2020. Individual sarcocysts from different cattle tissues were selected for morphologic characterization and DNA extraction. Each sarcocyst's *18S rDNA* gene was amplified, sequenced, and analyzed. **Results:** Overall, 92.5% (270/292) of cattle tissue samples contained microscopic thin walled sarcocysts and were exclusively found in esophagus by light microscopy. A statistically insignificant relationship exists between the prevalence of infection and age groups, gender of cattle, and the seasonal dynamics ($P>0.05$). Sarcocysts ultrastructural features were completely discussed. Sequencing of *18S rDNA Sarcocystis* gene confirmed *S. cruzi* (identity 99-100%), which was the first molecular identification of the current isolate in the study region. **Conclusion:** The current survey initially provides a brief account of knowledge about the epidemiology of *Sarcocystis* spp. infecting cattle and it is considered a starting point for the development of health awareness and efficient preventive schemes for this zoonotic protozoan parasite.

Key words: *Bos taurus*, Molecular characterization, *Sarcocystis cruzi*, Sarcocysts morphology, 18S rRNA

Introduction

Livestock, aside from its economic value, have come to be an energetic origin of pathogens dissemination in the environment with their products (faeces, hair, hide, crusts, and meat) and to be an energetic origin of pathogens dissemination to other animals including man. Likewise, they are recognized to be responsible for the persistence of infections in nature by harboring and permitting the pathogenic causal agents to survive.

Sarcocystis species, which are commonly herbivores, are common intracellular coccidian and food-borne parasites belonging to the phylum Apicomplexa with an obligatory two-host life cycle and having the sexual development in the intestinal tract of the definitive host and asexual growth in various tissues of the intermediate host. Cattle represent the most common and frequent intermediate host of numerous *Sarcocystis* species, including *S. cruzi* with canids as the definitive host, *S. bovifelis*, *S. bovini*, and *S. hirsuta* with felids as the definitive host, and *S. hominis* and *S. heydorni* with

humans as definitive host based on the genetic description of *18S rRNA*, *cox1*, and *ITS1* gene sequences (Gjerde, 2016). Likewise, cattle have recently been discovered to act as an intermediate host for *S. rommeli*, an organism with an unrecognized life cycle (Chen *et al.*, 2011; Moré *et al.*, 2014).

Eosinophilic myositis (Vangeel *et al.*, 2012) and fatal eosinophilic myocarditis (Aráoz *et al.*, 2019) are common diseases in bovines besides the economic losses in terms of reduced milk production, abortion, or neonatal mortality (Aráoz *et al.*, 2019). Likewise, human sarcocystosis, can occur under two forms due to consumption of fresh and/or poorly cooked meat. The well-recognized form is intestinal sarcocystosis because of zoonotic species, ensuing symptomatic gastric disturbance (Dubey, 2015). The second scenario is the muscular involvement, occurring when humans become incidental hosts due to ingestion of contaminated foodstuff by livestock *Sarcocystis* spp. fecal sporocysts stage (Rosenthal, 2013; Murata *et al.*, 2018). This finding may be related with myositis, fleeting edema,

and fever (Fayer, 2004). Recently, the significance of this issue has increased due to *Sarcocystis* secretory toxins that contaminate food (Ota *et al.*, 2019).

The total cyst dimension, existence or lack of septa, cyst-wall thickness, and fine structural morphology of the wall are regarded as key criterion for the identification of *Sarcocystis* species (Abdel-Ghaffar *et al.*, 2009; Dubey *et al.*, 2015; El-Morsey *et al.*, 2019; Lucas *et al.*, 2019). However, various *Sarcocystis* species with similar morphological features as seen by light and transmission electron microscopy are most likely present in the same host. Consequently, molecular indicator practice has become an effective tool for confirming the morphological species identification and determining whether morphologically similar sarcocysts in intermediate hosts belong to the same or different species (Motamedi *et al.*, 2011; Gjerde, 2013; Gjerde, 2016; El-Morsey *et al.*, 2019; Sudan *et al.*, 2021).

Previous indigenous investigations revealed a wide range of infection rates in various Egyptian provinces that range from 7.5% in the New Valley city (Ahmed *et al.*, 2016), to 28% in Sohag (Khalifa *et al.*, 2008), to 60% in Cairo and Giza (Nahed *et al.*, 2014), to 85.7% in Qena (El-kady *et al.*, 2018), and to 88% in Menoufia (Mousa *et al.*, 2021). However, based on the authors' knowledge, there is a paucity of data regarding the zoonotic foodborne parasites, particularly sarcocystosis, which represent a critical danger for human health and important economic animals including bovines in Upper Egypt. Moreover, this remains a well-documented problem in the farming industry, particularly the invisible sarcocysts. Therefore, the current research was conducted to provide data on the occurrence percentages, tissue distribution patterns, morphological characterization, and pathological impact together with the molecular identification of *Sarcocystis* spp. from slaughtered cattle (*Bos taurus*) in Upper Egypt.

Materials and Methods

Ethical approval

This article does not contain any studies with human participants performed by any of the authors. Also, the international guidelines for the care and use of animals were followed regarding the Research Ethics Committee of the University (code No. 65).

Study area and design

A cross-sectional study was carried out in Aswan in the southern region of Egypt, which is restricted by 24° 5' 20.18" N latitude and 32° 53' 59.39" E longitude, from January 2020 to December 2020. Aswan is famously known for its beautiful Nile Valley scenery, important archaeological sites, and peaceful atmosphere. The climate is warm throughout the year, making it an ideal winter destination. Furthermore, agriculture is the main source of employment opportunities in the province with approximately 29% of the province's population working in agriculture and animal rearing.

Study animals

A total of 292 cattle (*Bos taurus*) were screened for the presence of *Sarcocystis* sarcocysts by conventional techniques to evaluate the distribution and associated risk factors for their occurrence in the study area. During the sampling, gender, age, and monthly dynamics were recorded. Moreover, the collected specimens from the cardiac muscle, esophagus, diaphragm, tongue, and masseter muscles (50 g of each) were considered for investigation. All collected specimens were conveyed to the parasitic lab. and kept at 4°C until exploration.

Parasitological analysis

The collected tissue samples were carefully inspected by naked eye examination. Briefly, a sterile blade was used to cut each muscular tissue into small pieces (3-5 mm) and each piece was assessed using a hand lens in order to visualize macroscopic cysts according to procedures illustrated by Mavi *et al.* (2020).

For light microscopic analyses, additional tissue samples from different predilection spots of each slaughtered cattle were subjected to different diagnostic tools including Muscle squash, Pepsin-HCl tissue digestion technique, and H&E staining procedures (Dubey *et al.*, 2000; Barham *et al.*, 2005).

a) Muscle squash

One g of muscles was spliced into minute pieces, approximately 3-5 mm thick, and squashed strongly between two clean slides and inspected at magnifications of $\times 400$ under the light microscope. The cyst dimensions and shape, the cyst wall structure along with the morphometric parameters of bradyzoites were thought to be a crucial issue for the morphological description of the recovered sarcocysts (Kirillova *et al.*, 2018).

b) Peptic digestion

Briefly, 4 g of inspected sample was thoroughly mixed with 3.5 ml of hydrochloric acid, 2.5 g of trypsin, and 1500 ml of distilled water. The aforementioned mixture was kept in an incubator for 30 min at 37°C after digestion and filtered through the tea strainer with fine pores and centrifuged at 2000 g for 5 min. The supernatant fluid was removed with the support of a plastic pipette and a drop from the sediment was spread, air dried, fixed, and stained by giemsa staining technique. Furthermore, all samples were inspected at magnifications of 40 and 100 in order to recognize *Sarcocystis* bradyzoites under the light microscope as maintained by Barham *et al.* (2005), and Dubey *et al.* (2015).

c) Histomorphology

Moreover, 4 tissue samples were immersed in paraffin, spliced (5 μ m thickness), stained with haematoxylin and eosin (H&E) stain and then examined under the light microscope (Makhija, 2012).

Transmission electron microscopy

To disclose the fine structural features of the

sarcocysts, the positive tissue samples were kept in 2.5% glutaraldehyde for fixation, then post-fixed in osmium tetroxide 1%, dehydrated in alcohols, and finally immersed in an epon-araldite mixture. Ultrafine slices were contrasted with uranyl acetate and lead citrate before being observed by an electron microscope (JEM 100 CXII) at 80 KV and photographed using CCD digital camera Model XR-41 (Abdel-Ghaffar *et al.*, 2009).

Molecular typing

The deoxyribonucleic acid elicitation

The deoxyribonucleic acid (DNA) was successfully elicited from three tissue samples out of thirty samples using a QIAamp DNA Mini kit (Qiagen, Germany, GmbH) in accordance with the manufacturer's instructions and kept at -20°C until the PCR analysis.

PCR

Oligonucleotide primers of *Sar1* genes were brought from Metabion (Germany) and their isolates were clarified by Bahari *et al.* (2014) as follows: Sar-F1 forward: 5'-GCA CTT GAT GAA TTC TGG CA-3' and Sar-R1 reverse: 5'-CAC CAC CCA TAG AAT CAA G-3' for amplification of *18S rDNA* genes. Briefly, the tested primers were employed in a 25 µL reaction involving 12.5 µL of EmeraldAmp Max PCR Master Mix (Takara, Japan), 1 µL of each primer of 20 pmol concentrations, 5.5 µL of water, and 5 µL of DNA model. The reaction was performed in an Applied Biosystems 2720 thermal cycler as follows: denaturation at 94°C for 5 min followed by 35 cycles of 94°C for 45 s, annealing temperature 50°C for 40 s, extension at 72°C for 45 s, and final extension step at 72°C for 10 min.

Visualization of the PCR products

The PCR product was electrophoresed on 1.5% of agarose gel (Applichem, Germany, GmbH) in 1x TBE buffer. For gel investigation, about 20 µL of the products was inserted into the gel aperture. A common Gene indicator 100 bp ladder (Fermentas, Germany) was applied to clarify the size of the amplicons, stained with Ethidium Bromide (0.5 µg/ml) and visualized under the UV light. The result was verified by using a gel imaging system (Alpha Innotech, Biometra).

Sequencing and phylogenetic analysis

PCR products were purified using QIAquick PCR product extraction kit (Qiagen, Valencia). Bigdye terminator V3.1 cycle sequencing kit (Perkin-Elmer) was utilized for the sequence reaction and the purification process was conducted utilizing Centrisep spin column. DNA sequences were obtained by Applied Biosystems 3130 genetic analyzer (HITACHI, Japan), and were exposed to a BLAST analysis performed for sequence identity as two to three genetic sequences were selected to signify each amplicon in phylogenetic investigation. The sequences were then aligned and compared with the *18S rRNA* gene sequences of *Sarcocystis* species available in GenBank (Altschul *et al.*, 1990). The phylogenetic tree was constructed by MegAlign module

of DNA Star Lasergene software (Thompson *et al.*, 1994) and the analyses were carried out utilizing maximum likelihood, neighbor joining, and maximum parsimony in MEGA6 (Tamura *et al.*, 2013).

Statistical analysis

Chi-square trial was applied to evaluate the current epidemiological profile of *Sarcocystis* infection among screened cattle. Furthermore, the validity and agreement values were characterized on the basis of the sensitivity, specificity, and Kappa agreement index of the tests under the study (Petrie and Watson, 2013).

Results

Survey outcomes

Out of 292 animals examined, 270 showed a microscopic type of the *Sarcocystis cruzi* tissue cyst indicating an overall prevalence of 92.5% (95% CI, 0.88-0.95). Based on the current results, there was no visible cysts infection in the screened samples.

The results of prevalence relative to the age and gender of the screened cows are depicted in Table 1. The obtained results revealed that the infection rate was noticed to rise with the progression of age and with a high infection rate of 93.2% among old animals as compared to the young ones (85.2%). However, this marked difference was found to be statistically insignificant. Similarly, the frequency percentage of *Sarcocystis* infection was higher among male animals as compared to the female counterpart, with an insignificant association ($P>0.05$) between the rates of infection. Also, as Table 1 illustrates, the occurrence percentage of *Sarcocystis* infection among females increased with the progress in age and there was a significant association ($P<0.05$) between the rates of infection in female cows within each age category. In contrast, an insignificant association was found between the rate of *Sarcocystis* infection and male cows within each age class.

The current study revealed that the *Sarcocystis* infection in cattle prevailed throughout the year with the highest peak of occurrence in March, August, November, and December, while the lowest percentage value was recorded in September. Based on the seasonal dynamics of infection, the peak prevalence rate of *Sarcocystis* was found in autumn (97.2%) followed by spring (95.2%), winter (91.1%), and the lowest rate was observed in summer (87.5%, Table 2) indicating an evident pattern in the seasonality of the infection. However, an insignificant difference was observed between different seasons.

The distribution pattern of *Sarcocystis* infection regarding the screened organs is clarified in Table 3. The Table 3 reveals that the most frequently infected organ was the esophagus with an infection rate of 75.9%, while the other inspected organs showed a variable percentage of infection rates. This marked difference was found to be statistically significant ($\chi^2=10.630$, $P=0.031$). Similarly, the Table 3 shows the occurrence pattern of infection within each age group and gender of the

examined cattle. Additionally, the intensity of microscopic cyst was assessed by counting the number of cysts in 1 g. The mean intensity ranged from 3 to 35 (mean 15.3).

The obtained results revealed that the peptic digestion (PD) technique is a sensitive scheme for exploring the presence of *Sarcocystis* in slaughtered cattle giving the highest positive rate (83.1%, 123/148) as compared to the muscle squash (MS) tool as depicted in Table 4. Nevertheless, *Sarcocystis* spp. cannot be correctly recognized using this test. Also, the Table 4 displays the frequencies and tissue distribution of *Sarcocystis* spp. in tissue samples detected by the two different methods. Furthermore, MS identified 77 confirmed positive samples out of the 123 specimens recognized by PD, yielding a sensitivity of 62.6%. Nevertheless, out of the 25 samples verified as negative by PD, one case was revealed positive by MS, giving a specificity of 96%. The association between MS and PD was fair with Kappa agreement test = 0.371 (Table 5).

Table 2: Monthly and seasonal dynamics of *Sarcocystis* infection among cattle

Months	Examined	Infected	%
January	26	23	88.46
February	26	22	84.62
March	27	27	100
Winter	79	72	91.1
April	25	24	96
May	12	11	91.67
June	25	24	96
Spring	62	59	95.2
July	26	25	96.15
August	25	25	100
September	29	20	68.97
Summer	80	70	87.5
October	24	22	91.67
November	23	23	100
December	24	24	100
Autumn	71	69	97.2
P-value	0.114		

Table 1: Occurrence percentages of microcysts in slaughtered cattle relative to age and gender

Age											
Age		No. of examined				Infected (%)				P-value	
<2 years		27				23 (85.2)				0.132	
≥2 years		265				247 (93.2)					
Overall		292				270				92.5%	
Sex											
Male						Female					
<2 years		≥2 years		Total		<2 years		≥2 years		Total	
Examined	Infected (%)	Examined	Infected (%)	Examined	Infected (%)	Examined	Infected (%)	Examined	Infected (%)	Examined	Infected (%)
27	23 (85.2)	243	227 (93.4)	270	250 (92.6)	0	0	22	20 (90.9)	22	20 (90.9)
P-value						0.773					

Table 3: Distribution pattern of microscopic cysts in different organs of infected cattle

Organs	Masseter muscle		Tongue		Diaphragm		Esophagus		Heart	
	Examined	Infected (%)	Examined	Infected (%)	Examined	Infected (%)	Examined	Infected (%)	Examined	Infected (%)
Age										
<2 years	27	13 (48.2)	27	14 (51.9)	27	12 (44.4)	27	17 (63)	27	12 (44.4)
≥2 years	261	175 (67.1)	261	174 (66.7)	264	182 (68.9)	263	203 (77.2)	262	181 (69.1)
Sex										
Male	266	175 (65.8)	266	174 (65.4)	269	180 (66.9)	268	204 (76.1)	267	179 (67)
Female	22	13 (59.1)	22	14 (63.6)	22	14 (63.6)	22	16 (72.7)	22	14 (63.6)
Total	288	188 (65.3)	288	188 (65.3)	291	194 (66.7)	290	220 (75.9)	289	193 (66.8)

Table 4: Comparison of muscle squash analysis (M. squash) and pepsin-digestion method (Pepsin-D.) to detect microscopic cysts in different organs

	Esophagus		Heart		Masseter Ms.		Diaphragm		Tongue		Total		P-value
	MS	PD	MS	PD	MS	PD	MS	PD	MS	PD	MS	PD	
Examined	30	30	30	30	29	29	30	29	29	29	148	148	<0.00001*
Infected (%)	22 (73)	27 (90)	13 (43)	23 (76.)	9 (31)	22 (75.9)	12 (40)	24 (80)	21 (72.4)	27 (93.1)	77 (52.03)	123 (83.1)	

MS: Muscle squash, PD: Pepsin-digestion, and * Significant difference

Table 5: Diagnostic performance of muscle squash analysis and pepsin-digestion method for detecting microscopic cysts

Muscle squash	Pepsin-digestion		Sensitivity (95% C.I.)	Specificity (95% C.I.)	K-value	SE of kappa
	+Ve (n=123)	-Ve (n=25)				
+Ve	77	1	0.626 (0.758-0.885)	0.96 (0.776-0.997)	0.341	0.062
-Ve	46	24				

Table 6: Morphological features of thin-walled cysts

Parameters	Length (μm)	Width (μm)	Wall thickness of cysts (μm)
N		11	
Min.	73.3	20.54	0.9
Max.	281.47	97.99	2.2
Mean \pm SE	135.6 \pm 19.69	51.19 \pm 6.90	1.66 \pm 0.15

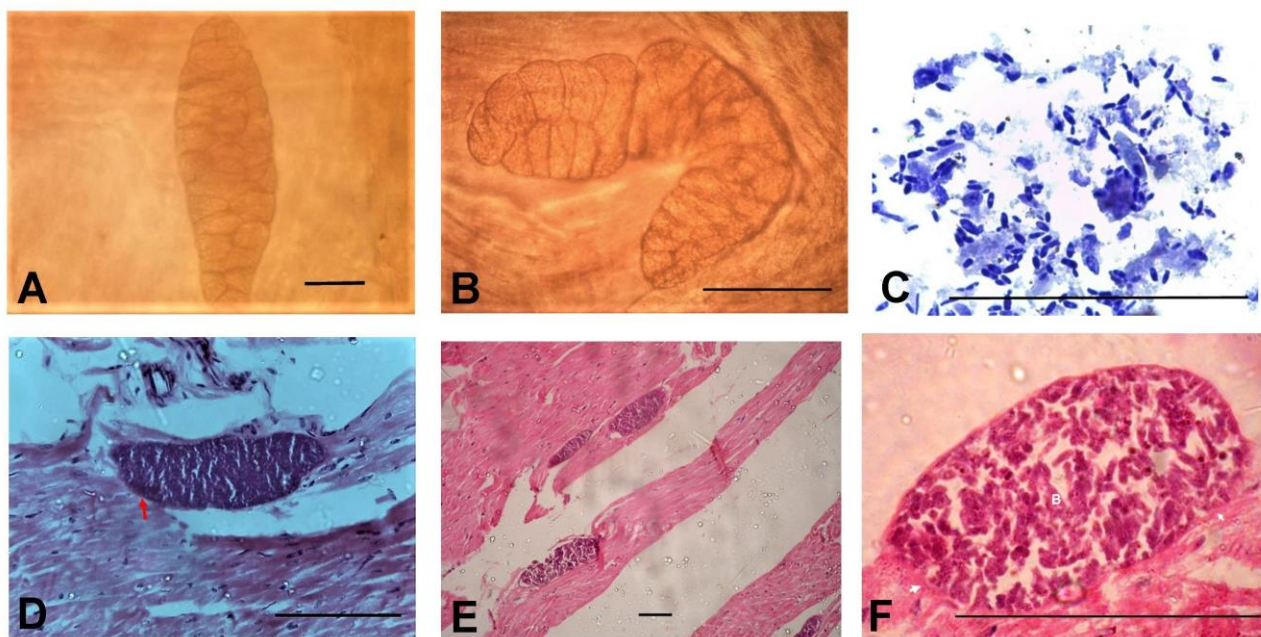


Fig. 1: A-C: Light micrographs of sarcocysts in muscle squash from cardiac muscle (A) and esophagus (B). Note the thin, smooth cyst wall with different compartments and clear septae. Crescent-shaped *Sarcocystis* bradyzoites in digested samples after staining with giemsa (C). D-F: Light micrographs of histological observation of sarcocysts in the cardiac muscles of native cattle. Note the cyst wall (red arrow), banana-like bradyzoites (B), hair-like projection (arrowhead, F) and multiple large fusiform shaped thin-walled sarcocysts (E), (H&E stain). Fig. 1 (scale bar, 100 μ)

Morphological identification

a) Light microscope observation

The recovered sarcocysts of all the inspected organs had similar morphologies and were of the thin-walled type with the assistance of LM. Subsequently, by conducting molecular investigations, cysts were identified as *S. cruzi*. The recovered cysts were elongated ovoid-shaped, with rounded tips. The cyst wall was thin and was characterized by the presence of fine hair-like protrusion that was located on its surface. The cyst core was divided into several compartments by a clear septa, and it was filled with banana-shaped bradyzoites (Figs. 1A-C).

On the histological stained sections, the recovered sarcocysts were characterized by a thin and smooth cell wall. The cysts were oval-shaped, but mostly fusiform. Additionally, several banana-like bradyzoites existed inside the cyst compartments. The micro-morphometric features of the recovered sarcocysts are illustrated in Table 6 and Figs. 1D-F.

Based on the histopathological investigation, the cysts were found in the foci of tissue necrosis and appeared to be degenerated. Also, there was an inflammation around the muscle fibers and between the cysts with an inflammatory cells infiltration consisting of neutrophils, lymphocytes, eosinophils, and plasma cells indicating myocardial sarcocystosis as shown in Figs. 2A and B. Besides, the oval-shaped sarcocysts were detected inside the muscle fibers of the esophagus with degenerative changes in the center of the recovered cysts (Figs. 2C and D).

b) TEM findings

The tissue sections showed the presence of two sarcocysts within the cardiac muscle fibers. Mature sarcocysts were fusiform shaped, measured 120 μm long and 63.6 μm across. The cyst walls were thin (1.7 μm in width) and had hair-like and flattened protrusions measured approximately 0.36 μm in length and 0.025 μm

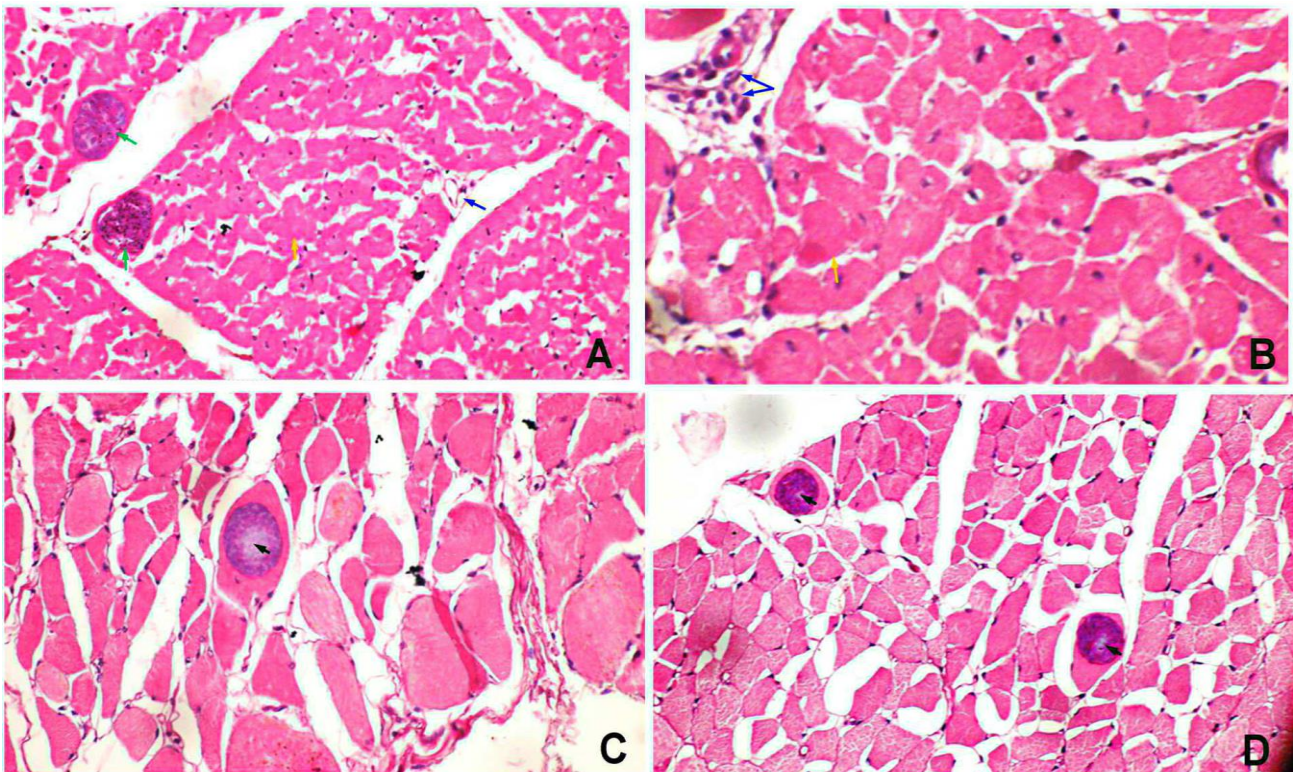


Fig. 2: A-B: Direct histopathological examination of the cardiac muscle revealed encapsulated circular to elongated basophilic sarcocysts filled with numerous bradyzoites inserted in muscle fibers (green arrows). Mononuclear cell infiltrates (blue arrow) discretely between the hyaline eosinophilic degenerated muscles (orange arrow) which are widely separated by signs of edema. C-D: Esophagus of cattle showing basophilic cysts inside the muscle fiber and the center of some cysts was degenerated and appeared as pale color (Black arrowheads) (A&D: $\times 20$, B&C: $\times 40$, LM, H&E)




Fig. 3: Transmission electron micrographs of *S. cruzi* sarcocysts from the heart of cattle (*Bos taurus*). (A) A high concentration of bradyzoites is enclosed by a thin cyst wall with magnified part of the wall showing the ground substance and protrusions. (B) Mature bradyzoites in longitudinal section with its magnified cyst wall depicting the characteristic bubble-like undulations, micropore and hair like protrusion. HC: Host cell, BZ: Mature bradyzoites, DBZ: Developing bradyzoites, CW: Cyst wall, VP: Villar protrusions, GS: Ground substance, N: Nucleus, BM: Bradyzoites membrane, MN: Micronemes (yellow arrow), Rh: Rhoptries, AM: Amylopectin granule, DG: Dense granule, C: Conoid, S: Septa, P: Hair-like protrusions, MT: Mitochondria, MP: Micropore, and BU: Bubble-like undulations

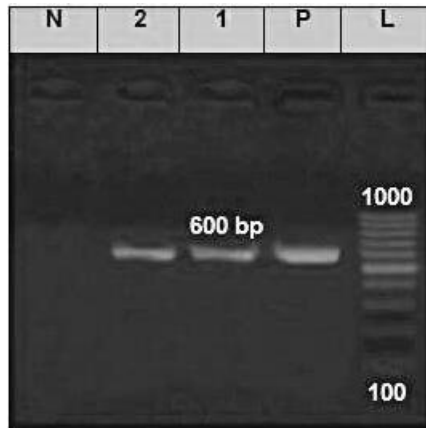


Fig. 4: Electrophoresis of PCR product of *18S rRNA* gene showing bands detected at 600 bp region belonged to *S. cruzi*. L: DNA ladder (1 kb), N: Negative control, P: Positive control, and Lanes 1-2: Beef samples

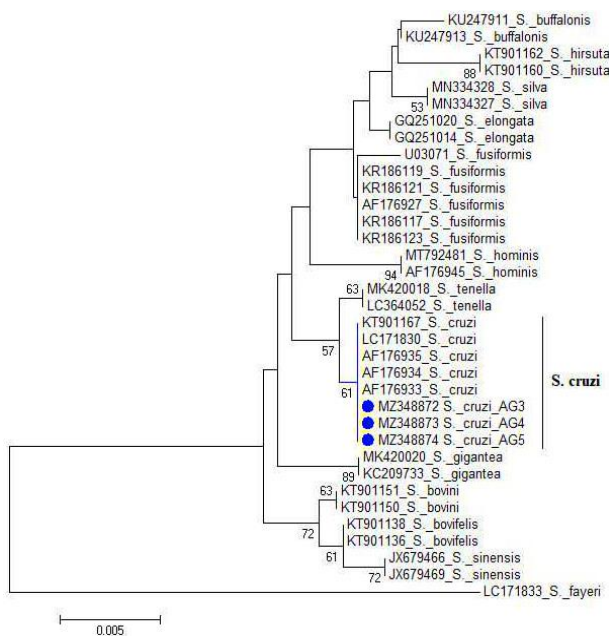


Fig. 5: Phylogenetic analysis of the *18S rRNA* gene sequences from *Sarcocystis* species and their evolutionary relationships of 31 taxa. The blue circles indicate that the isolates are *S. cruzi*

in width without microfilaments. The cysts had prominent septa that separated the core of the cyst into various chambers that enclosed different developmental stages of cystozoites. Furthermore, the sarcocysts were bounded by amorphous matrices that contained abundant fusiform bradyzoites. The primary cyst wall had numerous bubble-like undulations and the ground substance was 0.07 μm in thickness. The size of the bradyzoites reached $3\text{-}1.2 \times 0.9\text{-}0.3 \mu\text{m}$, and it had a double-membrane pellicle which consisted of 4 regions including several apicomplexan organelles as conoid, rhoptries up to 7, and a large number of micronemes in the first frontal region with abundant amylopectin granules in the second middle region. The nucleus was enclosed in the third region while further abundant amylopectin granules were located in the last posterior portion as shown in Figs. 3A and B.

PCR assay

A PCR-based assay with certain primers fructifies a smaller size band of 600 bp in PCR of *Sarl* genes, as shown in Fig. 4. *Sarl* gene amplification has been established to be an adequate tool for recognizing *Sarcocystis* species.

The phylogenetic typing

The current results suggest that sarcocystosis in Egyptian bovines is greatly linked to *S. cruzi*. Also, the BLASTN investigation of *Sarcocystis mtDNA* genes sequence displayed a 100% identity with the sequences of *S. cruzi* in cattle (accession No. MZ348872, MZ348873, and MZ348874), 99.8% similarity with *S. tenella*, 98.6% with *S. bovis*, and 98.4% with *S. fusiformis* as illustrated in Table 7. Moreover, the phylogeny of isolated *Sarcocystis* sequences indicated diversity of *Sarcocystis* species recorded in cattle as compared with the correlated isolates existing in the GenBank database (Fig. 5).

Discussion

Sarcocystis parasites are apicomplexan protozoan

Table 7: The similarity percentage of *S. cruzi* isolates with the sequences of *S. tenella* (99.8%), *S. bovis* (98.6%), and *S. fusiformis* (98.4%)

		Percent Identity																			
		1	2	3	4	5	6	7	8	9	10	11	12	13	14	15	16	17	18	19	20
Divergence	1	100.0	100.0	98.4	98.8	96.8	98.0	99.2	97.8	98.2	98.4	98.4	98.4	97.6	98.8	97.6	93.7	98.4	98.4	98.4	1
	2	0.0	100.0	98.4	98.8	96.8	98.0	99.2	97.8	98.2	98.4	98.4	98.4	97.6	98.8	97.6	93.7	98.4	98.4	98.4	2
	3	0.0	0.0	98.4	98.8	96.8	98.0	99.2	97.8	98.2	98.4	98.4	98.4	97.6	98.8	97.6	93.7	98.4	98.4	98.4	3
	4	0.4	0.4	0.4	98.8	95.7	96.4	98.0	96.2	96.6	96.8	96.8	96.0	98.2	96.0	93.1	96.8	96.8	96.8	96.8	4
	5	0.6	0.6	0.6	0.6	96.6	96.8	98.4	96.6	97.0	97.2	97.2	97.2	96.4	98.6	96.6	93.3	97.2	97.2	97.2	5
	6	0.8	0.8	0.8	1.5	1.3	97.0	96.6	96.6	96.8	96.6	96.6	96.6	96.4	97.0	97.0	93.1	96.6	96.6	96.6	6
	7	0.8	0.8	0.8	1.3	1.5	0.6	98.2	99.6	98.6	98.4	98.4	98.4	98.4	97.8	97.8	94.9	98.4	98.4	98.4	7
	8	0.4	0.4	0.4	0.4	0.6	1.5	1.1	97.8	97.8	98.0	98.0	98.0	97.6	99.2	98.0	93.3	98.0	98.0	98.0	8
	9	1.1	1.1	1.1	1.5	1.7	1.1	0.4	1.5	98.8	98.6	98.6	98.6	99.8	97.4	97.8	94.9	98.6	98.6	98.6	9
	10	1.1	1.1	1.1	1.5	1.7	1.3	1.1	1.9	0.8	99.8	99.8	99.8	98.6	97.4	98.0	94.7	99.8	99.8	99.8	10
	11	0.8	0.8	0.8	1.3	1.5	1.5	1.3	1.7	1.0	0.2	100.0	100.0	98.4	97.6	98.2	94.7	100.0	100.0	100.0	11
	12	0.8	0.8	0.8	1.3	1.5	1.5	1.3	1.7	1.0	0.2	0.0	100.0	98.4	97.6	98.2	94.7	100.0	100.0	100.0	12
	13	0.8	0.8	0.8	1.3	1.5	1.5	1.3	1.7	1.0	0.2	0.0	0.0	98.4	97.6	98.2	94.7	100.0	100.0	100.0	13
	14	1.3	1.3	1.3	1.7	1.9	1.3	0.6	1.7	0.2	1.0	1.3	1.3	97.2	97.6	94.7	98.4	98.4	98.4	98.4	14
	15	0.2	0.2	0.2	0.8	1.0	1.3	0.8	0.2	1.3	1.7	1.5	1.5	1.5	97.6	93.9	97.6	97.6	97.6	97.6	15
	16	1.1	1.1	1.1	1.5	1.5	1.7	1.3	1.0	1.3	1.5	1.3	1.3	1.3	1.5	0.8	93.1	98.2	98.2	98.2	16
	17	4.6	4.6	4.6	5.2	5.6	4.7	4.5	5.4	4.5	4.3	4.3	4.3	4.7	5.4	5.4	94.7	94.7	94.7	94.7	17
	18	0.8	0.8	0.8	1.3	1.5	1.5	1.3	1.7	1.0	0.2	0.0	0.0	0.0	1.3	1.5	1.3	4.3	100.0	100.0	18
	19	0.8	0.8	0.8	1.3	1.5	1.5	1.3	1.7	1.0	0.2	0.0	0.0	0.0	1.3	1.5	1.3	4.3	0.0	100.0	19
	20	0.8	0.8	0.8	1.3	1.5	1.5	1.3	1.7	1.0	0.2	0.0	0.0	0.0	1.3	1.5	1.3	4.3	0.0	0.0	20

organisms with global dissemination and they are one of the most common parasites infecting various livestock that can cause a severe disorder in some hosts such as cattle (Mirzaei and Rezaei, 2016). Also, some species of these parasites are important in public health since they cause clinical manifestations.

The existing survey declared that the total infection rate of *Sarcocystis* spp. was 92.5% among slaughtered cattle. Likewise, the highest peak prevalence between 91.0 and 100% was also described worldwide viz., Argentina (More *et al.*, 2008), South-West of Iran (Hamidinejat *et al.*, 2010), Southern Italy (Bucca *et al.*, 2011), Karnataka, India (Dafedar *et al.*, 2011), Italy (Chiesa *et al.*, 2013), Yazd and Hungary (Hornok *et al.*, 2015), and Iran (Sarafraz *et al.*, 2020). On the contrary, the low occurrence percentage of *Sarcocystis* spp. has been reported in different localities in Egypt (Khalifa *et al.*, 2008; Badawy *et al.*, 2012; Nahed *et al.*, 2014; Ahmed *et al.*, 2016; El-kady *et al.*, 2018; Mousa *et al.*, 2021) and across the globe like Sri Lanka (Kalubowila *et al.*, 2004), Malaysia (Latif *et al.*, 2013), and Nigeria (Mac *et al.*, 2018). This marked difference in the infection rates could be attributed to frequent issues such as the system of breeding, climatic factors, tissue type and anatomic location of analysis (Mounika *et al.*, 2018; Sheikhi *et al.*, 2020) in addition to the accessibility of definitive hosts.

The current findings showed that no visible cysts were detected in the screened tissue samples, and this issue was supported by the findings of the majority of earlier revisions (Okur *et al.*, 1995; Nourollahi-Fard *et al.*, 2009). The paucity of macroscopic cysts could be explained by the fact that such cysts are of feline origin and that cattle-cat contact in the studied area is uncommon (Shekarforoush *et al.*, 2013).

In the current survey, a statistically insignificant relationship was found between the cows' age and the prevalence and higher frequency percentages among old age groups. This finding was in line with the records of *Sarcocystis* infection in cattle from other countries (Bucca *et al.*, 2011; Hajimohammadi *et al.*, 2014). In contrast, Hornok *et al.* (2015) and Mounika *et al.* (2018) showed that the infection rate of bovine sarcocystosis among different age categories was statistically significant. This might be attributed to long-term exposure of matured cows to the infective stage. Likewise, the infection was more common in males and, according to the statistical results, this difference was insignificant, and this is in accordance with the previous data carried out by Taib *et al.* (2016) who could not report a significant difference between sexes and the frequency of parasites. In contrast to the present findings, a significant relationship between the rate of *Sarcocystis* infection and the gender of inspected cows was reported by More *et al.* (2008) and Nourani *et al.* (2010). These differences may be due to differences in the management conditions in such localities. Also, according to the culture of Egyptian farmers in Upper Egypt, they prefer to keep female animals inside home buildings for breeding under good and clean environment, whereas

most of the males are left in open-air pasture for grazing and are used by owners for hard labor; as a result, they may be more prone to the infection.

Currently, the present results indicated an insignificant relationship between the seasonality and prevalence of sarcocystosis, with a higher frequency of occurrence in the autumn (97.2%). Our findings correspond with results described by Nematollahia *et al.* (2013) who could not report a significant difference between season and the frequency of parasites. In contrast, Shahraki *et al.* (2018) reported the highest incidence of *Sarcocystis* infection in the spring (91.7%). Also, in another study in Egypt, the highest parasite outbreak was reported in June (16.13%) and the lowest in April (4%) (Ahmed *et al.*, 2016). These findings might be attributed to the longer grazing periods in the autumn. The survival and viability of sporocysts in the environment is another factor influencing the seasonal dynamics of the infection organized by climatic circumstances such as temperature, rainfall, and humidity.

Concerning the distribution pattern of the infection, there was a significant correlation between the rates of infection and the inspected tissues with the most frequently infected organ being the esophagus (75.9%). Likewise, Hu *et al.* (2017) in China mentioned that the distribution of the sarcocysts was 84.9% in the esophagus, 32.6% in the tongue, 57% in the diaphragm, 20.9% in the heart, and 79.1% in skeletal muscles. Similarly, other earlier revisions have shown that sarcocysts were more frequently realized in the esophagus than in any other regions of the bovine body (Nourani *et al.*, 2010; Domenis *et al.*, 2011; Abdullah, 2021). On the contrary, Shahraki *et al.* (2018) reported that the highest frequency percentage was found in the heart (68%) and the lowest in the esophagus (36.6%). Furthermore, *Sarcocystis* was also detected in cattle cardiac muscles at total infection rates of 100% in Brazil by Ferreira *et al.* (2018). In a study in Zabol, Iran, the positivity rate of thin-walled cysts was 58.8% for the cardiac muscle, 13.9% for Masseter muscles, 10.2% for the tongue, 9.3% for the esophagus, and 7.8% for the diaphragm (Faghiri *et al.*, 2019). Our findings suggest that the esophagus is a good selected location for sarcocysts in bovine body for future surveys.

The obtained consequences depicted that pepsin digestion is more accurate than the muscle squash approach in the recognition of *Sarcocystis* infection. Similarly, Davoudi *et al.* (2017) and Shahraki *et al.* (2018) also concluded that peptic digestion is a more efficient method for detection of infection. Also, this procedure is less complicated and quicker than other traditional approaches (Farhang-Pajuh *et al.*, 2014).

With respect to the evaluation of sensitivity and specificity of MS to PD, MS examination showed a great specificity with moderate sensitivity relative to PD recognition. The current differences in sensitivity and specificity could have a substantial influence on the finding and controlling of sarcocystosis. It seems that more than one test might be crucial for the recognition of

sarcocystosis.

In the current study, light microscope (LM) revision revealed that the sarcoplasms of the myocardia presented with bradyzoites enclosed in the thin smooth cyst walls, and the cysts ranged in morphology from oval to fusiform and measured between 73.3×281.1 (mean 135) μm in size; this description is similar to those in previous studies (Yang *et al.*, 1990; Choi *et al.*, 2018). Inappropriately, however, LM cannot recognize the difference between the three *Sarcocystis* spp. infecting cattle. *S. cruzi* thin-walled cysts can simply be discerned from *S. hominis* and *S. hirsuta* thick-walled sarcocysts conducted by histological sections as *S. hominis* and *S. hirsuta* have thick, radially striated cyst walls. The ultrastructure description of the recovered sarcocysts, on the other hand, showed close similarities with earlier studies illustrated by Mehlhorn *et al.* (1976), Dubey *et al.* (1989), and Calveria *et al.* (2001). Besides, the muscular tissue cysts of *Toxoplasma gondii* and *Hammondia hammondi* can easily be discerned from the recovered sarcocysts by the absence of septa (Mehlhorn *et al.*, 1980).

Regarding the histopathological findings, the current data showed inflammatory reactions around some of the recovered micro-sarcocysts with marked degenerative changes. Consistently, muscle tissue invaded by *Sarcocystis* spp. cysts may become inflamed with abundant inflammatory cell infiltration as well as muscle fiber degradation, and necrosis was noticed (Nourollahi-Fard *et al.*, 2015; Januškevičius *et al.*, 2018; Abdullah, 2021).

The 18S rRNA fragment is regarded as a sufficient tool for the differentiation of *Sarcocystis* spp. worldwide. On the basis of molecular analysis, the current study confirmed the presence of *S. cruzi* in cattle. This finding was endorsed by the previous report of Choi *et al.* (2018), Prakas *et al.* (2020), and Portella *et al.* (2021). Likewise, a uniform cattle haplotype of *S. cruzi* appears to be geographically widespread (Rosenthal *et al.*, 2008), and identical sequences of these species have been reported from Argentina to Japan (Gjerde, 2013). This finding confirms that dogs and cattle frequently interact in Egyptian farms, favoring the parasite life cycle (Ferreira *et al.*, 2018).

Concerning *Sarcocystis*-specific tissue matrices, the current study confirmed that *S. cruzi* was the only *Sarcocystis* species identified in the inspected tissue samples of cattle based on molecular analysis. In contrast, Ferreira *et al.* (2018) found that *S. cruzi* was the only species detected infecting the cattle hearts. Also, Portella *et al.* (2021) revealed that *S. cruzi* was identified in heart samples from cattle after genetic sequencing. Another investigation demonstrated the presence of *S. cruzi* in the diaphragm muscles of cattle (Prakas *et al.*, 2020). This difference is due to the muscle tissue selected for the analysis.

In conclusion, to the best of our knowledge, the current study is the first to identify *Sarcocystis cruzi* as the main and most pathogenic species in cattle in the studied area both morphologically and molecularly;

therefore, more attention should be given to avoid economic losses in meat industry. Additionally, the current survey demonstrated high prevalence of infection with microscopic cysts of *Sarcocystis* spp. in cattle intended for human consumption in Aswan, Egypt. Thus, farmers and veterinarians' awareness, creation, and strategies aimed at breaking the life cycle of the parasite are required to reduce the spread of the parasite and, thereby, the expected zoonotic and economic impact. Also, our data demonstrated that the peptic digestion assays studied in the current analysis can be very useful. Epidemiological concern and further genotyping of other genetic markers provide the knowledge about the genetic diversity and frequencies of *Sarcocystis* spp. among other Egyptian livestock.

Acknowledgements

We would like to sincerely thank the members of the Faculty of Veterinary Medicine, South Valley University, Qena for their support of this research. Also, we would like to acknowledge the Deanship of postgraduate and scientific research, South Valley University for supporting this research.

Conflict of interest

The authors declare that they have no conflict of interests.

References

- Abdel-Ghaffar, F; Mehlhorn, H; Bashtar, AR; Sakran, T and El-Fayoumi, H (2009). Life cycle of *Sarcocystis camelicanis* infecting the camel (*Camelus dromedarius*) and the dog (*Canis familiaris*) light and electron microscopic study. Parasitol. Res., 106: 189-195. doi: 10.1007/s00436-009-1648-x.
- Abdullah, SH (2021). Investigation of *Sarcocystis* spp. in slaughtered cattle and sheep by peptic digestion and histological examination in Sulaimani Province, Iraq. Vet. World. 14: 468-474. doi: 10.14202/vetworld.2021.468-474.
- Ahmed, AM; Elshraway, NT and Youssef, AI (2016). Survey on *Sarcocystis* in bovine carcasses slaughtered at the municipal abattoir of El-Kharga, Egypt. Vet. World. 9: 1461-1465. doi: 10.14202/vetworld.2016.1461-1465.
- Altschul, SF; Gish, W; Miller, W; Myers, EW and Lipman, DJ (1990). Basic local alignment search tool. J. Mol. Biol., 215: 403-410. doi: 10.1016/S0022-2836(05)80360-2.
- Aráoz, V; Silveira, C; Gastón, M; Banchemo, G; Riet-Correa, F and Giannitti, F (2019). Fatal *Sarcocystis cruzi*-induced eosinophilic myocarditis in a heifer in Uruguay. J. Vet. Diagn. Invest., 31: 656-660. doi: 10.1177/1040638719856651.
- Badawy, AII; Abouzaid, NZ and Ahmed, HA (2012). *Sarcocystis hominis* and other *Sarcocystis* species infecting cattle in Sharkia province, Egypt. J. Am. Sci., 8: 271-275.
- Bahari, P; Salehi, M; Seyedabadi, M and Mohammadi, A (2014). Molecular identification of macroscopic and microscopic cysts of *Sarcocystis* in sheep in North Khorasan Province, Iran. Int. J. Mol. Cell Med., 3: 51-56.
- Barham, M; Stützer, H; Karanis, P; Latif, BM and Neiss,

- WF (2005). Seasonal variation in *Sarcocystis* species infections in goats in northern Iraq. *Parasitology*, 130: 151-156. doi: 10.1017/s0031182004006134.
- Bucca, M; Brianti, E; Giuffrida, A; Ziino, G; Ciccari, S and Panebianco, A** (2011). Prevalence and distribution of *Sarcocystis* spp. cysts in several muscles of cattle slaughtered in Sicily, Southern Italy. *Food Control*, 22: 105-108. doi: 10.1016/j.foodcont.2010.05.015.
- Chen, X; Zuo, Y; Rosenthal, BM; He, Y; Cui, L and Yang, Z** (2011). *Sarcocystis sinensis* is an ultrastructurally distinct parasite of water buffalo that can cause foodborne illness but cannot complete its life-cycle in human beings. *Vet. Parasitol.*, 178: 35-39. doi: 10.1016/j.vetpar.2010.12.026.
- Chiesa, F; Muratore, E; Dalmasso, A and Civera, T** (2013). A new molecular approach to assess the occurrence of *Sarcocystis* spp. in cattle and products thereof: preliminary data. *Ital. J. Food Saf.*, 2: 148-151.
- Choi, T; Hong, E; Ryu, S; Sim, C; Chae, JS; Kim, HC; Park, J; Choi, KS; Yu, DH; Yoo, JG and Park, BK** (2018). Detection and identification of *Sarcocystis cruzi* (Protozoa: Apicomplexa) by molecular and ultrastructural studies in naturally infected Korean cattle (*Bos taurus coreanae*) from Daejeon, Korea. *Korean J. Parasitol.*, 56: 121-127. doi: 10.3347/kjp.2018.56.2.121.
- Claveria, FG; San-Pedro, LR; Cruz-Flores, MJ; Nagasawa, H; Suzuki, N and De La Peña, C** (2001). Ultrastructural studies of *Sarcocystis cruzi* (Hassellmann, 1926) Wenyon, 1926 infection in cattle (*Bos taurus*): Philippine cases. *Parasite*, 8: 251-254. doi: 10.1051/parasite/2001083251.
- Dafedar, A; D'Souza, PE and Mamatha, GS** (2011). Prevalence and morphological studies on *Sarcocystis* species infecting cattle in Bangalore. *J. Vet. Parasitol.*, 25: 183-184.
- Davoudi, J; Shabestari, AB; Mozahheb, P; Norouzi, R; Maadina, M and Mahmoudi, R** (2017). A study of *Sarcocystis* infection in mincemeat using digestion method in Ghazvin, Iran. *Arch. Hyg. Sci.*, 6: 178-181.
- Domenis, L; Peletto, S; Sacchi, L; Clementi, E; Genchi, M; Felisari, L; Felisari, C; Mo, P; Modesto, P; Zuccon, F; Campanella, C; Maurella, C; Guidetti, C and Acutis, PL** (2011). Detection of a morphogenetically novel *Sarcocystis hominis*-like in the context of a prevalence study in semi-intensively bred cattle in Italy. *Parasitol. Res.*, 109: 1677-1687. doi: 10.1007/s00436-011-2441-1.
- Dubey, JP** (2015). Foodborne and waterborne zoonotic sarcocystosis. *Food Waterborne Parasitol.*, 1: 2-11. <https://doi.org/10.1016/j.fawpar.2015.09.001>.
- Dubey, JP; Speer, CA and Lindsay, DS** (2000). *In vitro* cultivation of schizonts of *Sarcocystis speeri* Dubey and Lindsay, 1999. *J. Parasitol.*, 86: 671-678. doi: 10.1645/0022-3395(2000)086.
- El-Kady, AM; Hussein, NM and Hassan, AA** (2018). First molecular characterization of *Sarcocystis* spp. in cattle in Qena Governorate, Upper Egypt. *J. Parasit. Dis.*, 42: 114-121. doi: 10.1007/s12639-017-0974-7.
- El-Morsey, A; Abdo, W; Sultan, K; Elhawary, NM and Abouzaid, AA** (2019). Ultrastructural and molecular identification of the sarcocysts of *Sarcocystis tenella* and *Sarcocystis arieticanis* infecting domestic sheep (*Ovis aries*) from Egypt. *Acta Parasitol.*, 64: 501-513. doi: 10.2478/s11686-019-00070-8.
- Faghiri, E; Davari, A and Nabavi, R** (2019). Histopathological survey on *Sarcocystis* species infection in slaughtered cattle of Zabol-Iran. *Turkiye Parazit. Derg.*, 43: 182-186. doi: 10.4274/tpd.galenos.2019.6480.
- Farhang-Pajuh, F; Yakhchali, M and Mardani, K** (2014). Molecular determination of abundance of infection with *Sarcocystis* species in slaughtered sheep of Urmia, Iran. *Vet. Res. Forum*, 5: 181-186.
- Fayer, R** (2004). *Sarcocystis* spp. in human infections. *Clin. Microbiol. Rev.*, 17: 894-902. doi: 10.1128/CMR.17.4.894-902.2004.
- Ferreira, MST; Vogel, FSF; Sangioni, LA; Cezar, AS; Braunig, P; de Avilla Botton, S; Camillo, G and Portella, LP** (2018). *Sarcocystis* species identification in cattle hearts destined to human consumption in southern Brazil. *Vet. Parasitol. Reg. Stud. Reports*, 14: 94-98. doi: 10.1016/j.vprsr.2018.09.002.
- Gjerde, B** (2013). Phylogenetic relationships among *Sarcocystis* species in cervids, cattle and sheep inferred from the mitochondrial cytochrome C oxidase subunit I gene. *Int. J. Parasitol.*, 43: 579-591. doi: 10.1016/j.ijpara.2013.02.004.
- Gjerde, B** (2016). Molecular characterisation of *Sarcocystis bovifelis*, *Sarcocystis bovini* n. sp., *Sarcocystis hirsuta* and *Sarcocystis cruzi* from cattle (*Bos taurus*) and *Sarcocystis sinensis* from water buffaloes (*Bubalus bubalis*). *Parasitol. Res.*, 115: 1473-1492. <https://doi.org/10.1007/s00436-015-4881-5>.
- Hajimohammadi, B; Dehghani, A; Ahmadi, MM; Eslami, G; Oryan, A and Khamesipour, A** (2014). Prevalence and species identification of *Sarcocystis* in raw hamburgers distributed in Yazd, Iran using PCR-RFLP. *J. Food Qual. Hazards Control*, 1: 15-20.
- Hamidinejat, H; Jalali, MHR and Nabavi, L** (2010). Survey on *Sarcocystis* infection in slaughtered cattle in South-West of Iran, emphasized on evaluation of muscle squash in comparison with digestion method. *J. Anim. Vet. Adv.*, 9: 1724-1726. doi: 10.3923/javaa.2010.1724.1726.
- Hornok, S; Mester, A; Takacs, N; Baska, F; Majoros, G; Fok, E; Biksi, I; Nemet, Z; Hornyak, A; Janosi, S and Farkas, R** (2015). *Sarcocystis* infection of cattle in Hungary. *Parasit. Vectors*, 8: 69-75. doi: 10.1186/s13071-015-0685-9.
- Hu, JJ; Huang, S; Wen, T; Esch, GW; Liang, Y and Li, HL** (2017). *Sarcocystis* spp. in domestic sheep in Kunming City, China: prevalence, morphology, and molecular characteristics. *Parasite*, 24: 30-38. doi: 10.1051/parasite/2017025.
- Januškevičius, V; Januškevičienė, G; Banys, A; Dailidavičienė, J and Anilienė, A** (2018). Biochemical profile of blood in naturally occurring *Sarcocystis* infection in cattle. *Acta Vet. Brno.*, 87: 205-211. <https://doi.org/10.2754/avb201887030205>.
- Kalubowila, DG; Udagama-Randeniya, PV; Perera, NA and Rajapakse, RP** (2004). Seroprevalence of *Sarcocystis* spp. in cattle and buffaloes from the wet and dry zones of Sri Lanka: a preliminary study. *J. Vet. Med. B. Infect. Dis. Vet. Public Health*, 51: 89-93. doi: 10.1111/j.1439-0450.2004.00726.x.
- Khalifa, RM; El-Nadi, NA; Sayed, FG and Omran, EK** (2008). Comparative morphological studies on three *Sarcocystis* species in Sohag, Egypt. *J. Egypt. Soc. Parasitol.*, 38: 599-608.
- Kirillova, V; Prakas, P; Calero-Bernal, R; Gavarāne, I; Fernández-García, JL; Martínez-González, M; Rudaitytė-Lukošienė, E; Martínez-Estélez, MÁH; Butkauskas, D and Kirjušina, M** (2018). Identification and genetic characterization of *Sarcocystis arctica* and *Sarcocystis lutrae* in red foxes (*Vulpes vulpes*) from Baltic States and Spain. *Parasit. Vectors*, 11: 173-182. doi: 10.1186/s13071-018-2694-y.
- Latif, B; Vellayan, S; Heo, C; Kannan, M; Omar, E; Abdullah, S and Tappe, D** (2013). High prevalence of

- muscular sarcocystosis in cattle and water buffaloes from Selangor, Malaysia. *Trop. Biomed.*, 30: 699-705.
- Lucas, JR; Barrios-Arpi, M; José, R; Stephanie, B; Zarria, J; Namiyama, G; Noelia, T and Gonzales-Viera, O** (2019). Ultrastructural description of *Sarcocystis* sp. in cardiac muscle of naturally infected Alpacas (*Vicugna pacos*). *Iran. J. Parasitol.*, 14: 174-179.
- Mac, PA; Ibrahim, TM; Buba, DM; Airiohuodion, PA and Ambu, S** (2018). Prevalence of *Sarcocystis* species in meat of cattle, pigs and birds slaughtered in North Central Nigeria. *J. Vet. Sci. Med. Diagn.*, 7: 5-11. doi: 10.4172/2325-9590.1000269.
- Makhija, M** (2012). Histological identification of muscular *Sarcocystis*: a report of two cases. *Indian J. Pathol. Microbiol.*, 55: 552-554. doi: 10.4103/0377-4929.107813.
- Mavi, SA; Teimouri, A; Mohebbali, M; Sharifi Yazdi, MK; Shojaee, S; Rezaian, M; Salimi, M and Keshavarz, H** (2020). *Sarcocystis* infection in beef and industrial raw beef burgers from butcheries and retail stores: A molecular microscopic study. *Heliyon*. 6: e04171. doi: 10.1016/j.heliyon.2020.e04171.
- Mehlhorn, H and Frenkel, JK** (1980). Ultrastructural comparison of cysts and zoites of *Toxoplasma gondii*, *Sarcocystis muris*, and *Hammondia hammondi* in skeletal muscle of mice. *J. Parasitol.*, 66: 59-67.
- Mehlhorn, H; Hartley, WJ and Heydorn, AO** (1976). A comparative ultrastructural study of the cyst wall of 13 *Sarcocystis* species. *Protistologica*. 12: 451-467.
- Mirzaei, M and Rezaei, H** (2016). A survey on *Sarcocystis* spp. infection in cattle of Tabriz city, Iran. *J. Parasit. Dis.*, 40: 648-651. doi: 10.1007/s12639-014-0551-2.
- Motamedi, GR; Dalimi, A; Nouri, A and Aghaeipour, K** (2011). Ultrastructural and molecular characterization of *Sarcocystis* isolated from camel (*Camelus dromedarius*) in Iran. *Parasitol. Res.*, 108: 949-954. doi: 10.1007/s00436-010-2137-y.
- Moré, G; Basso, W; Bacigalupe, D; Venturini, MC and Venturini, L** (2008). Diagnosis of *Sarcocystis cruzi*, *Neospora caninum* and *Toxoplasma gondii* infections in cattle. *Parasitol. Res.*, 102: 671-675. doi: 10.1007/s00436-007-0810-6.
- Moré, G; Pantchev, A; Skuballa, J; Langenmayer, MC; Maksimov, P; Conraths, FJ; Venturini, MC and Schares, G** (2014). *Sarcocystis sinensis* is the most prevalent thick-walled *Sarcocystis* species in beef on sale for consumers in Germany. *Parasitol. Res.*, 113: 2223-2230. doi: 10.1007/s00436-014-3877-x.
- Mounika, K; Chennuru, S; Ravipati, V; Tumati, SR and Krovvidi, S** (2018). Studies on prevalence and histomorphology of *Sarcocystis* species infecting cattle in Andhra Pradesh, India. *J. Parasit. Dis.*, 42: 77-80. doi: 10.1007/s12639-017-0968-5.
- Mousa, MM; Sokkary, MYE and Hegazy, MA** (2021). The prevalence of sarcocystis affecting slaughtered cattle and buffalo at Sirs-Eliab abattoir in Egypt. *Alex. J. Vet. Sci.*, 69: 49-58. doi: 10.5455/ajvs.125880.
- Murata, R; Suzuki, J; Hyuga, A; Shinkai, T and Sadamasu, K** (2018). Molecular identification and characterization of *Sarcocystis* spp. in horsemeat and beef marketed in Japan. *Parasite*. 25: 27-35. doi: 10.1051/parasite/2018026.
- Nahed, H; Ghoneim, WM and Nader, MS** (2014). Occurrence of zoonotic sarcosporidiosis in slaughtered cattle and buffaloes in different abattoirs in Egypt. *Global Vet.*, 13: 809-813. doi: 10.5829/idosi.gv.2014.13.05.86211.
- Nematollahia, A; Khoshkerdar, A; Helan, JA; Shahbazi, P and Hassanzadeh, P** (2015). A study on the rate of infestation to *Sarcocystis* cysts in supplied raw hamburgers. *J. Parasit. Dis.*, 39: 276-279. <https://doi.org/10.1007/ms12639-013-0339-9>.
- Nourani, H; Matin, S; Nouri, A and Azizi, H** (2010). Prevalence of thin walled *Sarcocystis cruzi* and thick-walled *Sarcocystis hirsuta* or *Sarcocystis hominis* from cattle in Iran. *Trop. Anim. Health Prod.*, 42: 1225-1227. doi: 10.1007/s11250-010-9552-z.
- Nourollahi-Fard, SR; Asghari, M and Nouri, F** (2009). Survey of *Sarcocystis* infection in slaughtered cattle in Kerman, Iran. *Trop. Anim. Health Prod.*, 41: 1633-1636. doi: 10.1007/s11250-009-9358-z.
- Nourollahi-Fard, SR; Kheirandish, R and Sattari, S** (2015). Prevalence and histopathological finding of thin-walled and thick-walled *Sarcocystis* in slaughtered cattle of Karaj abattoir, Iran. *J. Parasit. Dis.*, 39: 272-275. <https://doi.org/10.1007/s12639-013-0341-2>.
- Okur, H; Kandemir, O and Sahine, I** (1995). An investigation on *Sarcocystis* species in cattle and sheep from Bayburt. *Turkiye Parazit. Derg.*, 19: 113-118.
- Ota, T; Nakano, Y; Mizuno, T; Shiozaki, A; Hori, Y; Yamanishi, K; Hayakawa, K; Hayakawa, T; Fujimoto, T; Nakamoto, C; Maejima, K; Wada, Y; Terasoma, F and Ohnishi, T** (2019). First case report of possible *Sarcocystis truncata*-induced food poisoning in venison. *Intern Med.*, 58: 2727-2730. doi: 10.2169/internalmedicine.2817-19.
- Petrie, A and Watson, P** (2013). *Statistics for veterinary and animal science*. 1st Edn., Oxford, Blackwell Publishing. PP: 101-109.
- Portella, LP; Fernandes, F; Rodrigues, FS; Minuzzi, CE; Sangioni, LA; Flores, MM and Vogel, FSF** (2021). Macroscopic, histological, and molecular aspects of *Sarcocystis* spp. infection in tissues of cattle and sheep. *Rev. Bras. Parasitol. Vet.*, 30: e003621. doi: 10.1590/S1984-29612021050.
- Prakas, P; Strazdaitė-Zielienė, Ž; Januškevičius, V; Chiesa, F; Baranauskaitė, A; Rudaitytė-Lukošienė, E; Servienė, E; Petkevičius, S and Butkauskas, D** (2020). Molecular identification of four *Sarcocystis* species in cattle from Lithuania, including *S. hominis*, and development of a rapid molecular detection method. *Parasit. Vectors*. 13: 1-9. <https://doi.org/10.1186/s13071-020-04473-9>.
- Rosenthal, BM** (2013). *Sarcocystosis: Hunter's tropical medicine and emerging infectious disease*. 9th Edn., Chapter 103, Amsterdam, Netherlands, Elsevier. PP: 780-783. doi: 10.1016/B978-1-4160-4390-4.00103-X.
- Rosenthal, BM; Dunams, DB and Pritt, B** (2008). Restricted genetic diversity in the ubiquitous cattle parasite, *Sarcocystis cruzi*. *Infect. Genet. Evol.*, 8: 588-592. doi: 10.1016/j.meegid.2008.04.004.
- Sarafraz, N; Spotin, A; Haniloo, A and Fazaeli, A** (2020). Prevalence and molecular analysis of *Sarcocystis* infections in cattle in Northwest Iran and the first global report of *S. gigantea* in cattle. *Comp. Immunol. Microbiol. Infect. Dis.*, 73: 101566. doi: 10.1016/j.cimid.2020.101566.
- Shahraki, MK; Ghanbarzahi, A and Dabirzadeh, M** (2018). Prevalence and histopathology of *Sarcocystis* in slaughtered carcasses in southeast Iran. *J. Adv. Vet. Anim. Res.*, 5: 381-387. doi: 10.5455/javar.2018.e288.
- Sheikhi, M; Salahi-Moghaddam, A; Najafi Asl, M; Farahani, A and Shamseddin, J** (2020). A survey on the frequency of *Sarcocystis* in Bandar Abbas, Iran in 2019-2020. *Gene Cell Tissue*. 7: e109990. doi: 10.5812/gct.109990.
- Shekarforoush, S; Razavi, S and Abbasvali, M** (2013). First detection of *Sarcocystis hirsuta* from cattle in Iran. *Iran. J. Vet. Res.*, 14: 155-157. doi: 10.22099/ijvr.2013.1591.

- Sudan, V; Kumar, R; Shanker, D and Singh, A** (2021). Sequence phylogenetic analysis and associative genetic diversity of *Sarcocystis hirsuta* based on *18S rRNA* gene. Beni-Suef Univ. J. Basic Appl. Sci., 10: 1-5. doi: 10.1186/s43088-021-00112-z.
- Taib, M; Harhoura, K; Aissi, M; Chaouadi, M and Djouhri, Y** (2016). Study of the bovine Sarcosporidiosis in the slaughterhouses of the North of Algeria: case of the Slaughterhouses of El Harrach (Algiers). Cell Dev. Biol., 5: 167-175.
- Tamura, K; Stecher, G; Peterson, D; Filipski, A and Kumar, S** (2013). MEGA6: Molecular evolutionary genetics analysis version 6.0. Mol. Biol. Evol., 30: 2725-2729. doi: 10.1093/molbev/mst197.
- Thompson, JD; Higgins, DG and Gibson, TJ** (1994). CLUSTAL W: improving the sensitivity of progressive multiple sequence alignment through sequence weighting, position-specific gap penalties and weight matrix choice. Nucleic Acids Res., 22: 4673-4680. doi: 10.1093/nar/22.22.4673.
- Vangeel, L; Houf, K; Geldhof, P; Nollet, H; Vercruyse, J; Ducatelle, R and Chiers, K** (2012). Intramuscular inoculation of cattle with *Sarcocystis* antigen results infocal eosinophilic myositis. Vet. Parasitol., 183: 224-230. doi: 10.1016/j.vet.par.2011.07.048.
- Yang, J; Kang, YB; Wee, SH; Lee, S and Kim, K** (1990). Prevalence of *Sarcocystis* infections in the slaughtered cattle in Cheju. Korean J. Vet. Res., 30: 507-510.