

Surgical Management of Comminuted, Displaced Greater Tuberosity Fractures: A New Technique of Subacromial Spacer on Top of Double-Row Suture Anchor Fixation

Leslie Naggar¹

¹ Cabinet Médical, Lausanne, Switzerland

Joints 2018;6:211–214.

Address for correspondence Leslie Naggar, MD, Cabinet Médical, Avenue du Servan 8, 1006 Lausanne, Switzerland (e-mail: cabinet.naggar@ortho-centre.ch).

Abstract

Arthroscopic treatment of greater tuberosity (GT) fractures has been previously described. Arthroscopy allows identifying and addressing coexisting injuries, such as rotator cuff tears, labrum, or superior labrum anterior and posterior lesions, which are often present. Fracture comminution precludes the use of rigid fracture fixation with screws and arthroscopic rotator cuff repair is performed instead. Recent articles have depicted the role of the balloon-shaped subacromial spacer in massive and irreparable rotator cuff tears. The purpose of this technical report is to outline another use of the spacer in patients with a GT fracture. The concept is to leverage the advantage of the compression effect of the subacromial spacer to prevent displacement of the GT fracture and allow early active shoulder rehabilitation, especially in comminuted or eggshell fractures when rigid fixation is not feasible.

Keywords

- ▶ greater tuberosity
- ▶ fracture
- ▶ arthroscopy
- ▶ subacromial spacer
- ▶ balloon

Introduction

Greater tuberosity (GT) fractures usually occur in younger patients and account for 20% of all proximal humeral fractures.¹ Surgical treatment of displaced GT fractures is usually recommended when as little as 3 to 5 mm of superior displacement occurs, because it alters rotator cuff biomechanics and may cause subacromial impingement in active patients.¹ Standard X-ray imaging is used to determine the amount of displacement of the GT fracture. If concomitant injuries are suspected, a magnetic resonance imaging can be useful.

Arthroscopic treatment of these fractures using percutaneous screw fixation has been described.^{2,3} Fracture comminution precludes the use of rigid fixation with screws and an arthroscopic double-row suture anchor fixation technique is used instead.^{4–7} The advantage of arthroscopic treatment is to identify and address concomitant injuries, such as rotator cuff or labral tears, and superior labrum anterior and posterior lesions, which are often present.^{1,8,9}

The InSpace device (OrthoSpace, Caesarea, Israel) is a biodegradable spacer (balloon shape) which is implanted between the acromion and the humeral head and helps to recenter the humeral head relative to the glenoid. The InSpace system consists of a cylinder cannula introducer in which the implantable part (the spacer) is folded to ease arthroscopic insertion. The spacer exists in three sizes: small (40 × 50 mm), medium (50 × 60 mm), and large (60 × 70 mm), to support various shoulder sizes. The InSpace is inflated using a physiological solution (e.g., saline) and biodegrades within 12 months after implantation. The spacer can be introduced using either arthroscopic, fluoroscopic, or mini-open approaches. While using an arthroscopic technique, it is positioned in the subacromial space through an anterolateral portal.

The spacer produces a humeral head depression restoring shoulder biomechanics, and serves as a temporary bursa substitute permitting frictionless gliding between the humeral head and the acromion. Recently, several studies have described the role of the spacer implantation, in massive and

received
December 28, 2017
accepted
September 9, 2018
published online
October 31, 2018

DOI <https://doi.org/10.1055/s-0038-1675162>.
ISSN 2282-4324.

Copyright © 2018 Georg Thieme Verlag
KG Stuttgart · New York

License terms



irreparable rotator cuff tears.¹⁰⁻¹⁷ There are no specific contraindications for device use, apart from a known allergy to the spacer material and implantation into areas with active or latent infection, or signs of tissue necrosis.

The purpose of this technical report is to outline another use of the InSpace system in patients with a GT fracture. The concept is to leverage the advantage of the compression effect of the subacromial spacer to prevent displacement of the GT fracture, especially in comminuted or eggshell fractures when rigid fixation is not feasible.

Surgical Technique

The lateral decubitus position is preferred for this procedure, but it can also be performed in the beach chair setting. Patients are usually under general anesthesia with scalene block supplementation.

Diagnostic arthroscopy is performed first through a posterior portal to determine if coexisting injuries, such as subscapularis or capsulolabral tears, are present. If this is the case, these additional lesions are addressed initially using other arthroscopic portals as needed. The posterior portal is more superior and lateral than the classical soft spot location, allowing a better visualization of the GT and the rotator cuff.³

The displacement of the GT fracture is initially visualized during glenohumeral arthroscopy. Then, the arthroscope is placed in the subacromial space using an anterior and one or two lateral portals. The lateral portals are identified with a spinal needle after thorough lavage of the subacromial space. One of these, the anterolateral portal, is used for subacromial spacer implantation. This portal is located in line with the supraglenoid tubercle, 1.5 to 2 cm laterally to the acromion.

The subacromial spacer surgical technique has been detailed elsewhere¹⁸ and the surgical procedure is performed arthroscopically, but it can also be performed fluoroscopically under local anesthesia.^{12,13} A bursectomy with a radiofrequency device is performed to enable correct visualization of the subacromial structures, and to liberate enough space to insert the balloon implant. Care should be taken not to cut the coracoacromial ligament. The distance from the lateral border of the GT to approximately 1 cm medial to the glenoid apex is then measured, using a surgical measurement probe to determine the required balloon size. If the measured distance falls between two spacer sizes, the larger implant size should be used to prevent device displacement, and to have a better compression on the GT fracture.

In case of GT fracture comminution, or if there is an eggshell fragment, a rigid construct with screws will not be possible and suture anchor fixation with a suture bridge type of repair is

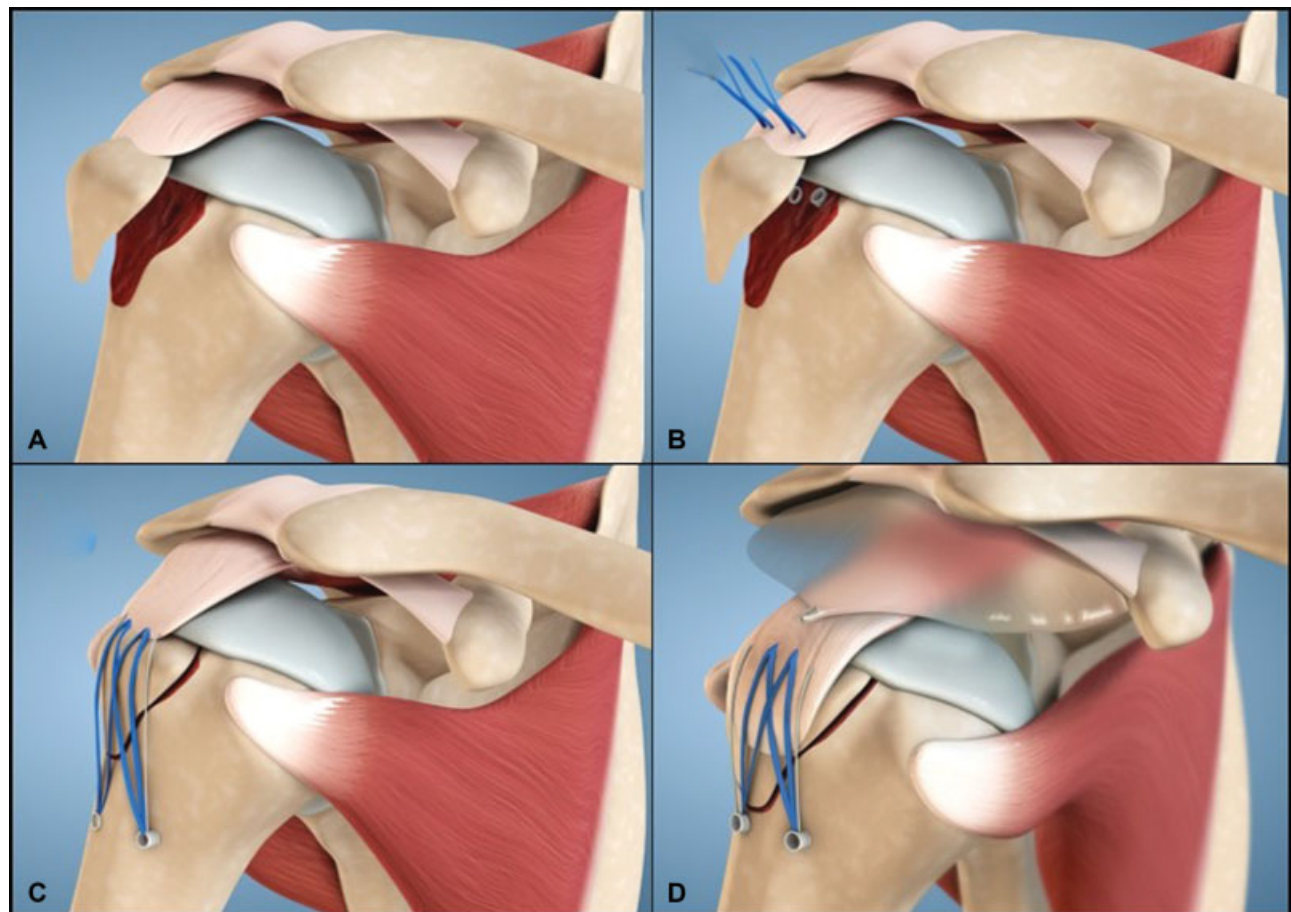


Fig. 1 (A) Greater tuberosity fracture displaced with the rotator cuff attached. (B) Sutures from medial row anchors are placed through the rotator cuff. (C) The fracture is reduced with a double row SpeedBridge-type configuration. (D) The subacromial spacer is placed on top of the construct.

avored. Before reducing the fragments, eventual interposed fibrous tissue is removed using a shaver.

Two proximal suture anchors are introduced in the humeral head just medially to the GT fracture. Anchors with tapes are usually preferred in this setting. The tapes or sutures are then passed as anteriorly as possible through the supraspinatus, and at the junction between the supraspinatus and infraspinatus posteriorly.

The GT fracture is reduced with a blunt trocar using one of the lateral portals. Once the reduction is adequate, a suture bridge type of fixation, using second row anchors, is performed.

The axillary nerve is located at a mean distance of 72 mm (range, 62–85 mm) from the lateral acromion.¹ As no dissection through the deltoid is needed with the arthroscopic technique, the risk of axillary nerve damage is lower,² but caution should be observed during tissue liberation and distal anchor placement due to axillary nerve proximity.⁶

Even in comminuted fractures, the reduction and fixation of the main fragments can be obtained using this technique, because the additional fragments are usually bound together with fibrous tissue. If more parts also need to be fixed, other anchors can be used in the first row.

After fracture fixation, spacer implantation can be performed. The cylinder cannula introducer protecting the

folded balloon will be inserted in the subacromial space until the laser mark is visible. This mark shows where the margin of the balloon is located, and should be flush with the lateral part of the GT. The cannula is removed, and the balloon is inflated using a saline solution to the recommended volume of the selected size (inflation volumes are provided in the device Instruction for Use/Package insert), and then sealed. The inflated balloon has a stabilizing effect on the humeral head like a balanced adjustable ring. Passive shoulder movements are then performed to control the stability of the fracture reduction and to check that the balloon stays in place.

Active rehabilitation of the shoulder is possible the day after the operation, but should be adapted according to operated or nonoperated coexisting lesions.

The intraoperative steps are shown in ►Fig. 1A–D. Preoperative and postoperative X-rays show the initial displacement and the final result (►Fig. 2).

Discussion

Outcomes of surgical treatment of GT fractures are good to excellent in 80 to 100% of the patients.¹ Tension-band fixation seems to produce less favorable results, though

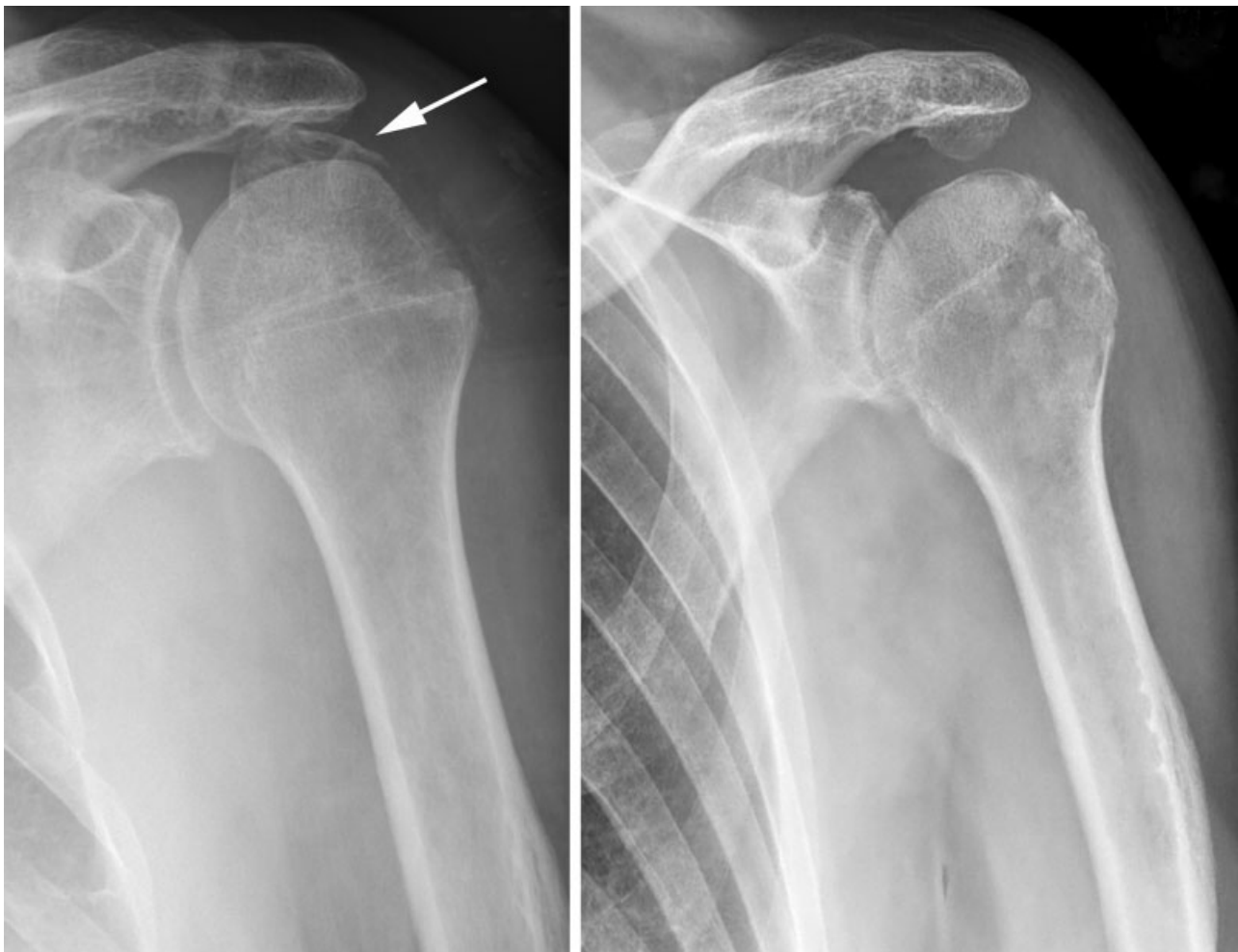

Fig. 2 Preoperative and postoperative X-rays showing the initial displacement and the final result in one case.

statistical significance was not observed in comparison to the other surgical techniques.¹

The extra surgical time related to balloon implantation is very short, varying between 10 to 15 minutes. Nonetheless, the presence of the balloon may alleviate pain, and subsequently reduce opioid demand. The rehabilitation is also faster and active shoulder movements can be encouraged immediately, on the next day following device implantation.

Experienced shoulder surgeons can treat GT fractures arthroscopically, but this can also be done through a mini-open approach to reduce the difficulty or the surgical time. The proposed additional surgical technique using balloon implantation, which can also be done open, is simple to handle, and the learning curve is short.

The cost of the spacer as well as the short additional operative time related to implantation are certainly an issue concerning cost-effectiveness, but this is counterbalanced by a less painful shoulder, a shorter hospital stay, less risk of secondary fracture displacement, and a patient rapidly returning to work.

In conclusion, in the setting of the surgical treatment of a displaced GT fracture, particularly in comminuted or egg-shell fractures, the addition of the balloon-shaped spacer on top of fracture fixation may improve the outcome and also speed up fracture healing because of the obtained compression. The operated patients can also resume their activities of daily living earlier.

This will allow early active shoulder mobilization, as the action of the suture bridge rotator cuff repair construct and the compression with the balloon-shaped implant will function as a “double tension-band,” thus preventing displacement.

Conflict of Interest

Leslie Naggar serves on the Scientific Advisory Board of OrthoSpace.

References

- Rouleau DM, Mutch J, Laflamme GY. Surgical treatment of displaced greater tuberosity fractures of the humerus. *J Am Acad Orthop Surg* 2016;24(01):46–56
- Bonsell S, Buford DA Jr. Arthroscopic reduction and internal fixation of a greater tuberosity fracture of the shoulder: a case report. *J Shoulder Elbow Surg* 2003;12(04):397–400
- Taverna E, Sansone V, Battistella F. Arthroscopic treatment for greater tuberosity fractures: rationale and surgical technique. *Arthroscopy* 2004;20(06):e53–e57
- Cadet ER, Ahmad CS. Arthroscopic reduction and suture anchor fixation for a displaced greater tuberosity fracture: a case report. *J Shoulder Elbow Surg* 2007;16(04):e6–e9
- Ji JH, Jeong JJ, Kim YY, Lee SW, Kim DY, Park SE. Clinical and radiologic outcomes of arthroscopic suture bridge repair for the greater tuberosity fractures of the proximal humerus. *Arch Orthop Trauma Surg* 2017;137(01):9–17
- Ji JH, Shafi M, Song IS, Kim YY, McFarland EG, Moon CY. Arthroscopic fixation technique for comminuted, displaced greater tuberosity fracture. *Arthroscopy* 2010;26(05):600–609
- Song HS, Williams GR Jr. Arthroscopic reduction and fixation with suture-bridge technique for displaced or comminuted greater tuberosity fractures. *Arthroscopy* 2008;24(08):956–960
- Kim SH, Ha KI. Arthroscopic treatment of symptomatic shoulders with minimally displaced greater tuberosity fracture. *Arthroscopy* 2000;16(07):695–700
- Maman E, Dolkart O, Chechik O, et al. Arthroscopic findings of coexisting lesions with greater tuberosity fractures. *Orthopedics* 2014;37(03):e272–e277
- Basat HC, Kirçil C, Armançil M, Demirtş M. Treatment alternative for irreparable rotator cuff ruptures: arthroscopic biodegradable balloon. *Niger J Clin Pract* 2017;20(08):952–957
- Deranlot J, Herisson O, Nourissat G, et al. Arthroscopic subacromial spacer implantation in patients with massive irreparable rotator cuff tears: clinical and radiographic results of 39 retrospectives cases. *Arthroscopy* 2017;33(09):1639–1644
- Gervasi E, Cautero E, Dekel A. Fluoroscopy-guided implantation of subacromial “biodegradable spacer” using local anesthesia in patients with irreparable rotator cuff tear. *Arthrosc Tech* 2014;3(04):e455–e458
- Gervasi E, Maman E, Dekel A, Cautero E. Fluoroscopy-guided biodegradable spacer implantation using local anesthesia: safety and efficacy study in patients with massive rotator cuff tears. *Musculoskelet Surg* 2016;100(Suppl 1):19–24
- Holschen M, Brand F, Agneskirchner JD. Subacromial spacer implantation for massive rotator cuff tears: clinical outcome of arthroscopically treated patients. *Obere Extrem* 2017;12(01):38–45
- Savarese E, Romeo R. New solution for massive, irreparable rotator cuff tears: the subacromial “biodegradable spacer”. *Arthrosc Tech* 2012;1(01):e69–e74
- Senekovic V, Poberaj B, Kovacic L, Mikek M, Adar E, Dekel A. Prospective clinical study of a novel biodegradable sub-acromial spacer in treatment of massive irreparable rotator cuff tears. *Eur J Orthop Surg Traumatol* 2013;23(03):311–316
- Senekovic V, Poberaj B, Kovacic L, et al. The biodegradable spacer as a novel treatment modality for massive rotator cuff tears: a prospective study with 5-year follow-up. *Arch Orthop Trauma Surg* 2017;137(01):95–103
- Szöllösy G, Rosso C, Fogerty S, Petkin K, Lafosse L. Subacromial spacer placement for protection of rotator cuff repair. *Arthrosc Tech* 2014;3(05):e605–e609