

Injury of the lower ascending reticular activating system in patients with pontine hemorrhage

Diffusion tensor imaging study

Sung Ho Jang, MD^a, Sang Seok Yeo, PhD^{b,*}

Abstract

Many studies have reported about injury of the ascending reticular activating system (ARAS) in patients with various brain pathologies, using diffusion tensor tractography (DTT); however, little is known about injury of the ARAS in patients with pontine hemorrhage. In this study, using DTT, we attempted to investigate injury of the lower ventral and dorsal ARAS in patients with pontine hemorrhage. Twenty-three consecutive patients with pontine hemorrhage and 14 control subjects were recruited into this study. The patients were classified into 2 subgroups on the basis of the preservation of arousal: subgroup A (14 patients)—intact arousal, subgroup B (9 patients)—impaired arousal. The lower ventral and dorsal ARAS between the pontine reticular formation with hypothalamus and thalamic intralaminar nucleus were reconstructed. Fractional anisotropy (FA), mean diffusivity (MD), and tract volume (TV) values were measured. The TVs of the lower ventral and dorsal ARAS were significantly lower in subgroup B than in the subgroup A and control group ($P < 0.05$). In terms of FA value, the lower dorsal ARAS were significantly lower in subgroup A and subgroup B than in the control group ($P < 0.05$). In conclusion, injury of the lower ventral and dorsal ARAS was demonstrated in patients with impaired arousal following pontine hemorrhage. We believe that analysis of the ARAS using DTT would be helpful in evaluation of patients with impaired consciousness after pontine hemorrhage.

Abbreviations: ARAS = ascending reticular activating system, DTI = diffusion tensor imaging, DTT = diffusion tensor tractography, FA = fractional anisotropy, GCS = Glasgow Coma Scale, ILN = intralaminar nucleus, MD = mean diffusivity, RF = reticular formation, ROI = regions of interest.

Keywords: ascending reticular activating system, consciousness, diffusion tensor imaging, hemorrhage, pons

1. Introduction

Pontine hemorrhage accounts for approximately 5% to 10% of intracranial hemorrhages.^[1–7] The survival rate of patients with pontine hemorrhage is approximately 40%; because the pons contains many nuclei for cranial nerves and neurotransmitters, and is the passage that provides an area for passage of neural fibers between the cerebral cortex and the spinal cord, patients

who survive commonly have various accompanying neurological sequelae.^[7–12] Impaired consciousness is a major clinical manifestation of pontine hemorrhage, which is ascribed to injury of the ascending reticular activating system (ARAS) in the pons.^[2,3,5,7] However, accurate evaluation of the ARAS in patients with impaired consciousness following pontine hemorrhage is limited.

Recently developed diffusion tensor imaging (DTI) technique enables evaluation of the integrity of white matter tracts by virtue of its ability to image water diffusion characteristics.^[13–15] Diffusion tensor tractography (DTT), which is derived from DTI, has enabled 3-dimensional reconstruction and estimation of the lower ventral ARAS between the pontine reticular formation (RF) and hypothalamus and the lower dorsal ARAS between the RF and thalamic intralaminar nucleus (ILN).^[10,12] As a result, many studies have reported about the injury of the ARAS in patients with various brain pathologies, using DTT.^[16–25] However, little is known about injury of the ARAS in patients with pontine hemorrhage.^[26]

In the current study, using DTT, we attempted to investigate injury of the lower ventral and dorsal ARAS in patients with pontine hemorrhage.

2. Methods

2.1. Subjects

Twenty-three consecutive stroke patients with pontine hemorrhage (21 males, 2 females; mean age 48.6 years; range 31–63 years) and 14 age- and sex-matched normal control subjects (10 males, 4 females; mean age 47.3 years; range

Editor: Eric Bush.

Authorship: SH J conceived and designed the study, and did the funding, data acquisition, manuscript development, and manuscript writing. SS Y did the manuscript development, data acquisition, manuscript writing, and manuscript authorization.

Funding/support: The present research was conducted by the research fund of Dankook University in 2014.

The authors declare that they have no conflict of interest.

^a Department of Physical Medicine and Rehabilitation, College of Medicine, Yeungnam University, Gyeongsangbuk-do, ^b Department of Physical Therapy, College of Health Sciences, Dankook University, Cheonan-si, Chungnam, Republic of Korea.

* Correspondence: Sang Seok Yeo, 119, Dandae-ro, Dongnam-gu, Cheonan-si, Chungnam 330-714, Republic of Korea (e-mail: eangbul@hanmail.net).

Copyright © 2016 the Author(s). Published by Wolters Kluwer Health, Inc. All rights reserved.

This is an open access article distributed under the terms of the Creative Commons Attribution-Non Commercial-No Derivatives License 4.0 (CCBY-NC-ND), where it is permissible to download and share the work provided it is properly cited. The work cannot be changed in any way or used commercially.

Medicine (2016) 95:50(e5527)

Received: 31 March 2016 / Received in final form: 31 October 2016 / Accepted: 10 November 2016

<http://dx.doi.org/10.1097/MD.0000000000005527>

38–64 years) with no history of neurologic or psychiatric disease were recruited into this study. Among consecutive patients with pontine hemorrhage admitted to the department of rehabilitation of a university hospital for rehabilitation, 23 patients were recruited according to the following inclusion criteria: first-ever stroke, age range: 30~65 years, hematoma confined to the pons, and more than 1 month after stroke onset. The patients were classified into the following 2 subgroups on the basis of the preservation of arousal based on the Glasgow Coma Scale (GCS): subgroup A—patients with intact arousal (GCS: 15) and subgroup B—patients with impaired arousal (GCS < 15).^[27,28] All subjects provided signed, informed consent, and the study protocol was approved by the Institutional Review Board of a university hospital and the study was conducted retrospectively.

2.2. Diffusion tensor imaging

Acquisition of DTI data was performed at an average of 2.8 months (range: 1~9 months) after stroke onset using a 6-channel head coil on a 1.5-T Philips Gyroscan Intera (Philips, Best, The Netherlands) and single-shot echo-planar imaging. For each of the 32 noncollinear diffusion sensitizing gradients, 67 contiguous slices were acquired parallel to the anterior commissure-posterior commissure line. Imaging parameters were as follows: acquisition matrix = 96×96 ; reconstructed matrix = 192×192 ; field of view = $240 \times 240 \text{ mm}^2$; repetition time = 10,726 ms; echo time = 76 ms; parallel imaging reduction factor (SENSE factor) = 2; EPI factor = 49; b = 1000 s/mm^2 ; NEX = 1; and a slice thickness of 2.5 mm with no gap (acquired isotropic voxel size $1.3 \times 1.3 \times 2.5 \text{ mm}^3$).

2.3. Probabilistic fiber tracking

Analysis of diffusion-weighted imaging data was performed using software from the Oxford Centre for Functional Magnetic Resonance Imaging of the Brain (FMRIB) Software Library (FSL v5.0; www.fmrib.ox.ac.uk/fsl). Affine multiscale 2-dimensional registration was used for correction of head motion and eddy current-induced image distortion. Fiber tracking was performed using a probabilistic tractography method based on a multifiber model using tractography routines implemented in FMRIB Diffusion (5000 streamline samples, 0.5 mm step lengths, curvature thresholds: 0.2).^[29]

The pathway of the ARAS was determined by selection of fibers passing through seed regions of interest (ROIs) and the target (termination) ROI. For the lower ventral ARAS between RF and hypothalamus, a seed ROI was placed on the RF of the pons, and the target ROI was drawn at the hypothalamus including the mammillary body, which was identified by the optic tract (anterior boundary) and mammillary body (posterior boundary) at the upper midbrain level with a b0 map.^[30] For the lower dorsal ARAS between RF and ILN, a seed ROI was placed on the RF of the pons at the level of the trigeminal nerve entry zone. The target ROI was placed on the ILN at the level of the commissural plane.^[12] In analysis of the connectivity of the ILN of the thalamus, the seed ROI was placed at the ILN at the level of the inter-commissural plane.^[12] Out of 5000 samples generated from the seed voxel, results for contact were visualized at a minimum threshold of 1 streamlined through each voxel for analysis (Fig. 1). The fractional anisotropy (FA), mean diffusivity (MD), and tract volume (TV) values were measured for the lower dorsal and ventral ARAS.

2.4. Statistical analysis

SPSS software (version 20.0; SPSS Inc., Chicago, IL) was used for analysis of data. Kruskal–Wallis with Mann–Whitney post hoc test was used for determination of differences in each DTT parameter between subgroups of patients and the control group. Mann–Whitney test was used for determining the significance of difference in DTI scanning time after stroke between the subgroups of patients. The level of statistical significance was set at $P < 0.05$.

3. Results

A summary of the demographic and clinical characteristics of the patients is summarized in Table 1. Fourteen patients (13 males, 1 female; mean age 49.4 years; range 31–63 years) belonged to subgroup A, and 9 patients belonged to subgroup B (8 males, 1 female; mean age 47.3 years; range 38–59 years). No significant differences in age and the time until DTI scanning after onset were observed between the 2 subgroups (subgroup A: mean 2.29 months, range 1–8 months; subgroup B: mean 2.78 months, range 1–9 months) ($P > 0.05$).

Results of statistical comparison of DTT parameters for the lower ventral ARAS between hypothalamus and ILN in the patient and control groups are summarized in Table 2. The TV of the lower ventral ARAS was significantly lower in subgroup B than in subgroup A and the control group ($P < 0.05$). However, no difference in other DTT parameters was observed between subgroups and the control group ($P > 0.05$) (Fig. 2A).

Results of statistical comparison of DTT parameters for the lower dorsal ARAS between RF and ILN in the patient and control groups are summarized in Table 3. The FA value was significantly lower in subgroup A and subgroup B than in the control group ($P < 0.05$). In addition, the TV was significantly lower in subgroup B than in subgroup A and the control group, respectively ($P < 0.05$), while no difference in the MD value was observed between patient subgroups and the control group ($P > 0.05$). No difference in all DTT parameters was observed between subgroup A and the control group ($P > 0.05$) (Fig. 2B).

4. Discussion

In the current study, using DTT, we evaluated the lower ventral and dorsal ARAS in patients with pontine hemorrhage and obtained the following results: the TV of the lower ventral ARAS was decreased in subgroup B compared with subgroup A and the control group, the FA value of the lower dorsal ARAS was decreased in subgroup A and subgroup B compared with the control group, the TV of the lower dorsal ARAS was decreased in subgroup B compared with subgroup A and the control group. The FA value represents the white matter organization: in detail, the degree of directionality and integrity of white matter microstructures (e.g., axons, myelin, and microtubules), while the MD value indicates the magnitude of water diffusion, which can increase in some forms of pathology, particularly vasogenic edema or accumulation of cellular debris from axonal damage.^[13–15] The TV is determined by counting the number of voxels contained within a neural tract, and thus reflects the total number of fibers in a neural tract.^[31] Therefore, the decrement of the FA value and TV in subgroup B appears to indicate injury of the neural tract.^[13–15,31] In contrast, the decrement of the FA in subgroup A appears to indicate mild injury of lower dorsal ARAS. As a result, patients in subgroup B

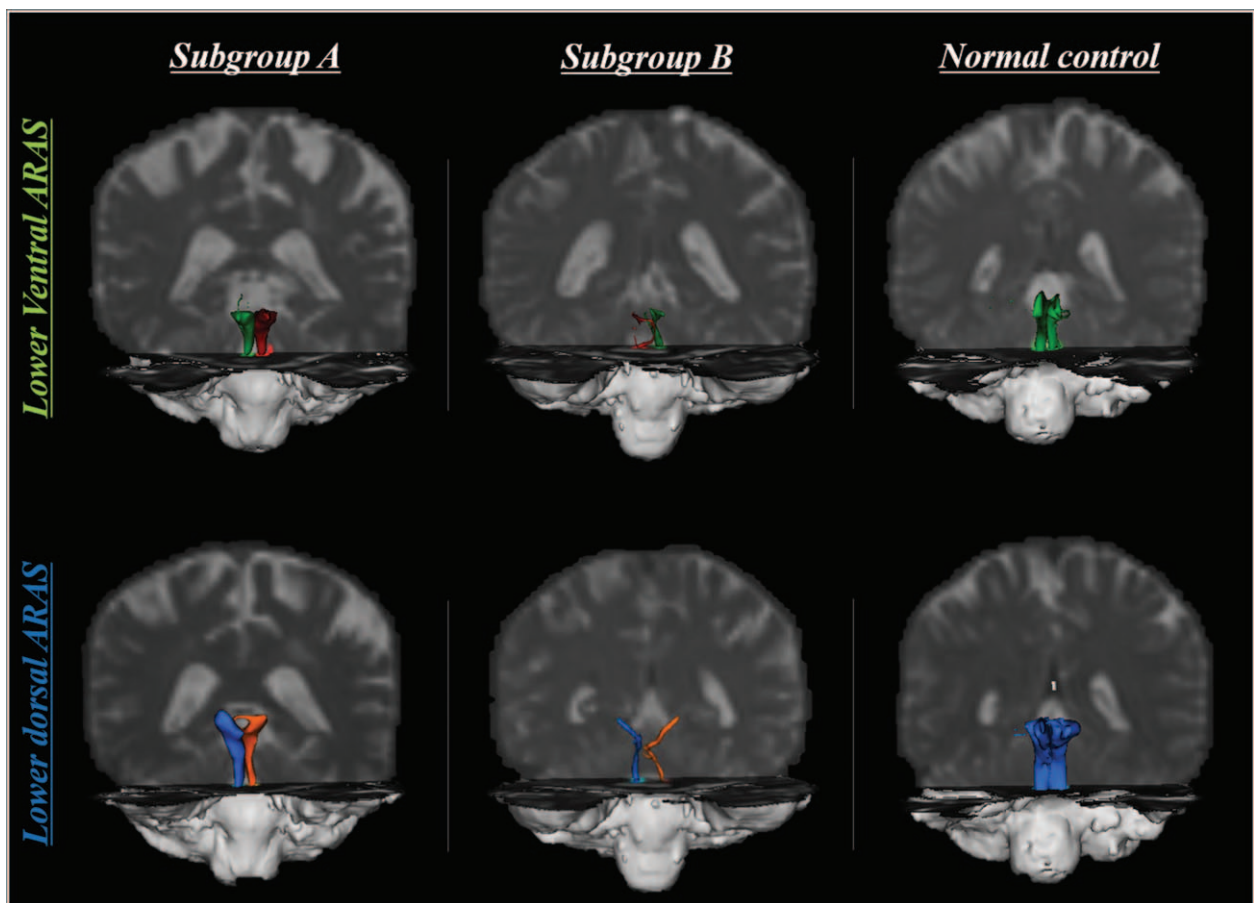


Figure 1. Diffusion tensor tractography of the lower ventral and dorsal ascending reticular activating system (ARAS) in each subgroup of patients and normal control; green color indicates lower ventral ARAS in unaffected side, red color indicates affected side, blue color indicates lower dorsal ARAS in unaffected side, and orange color indicates affected side.

appeared to have had severe injury of the lower ventral and dorsal ARAS than subgroup A. We believe that the DTT findings are compatible with the impaired consciousness of patients in subgroup B.

Since the introduction of DTT for the ARAS, many studies have reported about the lower ventral and dorsal ARAS in patients with various brain pathologies, including traumatic brain injury, hypoxic-ischemic brain injury, and stroke.^[16–26,32–36] Regarding pontine hemorrhage, a case of a patient with hypersomnia who showed injury of the lower ventral and dorsal ARAS following pontine hemorrhage was recently reported.^[26] However, the current study is the first original study to investigate injury of the lower ARAS in a large number of consecutive patients with pontine hemorrhage. Nevertheless, the limitations of this study should be considered. First limitation is

the small number of patients. Second, the time until DTI scanning after onset was relatively variable (1~9 months). Due to this limitation, we could not assess the correlation between the hematoma volume and DTT finding. Second, DTT is a powerful anatomic imaging tool that can demonstrate the gross fiber architecture; however, DTT may underestimate or overestimate the fiber tracts because regions of fiber complexity and crossing can prevent full reflection of the underlying fiber architecture.^[37–39] Therefore, further studies including a larger number of patients and studies to overcome the limitations of DTT should be encouraged.

In conclusion, injury of the lower ventral and dorsal ARAS was demonstrated in patients with impaired arousal following pontine hemorrhage. The results of this study would be helpful to evaluation of patients with impaired consciousness after

Table 1
Demographic data for the patient and control groups.

	Subgroup A	Subgroup B	Control group
Age, y	49.4±10.5	47.3±6.3	47.3±9.1
No. of subjects (male/female)	14 (13/1)	9 (8/1)	14 (10/4)
Duration from onset, mo	2.3±2.1	2.8±3.3	
Glasgow coma scale	15.0	5.2±0.9	

Table 2

Comparisons of diffusion tensor image parameters of the lower ventral of the ascending reticular activating system between the subgroups of patients and the control group.

	FA (scalar value)	MD ($\lambda_1 + \lambda_2 + \lambda_3/3$)	TV (number of voxel)
Subgroup A (n=14)	0.36±0.06	1.06±0.15	358.57±296.40
Subgroup B (n=9)	0.35±0.06	1.13±0.36	136.18±82.96
Control (n=14)	0.38±0.04	1.06±0.15	429.71±145.29
Subgroup A vs B	0.612	0.701	0.022*
Subgroup A vs Control	0.123	0.774	0.058
Subgroup B vs Control	0.116	0.914	0.000*

Values represent mean ± standard deviation.

Kruskal–Wallis with Mann–Whitney post hoc test was used for comparison of diffusion tensor parameters between patient groups and normal control.

FA=fractional anisotropy, MD=mean diffusivity, TV=tract volume.

* $P < 0.05$.

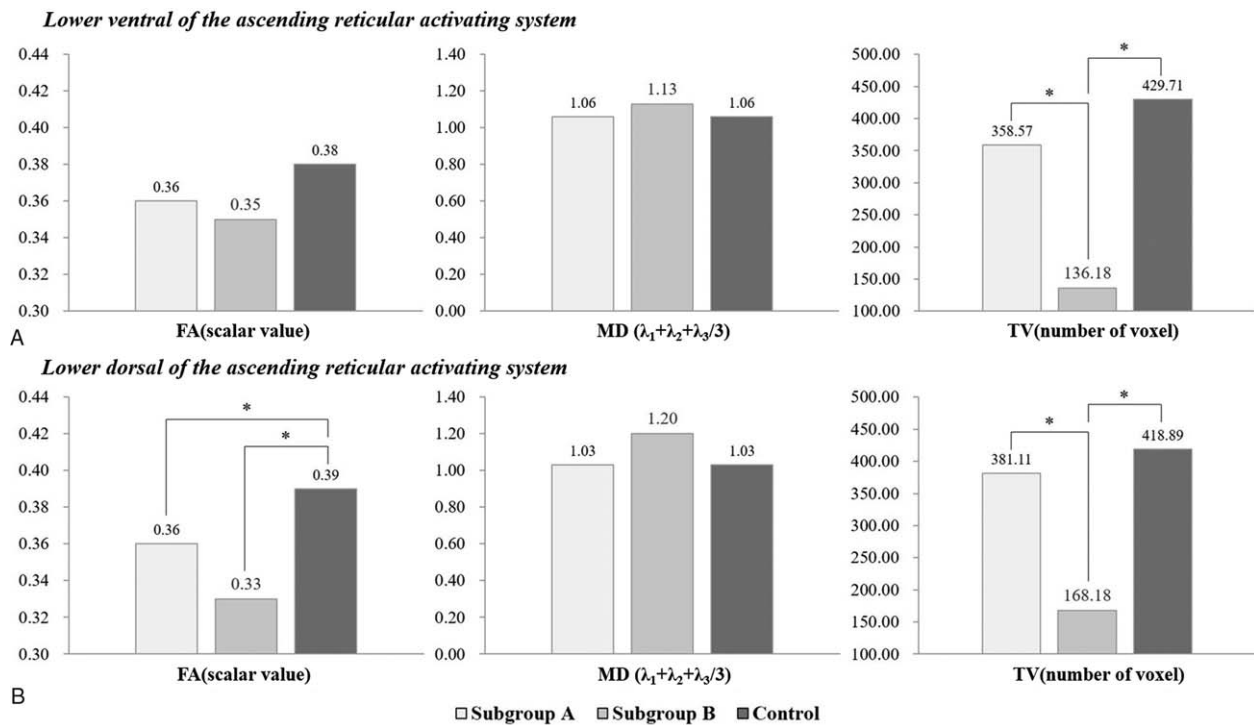


Figure 2. Comparisons of diffusion tensor image parameters of the lower ventral and dorsal of the ascending reticular activating system between the subgroups of patients and the control group. FA=fractional anisotropy, MD=mean diffusivity, TV=tract volume. * $P < 0.05$.

Table 3

Comparisons of diffusion tensor image parameters of the lower dorsal of the ascending reticular activating system between the subgroups of patients and the control group.

	FA (scalar value)	MD ($\lambda_1 + \lambda_2 + \lambda_3/3$)	TV (number of voxel)
Subgroup A (n=14)	0.36±0.05	1.03±0.20	381.11±180.95
Subgroup B (n=9)	0.33±0.08	1.20±0.51	168.18±141.84
Control (n=14)	0.39±0.05	1.03±0.38	418.89±144.53
Subgroup A vs B	0.167	0.648	0.000*
Subgroup A vs Control	0.009*	0.059	0.476
Subgroup B vs Control	0.004*	0.167	0.000*

Values represent mean ± standard deviation.

Kruskal–Wallis with Mann–Whitney post hoc test was used for comparison of diffusion tensor parameters between patient groups and normal control.

FA=fractional anisotropy, MD=mean diffusivity, TV=tract volume.

* $P < 0.05$.

pontine hemorrhage. In particular, we think that accurate assessment of the ARAS using DTT would be helpful for prediction of prognosis for impaired consciousness and planning of rehabilitation strategies for patients with pontine hemorrhage.^[20,40]

References

- [1] Goto N, Kaneko M, Hosaka Y, et al. Primary pontine hemorrhage: clinicopathological correlations. *Stroke* 1980;11:84–90.
- [2] Kushner MJ, Bressman SB. The clinical manifestations of pontine hemorrhage. *Neurology* 1985;35:637–43.
- [3] Masiyama S, Niizuma H, Suzuki J. Pontine haemorrhage: a clinical analysis of 26 cases. *J Neurol Neurosurg Psychiatry* 1985;48:658–62.
- [4] Wijidicks EF, St Louis E. Clinical profiles predictive of outcome in pontine hemorrhage. *Neurology* 1997;49:1342–6.
- [5] Parvizi J, Damasio AR. Neuroanatomical correlates of brainstem coma. *Brain* 2003;126:1524–36.
- [6] Wessels T, Moller-Hartmann W, Noth J, et al. CT findings and clinical features as markers for patient outcome in primary pontine hemorrhage. *AJNR Am J Neuroradiol* 2004;25:257–60.
- [7] Caplan LR, van Gijn J. *Stroke Syndrome*. 3rd ed. New York: Cambridge University Press; 2012.
- [8] Daube JR. *Medical Neurosciences: an Approach to Anatomy, Pathology, and Physiology by Systems and Levels*. 2nd ed. Boston, MA: Little, Brown and Co; 1986.
- [9] Afifi AKBR. *Functional Neuroanatomy: Text and Atlas*. 2nd ed. New York: Lange Medical Books/McGraw-Hill; 2005.
- [10] Edlow BL, Takahashi E, Wu O, et al. Neuroanatomic connectivity of the human ascending arousal system critical to consciousness and its disorders. *J Neuropathol Exp Neurol* 2012;71:531–46.
- [11] Jang SH, Kwon HG. Diffusion tensor tractography for the dorsal spinocerebellar tract in the human brain. *Somatosens Mot Res* 2014;31:7–10.
- [12] Yeo SS, Chang PH, Jang SH. The ascending reticular activating system from pontine reticular formation to the thalamus in the human brain. *Front Hum Neurosci* 2013;7:416.
- [13] Mori S, Crain BJ, Chacko VP, et al. Three-dimensional tracking of axonal projections in the brain by magnetic resonance imaging. *Ann Neurol* 1999;45:265–9.
- [14] Assaf Y, Pasternak O. Diffusion tensor imaging (DTI)-based white matter mapping in brain research: a review. *J Mol Neurosci* 2008;34:51–61.
- [15] Neil JJ. Diffusion imaging concepts for clinicians. *J Magn Reson Imaging* 2008;27:1–7.
- [16] Jang SH, Kim SH, Lim HW, et al. Recovery of injured lower portion of the ascending reticular activating system in a patient with traumatic brain injury. *Am J Phys Med Rehabil* 2015;94:250–3.
- [17] Edlow BL, Haynes RL, Takahashi E, et al. Disconnection of the ascending arousal system in traumatic coma. *J Neuropathol Exp Neurol* 2013;72:505–23.
- [18] Jang SH, Lee HD. Ascending reticular activating system recovery in a patient with brain injury. *Neurology* 2015;84:1997–9.
- [19] Jang SH, Lim HW, Yeo SS. Injury of the ascending reticular activating system by transtentorial herniation in a patient with intracerebral haemorrhage: a diffusion tensor tractography study. *J Neurol Neurosurg Psychiatry* 2015;86:1164–6.
- [20] Jang SH, Kim HS. Aneurysmal subarachnoid hemorrhage causes injury of the ascending reticular activating system: relation to consciousness. *AJNR Am J Neuroradiol* 2015;36:667–71.
- [21] Jang SH, Kwon HG. Injury of the ascending reticular activating system in patients with fatigue and hypersomnia following mild traumatic brain injury: two case reports. *Medicine* 2016;95:e2628.
- [22] Jang SH, Lee HD, Chang CH, et al. Recovery of hypersomnia concurrent with recovery of an injured ascending reticular activating system in a stroke patient: a case report. *Medicine* 2016;95:e2484.
- [23] Jang SH, Seo YS. Ascending reticular activating system in a patient with persistent vegetative state. *Am J Phys Med Rehabil* 2016;95:e46–7.
- [24] Jang SH, Lee HD. The ascending reticular activating system in a patient with severe injury of the cerebral cortex: a case report. *Medicine* 2015;94:e1838.
- [25] Jang SH, Lee J, Seo YS. Injury of the lower ascending reticular activating system in a patient with cerebral infarct. *Int J Stroke* 2015;10:E72–3.
- [26] Jang SH, Chang CH, Jung YJ, et al. Post-stroke hypersomnia. *Int J Stroke* 2016;11:N5–6.
- [27] Teasdale G, Jennett B. Assessment of coma and impaired consciousness. A practical scale. *Lancet* 1974;2:81–4.
- [28] Cavanna AE, Shah S, Eddy CM, et al. Consciousness: a neurological perspective. *Behav Neurol* 2011;24:107–16.
- [29] Smith SM, Jenkinson M, Woolrich MW, et al. Advances in functional and structural MR image analysis and implementation as FSL. *Neuroimage* 2004;23(suppl 1):S208–19.
- [30] Jang SH, Kwon HG. The ascending reticular activating system from pontine reticular formation to the hypothalamus in the human brain: a diffusion tensor imaging study. *Neurosci Lett* 2015;590:58–61.
- [31] Jang SH, Chang CH, Lee J, et al. Functional role of the corticoreticular pathway in chronic stroke patients. *Stroke* 2013;44:1099–104.
- [32] Jang SH, Yeo SS. Injury of the lower portion of the ascending reticular activating system in a patient with intraventricular hemorrhage. *Int J Stroke* 2015;10(suppl A100):162–3.
- [33] Jang SH, Seo YS. Injury of the contralateral lower ascending reticular activating system by an intracerebral hemorrhage. *AJNR Am J Neuroradiol* 2015;36:E58–9.
- [34] Jang SH, Kim SH, Lim HW, et al. Injury of the lower ascending reticular activating system in patients with hypoxic-ischemic brain injury: diffusion tensor imaging study. *Neuroradiology* 2014;56:965–70.
- [35] Jang S, Kim S, Lee H. Recovery from vegetative state to minimally conscious state: a case report. *Am J Phys Med Rehabil* 2016;95:e63–6.
- [36] Jang SH, Seo WS, Kwon HG. Post-traumatic narcolepsy and injury of the ascending reticular activating system. *Sleep Med* 2016;17:124–5.
- [37] Lee SK, Kim DI, Kim J, et al. Diffusion-tensor MR imaging and fiber tractography: a new method of describing aberrant fiber connections in developmental CNS anomalies. *Radiographics* 2005;25:53–65. discussion 6–8.
- [38] Parker GJ, Alexander DC. Probabilistic anatomical connectivity derived from the microscopic persistent angular structure of cerebral tissue. *Philos Trans R Soc Lond B Biol Sci* 2005;360:893–902.
- [39] Yamada K, Sakai K, Akazawa K, et al. MR tractography: a review of its clinical applications. *Magn Reson Med Sci* 2009;8:165–74.
- [40] Georgiopoulos M, Katsakiori P, Kefalopoulou Z, et al. Vegetative state and minimally conscious state: a review of the therapeutic interventions. *Stereotact Funct Neurosurg* 2010;88:199–207.