



A case of acute-colonic pseudo-obstruction (Ogilvie Syndrome) post robot-assisted radical prostatectomy

Mahima Tellambura^{a,b,*}, Marcus Cumberbatch^{b,c}, Jeremy Goad^b

^a Department of Surgery, St. Vincent's Hospital Melbourne, Fitzroy, VIC, Australia

^b Division of Cancer Surgery, Peter MacCallum Cancer Centre, Melbourne, VIC, Australia

^c Department of Oncology and Metabolism, The Medical School, University of Sheffield, Sheffield, UK

ARTICLE INFO

Keywords:

Ogilvie Syndrome
Acute colonic pseudo-obstruction
Prostatectomy
Robot-assisted
Radical prostatectomy

ABSTRACT

Acute Colonic Pseudo-obstruction (ACPO), or Ogilvie Syndrome, is a rare phenomenon where acute colonic distension occurs, in the absence of mechanical obstruction. Several post-operative cases of Ogilvie Syndrome are noted within the literature, pertaining to patients post hepatectomy, trauma or spinal surgery; but rarely following urological procedures. This case describes a 68-year-old gentleman who developed Ogilvie Syndrome post an uncomplicated robot-assisted radical prostatectomy (RARP). While bowel injury is an acknowledged rare complication following prostatectomy, patients with Ogilvie Syndrome may present in a similar manner, and an atypical case of colonic obstruction should raise suspicion of this as a cause.

1. Introduction

Ogilvie Syndrome, first coined by William Ogilvie FRCS in 1948, refers to significant colonic dilation without anatomical evidence of obstruction. Evidence has not yet revealed a single conclusive factor, instead attributing precipitants such as systemic illness, operative insult, and medications as contributing to dysfunction of the enteric nervous system, with concurrent autonomic imbalance (increased sympathetic activation, and impaired parasympathetic effect).

2. Case presentation

A 68-year-old patient was referred to a specialist oncological hospital with prostate cancer for consideration of prostatectomy. Pre-operative investigation yielded localised Gleason Grade Group 2 disease (Gleason 3 + 4 = 7), with an initial PSA of 9.2 and no evidence of lymphatic spread.

His medical history was significant for ischemic heart disease, hypertension, and well-controlled Type 2 diabetes. Medications included aspirin, irbesartan, metformin, metoprolol, and pravastatin. There was no pertinent gastrointestinal history, including of dysmotility.

The patient underwent a Robot-Assisted Radical Prostatectomy (RARP). The procedure was straightforward and utilised a six-port approach – with an open Hassan entry and five instrument ports

inserted under vision. Bilateral nerve sparing was achieved, and operating time was 3.5 hours. He was admitted overnight, and discharged day 1 post-operatively with aperients and a small quantity of oxycodone PRN, with a plan for a trial of void within two weeks.

Day 4 post-operatively, he re-presented with worsening nausea, abdominal pain, and haematuria. An absence of bowel movements was noted, despite having been discharged with regular aperients.

On examination, the abdomen was distended and hyper-tympanic, despite resolving pain. Investigations at the time yielded an elevated white cell count, and an X-Ray/CT of the abdomen yielded a dilated caecum (>11cm), with total collapse of the descending colon and rectum, but no transition point (Fig. 1).

Conservative management was commenced for a presumed bowel obstruction with bowel rest. Nasogastric drainage yielded dark bilious output. A CT with rectal contrast (Fig. 2) did not suggest any rectal or large bowel injury.

Colonoscopy was undertaken on D2 post re-admission, which yielded sloughy, hyperaemic mucosa in the ascending colon, but no site of anatomical obstruction.

Repeat CT imaging (Fig. 3) showed resolving colonic dilation, without obstruction, suggestive of acute colonic pseudo-obstruction. Regular aperients were prescribed, including sodium picosulfate to good effect. Metoclopramide was provided regularly for nausea and prokinetic effect. Given gradual clinical improvement, a trial of neostigmine

* Corresponding author. Department of Surgery, St. Vincent's Hospital Melbourne, 41 Victoria Parade, Fitzroy, VIC, 3065, Australia.

E-mail addresses: mahima.tellambura@svha.org.au (M. Tellambura), m.g.cumberbatch@sheffield.ac.uk (M. Cumberbatch), jeremy.goad@petermac.org (J. Goad).

was not required. Near-normal oral intake was established D7-8 of re-admission, and the patient was discharged home, D12 post re-admission.

On follow-up, the histology yielded acinar adenocarcinoma with a 2.6 cc tumour and uninvolved margins/no extra-prostatic extension (pT2). There were no ongoing issues with bowel motility.

3. Discussion

Ogilvie Syndrome/acute colonic pseudo-obstruction (ACPO) is a rare, poorly understood phenomenon of colonic dysmotility, leading to obstructive symptoms without an anatomical lesion. Initial theories suggested disruption of normal colonic transit, due to autonomic dysfunction. Although specific precipitants have not been fully elucidated, patients range from those undergoing major surgical procedures, to the critically unwell. Other theories include neuropraxia from retroperitoneal complications such as haemorrhage, or secondary to pneumoperitoneum. Key complications include perforation, which may necessitate resection and defunctioning. In critically unwell patients this may contribute significantly to morbidity/mortality – with literature suggesting up to 40–50% mortality in perforated pseudo-obstruction.¹

Management is largely supportive, aimed at preventing colonic perforation. Studies have purported a benefit in neostigmine, which through inhibition of acetylcholinesterase, potentiates nicotinic and muscarinic stimulation, encouraging colonic motility. In a double-blinded randomized controlled trial by Ponc et al.,² (treatment group - 2.0mg neostigmine bolus; control group – saline), the benefit shown was stark. 10/11 patients in the intervention group resolved, compared to 0/10 in the placebo group ($p < 0.001$). Furthermore, at the conclusion of the trial, all participants in the placebo group were given ‘open-label’ neostigmine, which resolved pseudo-obstruction in a further 7 participants in the control group, and in the non-responder within the treatment group. A second similar study by Van der Spoel et al.³ highlighted the benefits of neostigmine in a group of 24 intensive care patients with ACPO– 11/13 patients given neostigmine resolved, compared with 0/11 in the placebo group ($p < 0.001$).

The role of colonic decompression through endoscopy has been well-established and adopted into practice. Initially, a retrospective cohort study by Tsirlin et al.⁴ noted that endoscopic decompression was twice as successful at resolving pseudo-obstruction as neostigmine. Since then, endoscopic decompression has been adopted as a middle ground between conservative management and surgical intervention.

Furthermore, this precedent is supported in a retrospective study by Peker et al.⁵ who noted that, in a group of 68 patients, those undergoing

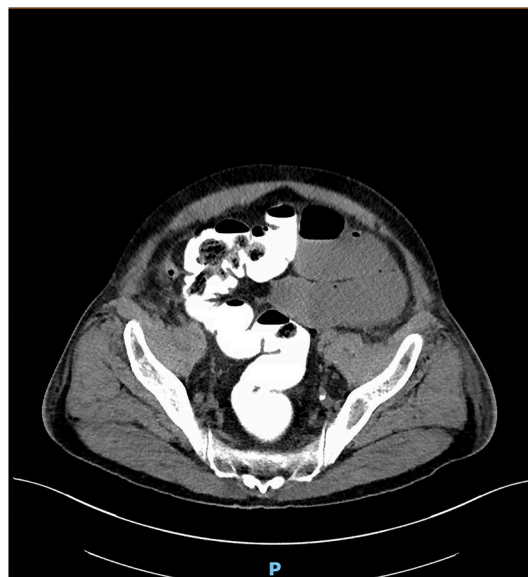

Fig. 2. CT-Abdomen with rectal contrast.

endoscopic decompression had a higher rate of response to first treatment (83.8%) compared to neostigmine treatment initially (48.4%).

Specific concerns in this case include the potential for misdiagnosis of pseudo-obstruction with mechanical bowel obstruction, or iatrogenic bowel injury. Features such as the elevated white cell count (with predominant neutrophilia) could obfuscate the diagnosis and pre-empt emergent operative management. Imaging may not be definitive in distinguishing between mechanical and pseudo-obstruction particularly in the immediate post-operative period.

The clinical examination (a lack of peritonism, and clinical stability), was more suggestive of a pseudo-obstruction than mechanical obstruction in this case. However, ACPO should be considered a differential diagnosis in patients presenting with abdominal discomfort and distension in the post-prostatectomy setting. As pharmacological and endoscopic approaches are available for management, care should be taken to distinguish it from mechanical obstruction or iatrogenic bowel injury, which may warrant prompt operative intervention.

Given the failure of conservative management, and the implications of re-operation in this case (owing to recent prostatectomy), the benefit of endoscopic intervention is apparent. The patient's history of ischemic

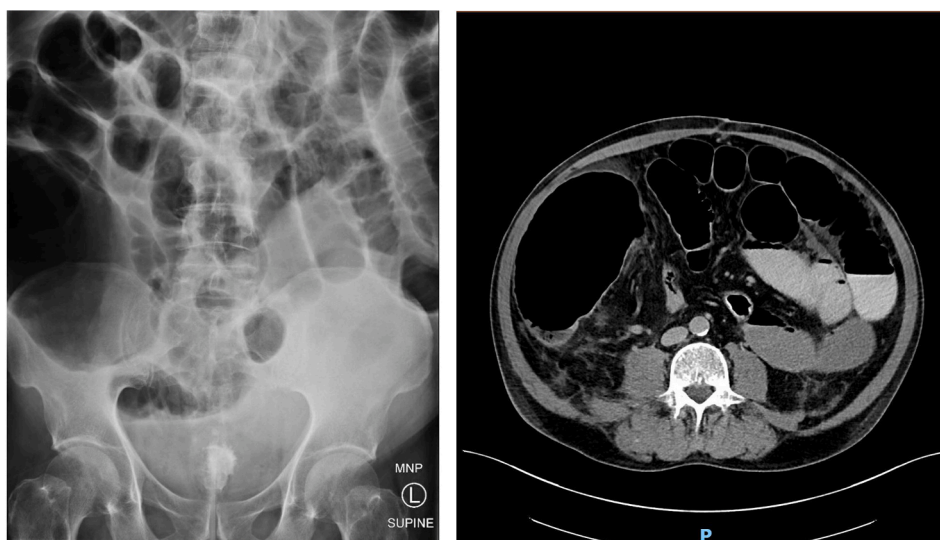


Fig. 1. Abdominal X-Ray/CT on admission highlighting gross distension of the caecum.

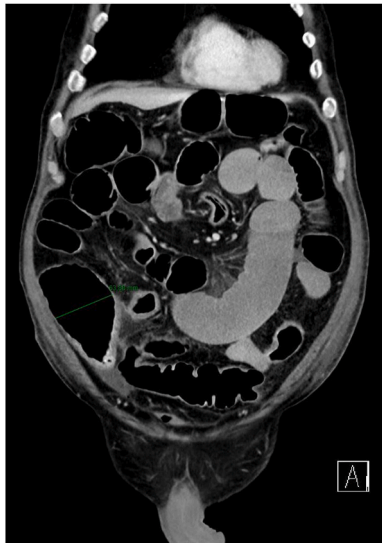

Fig. 3. Repeat CT on Day 4 of admission, highlighting ongoing resolution of pseudo-obstruction. Complete clinical resolution would require a further three days.

heart disease - a risk factor for neostigmine-related bradycardia, further preferences endoscopic decompression to acetylcholinesterase inhibitor

therapy.

4. Conclusion

In patients presenting with atypical obstructive symptoms post urological surgery, a diagnosis of pseudo-obstruction should be considered as a cause.

While the mechanism of pseudo-obstruction remains unclear, the paradigm of care is now reasonably established. Provision of bowel rest remains the mainstay, while endoscopic decompression is suggested as superior to alternatives such as neostigmine. However, moderate-quality evidence reveals that neostigmine (as a procholineric) may play a role in management of ACPO.

References

1. Vanek VW, Al-Salti M. Acute pseudo-obstruction of the colon (Ogilvie's syndrome). An analysis of 400 cases. *Dis Colon Rectum*. 1986;29(3):203–210.
2. Ponc R, Saunders MD, Kimmey MB. Neostigmine for the treatment of acute colonic pseudo-obstruction. *N Engl J Med*. 1999;341(3):137–141.
3. Van der Spoel J, Oudemans-van Straaten H, Stoutenbeek C, Bosman R, Zandstra D. Neostigmine resolves critical illness-related colonic ileus in intensive care patients with multiple organ failure—a prospective, double-blind, placebo-controlled trial. *Intensive Care Med*. 2001;27(5):822–827.
4. Tsirlina VB, Zemlyak AY, Avery MJ, et al. Colonoscopy is superior to neostigmine in the treatment of Ogilvie's syndrome. *Am J Surg*. 2012;204(6):849–855.
5. Peker KD, Cıkt M, Bozkurt MA, et al. Colonoscopic decompression should be used before neostigmine in the treatment of Ogilvie's syndrome. *Eur J Trauma Emerg Surg*. 2017;43(4):557–566.