

CASE REPORT

Successful intracoronary thrombolysis in a patient with anterior myocardial infarction and large thrombus burden associated with coronary artery ectasia

Iraj Jafaripour¹  | Mohammad Mostafa Ansari Ramandi²  | Amir Gholami³ |
Roghayeh Pourkia¹ | Kamyar Amin¹ 

¹Department of Cardiology, School of Medicine, Babol University of Medical Sciences, Babol, Iran

²Cardiovascular Diseases Research Center, Birjand University of Medical Sciences, Birjand, Iran

³Department of Nuclear Medicine, Shahid Beheshti Hospital, Babol University of Medical Sciences, Babol, Iran

Correspondence

Kamyar Amin, Department of Cardiology, School of Medicine, Babol University of Medical Sciences, Babol, Iran.

Email: kamyaramin@gmail.com

Abstract

Although ectatic coronary arteries with high thrombus burden, leading to acute coronary events, can be difficult to manage, intracoronary thrombolytics and glycoprotein IIb/IIIa inhibitors can act as potential successful treatment options.

KEYWORDS

acute medicine, cardiovascular disorders

1 | INTRODUCTION

ST-elevation myocardial infarction (STEMI) is a serious and life-threatening event often caused by atherosclerotic plaque injury and thrombus formation in the coronary lumen. The standard treatment for STEMI is reperfusion with angioplasty; however, in some cases, there are concerns about successful angioplasty and stenting due to the large volume of thrombus, such as thrombotic occlusion of an ectatic coronary artery. In these cases, treatment strategies may be different.^{1,2} We report a case of successful coronary reperfusion through a catheter-directed intracoronary (IC) thrombolysis in acute STEMI caused by thrombotic occlusion of an ectatic coronary artery.

2 | CASE REPORT

A 38-year-old female patient was presented with persistent retrosternal chest pain, having started 4 hours prior to

admission. The patient had no coronary risk factor. The pain increased with exertion and did not radiate to any area. Blood pressure of 125/75 mm Hg and heart rate of 78 beats/minute were recorded at the time of admission.

3 | DIFFERENTIAL DIAGNOSIS, INVESTIGATIONS, AND TREATMENT

Considering the symptoms, there was suspicion for acute coronary syndrome. The electrocardiography (ECG) showed ST segment elevation in V1 to V4 precordial leads, with Q wave formation (Figure 1). Troponin I level was 2.33 mcg/L (normal value: <0.03 mcg/L), and other laboratory data were unremarkable. At presentation, Killip class III was recorded.

Aspirin 325 mg (chewable), clopidogrel 600 mg and 80 mg atorvastatin were administered and coronary angiography

This is an open access article under the terms of the Creative Commons Attribution-NonCommercial License, which permits use, distribution and reproduction in any medium, provided the original work is properly cited and is not used for commercial purposes.

© 2020 The Authors. *Clinical Case Reports* published by John Wiley & Sons Ltd.

via the right femoral artery was performed for primary angioplasty, which showed complete thrombotic occlusion of the left anterior descending (LAD) artery from its ostium. The right coronary artery and left circumflex were normal (Supporting information S1).

Unfractionated Heparin with a dose of 100 units/kilogram (kg) was administered intravenously (IV). A Judkins left 3.5, 6-Fr guiding catheter was used to engage the left main ostium and after wiring with BMW 0.014-in. guidewires (Abbott Vascular), angioplasty with 2×15 Mozec Rx PTCA balloon dilation catheter was carried out. Subsequent brief blood flow was established in the LAD artery, and a large volume of thrombus that extended from the ostium to the mid-part of the LAD and the proximal portion of the diagonal artery was observed (Figure 2).

180 mcg/kg of Eptifibatide was injected intravenously and thrombus aspiration with Medtronic export advanced

aspiration catheter was done several times, resulting in partial improvement in LAD artery blood flow, but the thrombolysis in myocardial infarction (TIMI) Flow remained below 2 (Supporting information S2) and the patient continued to complain of chest pain. The second dose of Eptifibatide was also administered, and given the high volume of thrombus residue despite multiple thrombo-aspirations, and due to the diffuse involvement of the LAD and the relatively large diagonal artery, conditions were not suitable for stent placement. Thus, we decided to try IC thrombolysis.

Given that the only available thrombolytic agent was Reteplase, and according to previous studies, using a low dose of this agent,³ 5 units (9 mg) of this drug were diluted with 10 mL of normal saline and injected via a thrombo-aspiration catheter, placed into the proximal portion of the LAD artery, at the rate of 2 units/minute (Supporting information

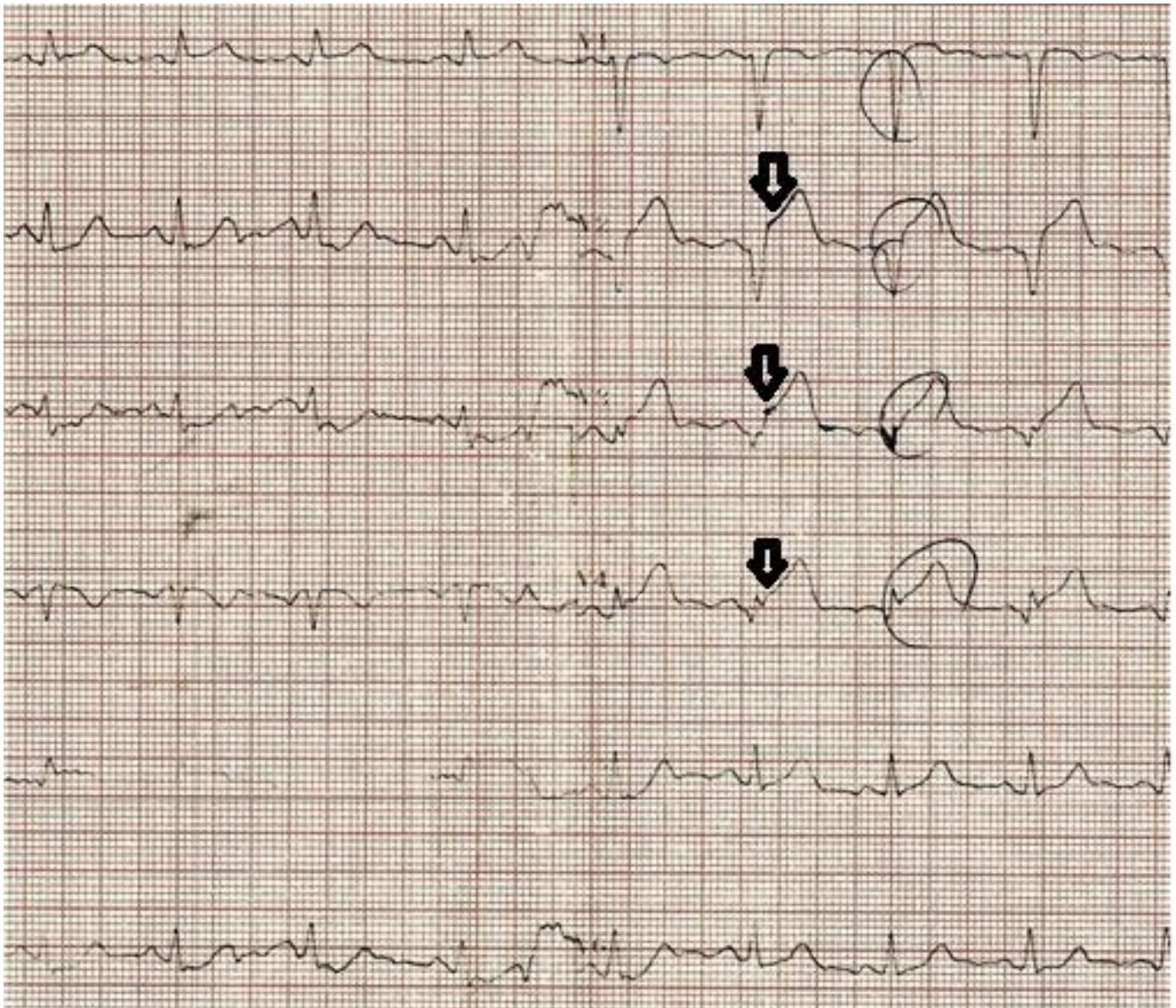


FIGURE 1 Electrocardiography at presentation showing ST segment elevation in V1-V4 (black arrows)

S3). During the injection, the patient suffered severe retrosternal burning pain, which decreased with the reduction of the rate of injection.

Control angiography was performed 15 minutes after the completion of the IC injection of Reteplase, which showed a significant reduction in luminal thrombus burden and TIMI 3 flow of LAD artery with the patient's chest pain completely relieved and partial resolution of ECG changes (Figure 3 and supporting information S4).

However, the thrombus was still present in the proximal and mid-part of the LAD artery, which did not resolve with rethromboaspiration. Coronary ectasia was also noted at proximal to mid-portion of LAD, at which time, we stopped the procedure and the patient was transferred to the coronary care unit.

Medications administered were as follows: Aspirin 80 mg once daily, Clopidogrel 75 mg once daily, Eptifibatide 2 mcg/

kg IV infusion for 72 hours, Atorvastatin 40 mg once daily, Captopril 25 mg twice daily, Carvedilol 6.25 mg twice daily, Spironolactone 25 mg once daily, and Enoxaparin 60 mg twice daily for 1 week. Echocardiography showed anterior wall akinesia and hypokinesia in the apical segments without the involvement of other segments. The right ventricle size and function were normal. Left ventricular ejection fraction was about 35% with no valvular lesion. The pulmonary artery pressure was within normal limits.

4 | OUTCOME AND FOLLOW-UP

During the hospital stay, the patient was completely asymptomatic and had no bleeding. Follow-up angiography was performed 1 week later, which showed complete resolution

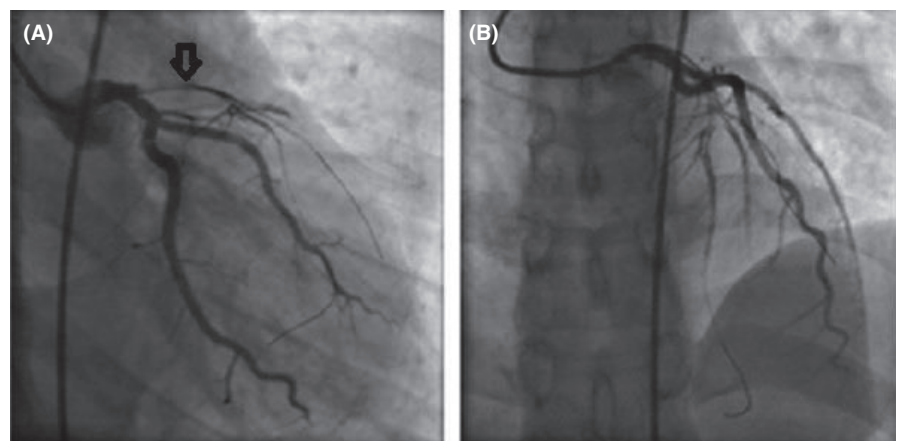


FIGURE 2 A, Caudal 25—right-anterior-oblique 22 projection showing left anterior descending artery (LAD) wiring with high thrombus burden (black arrow). B, Cranial 27—right-anterior-oblique 3 projection showing brief LAD flow

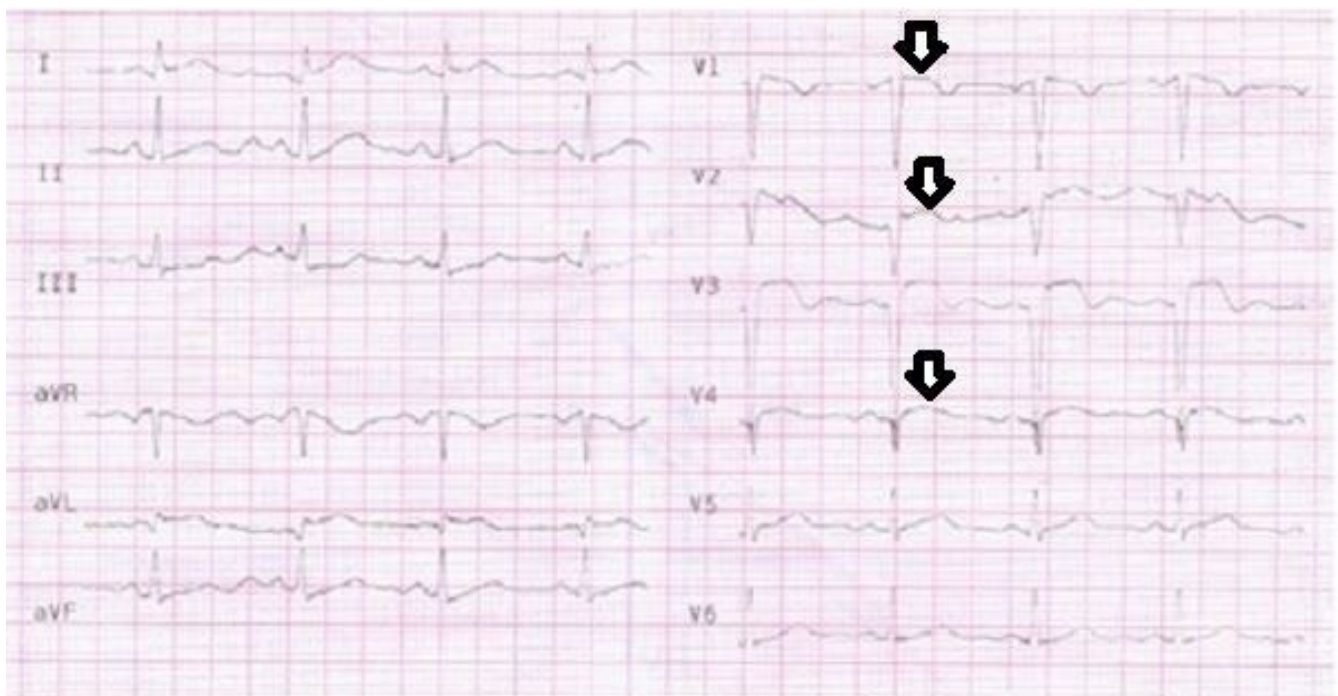


FIGURE 3 Electrocardiography showing resolution of ST segment elevation in precordial leads (black arrows)

of the intra-arterial thrombus and the LAD artery flow was normal, with no obstructive lesions, but the proximal to mid-portion of the LAD was ectatic (Figure 4 and supporting information S5).

The patient was discharged the next day and Aspirin 80 mg once daily, Clopidogrel 75 mg once daily, Atorvastatin 40 mg once daily, Bisoprolol 2.5 mg once daily, and Captopril 12.5 mg three times daily were prescribed. Two weeks after discharge, the patient's coagulation profile was examined, which showed no coagulation disorder.

Follow-up echocardiography at 1 month showed a relative improvement in cardiac systolic function with LVEF of approximately 40%. During the 1-year follow-up, the patient was completely symptom-free.

Due to atypical chest pain at about 1 year after myocardial infarction, coronary CT angiography was performed, which did not show obstructive lesion and coronary calcification (Figure 5).

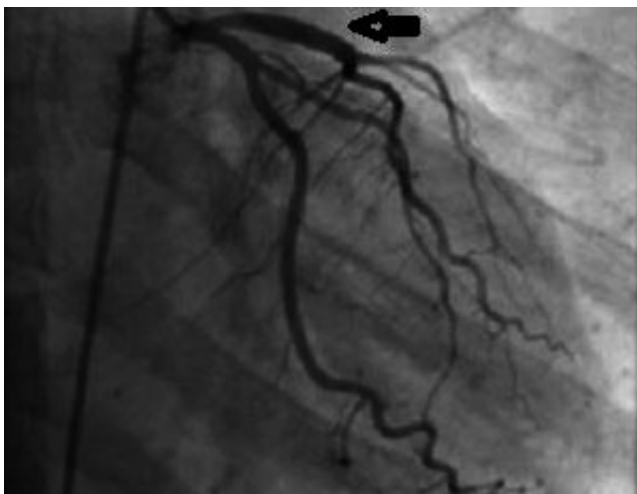

FIGURE 4 Caudal 20—right-anterior-oblique 19 projection showing ectasia in proximal to mid-part of the Left anterior descending artery (black arrow)

5 | DISCUSSION

Our patient developed coronary artery occlusion with a high volume of thrombus in the LAD artery with coronary ectasia. In such patients, who have a high thrombus burden, treatment modalities such as thrombo-aspiration and long-term heparin administration after thrombus aspiration have been used.^{3,4}

Given the high volume of thrombus and coronary ectasia, we used a combination of thrombo-aspiration and intracoronary thrombolysis, and continued heparin administration plus glycoprotein IIb/IIIa with a decent final result and no complication.

We also used two full doses of Eptifibatid intravenously, 10 minutes apart during the procedure and continued intravenous infusion for the next 72 hours, which could potentially increase the risk of bleeding, but our patient had no bleeding during hospitalization.

Although the standard treatment for myocardial infarction is angioplasty with stenting, in special cases such as extensive intracoronary thrombus, this procedure may not be feasible and may lead to unsuccessful angioplasty and adverse clinical outcomes.² Extensive intracoronary thrombosis can cause distal embolization and disruption of microvascular perfusion, which in turn increases infarct size and ultimately mortality.⁵ In these cases, the use of intracoronary thrombolysis can dramatically reduce the thrombus size, increase the effective blood flow, and improve coronary perfusion without significantly increasing complications.^{1,6,7}

Triantafyllou K and colleagues⁸ reported a primary percutaneous coronary intervention of a patient with STEMI due to severe thrombotic left main (LM) artery lesion and left circumflex (LCX) artery ostial occlusion facilitated by IC Reteplase. They injected 5 units of Reteplase into the LM artery within 2 minutes, which leads to rapid blood flow to

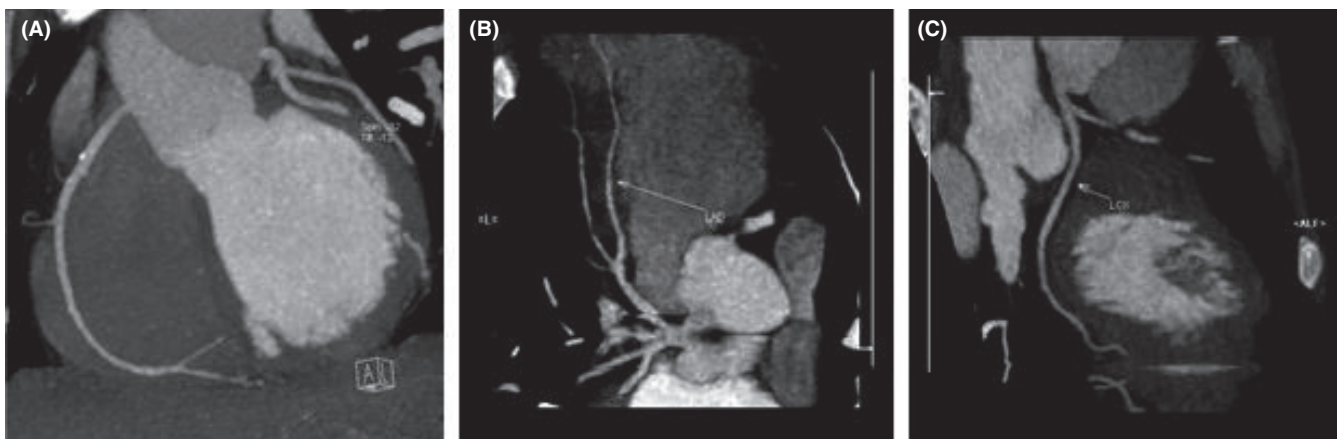


FIGURE 5 Coronary computed tomography angiography showing: A, right coronary artery. B, left anterior descending artery. C, left circumflex artery

the LCX artery but due to the complexity of the lesion, the patient underwent angioplasty with stent.

In other studies, generally, Streptokinase, Alteplase,^{1,6} and Tenecteplase⁷ were used to resolve large IC thrombus, but we used Reteplase for this purpose due to mere access to this agent. We used half of the standard Intravenous dose of Reteplase for IC thrombolysis.

Previous studies also showed no increase in bleeding with IC thrombolysis. Chen et al⁹ reported no major bleeding events in a pilot study on 22 patients with large thrombus burden, with the use of recombinant human Prourokinase, delivered by infusion catheter for 30 minutes. In another study by Emara et al,¹⁰ the use of streptokinase was also safe and effective in increasing the coronary perfusion and no major adverse events were reported.

In conclusion, the use of intracoronary thrombolysis in patients with an acute coronary obstruction due to a high volume of thrombus in the field of coronary ectasia which does not have an effective flow with balloon angioplasty and thrombo-aspiration can be an effective and safe treatment choice. We recommend the use of this therapeutic strategy based on individual case decision-making.

ACKNOWLEDGMENTS

We like to acknowledge the help provided by Mr Amirabbas Qassemi for editing and revising the language of the manuscript. Published with written consent of the patient.

CONFLICT OF INTEREST

None.

AUTHOR CONTRIBUTIONS

IJ, MMAR, and AG: involved in acquisition of data, drafting the manuscript, and participated sufficiently in the work. RP and KA: involved in acquisition of data, revising the manuscript, and participated sufficiently in the work.

ETHICAL APPROVAL


Informed consent was obtained from the patient regarding the report of her clinical scenario data in an anonymous way.

DATA AVAILABILITY STATEMENT

Data sharing not applicable to this article as no datasets were generated or analyzed during the current study.

ORCID

Iraj Jafaripour  <https://orcid.org/0000-0002-2702-1747>

Mohammad Mostafa Ansari Ramandi  <https://orcid.org/0000-0002-7431-0373>

Kamyar Amin  <https://orcid.org/0000-0002-5111-2059>

REFERENCES

1. Lee Y, Kim E, Kim BK, Shin JH. A case of successful reperfusion through a combination of intracoronary thrombolysis and aspiration thrombectomy in ST-segment elevation myocardial infarction associated with an ectatic coronary artery. *BMC Cardiovasc Disord.* 2017;17(1):94.
2. Napodano M, Dariol G, Al Mamary AH, et al. Thrombus burden and myocardial damage during primary percutaneous coronary intervention. *Am J Cardiol.* 2014;113(9):1449-1456.
3. Vergara R, Valenti R, Migliorini A, et al. TCT-145 rheolytic thrombectomy for acute myocardial infarction complicated by cardiogenic shock. *J Am Coll Cardiol.* 2016;68(18 Supplement):B59-B60.
4. Ielasi A, Anzuini A. Successful management of a huge thrombus in coronary aneurysmatic dilatation after failed mechanical thrombectomy during acute myocardial infarction. *J Cardiovasc Med.* 2014;15(1):80-81.
5. Jaffe R, Dick A, Strauss BH. Prevention and treatment of microvascular obstruction-related myocardial injury and coronary no-reflow following percutaneous coronary intervention: a systematic approach. *JACC Cardiovasc Interv.* 2010;3(7):695-704.
6. Kim JS, Kim JH, Jang HH, et al. Successful revascularization of coronary artery occluded by massive intracoronary thrombi with alteplase and percutaneous coronary intervention. *J Atheroscler Thromb.* 2010;17(7):768-770.
7. Gallagher S, Jain AK, Archbold RA. Intracoronary thrombolytic therapy: a treatment option for failed mechanical thrombectomy. *Catheter Cardiovasc Interv.* 2012;80(5):835-837.
8. Triantafyllou K, Metaxopoulos P, Babalis D. Primary percutaneous coronary intervention of an unprotected left main using mini-crush drug-eluting stents facilitated by intracoronary reteplase. *Catheter Cardiovasc Interv.* 2011;77(4):515-521.
9. Chen T, Wang Q, Liu G, et al. Safety and efficacy of intracoronary thrombolytic therapy via a new infusion catheter in patients with ST-segment elevation myocardial infarction with large thrombus burden: a pilot study. *Coron Artery Dis.* 2020. <https://doi.org/10.1097/MCA.0000000000000915>. [Epub ahead of print].
10. Emara HF, El Kilany WM, Zaki TM, El-Missiri AM. Administration of intracoronary streptokinase during primary percutaneous coronary intervention for anterior wall myocardial infarction with definite coronary thrombosis. *Cardiol Cardiovasc Res.* 2020;4(1):11.

SUPPORTING INFORMATION

Additional supporting information may be found online in the Supporting Information section.

How to cite this article: Jafaripour I, Ansari Ramandi MM, Gholami A, Pourkia R, Amin K. Successful intracoronary thrombolysis in a patient with anterior myocardial infarction and large thrombus burden associated with coronary artery ectasia. *Clin Case Rep.* 2021;9:93–97. <https://doi.org/10.1002/ccr3.3449>