

# The clinical outcome of the different HemiCAP and UniCAP knee implants: A systematic and comprehensive review

Michael-Alexander Malahias,<sup>1</sup> Dimitrios Chytas,<sup>2</sup> Fritz Thorey<sup>1</sup>

<sup>1</sup>ATOS Hospital Heidelberg, International Center for Hip, Knee and Foot Surgery, Heidelberg, Germany;

<sup>2</sup>National and Kapodistrian University of Athens, School of Medicine, 2<sup>nd</sup> Orthopedic Department, Athens, Greece

## Abstract

The focal metallic cartilage resurfacing is a surgical method that offers an appropriate *step* between the biological techniques and arthroplasty in middle-aged patients with full-thickness cartilage defects. The advantages of this technique are that it addresses the defect, respects healthy tissues and provides stability and contoured surface similar to a full arthroplasty. A systematic review was conducted according to Preferred Reporting Items for Systematic reviews and Meta-Analyses (PRISMA) guidelines. Two reviewers (MM and DC) independently conducted the search using the MEDLINE/PubMed database and the Cochrane Database of Systematic Reviews (CDSR). These databases were searched for the terms *hemicap knee implant* and *unicap knee implant* and *knee focal metallic implant*. From the initial 21 studies that were evaluated, 10 were eligible for analysis. Considering both the HemiCAP focal implant and the HemiCap® Wave patellofemoral prosthesis, we found a lack of mid- to long-term clinical outcomes in well-designed prospective clinical studies. No Level I or II studies were found, while the limited number of patients who were included undermines the overall clinical results of these studies. The progression of osteoarthritis, the persisting pain and the subsequent high revision or failure rates in the limited available studies with long-term follow-up, seem to be the major drawbacks of these partial resurfacing techniques. Utilization of partial resurfacing for femoral or patellofemoral compartments results in good short-term outcome for middle-aged patients as a *step* between biological technique and total knee arthroplasty. The surgeon should be cognizant and also notify the patient of the high failure rates that are reported in the literature in mid- to long-term follow-up and ultimately, the decision

to perform partial resurfacing should be taken by both the patient and the orthopedic surgeon.

## Introduction

The articular cartilage defects of the knee can be treated with several procedures depending on the age of the patient, the size and location of the defect. In young patients with localized defects, with a normal weight bearing axis and without further damage to the knee joint, biological repair methods such as marrow stimulation, osteochondral and autologous chondrocyte transplantation can be used with good clinical outcome.<sup>1,2</sup> In the older patient population with diffuse cartilage loss in one or more compartments, either a unilateral knee replacement or total knee replacement is recommended for surgical treatment. However, in the middle-aged patients, the treatment of these lesions is more complex and involves different methods and shared decision between patient and physician.<sup>3</sup> Especially, neither biological repair technique nor unicompartmental and total joint arthroplasty are suitable for many of these middle-aged patients.<sup>4</sup>

Furthermore, patellofemoral arthritis or chondromalacia can be treated with many conservative methods, which comprise non-steroidal anti-inflammatory drugs, rest and physical therapy, which includes stretching and strengthening exercises.<sup>5-11</sup> Debridement with lateral release, anterior advancement of the tibial tubercle, patellectomy, facetectomy and chondrectomy are possible surgical options for the treatment of these diseases.<sup>12</sup> Elderly patients with isolated patellofemoral arthritis can be treated with total knee replacement, a procedure which is generally not indicated for young patients.<sup>13</sup>

The focal metallic cartilage resurfacing is a method that aimed to offer an appropriate *step* between the biological techniques and arthroplasty.<sup>14</sup> The HemiCAP implant (HemiCAP\_ Focal Femoral Condyle Resurfacing Prosthesis, Arthrosurface Inc., Franklin, MA, USA) for femoral and patellofemoral resurfacing for treatment of cartilage lesions was introduced in 2003 and 2009 respectively.<sup>15,16</sup> The femoral resurfacing for large cartilage lesions with the anatomic UniCAP implant (UniCAP® Focal Femoral Condyle Resurfacing Prosthesis, Arthrosurface Inc., Franklin, MA, USA) was introduced in 2006.<sup>16</sup> We performed a review of the literature concerning the studies that have been published about the application of partial resurfacing

Correspondence: Michael-Alexander Malahias, International Centre for Hip, Knee and Foot Surgery and Sports Medicine Department (HKF), ATOS Hospital Heidelberg, Schlossberg 21, Heidelberg 69117, Germany.  
Tel.: +49.01737456054 - Fax: +49.062219839209.  
E-mail: alexandermalahias@yahoo.gr

Key words: knee focal metallic implant, hemicap, unicap, Wave prosthesis, inlay design.

Contributions: MAM was responsible for the conception and the design of this review. Furthermore, he participated in the collection of the data and in drafting and revising the final manuscript. DC participated in the collection of the data and in writing the manuscript. FT participated in revising critically the manuscript for important intellectual content.

Conflict of interest: the authors declare no potential conflict of interest.

Funding: none.

Received for publication: 10 December 2017.

Revision received: 1 March 2018.

Accepted for publication: 5 March 2018.

This work is licensed under a Creative Commons Attribution NonCommercial 4.0 License (CC BY-NC 4.0).

©Copyright M-A. Malahias et al., 2018  
Licensee PAGEPress, Italy  
Orthopedic Reviews 2018;10:7531  
doi:10.4081/or.2018.7531

for the treatment of focal femoral and trochlear full-thickness cartilage defects.

## Materials and Methods

A systematic review was conducted according to Preferred Reporting Items for Systematic reviews and Meta-Analyses (PRISMA) guidelines. Two reviewers (MM and DC) independently conducted the search using the MEDLINE/PubMed database and the Cochrane Database of Systematic Reviews (CDSR). These databases were searched for the terms *hemicap knee implant* and *unicap knee implant* and *knee focal metallic implant*. To maximize the search, backward chaining of the reference lists from the retrieved papers was also undertaken. A preliminary assessment of only the titles and abstracts of the search results was initially performed. The second stage involved a careful review of the full-text publications.

Our inclusion criteria were: clinical tri-

als involving a. the HemiCAP-Wave® implant and/or b. the HemiCAP focal femoral condyle resurfacing prosthesis and/or c. the UniCAP implant with recorded follow-up, written in English, published since 2011 (the first published clinical trial)<sup>17</sup> until April 30, 2017 (end of our search). The mean follow-up per study should be at least 2 years.

The quality of the evidence was classified using the US Preventive Services Task Force system for ranking level of evidence.

Differences between reviewers were discussed until agreement was achieved. They independently extracted data from each study and assessed variable reporting of outcome data. Descriptive statistics were calculated for each study. The methodological quality of each study and the different types of detected bias were independently assessed by each reviewer and then they were synthetically combined. The primary outcome that was measured was the postoperative statistically significant improvement of the clinical scores that were used in comparison with the preoperative scores per study. The secondary outcome was the reoperations' rate per study and the postoperative radiographic worsening of the patients according to Kellgren-Lawrence classification.

## Results

From the initial 21 studies, a total of 10 studies were eligible for analysis, according to our inclusion-exclusion criteria. We excluded all anatomical cadaveric studies (2), studies which just described the surgical technique without any clinical results (2), animal studies (4), review articles (2) and irrelevant papers (1: about first metatarsal failed hemicap-implant). A summary flowchart of our literature search can be found in Figure 1.

The total number of patients included in this review were 334, whereas the total mean age was 43.5 years. There were 162 male patients (48.5%) and 172 females (51.5%).

Ten papers met the criteria that we had posed: four of them (40%) dealt with the HemiCAP focal femoral condyle resurfacing prosthesis,<sup>3,14,17,18</sup> four (40%) explored the clinical use of the HemiCAP-Wave® implant for the treatment of trochlear cartilage lesions,<sup>15-21</sup> one study (10%) dealt with both these implants (HemiCAP focal and HemiCAP-Wave® implant)<sup>16</sup> and one study (10%) with the UniCAP implant for femoral condyle cartilage defects (Table 1).<sup>13-21</sup>

## Focal femoral condyle defects

After excluding an *in vivo* canine model which investigated the clinical outcome of a focal pyrolytic carbon implant and a pre-clinical ceramic implant,<sup>22,23</sup> all the clinical trials concerning focal femoral implants dealt with the metallic HemiCap or UniCap component.<sup>3,13,14,16-18</sup> The total number of patients involved were 180. The mean follow-up ranged from two years to seven years, while the complications' rate was 26.1% (47 patients).

The Knee Society Score (KSS),<sup>13,16</sup> the Western Ontario and McMaster Universities Osteoarthritis Index (WOMAC)<sup>3,14</sup> and the Tegner Activity Levels<sup>17,18</sup> were used in two of these studies, the pain Visual Analogue Scale (VAS)<sup>13,16,18</sup> and Knee injury and Osteoarthritis Outcome Score (KOOS)<sup>3,17,18</sup> in three of them, the Kellgren-Lawrence grade in four of them,<sup>13,16-18</sup> while each of the scores International Knee Documentation Committee (IKDC),<sup>3</sup> Hannover Scoring

System (HSS),<sup>3</sup> 12- Item Short Form Health Survey Instrument (SF-12),<sup>14</sup> 36-Item Short Form Health Survey Instrument (SF-36)<sup>17</sup> was used in one study (Table 2).

The mean preoperative VAS pain score was 7.3, whereas the total mean postoperative VAS pain score was found 2.4 (statistically significant improvement regarding VAS in all three studies where it was used). The total mean preoperative KSS amongst studies was estimated to be 50.5, while the total mean postoperative KSS was 89 (statistically significant improvement regarding KSS in the two studies where it was used). Furthermore, the total mean WOMAC was improved from an initial rate of 42 to a final rate of 86 (statistically significant improvement regarding WOMAC in the two studies where it was used). As for Tegner Activity Levels, only one of the two studies in which they were used (50%) recorded a significant improvement (from a total preoperative mean Tegner: 2.5 to a total postoperative Tegner: 3.2). In addition, all the studies

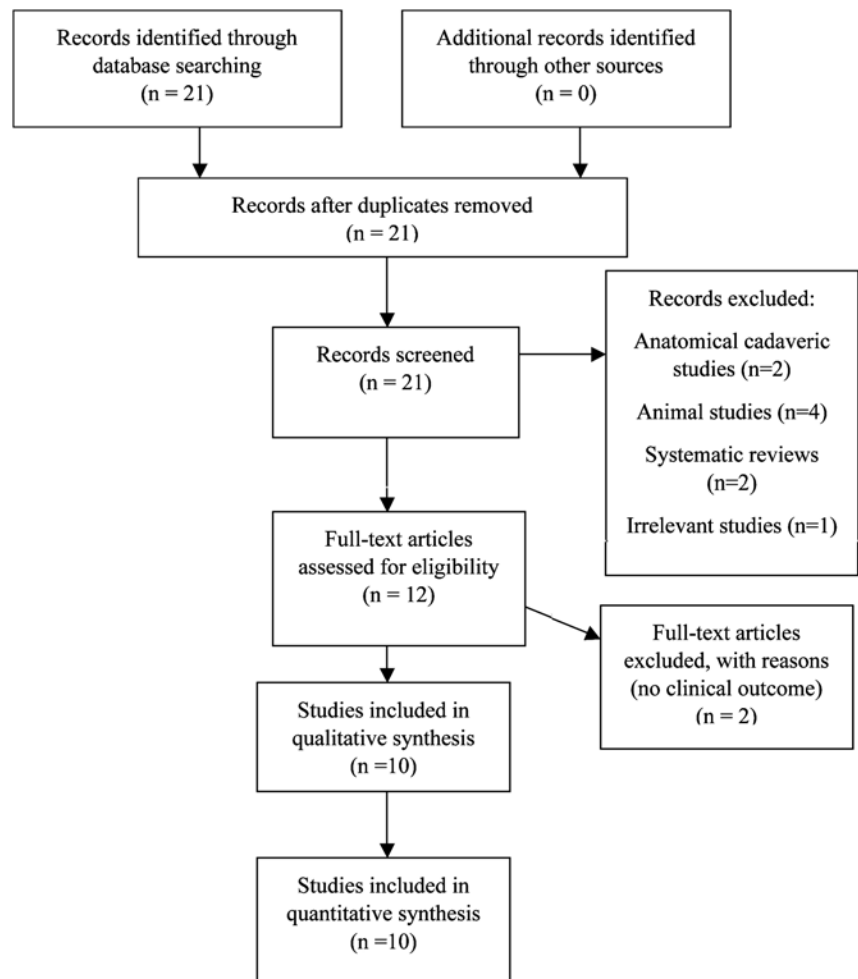


Figure 1. PRISMA flow chart.

which made use of HSS (from a mean preoperative value: 61.2 to a mean postoperative value: 86.2), SF-36 (from a mean preoperative value: 31.7 to a mean postoperative value: 46.9) and KOOS showed statistically significant improvement. One study which used the SF-12 showed no significant difference.<sup>14</sup> Finally, three out of four studies which statistically assessed the radiographic osteoarthritic changes reported significant worsening of the OA grade at the follow-up end point.

In total, there was a consensus amongst authors in favor of the clinical use of the HemiCap focal femoral implant, especially in middle-aged patients, to whom arthroplasty is not recommended.<sup>3,14,16-18</sup> There was only one study which showed clinical but no radiographic improvement, after failed index cartilage procedures.<sup>18</sup>

Laursen published a relatively large (64 patients) cohort study of level IV concerning the UniCap component, in which the Kaplan-Meier survival rate at 7 years was only 50%, due to the progression of cartilage lesions, progression of osteoarthritis or increased knee pain.<sup>13</sup> This study showed that this implant could have only a temporary use in young patients who are ineligible for arthroplasty treatment. The same author in another study, which dealt with the HemiCap implant in full-thickness cartilage femoral defects, showed a 23% revision rate.<sup>16</sup>

On the other hand, Bollars *et al.* reported excellent clinical results in 18 middle-aged, well-selected patients with the use of HemiCap after a median follow-up of 34 months.<sup>3</sup> Similar results were found by Becher *et al.* in a 5-year follow-up study about focal femoral condyle defects in 21 patients. Dhollander *et al.* demonstrated

that the use of HemiCap focal femoral implant led to radiologically significant osteoarthritic changes during the follow-up of 14 patients.<sup>18</sup> It seemed that the favorable clinical outcome was not confirmed by the radiographic findings. Finally, Pascual-Garrido *et al.* compared the HemiCap implant (32 patients) with biological procedures (30 patients), including debridement, microfracture, osteochondral autograft transplantation, osteochondral allograft, and autologous chondrocyte implantation.<sup>14</sup>

### Patellofemoral joint defects

In the current review, we found 5 clinical trials which investigated the HemiCap<sup>®</sup> Wave prosthesis.<sup>15-21</sup> The total number of patients involved were 154. The mean follow-up ranged from two years to seven years, while the complications' rate was 9.7% (15 patients). All the 5 studies demonstrated improved outcome (80 % with statistical significance and 20% with no statistical report).

Kellgren-Lawrence grade was utilized in five studies (100% of the studies), pain VAS score was used in four of them (80% of the studies), KOOS was calculated in three studies (60%), WOMAC score, Tegner Activity levels and Knee Society Score were used in two of them (40% of the studies, Table 3). Each of Lysholm, American Knee Society Score, OKS, KOOS, SF-36, subjective IKDC was utilized in one study (20% of the studies), while in another one (20% of the studies) the Self –designed Sports Questionnaire was used and, in another one (20% of the studies), the range of movement was assessed (Table 3).

The mean preoperative VAS pain score amongst studies was 6.5, whereas the total

mean postoperative VAS pain score was found 3.1 (statistically significant improvement regarding VAS in all three studies in which it was used). The total mean WOMAC was improved from an initial rate of 61.7 to a final rate of 82.5 (statistically significant improvement regarding WOMAC in the two studies in which it was used). Moreover, the total mean preoperative KSS was estimated to be 49, while the total mean postoperative KSS was 89 (statistically significant improvement regarding KSS in the study in which it was used). As for Tegner Activity Levels, there was a statistically significant improvement in the only study in which this score was utilized (from a total preoperative mean Tegner: 2 to a total postoperative Tegner: 3). In addition, each one of the trials which made use of SF-36 (from a mean preoperative value: 32 to a mean postoperative value: 53), Oxford Knee Score (from a mean preoperative value: 19 to a mean postoperative value: 35), IKDC (from a mean preoperative value: 41.1 to a mean postoperative value: 58.4), Lysholm (from a mean preoperative value: 34 to a mean postoperative value: 66) and KOOS demonstrated statistically significant improvement. Finally, only one out of four studies (25%) which statistically assessed the radiographic osteoarthritic changes showed significant worsening of the OA grade at the follow-up end point.

Overall, almost all the authors (80%) agreed that the use of the HemiCAP-Wave<sup>®</sup> prosthesis was clinically effective.<sup>15,16,19,21</sup>

In a level IV prospective case series, Imhoff *et al.* documented the results of 29 patients operated with this technique.<sup>19</sup> In nine of them, HemiCap<sup>®</sup> Wave prosthesis was combined with concomitant procedures

**Table 1. General characteristics of the studies included in our review.**

Author(s)	Number-sex of patients	Mean age Implant	Follow-up	Level of evidence	
Laursen <sup>13</sup>	64 (36F-28M)	51y	UniCAP	7 y	IV
Bollars <i>et al.</i> <sup>3</sup>	19 (18F-1M)	49y	HemiCAP	34 m	IV
Pascual-Garrido <i>et al.</i> <sup>14</sup>	62 (23F-39M)	44.6y (1st group) 47.9y (2nd group)	HemiCAP	2.6 y (1st group) 2 y (2nd group)	III
Dhollander <i>et al.</i> <sup>18</sup>	14 (6F-8M)	45.7y	HemiCAP	26.1 m	IV
Becher <i>et al.</i> <sup>17</sup>	21 (10F-11M)	53.7y	HemiCAP	5.3 y	IV
Laursen and Lind <sup>16</sup>	61 (37F-24M)	49y	HemiCaP HemiWave	7 y	IV
Laursen <sup>20</sup>	18 (12F-6M)	50y	HemiWave	6 y	IV
Feucht <i>et al.</i> <sup>21</sup>	30 (8F-22M)	48y (1st group) 49y (2nd group)	HemiWave	26 m (1st group) 25 m (2nd group)	III
Imhoff <i>et al.</i> <sup>19</sup>	29 (14F-15M)	42y	HemiWave	24 m	IV
Patel <i>et al.</i> <sup>15</sup>	16 (8F-8M)	63y	HemiWave	24.1 m	IV

y: years, m: months, M: male, F: female.

to address patellofemoral instability, patellofemoral malalignment and tibiofemoral malalignment, so only 20 patients could finally be assessed for an isolated patellofemoral arthroplasty. Imhoff *et al.* found a significant improvement in all subjective scores, whereas no progression of tibiofemoral osteoarthritis or changes in patellar height were noticed.<sup>19</sup>

On the other hand, Laursen also showed a significant improvement in 2-year follow-up subjective scores, but the revision rate after 6 years was up to 28%.<sup>20</sup> This early failure rate seems rather unacceptable for a knee prosthesis such as the HemiCAP® Wave prosthesis. Patel *et al.* in another clinical trial with small number of patients (16 patients) demonstrated excellent early results with the HemiCAP® Wave prosthesis.<sup>15</sup>

Finally, Feucht *et al.* in a Level III study compared the clinical and radiological outcomes between an inlay (HemiCAP® Wave, ArthroSurface) and an onlay design component (Journey, Smith & Nephew).<sup>21</sup> This is

the only comparative study that we found in the literature concerning the HemiCAP® Wave prosthesis. The difference between follow-up subjective scores was found to be statistically insignificant between the two groups. Despite that, more than half of the onlay-treated patients showed tibiofemoral osteoarthritic changes in their final follow-up, while no inlay-treated patients developed these radiological changes.

## Discussion

### Focal femoral condyle defects

Symptomatic full-thickness cartilage lesions are generally painful and disabling, and can progress to osteoarthritis when left untreated in the young or middle-aged patients.<sup>24</sup> These lesions undergo progressive changes resulting in resorption of the osseous walls of the defect, the formation of a large cavity, and the collapse of the surrounding articular cartilage and subchon-

dral bone.<sup>25</sup> Additionally, the presence of focal chondral or osteochondral defects can also damage the opposing meniscus and tibial cartilage surface.<sup>22</sup>

The vast majority of these lesions are observed in patients over the age of 40 years,<sup>26</sup> while approximately one fifth of these defects were categorized as grade IV.<sup>27</sup> Middle-aged patients are often affected by localized cartilage damage and are neither fit for biological repair methods nor candidates for traditional resurfacing techniques such as unicompartmental or total joint replacement due to their age.

A proposed solution is a focal hemiarthroplasty implant, intended for use as an alternative resurfacing treatment strategy for isolated lesions in patients who are too young for TKAs or not good candidates for regenerative biological procedures.<sup>28,29</sup> The concept of a minimally invasive hemiarthroplasty for the treatment of focal osteochondral knee defects offers the advantages of reduced pain, a shorter hospital stay, and increased range of motion.<sup>22</sup>

**Table 2. Outcome criteria, significantly (or non-) improved scores, complications, failures and brief conclusion of the studies dealing with focal femoral condyle defects implants (HemiCap or UniCap).**

Author(s)	Outcome criteria	Significant difference in scores	Complications and failures	Reoperations	Brief conclusion
Laursen <sup>13</sup>	Knee Society, Pain VAS, Kellgren-Lawrence Grade	KSS and VAS pain significantly improved. Kellgren-Lawrence significantly worsened	In 47% of implants: progression of cartilage lesions	Conversion to knee replacement	Temporary solution. Helpful for young patients to whom arthroplasty is not yet recommended
Bollars <i>et al.</i> <sup>3</sup>	KOOS, HSS, WOMAC	All clinical scores significantly improved	One prominent hardware of previous high tibial osteotomy (HTO)	Removal of HTO hardware	Excellent results in pain and function for middle-aged well selected patients
Pascual-Garrido <i>et al.</i> <sup>14</sup>	WOMAC, Short Form 12 (SF-12), Satisfaction	Total postoperative WOMAC: significantly improved. WOMAC between the two groups: no statistical difference. Total postoperative SF-12: no difference with preoperative. Radiographic changes to more severe OA grade.	One drainage of portal site. One clicking. One knee pain. One serious knee pain.	Medication. No treatment was needed. Physiotherapy. Conversion to unicompartmental knee arthroplasty	Excellent success at short follow-up, similar results with biologic procedures
Dhollander <i>et al.</i> <sup>18</sup>	KOOS, Tegner Activity levels, Pain VAS, Kellgren-Lawrence Grade	KOOS and VAS: significantly improved. Tegner: no difference. Kellgren-Lawrence: significant worsening	Significant osteoarthritic changes	N/A	Clinical but not radiological improvement after failed index cartilage procedures
Becher <i>et al.</i> <sup>17</sup>	KOOS, Tegner Activity levels, SF-36, satisfaction, Kellgren-Lawrence, OARSI grading	KOOS, Tegner, SF-36: significantly improved. Kellgren-Lawrence: no significant changes	One persistent pain. One pain+varus malalignment. One persistent pain	Arthroscopic debridement: 1) Arthroscopic debridement 2) High tibial osteotomy 3) Hardware removal, new debridement. Unicompartmental knee arthroplasty	Effective treatment for middle-aged patients.
Laursen and Lind <sup>16</sup>	Knee society (KSS), VAS pain score, Kellgren-Lawrence Grade	KSS and VAS: significantly improved. Kellgren-Lawrence: significant worsening	Nine cases of progression of cartilage lesions (25%)	Conversion to knee arthroplast	Helpful for young patients to whom arthroplasty is not yet recommended

Hemiarthroplasty also preserves bone stock, allowing for future revision or total joint replacement, if needed.<sup>22</sup>

A weak point of Larsen's study was that the operative technique was used both in trochlear and focal femoral defects.<sup>16</sup> This level IV case series - including 61 patients - appeared superior results to those of the previous UniCap study.<sup>13</sup> Despite that, the HemiCap implant was considered to be rather a temporary treatment before conversion to arthroplasty after a few years. In addition, both the studies by Bollars *et al.*<sup>3</sup> and Becher *et al.*<sup>17</sup> included a small number of patients, which compromised the results. However, the different number of subjective scores that were used increased the validity of these studies.<sup>3,17</sup> Finally, the trial by Pascual-Garrido *et al.* showed only 2-year short-term results and it was demonstrated that both techniques resulted in similar clinical outcomes and provided excellent success rates.<sup>14</sup> Also, the wide variety of the biological procedures which were used in this study could not guarantee the accuracy

of the results. All the aforementioned studies were subjected to the expected for the design of those studies selection, while all, apart from the last study,<sup>14</sup> were subjected to performance and detection bias. In brief, the use of large UniCap implants showed rather inferior clinical results to those of the smaller and less invasive HemiCap component (Table 2). Nevertheless, we reported a lack of mid- to long-term, well-designed clinical studies regarding the HemiCAP implant. No Level I or II studies were found, while the small number of patients who were included undermines the clinical results of the trials. The progression of osteoarthritis seemed to be the major drawback of this technique.

### Patellofemoral joint defects

Arthritis and chondromalacia of the patella are common pathologies that may lead to advanced degeneration requiring patellofemoral arthroplasty (PFA).<sup>30</sup> The trochlear groove is essential for correct patellar tracking during movement.<sup>31</sup>

According to Chawla *et al.*,<sup>32</sup> recent improvements in rates of implant survival have made PFA an economically beneficial joint-preserving procedure in younger patients, delaying TKA until implant failure or tibiofemoral osteoarthritis (OA) progression. Nevertheless, due to the variable outcomes, at present, PFA remains a controversial treatment for advanced patellofemoral OA.<sup>33,34</sup>

Many surgeons perform total knee replacement for isolated advanced patellofemoral OA, rather than PFA, in order to achieve more consistent outcomes.<sup>34-36</sup> Early patellofemoral implants were characterized by a high incidence of patellar maltracking, catching and subluxation, due to design features of the trochlear components, inadequate soft tissue balancing, and component malposition.<sup>37,38</sup> Some of the current issues surrounding isolated PFA are the fact that extensive exposure is necessary, the lack of long-term outcome studies, and the variable success rate of this procedure.<sup>33,39</sup> During the previous decade

**Table 3. Outcome criteria, significantly (or non-) improved scores, complications, failures and brief conclusion of the studies dealing with patellofemoral joint defects (HemiCAP-Wave® prosthesis).**

Author(s)	Outcome criteria	Significant difference in scores	Complications and failures	Reoperations	Brief conclusion
Laursen and Lind <sup>16</sup>	Knee society, pain score, Kellgren-Lawrence Grade	KSS and VAS: significantly improved. Kellgren-Lawrence: significant worsening	Nine cases of progression of cartilage lesions (25%)	Conversion to knee arthroplast	Helpful for young patients to whom arthroplasty is not yet recommended.
Imhoff <i>et al.</i> <sup>19</sup>	WOMAC, subjective IKDC Pain VAS score, Tegner Activity levels. Self-designed Sports Questionnaire. Kellgren-Lawrence grade Caton-Deschamps Index	WOMAC, IKDC, VAS, Tegner: significantly improved. Kellgren-Lawrence: no difference	One component disassembly	Revision of trochlear component	Effective and safe OA for patellofemoral
Patel <i>et al.</i> <sup>15</sup>	OKS, KOOS, SF-36, range of movement, Kellgren-Lawrence/Ahlback grades	OKS, KOOS, SF-36: significantly improved. Kellgren-Lawrence: no difference	One keloid scar. One synovitis. One infection. One asymptomatic OA	No additional treatment. NSAID's drugs. Revision to TKA. No treatment was needed	Effective, safe technique for isolated patellofemoral OA in selected patients.
Laursen <sup>20</sup>	American Knee society, Pain VAS, Kellgren-Lawrence grade	AKSS, VAS: significantly improved. Kellgren-Lawrence: changes to more severe OA grade	In 28% of implants: progression of cartilage damage	Conversion to knee arthroplasty	Improved short- to mid-term clinical outcome and reduced pain but high mid-term revision rate after patellofemoral inlay resurfacing using the HemiCAP-Wave® implant
Feucht <i>et al.</i> <sup>21</sup>	WOMAC, Lysholm, Pain VAS Kellgren-Lawrence grade Caton-Deschamps Index	Postoperative WOMAC, Lysholm, VAS: no statistical difference between inlay and onlay group, but with significant difference when compared with the preoperative rates per group. Kellgren-Lawrence: no difference in the inlay group, while 53% OA progression in the onlay group.	One component disassembly. One lateral hyperpression syndrome. One osteoarthritis.	Implantation of a new trochlear component. Lateral patellar facetectomy. Conversion to arthroplasty	The technique may improve the long-term results and survival rates after isolated patellofemoral arthroplasty.

these concerns led to the development of a new minimally invasive, anatomic, joint-preserving PFA resurfacing component which might provide some of the solutions required in this area.<sup>12</sup> This was the first isolated PFA with an inlay design trochlear component (HemiCAP® Wave, Arthrosurface). This component is preferred in young or middle-aged patients with an extended cartilage defect of the trochlea or isolated patellofemoral arthritis, who showed no improvement after biological therapies.<sup>12</sup>

Regarding the study by Imhoff *et al.*, although 93% of the patients completed the follow-up, the number of patients who were included was rather small, while the short-term follow-up (2 years) did not reveal the actual long-term clinical outcome, which is required for the evaluation of a knee arthroplasty.<sup>19</sup> A major drawback of the Level IV study by Laursen was the very small number of patients (18 patients), which compromises its scientific value.<sup>20</sup> Finally, the study by Feucht *et al.*, despite its superior design (it was the only Level III comparative study), included again a rather small number of patients (15 inlay *versus* 15 onlay patients) All the aforementioned studies<sup>15,16,19-21</sup> were subjected to the expected for their design selection bias, while all apart from the last study<sup>21</sup> were subjected to performance and detection bias.

In total, as far as the HemiCAP® Wave is concerned, we noticed a lack of mid- to long-term, well-designed clinical studies. No Level I or II studies were found, while the small number of patients who were included undermines the clinical results of the studies. Nevertheless, this inlay design component seemed to be slightly superior to the onlay design of other prostheses. However, more comparative studies on current inlay and onlay prostheses are needed.<sup>40</sup>

Aseptic loosening or wear of the HemiCAP® Wave is negligible, according to the aforementioned clinical studies. Nevertheless, issues like postoperative effusion or insignificant persisting pain have to be addressed about this type of prosthesis. According to our clinical experience, a possible slight overstuffing of the trochlear component may lead to a temporary patella *clunk* syndrome during the flexion-extension movements of the knee, which is disappeared a few days after the operation.

## Conclusions

The HemiCap focal femoral implant could be an interesting alternative in the

treatment of large full-thickness osteochondral knee lesions in middle-aged patients suffering from isolated post-traumatic arthritis or osteonecrosis. Nevertheless, this kind of treatment must be preserved as a second-line option and only after the failure of biological procedures. Finally, it seems that the HemiCAP® Wave patellofemoral prosthesis might be the indicated primary implant in cases of isolated patellofemoral arthritis in young patients. Further clinical evidence, via the performance of well-designed mid- and long-term studies, is required.

## References

1. Brittberg M, Lindahl A, Nilsson A et al. Treatment of deep cartilage defects in the knee with autologous chondrocyte transplantation. *N Engl J Med* 1994;331: 889-95.
2. Hangody L, Fules P. Autologous osteochondral mosaicplasty for the treatment of full-thickness defects of weight-bearing joints: ten years of experimental and clinical experience. *J Bone Joint Surg Am* 2003;85A:25-32.
3. Bollars P, Bosquet M, Vandekerckhove B, et al. Prosthetic inlay resurfacing for the treatment of focal, full thickness cartilage defects of the femoral condyle: a bridge between biologics and conventional arthroplasty. *Knee Surg Sports Traumatol Arthrosc* 2012;20:1753-9.
4. Becher C, Huber R, Thermann H, et al. Effects of a contoured articular prosthetic device on tibiofemoral peak contact pressure: a biomechanical study. *Knee Surg Sports Traumatol Arthrosc* 2008;16:56-63.
5. Kooijman HJ, Driessen APPM, van HORN JR. Long term results of patellofemoral arthroplasty. *J Bone Joint Surg (Br)* 2003;8-B:836-40.
6. Krajca-Radcliffe JB, Coker TP. Patellofemoral arthroplasty: a 2- to 18-year follow-up study. *Clin Orthop Relat Res* 1996;330:143-51.
7. Sisto DJ, Sarin VK. Custom Patellofemoral Arthroplasty of the Knee. *J Bone Joint Surg* 2006;88:1475-80.
8. Arciero RA, Toomey HE. Patellofemoral arthroplasty: a three- to nine-year follow-up study. *Clin Orthop Relat Res* 1988;236:60-71.
9. Argenson JNA, Guillaume JM, Aubaniac JM. Is there a place for patellofemoral arthroplasty? *Clin Orthop Relat Res* 1995;321:162-7.
10. Fulkerson JP. Alternatives to Patellofemoral Arthroplasty. *Clin Orthop Relat Res* 2005;436:76-80.
11. Crossley K, Bennell K, Green S, et al. Physical therapy for patellofemoral pain: a randomized, double-blinded, placebo-controlled trial. *Am J Sports Med* 2002;30:857-65
12. Cannon A, Stolley M, Wolf B, Amendola A. Patellofemoral resurfacing arthroplasty: literature review and description of a novel technique. *Iowa Orthop J* 2008;28:42-8.
13. Laursen JO. Treatment of full-thickness cartilage lesions and early OA using large condyle resurfacing prosthesis: UniCAP®. *Knee Surg Sports Traumatol Arthrosc*. 2016;24:1695-701.
14. Pascual-Garrido C, Daley E, Verma NN, Cole BJ. A comparison of the outcomes for cartilage defects of the knee treated with biologic resurfacing versus focal metallic implants. *Arthroscopy* 2017;33:364-73.
15. Patel A, Haider Z, Anand A, Spicer D. Early results of patellofemoral inlay resurfacing arthroplasty using the HemiCap Wave prosthesis. *J Orthop Surg (Hong Kong)* 2017;25:2309499017692705.
16. Laursen JO, Lind M. Treatment of full-thickness femoral cartilage lesions using condyle resurfacing prosthesis. *Knee Surg Sports Traumatol Arthrosc* 2017;25:746-51.
17. Becher C, Kalbe C, Thermann H, et al. Minimum 5-year results of focal articular prosthetic resurfacing for the treatment of full-thickness articular cartilage defects in the knee. *Arch Orthop Trauma Surg* 2011;131:1135-43.
18. Dhollander AA, Almqvist KF, Moens K, et al. The use of a prosthetic inlay resurfacing as a salvage procedure for a failed cartilage repair. *Knee Surg Sports Traumatol Arthrosc* 2015;23:2208-12.
19. Imhoff AB, Feucht MJ, Meidinger G et al. Prospective evaluation of anatomic patellofemoral inlay resurfacing: clinical, radiographic, and sports-related results after 24 months. *Knee Surg Sports Traumatol Arthrosc* 2015;23:1299-307.
20. Laursen JO. High mid-term revision rate after treatment of large, full-thickness cartilage lesions and OA in the patellofemoral joint using a large inlay resurfacing prosthesis: HemiCAP-Wave®. *Knee Surg Sports Traumatol Arthrosc* 2016 Oct 6. [Epub ahead of print]
21. Feucht MJ, Cotic M, Beitzel K, et al. A matched-pair comparison of inlay and onlay trochlear designs for patellofemoral arthroplasty: no differ-

- ences in clinical outcome but less progression of osteoarthritis with inlay designs *Knee Surg Sports Traumatol Arthrosc* 2015 Aug 1. [Epub ahead of print]
22. Salkeld SL, Patron LP, Lien JC, et al. Biological and functional evaluation of a novel pyrolytic carbon implant for the treatment of focal osteochondral defects in the medial femoral condyle: assessment in a canine model. *J Orthop Surg Res* 2016;11:155.
  23. Waldorff EI, Roessler BJ, Zachos TA et al. Preclinical evaluation of a novel implant for treatment of a full-thickness distal femoral focal cartilage defect. *J Arthroplasty* 2013;28:1421-9.
  24. Sellards RA, Nho SJ, Cole BJ. Chondral injuries. *Curr Opin Rheumatol* 2002;14:134-41.
  25. Jackson DW, Lalor PA, Aberman HM, Simon TM. Spontaneous repair of full-thickness defects of articular cartilage in a goat model. A preliminary study. *J Bone Joint Surg Am* 2001;83A:53-64.
  26. Hjelle K, Solheim E, Strand T, et al. Articular cartilage defects in 1,000 knee arthroscopies. *Arthroscopy* 2002;18:730-4.
  27. Curl WW, Krome J, Gordon ES, et al. Cartilage injuries: a review of 31,516 knee arthroscopies. *Arthroscopy* 1997;13:456-60.
  28. Kirker-Head CA, Van Sickle DC, Ek SW, McCool JC. Safety of, and biological and functional response to, a novel metallic implant for the management of focal full-thickness cartilage defects: preliminary assessment in an animal model out to 1 year. *J Orthop Res* 2006;24:1095-108.
  29. Schindler OS. Articular cartilage surgery in the knee. *Orthop Trauma* 2010;24:107-20.
  30. Hinman RS, Crossley KM. Patellofemoral joint osteoarthritis: an important subgroup of knee osteoarthritis. *Rheumatology (Oxford)* 2007;46:1057-62.
  31. Valoroso M, Saffarini M, La Barbera G, et al. Correction of Patellofemoral Malalignment With Patellofemoral Arthroplasty. *J Arthroplasty* 2017;32:3598-602.
  32. Chawla H, Nwachukwu BU, van der List JP, et al. Cost effectiveness of patellofemoral versus total knee arthroplasty in younger patients. *Bone Joint J* 2017;99B:1028-36.
  33. Van der List JP, Chawla H, Villa JC, Pearle AD. Why do patellofemoral arthroplasties fail today? A systematic review. *Knee* 2017;24:2-8.
  34. Dy CJ, Franco N, Ma Y et al. Complications after patello-femoral versus total knee replacement in the treatment of isolated patello-femoral osteoarthritis. A meta-analysis. *Knee Surg Sports Traumatol Arthrosc* 2012;20:2174-90.
  35. Saragaglia D, Mader R, Refaie R. Are results of total knee arthroplasty for isolated patellofemoral OA as good as for medial compartment OA? A medium-term retrospective comparative study. *Eur J Orthop Surg Traumatol* 2015;25:381-6.
  36. Becher C, Renke A, Heyse TJ et al. Patellofemoral arthroplasty--results of a nation-wide survey in Germany and review of the literature. *Z Orthop Unfall* 2008;146:773-81.
  37. Lonner JH. Patellofemoral arthroplasty. *Orthopedics* 2010;33:653.
  38. Lonner JH, Bloomfield MR. The clinical outcome of patellofemoral arthroplasty. *Orthop Clin North Am* 2013;44:271-80.
  39. Walker T, Perkinson B, Mihalko WM. Patellofemoral arthroplasty: the other unicompartmental knee replacement. *Instr Course Lect* 2013;62:363-71.
  40. Cotic M, Imhoff AB. Patellofemoral arthroplasty: indication, technique and results. *Orthopade* 2014;43:898-904.