



Case report

Open Access

Nadroparine-induced skin necrosis on a patient with essential thrombocythaemia: a case report

Manousos-Georgios Pramateftakis*, Dimitrios Kanellos, Stefanos Psomas and Ioannis Kanellos

Address: Department of Surgery, European Medical Center, Asklipiou 10, 57001 Thessaloniki, Greece

Email: MGP* - mpramateftakis@hotmail.com; DK - kanellosd@yahoo.com; SP - st.psomas@gmail.com; IK - ik@hol.gr

* Corresponding author

Published: 10 March 2009

Received: 29 January 2009

Cases Journal 2009, 2:6458 doi: 10.1186/1757-1626-2-6458

Accepted: 24 February 2009

This article is available from: <http://casesjournal.com/casesjournal/article/view/2/3/6458>

© 2009 Pramateftakis et al; licensee Cases Network Ltd.

This is an Open Access article distributed under the terms of the Creative Commons Attribution License (<http://creativecommons.org/licenses/by/3.0>), which permits unrestricted use, distribution, and reproduction in any medium, provided the original work is properly cited.

Abstract

Skin necrosis is a rare but serious complication of subcutaneously administered low-molecular-weight heparin. We report a case of a 53-year-old female patient with skin necrosis induced by subcutaneous administration of nadroparine. The patient suffered from essential thrombocythaemia on a background of chronic myeloproliferative disease. She was admitted to our clinic with a subacute ileus due to endometriosis of the rectosigmoid junction. She underwent a high anterior resection and she received pre- and postoperative antithrombotic prophylaxis with subcutaneous nadroparine on a daily basis. On the 6th and 7th postoperative days, two skin necroses occurred at two injection sites.

Introduction

Skin necrosis following subcutaneously administered low-molecular-weight heparin (LMWH) is a rare but serious complication. It is believed that skin necrosis, amongst other thrombotic complications observed, are the result of LMWH-induced platelet aggregation followed by intravascular thrombosis. According to current literature, 24 cases of LMWH-induced necroses have been reported. Three of those cases occurred following nadroparine injections. All 24 cases are reporting on patients with thrombocytopenia. Our case is the only thrombocytotic patient amongst all published cases. The aim of this paper is to report on a rare case of skin necrosis following nadroparine injections on a patient with thrombocytosis.

Case presentation

A 45-year-old Caucasian female patient, with a known history of essential thrombocythaemia on a background of chronic myeloproliferative disease, was admitted to our clinic with a subacute ileus. Laboratory blood tests revealed the following results: Glucose 88 mg/dl, urea 17 mg/dL, creatinine 0.6 mg/dL, SGOT 33 iu/L, SGPT 24 iu/L, γ GT 99 iu/L, LDH 418 iu/L, CRP 0.1, total bilirubin 0.7 μ mol/L, direct bilirubin 0.35 μ mol/L, anti-HCV positive, WCC $9.83 \times 10^9/L$, Ht 32.2, PLT 768 (Normal value: $>150-300 \times 10^9/L$).

All coagulation parameters, including protein S and C activity, antithrombin III activity, activated partial

thromboplastin time, prothrombin time, fibrinogen concentration and fibrinogen degradation products, were within normal range. Computed tomography (CT) of the abdomen (after gastrograffin intake) revealed spleen distention and stenosis at the rectosigmoid junction. The following day the patient was taken to the operation theatre and the patient underwent a high anterior resection, due to endometriosis of the rectosigmoid junction. On postoperative blood test results, the platelet count was constantly high, ranging between $800 \times 10^9/L$ & $900 \times 10^9/L$. During her stay in our clinic, the patient received piperacillin-tazobactam 4.5gr intravenously (I.V.) for one day, omeprazole 40mg I.V. for two days and 0.6 ml of nadroparine subcutaneously to the abdominal wall, on a daily basis. On the sixth postoperative day, the patient complained of pain in the right lower abdomen, at the site of the nadroparine injections and a purple discoloration appeared on the right lower site of the abdominal wall.

Within 24 hours of the onset of pain, a necrotic eschar surrounded by erythema had formed on the right lower abdomen (Figure 1). The necrotic margins were well demarcated. One day later a second lesion appeared on the left side (Figure 2). Subcutaneous injections of nadroparine were stopped. The pain at the necrotic areas became severe. The patient developed spiking pyrexia, reaching a maximum of $38.7^\circ C$. The fever was thought to be a result of the necroses. The lesions were treated conservatively and they gradually settled. The skin returned to its normal appearance 4–5 weeks later.

Discussion

Essential thrombocytosis is an acquired myeloproliferative disorder, characterized by the overproduction of platelets by megakaryocytes in the bone marrow in the absence of an alternative cause. Arterial and venous thromboses

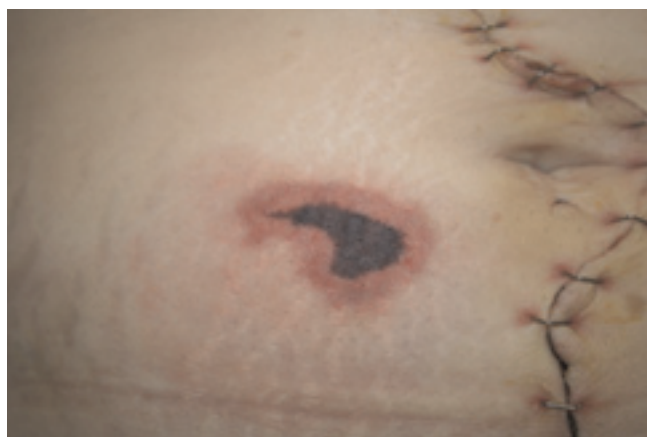

Figure 1.
Necrotic eschar at nadroparine injection site.

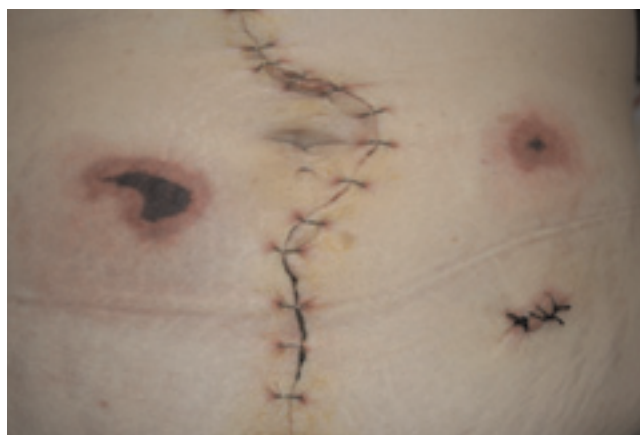


Figure 2.
Second lesion one day later at the left side of the abdomen.

represent the main risks for patients suffering from essential thrombocytosis [1,2].

Low molecular weight heparins are currently used as the standard anti-thrombotic therapy. Skin necrosis caused by LMWH is a rare complication. 24 cases have been reported up to today, and only 3 of these cases occurred during nadroparine administration [3]. All reported cases occurred on patients with concomitant thrombocytopenia (platelet count $<300,000$ cells/ml) rather than thrombocytosis, as was the case in our patient. In our case, the determination of Platelet Factor 4 (PF4)-induced antibodies tested positive on Enzyme-Linked ImmunoSorbent Assay (ELISA). Even though our patient had an increased number of platelets, an absolute or even relative decrease of the platelet count is often the only abnormality observed during routine laboratory tests in patients with LMWH-induced skin necroses.

Heparin-dependent IgG antibodies, which activate platelets via their Fc receptors, are regularly found on patients with LMWH-induced skin necroses, independent of the type of LMWH used or of whether the necroses occur locally at the injection sites or further away [4,5]. These antibodies are specific for complexes consisting of heparin and PF4, which are recognized by the antibody, resulting in antibody-mediated vascular injury [6,7]. It is believed that heparin causes platelet aggregation in vessels surrounding the site of injection, with subsequent thrombosis. The presence of fibrin thrombi in the veins and capillaries of fresh histopathological specimens lends further strength to this proposition. Histological examination of LMWH-induced skin necrosis specimens reveals microvascular thrombi in the dermal vessels with minimal inflammation and without signs of vasculitis [3].

According to current literature, skin necroses occur most of the times between the 6th and 12th day after the first injection [8]. It is possible that LMWH has a low immunogenic profile and therefore requires repeated exposure in order to lead to skin necrosis [3]. The diagnosis of heparin-induced platelet aggregation should be strongly suspected whenever necrosis occurs at an injection site. Once skin necrosis is noticed or suspected, the initial therapeutic action is to immediately stop the LMWH therapy. The administration of any other type of (fractioned or unfractioned) LMWH is not recommended, due to a well known cross reaction of the heparin-dependent antibodies amongst the above products. Should further anticoagulation be necessary, one has the option of acetyl-salicylic acid (ASA) or protamin [7,9–11]. Even though Coumarins may be used, there is a published report on coumarin-induced skin necrosis following HIT syndrome [12].

Conclusion

In conclusion, skin necrosis following subcutaneously administered low-molecular-weight heparin (LMWH) is a rare but serious complication. It represents a localized manifestation of heparin-induced platelet aggregation and thrombosis.

List of abbreviations

LMWH, Low molecular weight heparin; SGOT, Serum Glutamic Oxaloacetic transaminase; SGPT, Serum Glutamic Pyruvic Transaminase; γ GT, Gamma-glutamyl Transferase; LDH, Lactate Dehydrogenase; CRP, C-Reactive Protein; WCC, White Cell Count; HCV, Hepatitis C Virus; Ht, Hematocrit; PLT, Platelet Count; PF4, Platelet Factor 4; ASA, Acetylsalicylic Acid; HIT, Heparin-induced thrombocytopenia; Fc, Fragment, crystallizable.

Consent

Written informed consent was obtained from the patient for publication of this case report and accompanying images. A copy of the written consent is available for review by the Editor-in-Chief of this journal.

Competing interests

The author(s) declare that they have no competing interests.

Authors' contribution

MGP, SP and IK performed the patient's surgery. MGP, DK, SP and IK assessed the patient on a daily basis and observed the skin abnormalities. MGP and SP wrote the manuscript and performed the data analysis. DK performed the data collection, the image editing, the manuscript drafting and the revision. IK analyzed and interpreted the patient data and was a major contributor in revising the manuscript and giving the final approval. All authors read and approved the final manuscript.

References

1. Elliott MA, Tefferi A: **Thrombosis and haemorrhage in polycythaemia vera and essential thrombocythaemia.** *Br J Haematol* 2005, **128**:275-290.
2. Michiels JJ, Berneman Z, Bockstaele DV, van der Planken M, De Raeve H, Schroyens W: **Clinical and laboratory features, pathology of platelet-mediated thrombosis and bleeding complications and the molecular etiology of essential thrombocythemia and polycythemia vera: therapeutic implications.** *Semin Thromb Hemost.* 2006, **32**:174-207.
3. Handschin AE, Trentz O, Kock HJ, Wanner GA: **Low molecular weight heparin-induced skin necrosis - a systematic review.** *Langenbecks Archives of Surgery* 2005, **390**:249-254.
4. Tietge UJF, Schmidt HH-J, Jackel E, Trautwein C, Manns M.P: **Low molecular weight heparin-induced skin necrosis occurring distant from injection sites and without thrombocytopenia.** *Journal of Internal Medicine* 1998, **243**:313-315.
5. Santamaria A, Romani J, Souto JC, Lopez A, Mateo J, Fontcuberta J: **Skin necrosis at the injection site induced by low-molecular-weight heparin: case report and review.** *Dermatology* 1998, **196**:264-265.
6. Eika C: **Inhibition of Thrombin Induced Aggregation of Human Platelets by Heparin.** *Scand J Haematol* 1971, **8**:216.
7. Eika C: **On the Mechanism of Platelet Aggregation Induced by Heparin, Protamine and Polybrene.** *Scand J Haematol* 1972, **9**:248.
8. Ojeda E, Perez MC, Mataix R, Arbelo R, Jimenez S, Campo C, Balda I: **Skin necrosis with a low molecular weight heparin.** *Br J Haematol* 1992, **82**:620.
9. Landolfi R, Di Gennaro L, Novarese L, Patrono C: **Aspirin for the control of platelet activation and prevention of thrombosis in essential thrombocythemia and polycythemia vera: current insights and rationale for future studies.** *Semin Thromb Hemost* 2006, **32**:251-259.
10. Van Genderen PJJ, Mulder PGH, Weleboer M, Van de Moesdijk D, Michiels JJ: **Prevention and treatment of thrombotic complications in essential thrombocythaemia: efficacy and safety of aspirin.** *Br J Haematol.* 1997, **97**:179-184.
11. Griesshammer M, Bangert M, van Vliet HH, Michiels JJ: **Aspirin in essential thrombocythemia: status quo and quo vadis.** *Semin Thromb Hemost* 1997, **23**:371-377.
12. Faraci PA, Deterling RA, Stein AM: **Warfarin Induced Skin Necrosis.** *Surg Gynecol Obstet* 1978, **146**:695.

Do you have a case to share?

Submit your case report today

- Rapid peer review
- Fast publication
- PubMed indexing
- Inclusion in Cases Database

Any patient, any case, can teach us something



**CASES
NETWORK**

www.casesnetwork.com