

Radical prostatectomy specimens – a voice against focal therapy

Przemysław Adamczyk¹, Jakub Tworkiewicz¹ and Tomasz Drewna^{1,2}

¹Nicolaus Copernicus Hospital in Toruń, Department of General and Oncologic Urology, Toruń, Poland

²Regenerative Medicine Engineering Department, Collegium Medicum, Nicolaus Copernicus University, Bydgoszcz, Poland

Article history

Submitted: March 24, 2014

Accepted: June 17, 2014

Correspondence

Przemysław Adamczyk
Nicolaus Copernicus City
Hospital
Department of General
and Oncologic Urology
17/19, Batorego Street
87–100 Toruń, Poland
phone: +48 606 184 840
przemekad@poczta.
onet.pl

Introduction The main treatment methods of prostate carcinoma are surgery and radiation therapy, both having serious side effects. Because of these side effects, the idea of organ preserving therapy emerged. Rationale to perform focal therapy is to preserve the prostate gland, along with potency and continence, offering good cancer control with appropriate treatment. The idea of gland sparing therapy is quite controversial. Presently, EAU Guidelines propose focal therapy as experimental in the treatment of prostate carcinoma.

Material and methods The aim of the study was to assess how many patients could be qualified for focal therapy, according to post prostatectomy pathological findings. 720 patients suspected of prostate cancer were biopsied. In 324 patients, prostate carcinoma was revealed, of which 81 were subjected to radical prostatectomy. Pre and post-operative pathological results were analyzed, according to possible qualification for focal treatment.

Results According to the clinical evaluation of all the patients referred to the treatment, 25% could be assumed to have unifocal disease and could be qualified to the focal treatment. Post-operative evaluation revealed pT2b cancer in 5%, pT2c disease in 65%, and pT3a–pT4a disease in 20% of these patients. Cancer was unilateral (pT2a–b) in only 15% of cases, and was suitable for focal treatment (small disease not extending to whole lobe– pT2a disease) in only 10%.

Conclusions It seems that with the use of current methods, proper T-staging of the disease and amount of neoplastic tissue inside the gland can not be reached with great certainty. In our opinion, focal therapy should not be used in patients with \leq pT2b and high risk disease. For them, radical treatment (surgery or radiation therapy) should be recommended. For the rest of the patients, with low risk disease, keeping in mind the large scale of possible overtreatment, active surveillance is a valid treatment option. Focal therapy can be an interesting therapeutic proposition for a small group of patients with pT2a cancer, but it is not possible to select them with big certainty with current methods of imaging medicine.

Key Words: prostate carcinoma ◊ focal therapy

INTRODUCTION

Prostate cancer (PCa) is one of most commonly diagnosed cancers and one of leading causes of deaths in the Western world [1, 2]. Main methods of radical treatment are radical prostatectomy and radiation therapy. Both of them have important side effects and complications; therefore, the idea of focal and organ preserving therapy emerged.

Organ preserving therapy in oncologic urology is not a new issue. Not many years ago, radical nephrectomy was a gold standard method of treatment of all kidney tumors, irrespective of their size and localization. During a course of study and the development of new methods of imaging (such as the introduction of computer tomography and magnetic resonance along with ultrasonographs of better quality

of imagining), it was established that many kidney tumors can be treated in organ preserving methods. Therefore, nephron sparing surgery (NSS) was introduced into the oncologic therapy of kidney tumors and become a gold standard of treatment of small, organ limited renal tumors. The same idea was proposed in the treatment of prostate carcinoma. The idea of prostate sparing surgery with destroying only the malignant tissue emerged as a new therapeutic option. Since their development in the 1990s, focal therapies have shown increasing efficacy without the morbidities associated with more aggressive therapies [3]. It was believed that with this method, most complications and side effects of the accepted therapy were postponed, and there was good cancer control.

The idea of gland sparing therapy is quite controversial. There are many voices against, which support the idea of multifocal development of prostate carcinoma. Most studied are two methods of treatment: high-intensity focused ultrasound (HIFU) and cryosurgical ablation of the prostate (CSAP). While cryoablation is recognized by the American Association of Urology (AUA) guidelines as a valid method with good clinical background, the European Association of Urology (EAU) did not support it until recently and HIFU is still considered to be an experimental treatment. Until 2006 no results of controlled trials or survival data were published for HIFU, and no validated biochemical, surrogate end-point was available for this treatment [4].

Therefore, EAU guidelines proposes both methods as experimental in the treatment of prostate carcinoma.

In our work, we attempted to establish the presumable preoperative stage of the disease and how it corresponds with postoperative staging, as well as how many of patients treated in our department would be suitable for prostate sparing techniques.

The aim of this study was to assess the incidence and grade of prostatic carcinoma in patients undergoing biopsy for suspected PCa, with its relation to the postoperative results.

MATERIAL AND METHODS

From the period of January 2012 to December 2013, 720 patients were biopsied. The inclusion criteria were elevated PSA level (cut-off value was set at 4 ng/ml), changes found on digital rectal exam (DRE), and/or the presence of changes in the transrectal ultrasound (TRUS) image.

Patients were referred to the outpatient clinic, where with local anesthesia and prophylactic treatment of quinolone chemotherapy, a 10 core biopsy was per-

formed with a Tru-Cut Cook 18G needle and TRUS guidance. Ten specimens were most often collected, but the protocol was sometimes extended to include additional segments of areas found to be suspicious in TRUS imaging.

Histopathological evaluation of the preparations was carried out by two pathologists. The clinical TNM was assessed by combined use of DRE, histopathology, TRUS and PSA level, occasionally with the help of pelvic MRI and bone scintigraphy when M+ or N+ stage was suspected.

In the case of 324 men, prostate carcinoma was diagnosed. For all eligible patients, radical prostatectomy was proposed, and was performed in the case of 81 patients (either open-in 29 patients, or laparoscopic in 52). These patients were enrolled into the study.

Postoperative histopathologic evaluation was performed by two pathologists.

RESULTS

Biopsy

In 81 patients, prostatic carcinoma was revealed. Mean PSA value was 11.1 ng/ml (median 8.56 ng/ml). Mean age was 65.5 years, where the youngest was 49 and the oldest 77 years old. Mean BMI of patients who were operated was 27.63 kg/m² (median 27.55 kg/m²).

In 35 patients DRE was negative. Out of 46 men with positive DRE in 29 cases suspicious lesion was palpable in one lobe, and 17 in both lobes. In 66 patients, cT1c–T2c cancer was assessed. In the case of 12 patients it was cT3a, and in 3 patients it was cT3b (Figure 1). From all those referred to the treatment,

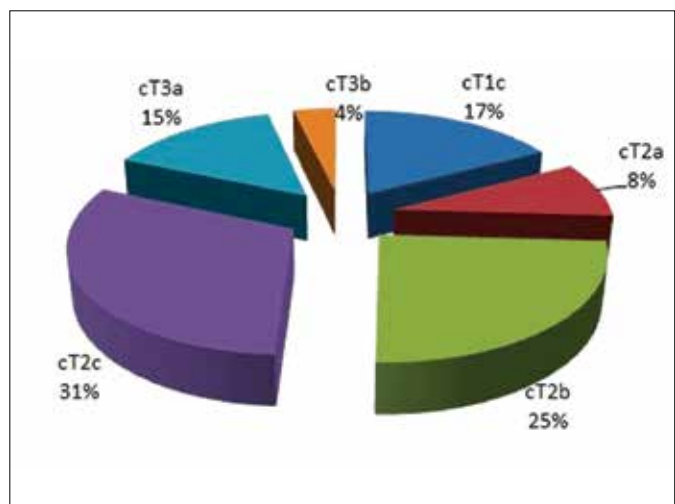


Figure 1. Clinical staging of prostate cancer before operation.

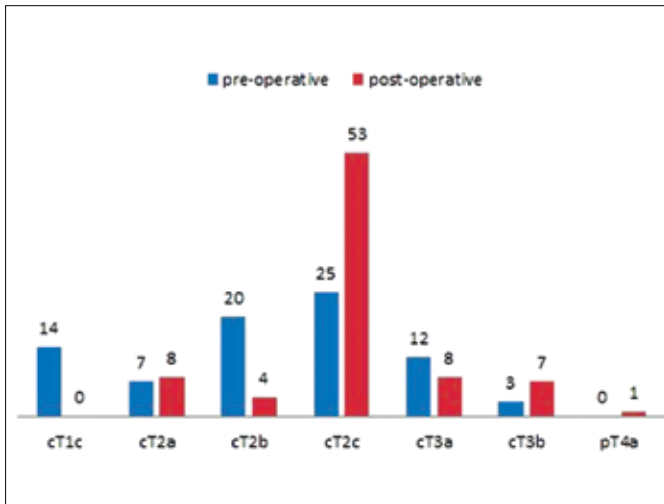


Figure 2. Gleason score of PCa found in patients during biopsy.

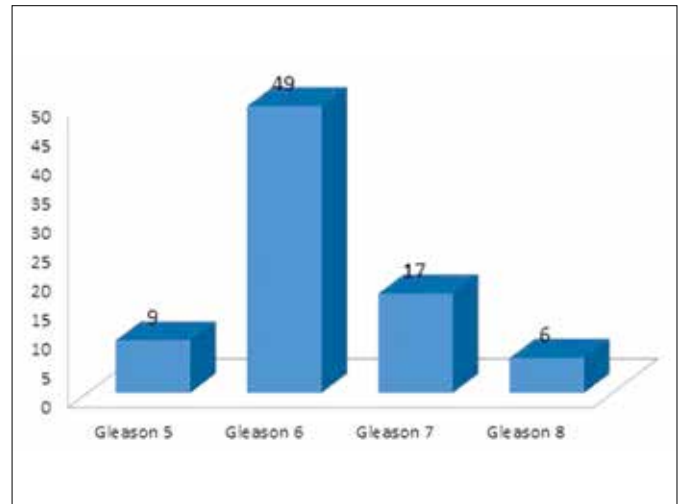


Figure 4. Histopathologic grading of the cancer found in specimen after operation.

25% could be assumed to have unifocal disease which could qualified these patients to focal treatment. In 15 patients with positive DRE, prostate carcinoma was not found during biopsy in the same lobe, but was present in the opposite side. Gleason score for all adenocarcinomas found during prostate biopsy was predominantly 6 (63%), but one patient had Gleason 4 found in biopsy specimen, and five patients had Gleason 8 (Figure 2). Of those with low Gleason score, all had positive TRUS, which qualified them to surgery.

Surgery

All patients who underwent radical prostatectomy had either open or laparoscopic surgery. 51 had

laparoscopic procedures, 8 laparoscopic procedures were converted to open, and 22 were open prostatectomies. The reasons of conversion were: in one case unexpected anatomical finding (large aneurysm of internal iliac artery, covering surface of the prostate), and in seven cases it was impossible to remove all the malignant tissue during laparoscopic procedure because of the extent of the disease. Different approaches had no influence on histopathologic outcomes.

The most common pathological outcome was pT2c disease (65%). In 20% of patients cancer extended further than presumed, and it was accounted as pT3a–pT4a disease (Figure 3). Cancer was unilateral only in 15% of post-operatively cases, and as suitable for focal treatment (small disease not extending to whole lobe– pT2a disease) only in 10%. In the majority of cases, cancer was found in both lobes and was spread largely throughout the whole prostatic tissue. Most common Gleason score was 6, (60.5% of cases), and Gleason 7 and 8 was found in 20.9% and 7.4% of patients respectively (Figure 4).

Of those 21 patients whom preoperatively could be referred to the focal treatment (assumed to present with cT1c–cT2a disease), only five (23.8%) postoperatively had unifocal disease; the rest (76.2%) postoperatively had pT2b or higher stage. Concluding, from all those referred to the radical treatment a maximum of 25% could be assumed to have unifocal disease, but it is absolutely unpredictable (Figure 5).

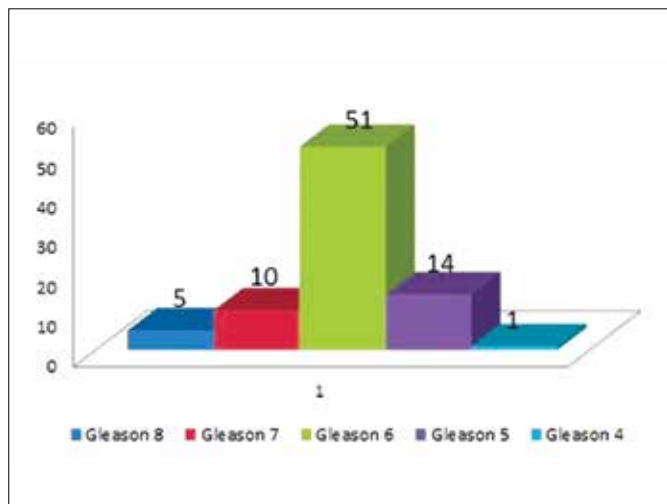


Figure 3. Histopathologic outcomes of operation.

DISCUSSION

During the last decade, focal therapy of prostate carcinoma emerged as one of the potential tools in the

treatment of the disease. Rationale to perform focal therapy is to preserve the prostate gland, along with potency and continence, offering good cancer control with appropriate treatment. However patient anxiety can still be a drawback of such treatment. Short term control rates of HIFU treatment are in the range of 55–84% [5]. Cryoablation seems to give better cancer control of 88–94% of patients (based on postoperative PSA level) [6]. On the other hand, data on this topic is quite immature and studies are ongoing. Series of patients treated by both methods are still quite small and the level and severity of side effects is still unsure. Therefore, presently focal therapy is still assumed to be an option rather than a standard treatment, according to EAU guidelines [7]. According to EAU guidelines, patients qualifying for focal therapy are those with low (PSA <10 ng/mL, \leq T2a, Gleason score <6) or moderate risk disease (PSA 10–20 ng/mL, or Gleason score 6–7) and with clinical stage of the tumor \leq cT2a) [7].

The aim of the study was to assess how many patients could be qualified for focal therapy, according to the post prostatectomy anatomopathological findings. In our study, eighty one consecutive patients treated by prostatectomy were enrolled according to the Epstein criteria [8, 9]. Of those, 10% were unifocal and 90% presented with multifocal disease for which focal therapy is not possible. From anatomopathological studies of post-prostatectomy specimens, it is known that most of the prostate carcinomas are multifocal and generally present as a spread disease throughout the whole prostate, rather than a focal disease. The higher the grade and stage of the disease, the higher the possibility of multifocal disease, even limited to the organ. It was also seen in the case of our patients that pT2c disease was most common (65%), and pT3a–b accounted for 19%. Very close results are presented by Iremashvili et al. where in 1444 prostatectomy specimens, only 72 (18.8%) were unifocal. In that paper, it was presented that the number of positive biopsy cores was slightly lower in the unifocal group, and patients in the multifocal group had higher pathologic Gleason scores, increased incidence of positive surgical margin and larger tumors [10]. It seems that prostate carcinoma grows as islands of tumor areas dispersed throughout the entire gland rather than a densely clustered tumor in a single anatomic location, in comparison with kidney cancer [11]. Therefore, in the opinion of many authors, focal therapy for prostatic carcinoma is currently more of a concept than a real treatment option [12].

If it is to be a valuable tool, it has to be applied to a very selected group of patients. It requires very precise diagnosis which would be accurate enough

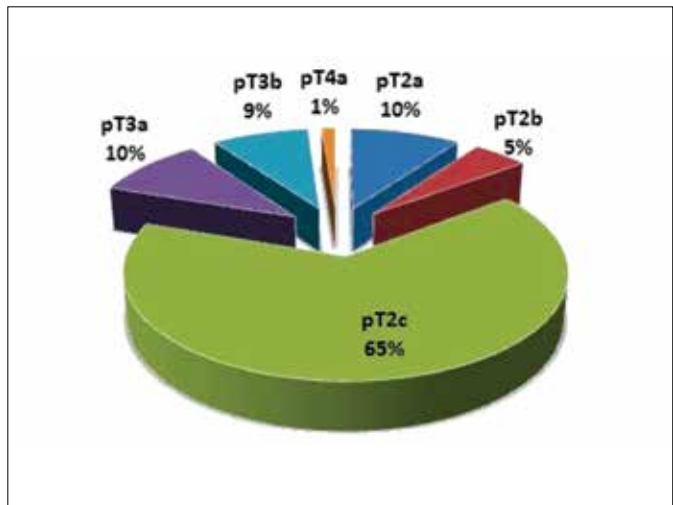


Figure 5. Clinical versus histopathological staging of prostate cancers.

to distinguish that there is only one cancer lesion in the prostate and to locate it with great precision. If such diagnostic procedures would be available, focal therapy would be used with great favor to such selected group of patients.

Some authors propose focal therapy as a treatment option to all those patients with prostate carcinoma which are not treated actively (prostatectomy, EBRT). They propose to use EBRT or prostatectomy in high and very high risk group of patients, and focal therapy in low risk (according to Epstein criteria).

In our opinion, this concept falls into the wrong path of active treatment of all patients with prostate cancer cells in biopsy specimens. PIVOT trial failed to demonstrate mortality benefit for active and aggressive treatment of prostate carcinoma. Throughout 10 years of observation, a difference between groups of patients treated actively and only observed was only 3.4%. As it is known from the PIVOT study, generally very few patients are gaining from our active treatment, and are generally those with intermediate and high risk disease. Surgically treated men with intermediate-risk tumors revealed a 31% relative reduction in all-cause mortality, as compared to those assigned to the observation group. In the group of high-risk tumors, surgery resulted in a non significant reduction in mortality of 6.7% as compared with observation group. In low-risk cancers, there was a 15% non-significant increase in mortality among men randomly assigned to radical prostatectomy, as compared with those assigned to observation [13].

Focal treatment applied to low risk disease patients would create a great number of unnecessary procedures because it would be applied to a clinically not

significant disease. In our opinion, it is not in favor of our patients and surely not cost effective. For those patients, active surveillance (for example applied by PRIAS trial) is a valid treatment option. For rest, with locally advanced disease and high risk disease, active treatment is currently the only treatment option.

Besides this, since prostate carcinoma very often grows throughout the whole prostate as a diffuse disease, and multifocal disease can not be seen by current methods of imaging, a large number of patients treated by organ preserving method would in the future require active therapy due to relapse of the disease. Most probably, the first choice for those patients would be EBRT instead of prostatectomy, since operative procedures can be challenging. This is only speculation due to the small numbers of patients treated by organ preserving method, and an even less number of those patients relapsing.

Most imaging procedures used in medicine today do not give us a precise answer if the disease is disseminated throughout whole gland or is located just in one place. CT, MRI, TRUS and others have low specificity and the decision of the type of treatment cannot be driven only based on those diagnostic tools [14, 15].

The cornerstone for the success of focal therapy is precise patient selection and proper TNM staging of the disease. By EAU guidelines, T-staging can be achieved by digital rectal examination (DRE), transrectal ultrasound (TRUS), magnetic resonance/computer tomography (MRI/CT) and prostate biopsy. Even today, radiologic imaging (both TRUS, CT and MRI), can not distinguish between malignant and benign prostatic tissue with 100% accuracy. TRUS is a very operator-dependent procedure and can visualize no more than 60% of prostate tumors. Its role was discussed in a large multi-institutional study, where TRUS was no more accurate at predicting organ-confined disease than DRE [16]. Both CT and MRI are also not able to differentiate between T2 and T3 tumors with high precision [17, 18]. Therefore, both modalities are not recommended in routine staging by EAU Guidelines [7]. Other imaging procedures such as 11-C-choline positron emission tomography (PET), endorectal MRI (e-MRI), or MR spectroscopic imaging (MRSI) are of sparse clinical use and are used mainly in very selected cases of patients or clinical studies. PET tends to underestimate the area of neoplastic growth in the prostate and has only a 70% specificity in the estimation of the clinical stage of the disease, and should not be used in routine clinical settings [19]. Most imaging procedures are highly operator-dependent, and have their limitations, such as post-biopsy hemorrhages or inflammatory changes which can lead to false clinical staging [20, 21].

Since there are problems with prostate cancer imaging, the main diagnostic method of prostatic carcinoma remains biopsy. It shows generally not only the amount of malignant tissue, but also the grade of the disease. During prostate biopsy, it is assumed that for analysis 0.01% of prostate tissue is taken (when performing 10–12 core biopsy in the prostate of the size 40 cm³). This small amount of information is interpolated to the remaining whole gland. Certainly, such approximation leads to a large scale of under and over diagnosis.

The main discriminator used in focal therapy qualification is the length of prostatic tissue in the sample. It was shown that it correlates with tumor volume, extraprostatic extension, and prognosis after prostatectomy [22, 23, 24]. Much more precise information can be gained from transperineal prostate biopsy using a template-guided approach. With the use of a 5mm frame, it was shown to be able to present small carcinoma foci of 0.2–0.5 mL with 90% certainty [25]. The biggest problem with this approach is that general anesthesia is necessary, and additional procedures have to be made in order to demonstrate correct T-staging. Therefore, classical 10–12 core prostate biopsy used in normal staging of the disease (in case of qualification to prostatectomy) should not be used in the case of focal therapy.

It can be assumed that serum PSA levels should increase with advancing stage of the disease. PSA alone is inadequate to predict the clinical stage of the disease, and it was shown that there is no direct relationship between serum PSA concentration and the clinical and pathological tumour stage [26].

When new diagnostic procedures will show their benefit in the selection of patients with localized single focal disease, focal therapy can be an interesting treatment option for prostate cancer patients. Until then, it should be reserved only to clinical trials and should not be generally proposed to patients. It seems that great success of focal therapy lies mainly on correct preoperative staging and adequate patient selection in order to maximize cancer control and minimize morbidity associated with the method. Therefore, the clue lies in the hands of diagnostic imaging.

Prostate cancer is a unexposed disease. In the absence of well-designed and repetitive methods of imaging, we have to rely on prostate biopsy findings to estimate disease extension and its aggressiveness [27]. It is sad to realize that our situation has generally not changed since 15–20 years, when PSA was introduced into the diagnosis of prostate cancer. We still expect new progress of the same quality and value as PSA assay. New imaging techniques

- invasion, Gleason score, DNA ploidy and proliferation, and preoperative serum prostate specific antigen: a report of 454 cases. *Cancer*. 2001; 91: 2196–2204.
23. Grossklaus DJ, Coffey CS, Shappell SB, Jack GS, Chang SS, Cookson MS. Percent of cancer in the biopsy set predicts pathological findings after prostatectomy. *J Urol*. 2002; 167: 2032–2035.
24. Freedland SJ, Terris MK, Csathy GS, Search Database Study Group. Preoperative model for predicting prostate specific antigen recurrence after radical prostatectomy using percent of biopsy tissue with cancer, biopsy Gleason grade and serum prostate specific antigen. *J Urol*. 2004; 171: 2215–2220.
25. Crawford ED, Wilson SS, Torkko KC, Hirano D, Stewart JS, Brammell C, et al. Clinical staging of prostate cancer: a computer-simulated study of transperineal prostate biopsy. *BJU Int*. 2005; 96: 999–1004.
26. Partin AW, Carter HB, Chan DW, Epstein JI, Oesterling JE, Rock RC, et al. Prostate specific antigen in the staging of localized prostate cancer: influence of tumour differentiation, tumour volume and benign hyperplasia. *J Urol*. 1990; 143: 747–752.
27. Polascik TJ, Mayes JM, Schroeck FR, Sun L, Madden JF, Moul JW, Mouraviev V. Patient selection for hemiablativ focal therapy of prostate cancer: variables predictive of tumor unilaterality based upon radical prostatectomy. *Cancer*. 2009; 115: 2104–2110.
28. Seitz M, Gratzke C, Schlenker B, Buchner A, Karl A, Roosen A, Singer BB, et al. Contrast-enhanced transrectal ultrasound (CE-TRUS) with cadencecontrast pulse sequence (CPS) technology for the identification of prostate cancer. *Urol Oncol*. 2009; 29: 295–301.
29. Villers A, Lemaitre L, Haffner J, Puech P. Current status of MRI for the diagnosis, staging and prognosis of prostate cancer: implications for focal therapy and active surveillance. *Curr Opin Urol*. 2009; 19: 274–282.
30. Onik G, Miessau M, Bostwick DG. Three-dimensional prostate mapping biopsy has a potentially significant impact on prostate cancer management. *J Clin Oncol*. 2009; 27: 4321–4326.
31. de la Rosette J, Ahmed H, Barentsz J, Johansen TB, Brausi M, Emberton M, et al. Focal therapy in prostate cancer – report from a consensus panel. *J Endourol*. 2010; 24: 775–780. ■