

Does ureteral access sheath have an impact on ureteral injury?

Mehmet Kazim Asutay^{1,2}, Marco Lattarulo^{2,3}, Despoina Liourdi^{2,4}, Abdulrahman Mohamed Al-Aown⁵, Konstantinos Pagonis², Noor Nedat^{2,6}, Amelia Pietropaolo^{7,8}, Esteban Emiliani^{8,9}, Evangelos Liatsikos², Panagiotis Kallidonis^{2,8}

¹Department of Urology, Sanliurfa Training and Research Hospital, Sanliurfa, Turkey, ²Department of Urology, University of Patras, ⁴Department of Internal Medicine, Ag. Andreas General Hospital, Patras, Greece, ³Department of Urology, ASST Spedali Civili di Brescia, Medical and Surgical Specialties, Radiological Sciences, and Public Health, University of Brescia, Brescia, Italy, ⁵Department of Urology, Armed Forces Hospital Southern Region, Khamis Mushait, ⁶Department of Urology, Umm Al-Qura University, Makkah, Kingdom of Saudi Arabia, ⁷Department of Urology, University Hospital Southampton NHS Foundation Trust, Southampton, United Kingdom, ⁸Young Academic Urologists-Endourology and Lithiasis Working Group, European Association of Urology, Arnhem, The Netherlands, ⁹Department of Urology, Fundacio Puigvert, Barcelona, Catalunya, Spain

Abstract

Objective: To present a well-organized review about ureteral access sheath impact on ureteral injury.

Materials and Methods: Systemic search on literature was done. Total of 3766 studies observed by two urologists and results were unified. A Prisma diagram was used for eliminating irrelevant studies and at the end of elimination process 28 studies were found eligible for this review.

Results: Not only clinical studies but also comparative experimental animal studies show that there is no significant data to claim that ureteral access sheath insertion causes more ureteral injury. Pre-stented patients were found to be at lower risk for ureteral injury. Risk of progression to ureteral injury seems to be low even if ureteral injury occurs with insertion of ureteral access sheath.

Conclusion: Summary of studies' results indicate that use of ureteral access sheath doesn't increase ureteral injury. This review may help understanding safety profile of ureteral access sheath on evidence-based level. There is not enough data to make a statement that ureteral access sheath prevents ureteral injury.

Keywords: Retrograde intrarenal surgery, ureteral access sheath, ureteral injury, ureteral stricture, ureteroscopy

Address for correspondence: Dr. Abdulrahman Al-Aown, Department of Urology, Armed Forces Hospital Southern Region, Khamis Mushait, Kingdom of Saudi Arabia.
E-mail: aown22@hotmail.com

Received: 09.10.2020, **Accepted:** 19.07.2021, **Published:** 20.01.2022.

INTRODUCTION

Ureteroscopy is a widely used surgical procedure for minimally invasive treatment of upper urinary tract stones and urothelial tumors. The introduction of flexible ureteroscopes allowed for the development of retrograde

intrarenal surgery (RIRS) which has been widely adopted in the endourological armamentarium. There is a controversy on literature about whether to use or not to routinely use ureteral access sheaths (UASs) during the performance of RIRS. UASs are useful for urologic procedures that need

This is an open access journal, and articles are distributed under the terms of the Creative Commons Attribution-NonCommercial-ShareAlike 4.0 License, which allows others to remix, tweak, and build upon the work non-commercially, as long as appropriate credit is given and the new creations are licensed under the identical terms.

For reprints contact: WKHLRPMedknow_reprints@wolterskluwer.com

How to cite this article: Asutay MK, Lattarulo M, Liourdi D, Al-Aown A, Pagonis K, Nedat N, *et al.* Does ureteral access sheath have an impact on ureteral injury? *Urol Ann* 2022;14:1-7.

Access this article online	
Quick Response Code:	Website: www.urologyannals.com
	DOI: 10.4103/UA.UA_163_20

multiple ureteroscope entries. Moreover, the presence of the UAS may improve irrigation conditions resulting in improved intraoperative visualization while keeping intrarenal pressure and irrigation fluid temperature within safety limits. The use of UAS may improve operative times and stone-free rates. Nonetheless, UASs may also increase the complication rates by injuring directly the organ or by inducing ureteral ischemia.

The objective of this review is to present an updated evidence on the use of UASs and to clarify any possible relation with ureteral wall injuries and related complications such as ureteral stricture.

MATERIALS AND METHODS

A systematic review of the literature was conducted according to the requirements of the PRISMA statement.^[1,2]

The database search (January 2019) included PubMed, SCOPUS, Cochrane, Embase, and Web of Science. There was no restriction for language and year of publication. Manual search was also acceptable. The search keywords included ureter, ureteral, ureteric, ureteros* (ureter in Greek language), and sheath.

Eligibility criteria for the articles to be included in this review were prospective studies (randomized or quasi-randomized), nonrandomized prospective, or retrospective studies comparing the clinical outcome with the use of UAS and without its use in ureteroscopy and experimental studies evaluating parameters related to the use of UAS for ureteroscopy. Primary endpoint was ureteral wall injury related to the use of UASs and their prevention.

Two independent reviewers eliminated irrelevant studies according to PRISMA recommendations. Any discrepancies were solved with the aid of the senior author. The reviewers extracted any relative information from the eligible articles according to a standardized pro forma.

RESULTS

Three thousand seven hundred and sixty-six studies were identified with the literature search resulting in 3121 items after the exclusion of duplicates. PRISMA diagram is presented in Figure 1. A total number of 28 studies were eligible for the current review. Six of these studies were animal experiments. There were 22 clinical studies, 2 for pediatric, and 20 for adult patients. Thirteen clinical studies were prospective in nature.

Experimental animal studies

UASs have been proposed to facilitate flexible ureteroscopy in the treatment of urolithiasis. UASs allow multiple pass of ureteroscope, reduce operative times, and improve visualization. Moreover, the use of UAS decreases intrarenal pressure levels which could be related to renal damage.^[3] On the other hand, any ureteral injury related to the use of a UAS may be related to chronic effects.

In the current systematic review, 3 of the experimental animal studies were investigating the changes that UAS insertion induces on the cellular microenvironment of the ureter [Table 1]. Two studies showed that the insertion of UAS increased the fibroblastic precursors.^[4,5] The one study was performed in a rabbit model, either 2 or 3 Fr ureteral catheter was introduced to ureter for 1–4 h. The fibrotic activity in the ureters was investigated after a month.^[4] Seventy-two ureter units were investigated. Longer catheterization time and increased diameter of catheter were found to be associated with increased fibrotic activity. The other study included 22 pigs, a 13–15 Fr UAS was inserted either for 2 min or for 2 h. The ureteral COX-2 and TNF-alpha levels were analyzed.^[5] Higher proinflammatory mediators were found to be related to the presence of the UAS and longer indwelling periods (2 h).

On the contrary, a study with porcine model showed that despite the presence of inflammation on early postoperative period, there was no chronic histological effect.^[6] 9.5/11.5 Fr UAS was inserted to pig ureters and left for variable time periods ranging from 2 min to 2 h. Histological evaluation was performed in specimens removed immediately, 1 week, and 2 weeks after the intervention. No chronic inflammation was observed. Signs of acute inflammation were evident in immediately harvested tissue samples but not in the specimens at 2 weeks.

Ureteral ischemia due to the use of UAS was investigated in a swine animal model study.^[7] Ureteral blood flow was measured in ureters with indwelling UASs with a size of 10/12Fr, 12/14 Fr, and 14/16 Fr and a control group (non--UAS). There was more than 50% decrease in baseline ureteral blood flow when larger UASs were used. There was no evidence of histologic damage at 72 h, and there were no ureteral injuries. Nonetheless, there was no evidence on the chronic effects of ureteral blood flow decrease in the ureteral anatomy, histology, or physiology. In another study, the insertion forces of a UAS on *ex vivo* porcine ureter were measured with and without safety guidewire.^[8] The results showed that the use of a safety guidewire increased the insertion forces but there was no significant difference in rates of ureteral injury.

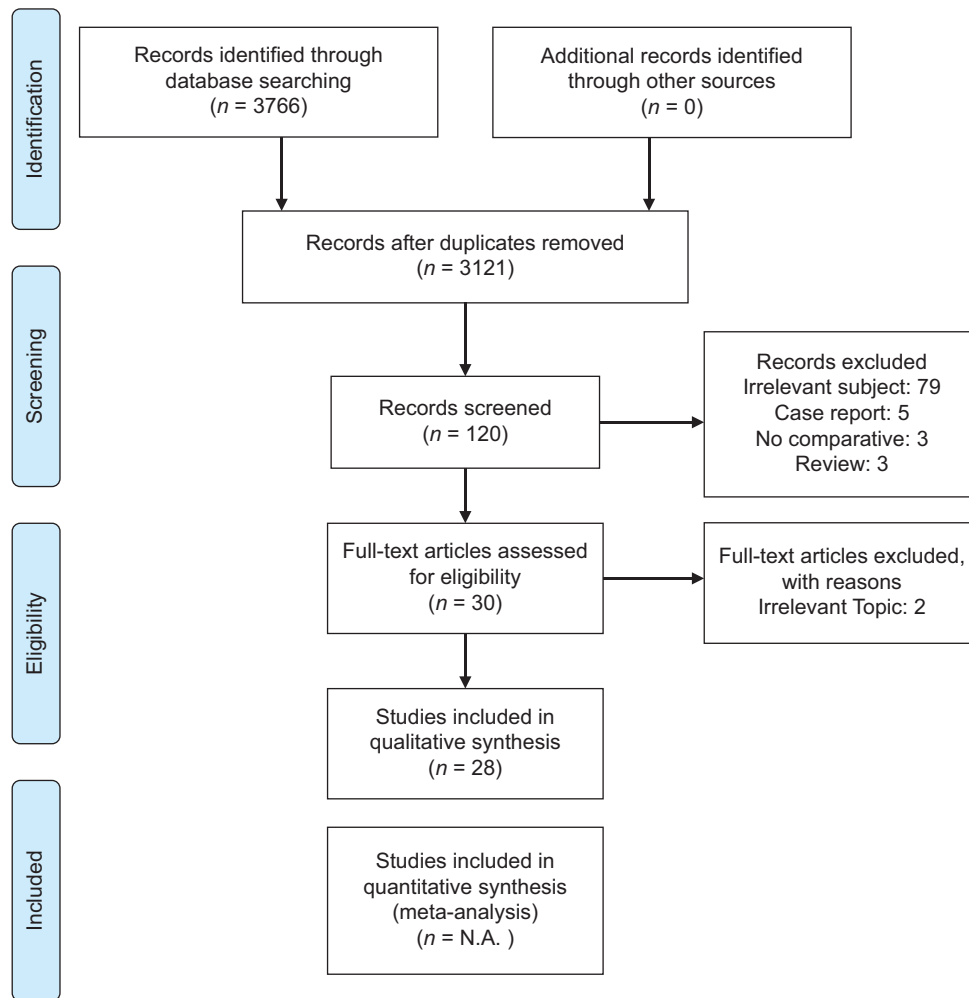


Figure 1: PRISMA Diagram used in literature review

An interesting perspective was evaluated by Lildal *et al.* in a prospective comparative blinded study in porcine model.^[9] The authors investigated if the use of topical beta-blockers (isoproterenol) could decrease ureteral injuries related to the use of UAS.^[10] Isoproterenol solution was compared to saline solution (control). The isoproterenol solution ureteral injury rates were less than those of the saline group, but the statistical analysis was inconclusive.

Clinical studies about stricture formation and grading systems

Sixteen out of 28 studies included in the current review provided information on the safety of UAS [Table 2]. Most of the studies used the ureteral injury scale proposed by Traxer *et al.* in an attempt to classify the level of ureteral injury.^[11] A retrospective cohort with 165 patients compared the efficacy and safety of the 9.5/11 Fr to the 12/14 Fr UAS. None of the patients were previously stented.^[12] Mean follow-up time was 115 days. None of the patients developed a ureteral stricture. Even the use of wider UASs was not related to the formation of strictures.

Pardalidis *et al.* in a prospective randomized study compared the use of a UAS or ureteral balloon dilatation for the facilitation of the access to distal ureteral stones.^[13] 98 patients were totally included. Ureteral perforation was seen in 8% of patients after balloon dilatation while there were no ureteral perforations in the case of the UAS group ($P < 0.05$). Complication rates were lower with the use of UAS, and the operative time was shorter in comparison to the balloon dilatation (45.5 vs. 58.5 min). Strictures were not encountered in any of the group after 1 year of follow-up.

Data from 359 consecutive patients, who had RIRS with the use of a UAS, were retrospectively analyzed by Traxer *et al.*, and new classification for severity of ureteral injury was proposed (the Traxer ureteral injury classification).^[11,14] Among the 359 patients, 167 (46.5%) had a ureteral injury. Forty eight (13.3%) of these patients had severe ureteral injuries including not only the mucosa but also the muscle layers or even the serosa. The risk of ureteral injury for patients without previous stent placement was found to be 7 times more than

Table 1: Animal studies about the safety of ureteral access sheaths

	Study type	Comparison	Result	P
Lallas <i>et al.</i>	<i>In vivo</i> porcine	Ureteral blood flow for different size of UAS	No significant difference	>0.05
Graversen <i>et al.</i>	<i>Ex vivo</i> porcine	Injury rates of UAS with and without safety wire	No significant difference	1
Gucuk <i>et al.</i>	<i>In vivo</i> rabbit	FGF-2 levels on UAS model	Higher FGF-2 levels with larger catheter	<0.05
Lildal <i>et al.</i>	<i>In vivo</i> porcine	COX-2 and TNF-a levels and histologic analysis after UAS insertion	Higher COX-2 and TNF-a with larger UAS and with longer duration	<0.05
Ozsoy <i>et al.</i>	<i>In vivo</i> porcine	Early and late histologic changes after insertion of UAS	Early acute inflammation, no late chronic change	NA
Lildal <i>et al.</i>	<i>In vivo</i> porcine	Effect of beta-agonists on UAS insertion force	Easier to insert UAS with beta agonist irrigation solution	0.8

UAS: Ureteral access sheaths, NA: Not applicable, FGF-2: Fibroblast growth factor-2, TNF-a: Tumor necrosis factor-alpha, COX: Cyclooxygenase-2

Table 2: Studies compare ureteral access sheath injury/complication rates

	Study type	Comparison	Result	P
Kourambas <i>et al.</i>	Retrospective	Complications with or without ureteral access sheath on RIRS patients	No significant difference	>0.05
Barboour <i>et al.</i>	Retrospective	Hydronephrosis on follow-up with or without UAS RIRS	No significant difference	>0.05
Bas <i>et al.</i>	Retrospective	Complications after RIRS for proximal ureteral and renal stones with or without UAS	No significant difference	>0.05
Lildal <i>et al.</i>	Retrospective	Comparison of ureteral lesions with 10/12Fr UAS or larger size UAS or without UAS	More superficial ureteral injury lesions seen with UAS	<0.05
Tefik <i>et al.</i>	Cohort-prospective	UAS injuries; presented patients versus others	Less UAS-related injury in preintended patients	NA
Traxer <i>et al.</i>	Prospective	Factors that have an impact on UAS	Preintended patients have a lower risk for UAS injury	<0.0001
Stoller <i>et al.</i>	Retrospective	Stricture formation with different sizes of UAS on RIRS	No difference	NA
Tracy <i>et al.</i>	Retrospective	Comparison of ureteral lesions with 10/12Fr, 12/14Fr, and 14/16 Fr UAS or without UAS	No significant difference	0.87
Parpadilis <i>et al.</i>	Retrospective	UAS compared to balloon dilatation for distal ureteral stones	Significant lower ureteral perforation with UAS	<0.05
Gorin <i>et al.</i>	Retrospective	UAS for endoscopic treatment of upper urinary urothelial tumors	No complication rates	NA
Stern <i>et al.</i>	Prospective	Stricture rates on intermediate term follow-up after RIRS with UAS	Low probability for stricture progression	NA
Multescu <i>et al.</i>	Prospective	RIRS for renal stones with or without UAS	Similar complication rates	0.44
Cooper <i>et al.</i>	Retrospective	Impact on UAS on postoperative hydronephrosis	No significant difference	>0.05
Geraghty <i>et al.</i>	Prospective	RIRS for renal stones with UAS versus without UAS. Complication rates	No significant difference	0.82
Loftus <i>et al.</i>	Prospective	Two different types of UAS, access rates, and injury rates	No difference between two UAS	0.42

RIRS: Retrograde intrarenal surgery, UAS: Ureteral access sheaths, NA: Not applicable

Table 3: Studies about insertion of ureteral access sheaths with or after ureteroscopy

	Study type	Complication rates	P value for comparison of ureteral injury
Karabulut <i>et al.</i>	Retrospective	No significant difference of complications under direct vision	0.079
Boulalas <i>et al.</i>	Prospective	Significant lower injury rates with UAS when preoperative assessment of ureter is done with ureteroscopy	<0.05
Hu <i>et al.</i>	Retrospective	No injuries	NA
Sonmez <i>et al.</i>	Retrospective	Significantly less injuries under visual insertion of UAS	0.032

UAS: Ureteral access sheaths, NA: Not applicable

preintended patients. Male patients and older patients had higher rates of high-grade injuries. A comparison of injuries according to UAS size was not reported. Although ureteral lesions after insertion of UAS were not rare, presenting was a very important factor for decreasing the injury rates.

In a prospective study, data from patients who underwent RIRS surgery with or without the use of UAS was compared.^[15] All cases had stones >2 cm. A UAS was used in 58.8% of cases. The UAS was not inserted if surgeon defined ureter as “too narrow to insert a UAS.” Follow-up

time after surgery was ranged between 2 and 3 months and did not reveal ureteral strictures. Another interesting point of the study was that there is no significant impact of UAS use on complication rates ($P = 0.82$).

A recent prospective study investigated the possible correlation of high-grade ureteral injuries after UAS insertion to the formation of a stricture.^[16] High-grade injuries after RIRS surgery were observed in 56 (12.5%) out of 446 patients. Median follow-up was 35.8 months. Strictures were observed in only 3 (5.6%) cases. The authors

concluded that the severity of the ureteral injury was not related to ureteral stricture progression. Nonetheless, the short duration of postoperative double-J stent indwelling time (median: 16 days, 1–48 days) was correlated to the formation of a stricture but it remained statistically insignificant ($P = 0.11$).

In a retrospective comparative study, 126 patients and 111 patients underwent RIRS with the use of 10/12Fr UAS and without any UAS, respectively.^[17] There was no significant difference in the rates of ureteral wall injury among the groups. Only one patient had Grade 3 (0.8%) ureteral wall injury related to UAS and there was no Grade 4 injury. Only one patient had ureterovesical stricture after a follow-up period of 18 months. Moreover, higher grades of ureteral injury were more common in group that UAS was not used. Septic complications were observed in 28.7% and 68.3% of the cases with and without the use of a UAS ($P = 0.034$). The authors advocated that the use of UAS was not only safe but also provided better view with less septic complications probably due to the lower internal pressure.

In a prospective randomized study, 47 patients who did not need ureteral dilatation were enrolled. 23 (49%) of the patients underwent ureteroscopy with the use of UAS and 24 (51%) of cases were treated without a UAS and with dilation of the ureter with a balloon.^[18] There was no significant difference between groups in terms of symptoms, complication rates, or stone-free status in the UAS and non-UAS groups.

Operative time was shorter, and costs were lower in UAS group in comparison to the balloon dilation group. There were significantly more postoperative symptoms in patients to whom ureteral dilation was done by balloon dilatation rather than using UAS.

Two retrospective studies investigated the incidence of stricture formation after UAS insertion and provided similar results. Stricture rates with the use of UAS were between 0.9% and 1.4%. Considering that the stricture rate of the cases not managed by the use of a UAS was not higher than the cases without any UAS use, a UAS during RIRS should not be considered as a contributing factor for ureteral stricture formation.^[19,20] On the contrary, another retrospective study showed higher ureteral lesion rates when a 10/12Fr UAS was used in comparison to cases that a UAS was not used.^[9] Odds ratio for the ureteral lesion after the use of UAS was 1.84, but after adjusting age and gender data, the comparative outcomes were statistically insignificant.

A retrospective study investigated 1332 URS cases at 8 weeks after the procedure.^[21] Data from 1060 patients who returned for routine upper tract imaging were evaluated. Postoperative hydronephrosis was noted on 12% of patients. Low body mass index ($P = 0.0016$), greater stone size ($P = 0.0003$), increased operative time ($P < 0.0001$), preoperative ureteral stent placement ($P = 0.0299$), and postoperative ureteral stent placement ($P = 0.0031$) were factors predicting for postoperative hydronephrosis.

Considering the above evidence, a brief conclusion regarding the safety of UAS could be made. It seems that the use of UASs did not have a significant impact on the development of postoperative ureteral strictures. The routine use of a UAS during RIRS seems to be safe. Postoperative follow-up with ultrasound is important to detect cases with ureteral stricture formation.

Technique for optimal insertion of ureteral access sheath

Two of the clinical studies of the current review compared the insertion of the UAS fluoroscopically over a safety wire or under direct vision with the use of a semirigid ureteroscope.^[22,23] Specifically, Hu *et al.* presented an observational study including 81 upper ureteral stone cases.^[22] The UAS was inserted under direct vision with a 6F semirigid ureteroscope. Stone-free rate was 100% and no major complications were seen over a 2-month follow-up period. In another study, 84 RIRS cases were prospectively investigated. The patients were divided into two groups: in the first group, a UAS was inserted over a safety guidewire whereas in the second group, a UAS was inserted under direct vision (outer part of UAS was worn on semirigid ureteroscope).^[23] Follow-up time was 1 month. Fluoroscopy screening time, UAS placement time, and operation time were significantly shorter in the second group. Complications were classified according to Traxer ureteral injury classification system. A total of 16.6% of patients had Grades 1 and 2 ureteral injury. There were no major complications. Follow-up period ranged between 2 and 3 months. The complication rate was found higher in over-the-wire technique group, but the results were not statistically significant ($P = 0.079$). The only significant advantage of the direct vision insertion of UAS was the shorter operative and fluoroscopy times during insertion of UAS (58.7 and 51.2 min, 11.7 and 0 min, respectively) in comparison to the over-the-wire approach. Insertion of the UAS under direct vision of semirigid ureteroscope was studied in another retrospective study.^[24] There were 19 patients on direct vision UAS group and 22 patients in classic fluoroscopic insertion group. Results show that insertion of UAS under direct vision had significantly less ureteral injury complications and less fluoroscopy time.

To provide clues for the optimal safety of UASs, Boulalas *et al.* compared two groups of patients undergoing RIRS.^[25] Hundred consecutive patients were included in the study, 77% of patients had “compliant ureter” which represented ureters eligible for 12/14 Fr UAS insertion. A semirigid ureteroscopy was done before the UAS insertion to inspect the ureter and estimate if the lumen of the ureter was compatible with 14 Fr or greater in diameter UAS. If ureter did not seem compliant, a smaller diameter UAS or non-UAS at all was used. This approach is used in all the patients, and the complication rates were 10%. Most of them were Grade 1 ureteral injuries. Ureteral complications such as stricture formation were significantly lower if the patient had a complaint of ureter.

Lokus *et al.* performed ureteroscopy by using two different types of UAS in a randomized trial including 95 patients; Cook Flexor or Boston Scientific Navigator both with a diameter of 12/14 Fr were used.^[26] Ureteroscopy was done for the treatment of urinary stones. Thirty percent of the patients had stones located in the kidney, 63% in the ureter, and 7% of patients had both ureteral and kidney stones. There was no difference between two different types of UAS in terms of ureteral injury rates. Large stone burden, male gender, longer time of sheath insertion, and when the surgeon felt resistance to insert UAS were associated with high-grade (Grade 2 or 3) ureteral injury ($P = 0.018$). Grade 0 (no injury) and Grade 1 injuries were seen on 76.2% of patients compared to 23.8% for high-grade (Grades 2 and 3) injuries.

Considering the above studies, it is unclear that is the optimal method for the insertion of UASs in terms of significant differences in ureteral injury rates [Table 3].

Impact of insertion force

On a small group of patients ($n = 7$), the magnitude of the insertion forces of UAS with different diameters was measured.^[27] Treated stones had a maximal diameter between 10 and 24 mm. Stones were located either at renal calyx or ureteropelvic junction. Stricture formation was followed up by urinary ultrasound imaging and further investigated if there was hydronephrosis. Although the follow-up period was not clearly mentioned, there was no stricture formation in any of the patients. The authors concluded that the magnitude of the needed force to insert the UAS was lower when patients were pre-stented.

Impact of the size of ureteral access sheath

A retrospective study by Stoller *et al.* classified ureteral injuries according to UAS size.^[28] 71 cases of RIRS were included. A 12/14 Fr UAS was used on 56 (78.9%) cases, a

10/12 Fr UAS was used on 8 (11.2%), and 14/16 Fr UAS was used on 7 (9.8%). Only one patient had a stricture at the ureteropelvic junction. This complication was considered as unrelated to the UAS since the stricture site was above the level of UAS insertion. Although the comparison of different sizes of UASs can provide clues on the relation of UAS to ureteral injury, there is not a control group and the ureteral injury rates after the surgery were not reported.

A retrospective study investigated 257 RIRS patients who were treated with either a 12/14 Fr UAS or a 14/16 Fr UAS or without any UAS.^[29] The study attempted to evaluate a possible correlation of a larger UAS size to higher rates of ureteral injury. There was no significant difference in the ureteral injury between any of the groups. Stone burden treated per minute was higher in 14/16 Fr group in comparison to the other groups and it was the only statistically significant parameter.

Treatment of upper urinary tract tumors

Gorin *et al.* investigated the safety profile of UAS in the treatment of upper tract urothelial carcinomas (UTUC).^[30] RIRS with the use of a UAS for the diagnosis and treatment of upper urinary tract tumors was performed in 64 patients. UAS was used if there were no previous strictures in semirigid ureteroscopy. Brand of the UAS was mentioned but the size of UAS and follow-up periods were not clearly mentioned. No strictures were reported during the follow-up. The investigators concluded that the use of UAS in UTUC cases was safe and associated with low complication rates.

Pediatric population

Berrejni *et al.* performed 16 RIRS cases on 13 pediatric patients who had a bodyweight <20 kg. All patients were stented 2 weeks before surgery.^[31] 9.5/11.5 Fr size UAS was used in all cases. During the follow-up period which extended up to a year, ureteral strictures or any chronic complication implicating ureteral wall injury was not observed. The authors concluded that RIRS with UAS insertion seemed to be a safe even for preschool children. Anbarasan *et al.* reported the results of RIRS in 21 pediatric patients (school age, <16 years of age) in a retrospective study. Mean follow-up of patients was 26 months.^[32] Cases treated with the use of 9.5F UAS were not related to long-term complications.

CONCLUSION

UASs cannot be directly related to ureteral injury according to the current evidence. Pre-stented patients seem to have a lower risk for ureteral injuries; and even if ureteral injuries occur, the probability of progression to chronic ureteral stricture seems to be low.

Financial support and sponsorship

Nil.

Conflicts of interest

There are no conflicts of interest.

REFERENCES

- Moher D, Liberati A, Tetzlaff J, Altman DG, The PG. Preferred Reporting Items for Systematic Reviews and Meta-Analyses: The PRISMA Statement. *PLOS Medicine* 2009;6:e1000097.
- Antes G, von Elm E. [The PRISMA Statement - what should be reported about systematic reviews?]. *Dtsch Med Wochenschr* 2009;134:1619.
- Patel N, Monga M. Ureteral access sheaths: a comprehensive comparison of physical and mechanical properties. *Int Braz J Urol* 2018;44:524-35.
- Gucuk A, Soyler G, Uyeturk U, Yilmaz B, Nalbant I, Gucuk S, et al. Does ureteral access sheath usage lead to permanent damage in the ureter? A placebo controlled trial in a rabbit model. *Acta Cir Bras* 2018;33:408-14.
- Lildal SK, Norregaard R, Andreassen KH, Christiansen FE, Jung H, Pedersen MR, et al. Ureteral Access Sheath Influence on the Ureteral Wall Evaluated by Cyclooxygenase-2 and Tumor Necrosis Factor-alpha in a Porcine Model. *J Endourol* 2017;31:307-13.
- Ozsoy M, Kyriazis I, Vrettos T, Kotsiris D, Ntasiotis P, Seitz C, et al. Histological changes caused by the prolonged placement of ureteral access sheaths: an experimental study in porcine model. *Urolithiasis* 2018;46:397-404.
- Lallas CD, Auge BK, Raj GV, Santa-Cruz R, Madden JF, Preminger GM. Laser Doppler flowmetric determination of ureteral blood flow after ureteral access sheath placement. *Journal of Endourology* 2002;16:583-90.
- Graversen JA, Valderrama OM, Korets R, Mues AC, Landman J, Badani KK, et al. The effect of extraluminal safety wires on ureteral injury and insertion force of ureteral access sheaths: Evaluation using an ex vivo porcine model. *Urology* 2012;79:1011-4.
- Lildal SK, Andreassen KH, Jung H, Pedersen MR, Osther PJS. Evaluation of ureteral lesions in ureterorenoscopy: impact of access sheath use. *Scand J Urol* 2018;52:157-61.
- Lildal SK, Andreassen KH, Christiansen FE, Jung H, Pedersen MR, Osther PJS. Pharmacological Relaxation of the Ureter When Using Ureteral Access Sheaths during Ureterorenoscopy: A Randomized Feasibility Study in a Porcine Model. *Advances in Urology* 2016;2016.
- Traxer O, Thomas A. Prospective evaluation and classification of ureteral wall injuries resulting from insertion of a ureteral access sheath during retrograde intrarenal surgery. *J Urol* 2013;189:580-4.
- Shvero A, Herzberg H, Zilberman D, Mor Y, Winkler H, Kleinmann N. Is it safe to use a ureteral access sheath in an unstented ureter? *BMC Urol* 2019;19:80.
- Pardalidis NP, Papatouris AG, Kapotis CG, Kosmaoglou EV. Treatment of impacted lower third ureteral stones with the use of the ureteral access sheath. *Urological Research* 2006;34:211-4.
- De Coninck V, Keller EX, Rodriguez-Monsalve M, Audouin M, Doizi S, Traxer O. Systematic review of ureteral access sheaths: facts and myths. *BJU Int* 2018;122:959-69.
- Geraghty RM, Ishii H, Somani BK. Outcomes of flexible ureteroscopy and laser fragmentation for treatment of large renal stones with and without the use of ureteral access sheaths: Results from a university hospital with a review of literature. *Scand J Urol* 2016;50:216-9.
- Stern KL, Loftus CJ, Doizi S, Traxer O, Monga M. A prospective study analyzing the association between high-grade ureteral access sheath injuries and the formation of ureteral strictures. *Urology* 2019.
- Mulțescu R, Geavlete B, Satalan R, Georgescu D, Geavlete P. Ureteral access sheath during retrograde flexible uretero-rensoscopy: Safe tool or safety hazard? *Journal of Translational Medicine and Research* 2015;20:138-41.
- Kourambas J, Byrne RR, Preminger GM. Dose a ureteral access sheath facilitate ureteroscopy? *Journal of Urology* 2001;165:789-93.
- Barbour ML, Raman JD. Incidence and Predictors for Ipsilateral Hydronephrosis Following Ureteroscopic Lithotripsy. *Urology* 2015;86:465-71.
- Bas O, Tuygun C, Dede O, Sari S, Cakici MC, Ozturk U, et al. Factors affecting complication rates of retrograde flexible ureterorenoscopy: analysis of 1571 procedures-a single-center experience. *World J Urol* 2017;35:819-26.
- Cooper JL, Francois N, Sourial MW, Miyagi H, Rose JR, Shields J, et al. The impact of ureteral access sheath use on the development of abnormal postoperative upper tract imaging after ureteroscopy. *J Urol* 2020;204.5: 976-981.
- Hu JS, Xie GH, Yuan HS, Liu GL, Jia XL, Zheng Z, et al. Guide sheath-assisted ureteroscopy lithotripsy for upper ureteral calculi: An observational study on 81 cases. *Exp Ther Med* 2018;16:3459-63.
- Karabulut I, Keskin E, Bedir F, Yilmazel FK, Ziyapak T, Doluoglu OG, et al. Rigid Ureteroscope Aided Insertion of Ureteral Access Sheath in Retrograde Intrarenal Surgery. *Urology* 2016;91:222-5.
- Sonmez MG, Kara C. A new approach in ureteral access sheath locating in retrograde intrarenal surgery (RIRS) by endovisional technique. *Arch Ital Urol Androl* 2016;87:286-90.
- Boulalas I, De Dominicis M, Defidio L. Semirigid ureteroscopy prior retrograde intrarenal surgery (RIRS) helps to select the right ureteral access sheath. *Arch Ital Urol Androl* 2018;90:20-4.
- Loftus CJ, Ganesan V, Traxer O, Schold JD, Noble M, Sivalingam S, et al. Ureteral wall injury with ureteral access sheaths: A randomized prospective trial. *J Endourol* 2020;34.9:932-936.
- Tefik T, Buttice S, Somani B, Erdem S, Oktar T, Ozcan F, et al. Impact of ureteral access sheath force of insertion on ureteral trauma: In vivo preliminary study with 7 patients. *Ulus Travma Acil Cerrahi Derg* 2018;24:514-20.
- Stoller ML, Meng MV, Delvecchio FC, Preminger GM. Assessment of stricture formation with the ureteral access sheath. *Urology* 2003;61:522.
- Tracy CR, Ghareeb GM, Paul CJ, Brooks NA. Increasing the size of ureteral access sheath during retrograde intrarenal surgery improves surgical efficiency without increasing complications. *World J Urol* 2018;36:971-8.
- Gorin MA, Santos Cortes JA, Kyle CC, Carey RI, Bird VG. Initial clinical experience with use of ureteral access sheaths in the diagnosis and treatment of upper tract urothelial carcinoma. *Urology* 2011;78:523-7.
- Berrettini A, Boeri L, Montanari E, Mogiatti M, Acquati P, De Lorenzis E, et al. Retrograde intrarenal surgery using ureteral access sheaths is a safe and effective treatment for renal stones in children weighing <20 kg. *Journal of Pediatric Urology* 2018;14:59.e1-e6.
- Anbarasan R, Griffin SJ, Somani BK. Outcomes and Long-Term Follow-Up with the Use of Ureteral Access Sheath for Pediatric Ureteroscopy and Stone Treatment: Results from a Tertiary Endourology Center. *J Endourol* 2019;33:79-83.