


CASE REPORT

An unusual presentation of brucellosis: hepatic microabscesses

Ilknur Erdem¹ , Ritvan Kara Ali¹, Senay Elbasan¹, Omer Ozcaglayan², Pelin Osanmaz Degirmenci³, Samet Sedef³ & Aynur Eren Topkaya⁴

¹Department of Infectious Diseases, Faculty of Medicine, Namik Kemal University, Tekirdag, Turkey

²Department of Radiology, Faculty of Medicine, Namik Kemal University, Tekirdag, Turkey

³Department of Internal Medicine, Faculty of Medicine, Namik Kemal University, Tekirdag, Turkey

⁴Department of Medical Microbiology, Faculty of Medicine, Namik Kemal University, Tekirdag, Turkey

Correspondence

Ilknur Erdem, Department of Infectious Diseases, Faculty of Medicine, Namik Kemal University, Tekirdag, Turkey.
Tel: 90 216 306578; Fax: 90 216 310 6578;
E-mail: ilknurerdem@hotmail.com

Funding Information

No sources of funding were declared for this study.

Received: 9 February 2016; Revised: 9 May 2016; Accepted: 16 November 2016

Clinical Case Reports 2017; 5(3): 229–231

doi: 10.1002/ccr3.810

Introduction

Brucellosis is a systemic infection that may affect any organ or system of the human body. Hepatic involvement is frequent in both acute and chronic brucellosis. Usually, a slight increase in the liver function tests and mild hepatosplenomegaly occur, and sometimes, acute hepatitis develops, but hepatic abscess is a rare manifestation of that disease [1–3]. This report describes a hepatic microabscesses probably due to brucellosis in a 33-year-old woman.

Case Report

A 33-year-old woman was admitted to our university hospital with the complaints of temperature up to 40°C, headache, nausea, and weakness for 2 weeks. She had a history of raising livestock and lived in rural area. On physical examination, there was no abnormal finding except right upper quadrant mild tenderness. The laboratory data were as follows: total leukocyte count, 5600/

Key Clinical Message

Hepatic abscess due to *Brucella* species is an extremely rare complication especially in acute illness. Here, we report a case of hepatic microabscesses probably caused by *Brucella* in a 33-year-old woman with acute infection who was successfully treated with a combination of doxycycline and rifampicin for 3 months.

Keywords

Brucellosis, hepatic abscess

mm³ (4000–10,000/mm³); differential leukocyte count: neutrophils, 54%; lymphocytes, 36%; monocytes, 8%; basophils, 0.3%; eosinophils, 1.7%; platelets, 285,000/mm³ (normal range: 150,000–450,000/mm³); hemoglobin, 12 g/dL; hematocrit, 36.6%; serum alanine transferase (ALT), 242 U/L (RR 0–35 IU/L); serum aspartate transferase (AST), 162 U/L (RR 0–32 IU/L); serum γ -glutamyl transpeptidase (γ -GTP), 60 U/L (RR 0–40 IU/L); alkaline phosphatase (ALP), 95 IU/mL (RR 35–114 IU/L); total bilirubin, 0.4 mg/dL (RR 0–1.2 mg/dL); sedimentation rate, 17 mm/h; and C-reactive protein, 11.3 mg/L (RR 0–5 mg/L). Viral hepatitis markers (the HBsAg, anti-HBc IgM, anti-HAV IgM, and anti-HCV tests) were negative. The *Brucella* standard tube agglutination test was positive at a titer of 1:1280. Abdominal ultrasonography showed multiple small echogenic foci are more prominent in the right lobe of the liver (Fig. 1). With these findings, the patient was diagnosed as having hepatic microabscesses due to brucellosis. Doxycycline (2 × 100 mg/day p.o.) and rifampicin (1 × 600 mg/day p.o.) combination was started. The patient received this treatment for 3 months.

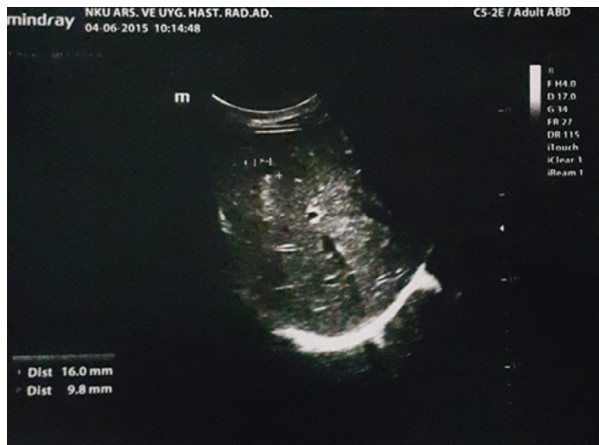

Figure 1. Ultrasonography of the liver showing small echogenic foci.

On the fifty-ninth day of the treatment, the levels of serum alanine transferase level and serum aspartate transferase decreased to the reference range. The repeated ultrasonography at the end of the treatment showed normal result.

Discussion

Brucellosis is a zoonosis that has been virtually eliminated from most developed countries, but it is still endemic in many regions of the world including Mediterranean areas, in parts of South and Central America, and East and Western Africa. The disease is transmitted to man mainly after consumption of contaminated unpasteurized milk and dairy products and less often after direct contact with infected animals [1].

Hepatic involvement in brucellosis covers a wide spectrum, ranging from mild elevation of aminotransferases to hepatitis including granulomatous forms and to liver abscesses. Increases in aminotransferases are noted in one-fourth to one-third of brucellosis cases and are more frequent in the acute stages. All cases with elevated liver enzymes should not be evaluated as hepatic involvement. Hepatic involvement in brucellosis has been reported in the literature in around 2–3% of the cases. Although *B. abortus* tends to establish a granulomatous form of hepatitis, *B. melitensis* may cause both diffuse and granulomatous lesions in the liver [1–4]. An abscess caused by *Brucella* spp usually represents the chronic form of disease, but it can occur in acute or subacute brucellosis.

Most of the clinical signs and symptoms of hepatic abscess are nonspecific. In most reported cases of brucellar abscess, fever is the main symptom. Two-thirds of patients had prolonged, slight pain in the right upper abdominal quadrant. Routine laboratory findings in

brucellosis are not usually diagnostic that may include leukopenia, anemia, thrombocytopenia, pancytopenia, and mild-to-moderate elevation of liver function tests [2, 5, 6]. Ultrasonography and computed tomography images are characteristic. Ultrasonography most commonly shows a single, hypoechoic lesion with ≥ 1 centrally located calcium deposits. Computed tomography findings most commonly depict a hypodense area, and often one or more saccular, loculated, heterogeneous mass, and one or more calcifications [5, 6].

The diagnosis of brucellosis can be established according to the isolation of *Brucella* spp. in blood, bone marrow or any other body fluid or tissue sample, or the presence of a compatible clinical picture with the demonstration of specific antibodies at significant titers or seroconversion. Significant titers are considered to be a standard agglutination test (SAT) result $\geq 1/160$ or a Coombs' anti-*Brucella* or immunocapture agglutination test result $\geq 1/320$ [1, 6]. The best regimen for the treatment of localized lesions has not been clearly defined. There is no consensus on the optimal duration of antimicrobial treatment. The duration of treatment varies depending on the individual case and the response to treatment [1]. Small, multifocal abscesses which can be detected in the acute forms of the disease respond very well to medical treatment. Other types of abscesses with an indolent course have a much worse prognosis, which considered to be a true focal complications of the disease. However, no clear distinction is made of these groups [7]. In this case, the short duration of symptoms and the high titer of *Brucella* agglutination test suggest that this case was acute. It was identified multiple millimetric foci were more prominent in the right lobe of the liver parenchyma to be significant in terms of microabscesses. Our patient was successfully treated with a combination of doxycycline and rifampicin for 3 months. The diagnosis of brucellosis in our case was confirmed with clinical findings, livestock farming history, positive serological tests, and complete response to medical treatment.

In conclusion, brucellosis is a systemic infectious disease and it is still an important public health problem in endemic areas of the world including Turkey that can cause serious complications and significant morbidity. Clinicians should be considered in the differential diagnosis of this unusual complication of brucellosis for those who live in or have visited endemic areas.

Authorship

IE, SE and, AET: wrote the manuscript and revised the manuscript. IE, RKA, OO, POD, and SS: performed the analysis of case data. All authors: contributed toward data analysis, drafting and critically revising the manuscript,

and agree to be accountable for all aspects of the manuscript.

Conflict of Interest

None declared.

References

1. Gul, H. C., and H. Erdem. 2015. Brucellosis. Pp. 2584–2588 in J. E. Bennett, R. Dolin and M. J. Blaser, eds. *Mandell, Douglas, and Bennett's principles and practice of infectious diseases*, 8th ed. Elsevier Saunders, Philadelphia.
2. Engin, D. O., H. Erdem, S. Gencer, S. Kaya, A. I. Baran, A. Batirel, et al. 2014. Liver involvement in patients with brucellosis: results of the Marmara study. *Eur. J. Clin. Microbiol. Infect. Dis.* 33:1253–1262.
3. Erdem, I., N. Cicekler, D. Mert, B. Yucesoy Dede, S. Ozyurek, and P. Goktas. 2005. A case report of acute hepatitis due to brucellosis. *Int. J. Infect. Dis.* 9:349–350.
4. Buzgan, T., M. K. Karahocagil, H. Irmak, A. I. Baran, H. Karsen, O. Evirgen, et al. 2010. Clinical manifestations and complications in 1028 cases of brucellosis: a retrospective evaluation and review of the literature. *Int. J. Infect. Dis.* 14:e469–e478.
5. Starakis, I., E. E. Mazokopakis, and H. Bassaris. 2010. Unusual manifestations of brucellosis: a retrospective case series in a tertiary care Greek university hospital. *East Mediterr. Health J.* 16:365–370.
6. Barutta, L., D. Ferrigno, R. Melchio, V. Borretta, C. Bracco, C. Brignone, et al. 2013. Hepatic brucelloma. *Lancet Infect Dis.* 13:987–993.
7. Colmenero Jde, D., M. I. Queipo-Ortuño, J. Maria Reguera, M. Angel Suarez-Muñoz, S. Martín-Carballino, and P. Morata. 2002. Chronic hepatosplenic abscesses in Brucellosis. Clinico-therapeutic features and molecular diagnostic approach. *Diagn. Microbiol. Infect. Dis.* 42:159–167.