


## CASE REPORT

# Management of upper retropharyngeal abscesses in children: Two case reports of a troublesome situation

Sara Torretta<sup>1,2</sup> | Tullio Ibba<sup>1</sup> | Claudio Guastella<sup>1</sup> | Lorenzo Gaini<sup>1</sup> |  
Maurizio Di Cicco<sup>1</sup> | Francesco Folino<sup>3</sup>  | Paola Marchisio<sup>1,3</sup> | Samantha Bosis<sup>1</sup> |  
Raffaella Pinzani<sup>1</sup> | Mario D'Amico<sup>1</sup> | Lorenzo Pignataro<sup>1,2</sup>

<sup>1</sup>Fondazione IRCCS Ca' Granda Ospedale Maggiore Policlinico, Milan, Italy

<sup>2</sup>Department of Clinical Sciences and Community Health, Università degli Studi di Milano, Milan, Italy

<sup>3</sup>Department of Pathophysiology and Transplantation, Università degli Studi di Milano, Milan, Italy

## Correspondence

Francesco Folino, Department of Pathophysiology and Transplantation, Università degli Studi di Milano, Via Festa del Perdono 7, Milan 20122, Italy.  
Email: francesco.folino@unimi.it

## Abstract

Management of upper retropharyngeal abscesses in children is challenging. In surgical cases, ultrasound-assisted intra-operative procedures may be helpful to reach peculiar locations, thus reducing surgical morbidity and complications rate.

## KEYWORDS

case report, children, infection, retropharyngeal abscess

## 1 | INTRODUCTION

Retropharyngeal abscesses in children are potentially life-threatening events generally resulting from purulent spreading into the retropharyngeal space after an upper airway infection. Surgical drainage may be difficult especially in the case of upper deep locations. We here describe the therapeutic approach adopted in two young children with upper retropharyngeal abscesses.

Retropharyngeal abscesses in children are not frequent but potentially life-threatening events, and according to some studies, they are the most common site of deep neck space infection in children.<sup>1</sup> They generally result from purulent spreading into the retropharyngeal space after the breakdown of a suppurated lymphadenopathy following an acute upper airway infection such as adenoiditis, rhinosinusitis, and tonsillitis.<sup>2-4</sup> Given that retropharyngeal lymph nodes generally regress by the age of six, this condition mainly affects

preschoolers, as it has been reported that more than 95% of retropharyngeal abscesses occur in children younger than six.<sup>5</sup>

The retropharyngeal space is a potential space extending from the skull base to the mediastinum at the level of T1 or T2, which is delimited anteriorly by the dorsal portion of the visceral layer and posteriorly by the alar division of the deep layer of the cervical fascia. The dangerous nature of retropharyngeal abscesses is related to the possible risk of airway obstruction and inhalation of purulent material, due to both spontaneous and induced abscess fistulization into the airways (mainly during orotracheal intubation or palpation of the posterior pharynx during clinical examination). Septic sequelae including toxic syndrome, abscess extending to other deep neck compartments, and mediastinitis are other severe complications. The latter results from gravitational descent of purulent fluid into the posterior mediastinum from the so-called danger space: an anatomic recess within the deep

This is an open access article under the terms of the Creative Commons Attribution-NonCommercial-NoDerivs License, which permits use and distribution in any medium, provided the original work is properly cited, the use is non-commercial and no modifications or adaptations are made.

© 2021 The Authors. *Clinical Case Reports* published by John Wiley & Sons Ltd.

retropharyngeal region placed directly in front of the vertebral space that has no inferior anatomic boundaries, rather it directly joints the posterior mediastinum caudally.<sup>6</sup> For all these reasons, retropharyngeal abscesses require a prompt diagnosis and early treatment under an urgent or emergent regimen.

Children appear extremely ill, with great discomfort with neck extension. Clinical presentations include dysphagia and odynophagia, neck stiffness and torticollis, drooling, hot potato voice, trismus (in case of parapharyngeal involvement), neck swelling (in case of extension to other deep neck compartments), chest pain (in case of mediastinal involvement), respiratory distress, and toxic appearance.<sup>6,7</sup>

Scheduled treatments include medical therapy, surgery, and minimally-invasive needle aspiration, in a single or multimodal approach. Given that the most commonly involved bacteria are *Streptococcus spp.* and *S. pyogenes*, followed by *S. aureus* and *H. influenzae*,<sup>6</sup> first-line antibiotic treatment include ampicillin-sulbactam or clindamycin; vancomycin or linezolid can be considered in septic involvement or non-responders.<sup>6</sup>

Treatment may be challenging, as surgical drainage may be difficult especially in the case of upper deep locations. Surgical approaches exploit cervicotomic, intra-oral, or combined routes. In addition, given that protection of the airways is an absolute priority, temporary tracheostomy may be required in case of impossibility to proceed with orotracheal intubation.

We here describe the therapeutic approach adopted in two young children with upper retropharyngeal abscesses.

## 2 | CASE N.1

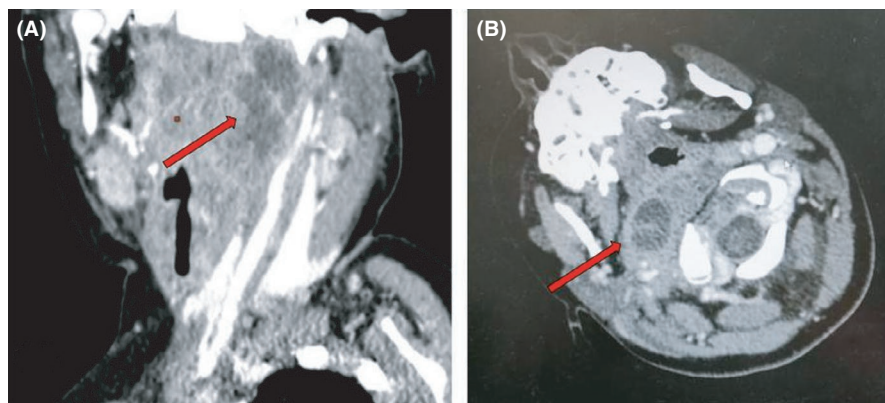
A 6 years-old girl was transferred to our pediatric division from the Emergency room for fever (max 39°C) and painful stiff neck for 3 days. Treatment with intravenous Cephtriaxone 2 g/daily was started 2 days before. Clinical

evaluation revealed the presence of torticollis with the head rotated toward the right side and restriction in the neck movement.

### 2.1 | Investigation and treatment

Inspection of the oropharynx, limited by the presence of trismus, documented a swelling of the right anterior tonsillar pillar with medialization of the ipsilateral tonsillar complex. A small incision on the cranial insertion of the anterior tonsillar pillar was performed under local anesthesia by the ENT specialist, but no frank pus collection was found. At flexible nasopharyngeal and laryngeal fiber endoscopy, a bulging of the posterior pharyngeal wall, not obstructing the airways, was documented. Laboratory tests documented an increase in inflammatory markers with a white blood cell count of 25.000 cells/microliter and a C-reactive protein level of 22 mg/dl (normal value <0.5 mg/dl). Systemic antibiotic therapy with intravenous Cefotaxime (100 mg/kg/die) was started. The patient underwent an urgent pre-operative contrasted computed tomography (CT)-scan under sedation documenting the presence of a large (40 × 23 × 20 mm) abscessual cavity placed in the deep retropharyngeal space extending from the nasopharynx to a plane passing through the pharyngo-epiglottic fold (Figure 1). Based on this finding, antibiotic treatment was changed into Piperacillin/tazobactam (150 mg/kg three times a day) and Vancomycin (400 mg three times a day), and urgent surgical drainage under general anesthesia was planned.

With head hyperextension and after the placement of a gag to open the mouth, the presence of a medialization of the right tonsillar fossa was confirmed. A further incision was performed on the soft palate 5 mm cranially to the superior pole of the right tonsil without the finding of any abscessual cavity. Tonsillectomy was performed to expose the posterior wall of the tonsillar fossa without detection of any pathological finding. Therefore, a horizontal skin incision parallel and about 1 cm behind the inferior border of the mandibular angle



**FIGURE 1** A, Contrasted sagittal CT scan documenting the presence of a multilocular abscessual cavity in the upper retropharyngeal space and the nearest neurovascular bundle; B, Axial CT scan documenting a right retropharyngeal abscess

was performed to gain access to the parapharyngeal space. Surgical steps were performed as follows: After identification and ligation of the facial vein, the submandibular gland was dissected and moved up; then, the facial artery was ligated; and the posterior belly of the digastric muscle, the stylohyoid muscle, and the stylomandibular ligament were isolated and pushed forward to reach the parapharyngeal space, but no abscessual cavity was detected during the cervicotomic approach. The neurovascular bundle was identified and great vessels were prepared, in order to be able to control any possible massive intra-oral bleeding. At this point, we turned to the intra-oral approach: The right palatopharyngeal muscle was incised at its cranial portion through the trans-oral approach, and the abscessual cavity was identified deeply and above it and opened with the drainage of about 5 cc of purulent liquid. This was performed after having prepared the great neck vessels through the trans-cervical approach to be possibly ligated in case of bleeding while approaching the deeper retropharyngeal space by the trans-oral route.

## 2.2 | Outcome and follow-up

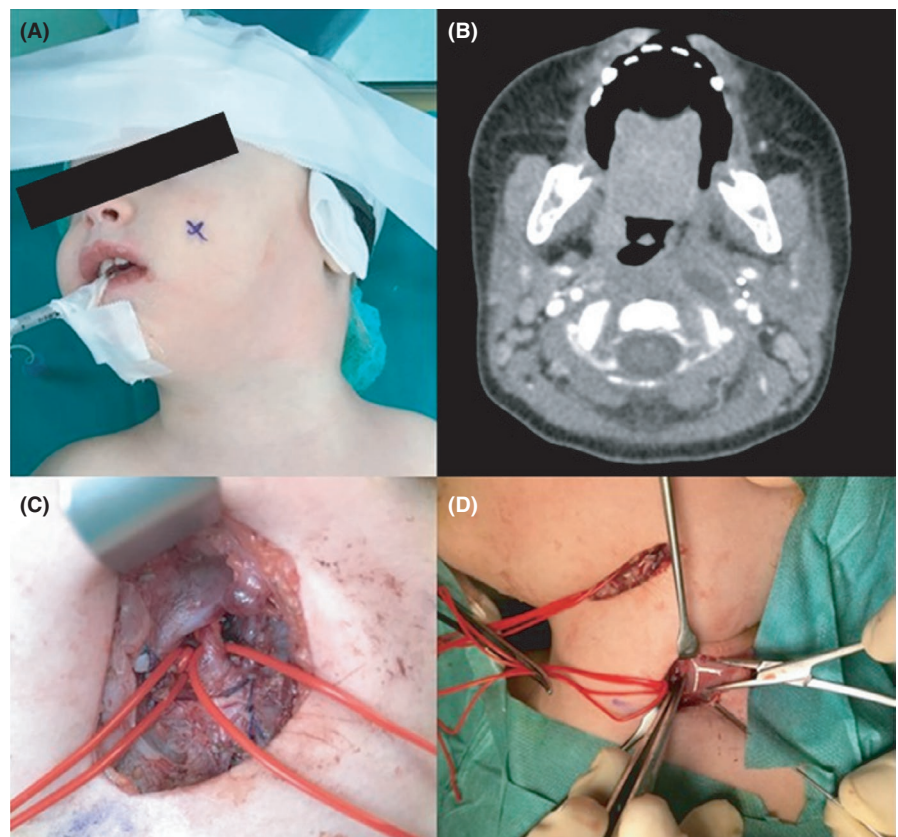
A progressive clinical improvement and reduction in the inflammatory markers were documented, and the child was discharged 21 days after surgery.

## 3 | CASE N.2

A 22-month-old previously healthy girl was transferred to our pediatric division from the Emergency room for fever (max 39°C) and painful stiff neck for 2 days. Clinical evaluation revealed the presence of a painful left cervical swelling and redness (Figure 2A); her head was flexed and rotated to the right side with restriction in the neck movement. The patient complained about sore throat and dysphagia, but neither dyspnea nor trismus occurred.

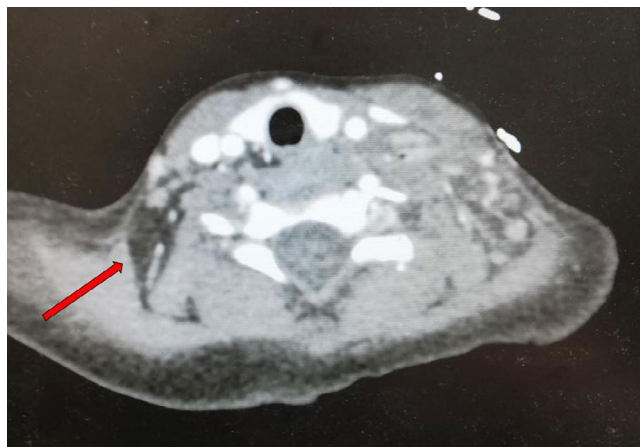
### 3.1 | Investigation and treatment

Laboratory tests documented an increase in inflammatory markers with a white blood cell count of 33.000 cells/microliter and a C-reactive protein level of 33 mg/dl. Trans-nasal fiber optic examination documented a swelling of the posterior wall of the upper pharynx, without any airway obstruction or purulent discharge. No swelling of the oropharyngeal walls or medialization of the tonsillar complex was detected. An urgent contrasted CT scan was performed, documenting a 26 × 18 × 10 mm abscessual formation placed in the deep retropharyngeal space, extending from C2 to C4 (Figure 2B), with inflammatory edematous imbibition of the soft tissues just in front of the vertebral space until C6; in addition, a



**FIGURE 2** Clinical picture of the child A; contrasted axial CT scan B; intra-operative view: common, internal and external carotid arteries have been identified and isolated (surgical loops) before approaching the parapharyngeal space by the cervicotomic route C; surgical drainage of pus collection from the supraclavicular neck incision D

23 × 9 mm low-density area involving the left laterocervical region, extending from the supraclavicular fossa behind the collarbone and the sternum into the upper anterior ipsilateral mediastinum, was detected (Figure 3). Systemic antibiotic therapy with piperacillin/tazobactam (150 mg/kg/die) and vancomycin (40 mg/kg/die) was started, and urgent surgical drainage was planned. The surgical approach was performed by a combined intra-oral and cervicotomic approach as follows: With head hyperextension and after the placement of a gag to open the mouth, the oropharynx was inspected, without the finding of any swelling; before any further procedure, a horizontal skin incision, parallel and about 1 cm behind the inferior border of the mandibular angle, was performed to identify and isolate the internal jugular vein and the internal and external carotid artery, in order to be able to control any possible massive intra-oral bleeding (Figure 2C); a left tonsillectomy was successively performed and the palatopharyngeal muscle was dissected without any pathological finding; therefore, through the cervical approach, the submandibular gland and the digastric muscle were isolated to gain access to the parapharyngeal region, which was explored without the finding of any abscessual cavity, yet an inflammatory reaction of the fascial and deep muscular planes was documented; a horizontal skin incision was then performed, about 1 cm above the collarbone, to approach the supraclavicular area: The choice to perform a second horizontal skin incision was driven by the failure in obtaining a complete abscess drainage through the intra-oral approach, and by the pre-operative radiological evidence of two abscessual cavities; we presumed that during surgical dissection and intra-oral palpation the cranial cavity emptied into the caudal one, and this could be the reason why we were not able to drain it at the beginning of the surgery. The first trans-cervical upper incision was used to expose the great neck vessels in order to control any possible bleeding during the intra-oral approach; to reach the previously radiologically documented upper retropharyngeal



**FIGURE 3** Axial CT scan documenting imbibition of the left supraclavicular area and the upper mediastinal space

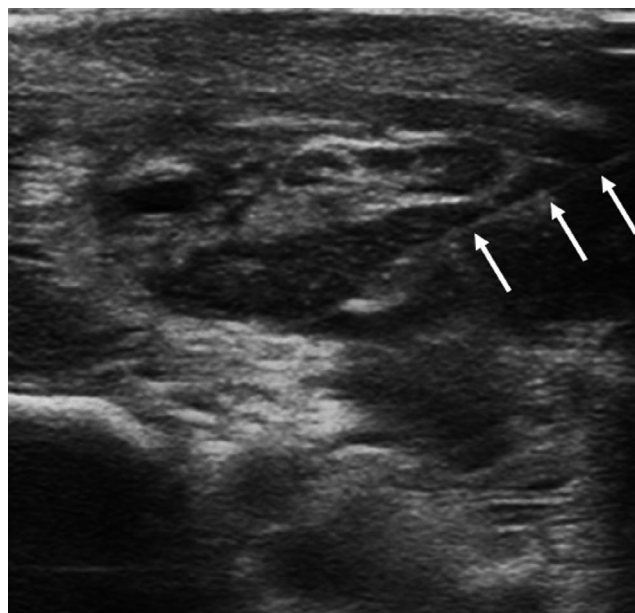
abscessual cavity, and given the strict anatomic relationship with the nearest great neck vessels, an ultrasonically guided needle puncture was performed, without the finding of any further fluid collection; on the contrary, a large pus collection was identified and surgically evacuated with the guide of a needle placed under ultrasonographic control (Figures 2D and 4), deeply to the clavicular insertion of the sternocleidomastoid muscle and close to the neurovascular bundle. An intra-operative ultrasonographic control disclosed the presence of further residual pus collection.

### 3.2 | Outcome and follow-up

A progressive clinical improvement and reduction in the inflammatory markers were documented. A contrasted CT scan performed 48 h after surgery confirmed the almost complete resolution of any colliquative process. Given the finding of a multi-sensitive *S. pyogenes* isolated from the purulent fluid, Vancomycin was stopped and replaced by clindamycin (30 mg/kg/die). A progressive complete recovery was documented, and the child was discharged 14 days after surgery.

## 4 | DISCUSSION

These cases document that surgical management of an upper and deeply located retropharyngeal abscess may be challenging for several reasons. They include the fact that the closeness to the major neck vessels makes any surgical approach



**FIGURE 4** Fine needle aspiration under ultrasonographic control of the supraclavicular pus collection (white arrows to indicate the needle)

risky; this is particularly true in the case of a pure intra-oral approach, in which major bleeding cannot be effectively controlled. Under these circumstances, a combined intra-oral and cervicotomic approach with identification and preparation of the great vessels for precautionary purposes may be helpful. On the other hand, upper locations can be difficult to be reached both through an intra-oral and a cervical route. Moreover, an abscessual cavity may be compartmentalized or separated but somehow connected multiple locations may be present. This happened in case n. 2, where the cranial abscessual cavity probably emptied into the lower one (to which was presumably connected through a fistulous tract) during surgical manipulation of the retropharyngeal space. In these cases, the resort to an intra-operative ultrasonographic control with a possible interventional approach may be useful to increase the effectiveness and safety of the surgical action. Percutaneous needle aspiration has been described by other authors as a single procedure or combined with an intra-oral surgical approach.<sup>8-12</sup>

Literature corroborates these considerations, as it has been reported that surgical failure is possible, with the needing for a second surgical drainage in about 16% of cases.<sup>8</sup>

Given the toxic status of our patients and the large abscess volume, surgery was chosen as the first-line approach. However, in the case of smaller locations without any airway involvement or septic condition, primary antibiotic treatment could be considered with the resort to surgery only after medical failure, reported to vary between 0% and 59%.<sup>8,13</sup> In particular, Hoffmann et al<sup>8</sup> documented that medical failure more frequently occurs in the case of pus collection having a largest long axis  $\geq 20$  mm. The authors concluded that surgery should be reserved for children with severe complications including dyspnea and septic shock and in case of abscesses diameter larger than 20 mm.<sup>8</sup> Age lower than 15 months was found to be another negative predictor for effectiveness of medical treatment alone.<sup>14</sup>

## 5 | CONCLUSIONS

In conclusion, management of upper and deeply located retropharyngeal abscesses in children is challenging. In surgical cases, the intra-oral approach is traditionally considered the route of choice, with cervicotomy to be reserved to patients with pus collections placed laterally to the great neck vessels or inferiorly to the mediastinum.<sup>8</sup> The resort to ultrasound-assisted intra-operative procedures may be helpful to reach peculiar locations, thus reducing surgical morbidity and complications rate. In our patients, a combined approach was chosen based on the strict relationship with the neurovascular bundle, the failure to evacuate the cranial pus collection by a pure intra-oral approach, and the presence of multiple separated abscessual cavities (in case n. 2).

## ACKNOWLEDGEMENTS

No acknowledgments.

## CONFLICTS OF INTEREST

The author(s) declare no potential conflicts of interest with respect to the research, authorship, and/or publication of this paper.

## AUTHOR CONTRIBUTIONS

Sara Torretta involved in conception, drafting, and revising. Tullio Ibba involved in data acquisition and interpretation. Claudio Guastella, Lorenzo Gaini, and Maurizio Di Cicco involved in data acquisition and interpretation. Francesco Folino contributed in drafting and revision. Paola Marchisio and Lorenzo Pignataro revised the paper for important intellectual contributions. Samantha Bosis, Raffaella Pinzani, and Mario D'Amico involved in data acquisition and drafting.

## ETHICAL APPROVAL

The study was published with written consent of the patients.

## DATA AVAILABILITY STATEMENT

All relevant data are included and are available as part of the article.

## ORCID

Francesco Folino  <https://orcid.org/0000-0002-1003-6993>

## REFERENCES

1. Yen CW, Lin CY, Tsao LY, Yang SC, Chen HN, Chang MY. Children's deep neck infections in central Taiwan. *Acta Paediatr Taiwan*. 2007;48(1):15-19.
2. Ungkanont K, Yellon R, Weissman J, Casselbrant M, González-Valdepeña H, Bluestone C. Head and neck space infections in infants and children. *Otolaryngol Head Neck Surg*. 1995;112(3):375-382. [https://doi.org/10.1016/s0194-5998\(95\)70270-9](https://doi.org/10.1016/s0194-5998(95)70270-9)
3. Daya H, Lo S, Papsin BC, et al. Retropharyngeal and parapharyngeal infections in children: the Toronto experience. *Int J Pediatr Otorhinolaryngol*. 2005;69(1):81-86. <https://doi.org/10.1016/j.ijporl.2004.08.010>
4. Lee SS, Schwartz RH, Bahadori RS. Retropharyngeal abscess: epiglottitis of the new millennium. *J Pediatr*. 2001;138(3):435-437. <https://doi.org/10.1067/mpd.2001.111275>
5. Gates GA. Deep neck infection. *Am J Otolaryngol*. 1983;4(6):420-421. [https://doi.org/10.1016/s0196-0709\(83\)80052-0](https://doi.org/10.1016/s0196-0709(83)80052-0)
6. Jain A, Singh I, Meher R, Raj A, Rajpurohit P, Prasad P. Deep neck space abscesses in children below 5 years of age and their complications. *Int J Pediatr Otorhinolaryngol*. 2018;109:40-43. <https://doi.org/10.1016/j.ijporl.2018.03.022>
7. Jain H, Knorr TL, Sinha V. Retropharyngeal Abscess. In: *StatPearls [Internet]*. Treasure Island, FL: StatPearls Publishing; 2020.
8. Hoffmann C, Pierrot S, Contencin P, Morisseau-Durand MP, Manach Y, Couloigner V. Retropharyngeal infections in children. Treatment strategies and outcomes. *Int J Pediatr Otorhinolaryngol*. 2011;75(9):1099-1103. <https://doi.org/10.1016/j.ijporl.2011.05.024>

9. Yeow KM, Liao CT, Hao SP. US-guided needle aspiration and catheter drainage as an alternative to open surgical drainage for uniloculated neck abscesses. *J Vasc Interv Radiol*. 2001;12(5):589-594. [https://doi.org/10.1016/s1051-0443\(07\)61481-x](https://doi.org/10.1016/s1051-0443(07)61481-x)
10. Abdel-Haq NM, Harahsheh A, Asmar BL. Retropharyngeal abscess in children: the emerging role of group A beta hemolytic streptococcus. *South Med J*. 2006;99(9):927-931. <https://doi.org/10.1097/01.smj.0000224746.39728.cd>
11. Wagner R, Espitalier F, Madoz A, Picherot G, Bordure P, Malard O. Abscès rétro- et parapharyngés de l'enfant: facteurs prédictifs d'échec du traitement médical [Retro- and parapharyngeal abscess in children: predictive factors of medical treatment failure]. *Ann Otolaryngol Chir Cervicofac*. 2009;126(3):112-119. French. <https://doi.org/10.1016/j.aorl.2009.03.004>
12. Duque CS, Guerra L, Roy S. Use of intraoperative ultrasound for localizing difficult parapharyngeal space abscesses in children. *Int J Pediatr Otorhinolaryngol*. 2007;71(3):375-378. <https://doi.org/10.1016/j.ijporl.2006.10.018>
13. Al-Sabah B, Bin Salleen H, Hagr A, Choi-Rosen J, Manoukian JJ, Tewfik TL. Retropharyngeal abscess in children: 10-year study. *J Otolaryngol*. 2004;33(6):352-355. <https://doi.org/10.2310/7070.2004.03077>
14. Cheng J, Elden L. Children with deep space neck infections: our experience with 178 children. *Otolaryngol Head Neck Surg*. 2013;148(6):1037-1042. <https://doi.org/10.1177/0194599813482292>

**How to cite this article:** Torretta S, Ibba T, Guastella C, et al. Management of upper retropharyngeal abscesses in children: Two case reports of a troublesome situation. *Clin Case Rep*. 2021;9:e04598. <https://doi.org/10.1002/ccr3.4598>