

Multiple Time Aortic Valve Replacement

Tae-Eun Jung, M.D.*, Dong-Hyup Lee, M.D.*

A 32-year-old female who had undergone aortic valve replacement (AVR) 10 years previously as a result of an episode of infective endocarditis with the pathogen *Staphylococcus epidermidis*, was admitted to the hospital with a history of appetite loss, chilling, relapsing fever up to 39°C, and left leg pain.

Her medical history included Williams syndrome along with patch aortoplasty and aortic valve commissuroplasty 22 years earlier when she was 10 years old. The patient was lost to follow-up until age 16, when she was readmitted with native valve endocarditis. She was treated with AVR with a 21-mm CarboMedics mechanical valve (CarboMedics, Inc., Sorin Group, Burnaby, British Columbia, Canada) and graft interposition of the ascending aorta with a 20-mm Hemashield artificial graft (Maquet Cardiovascular, Wayne, NJ). She was again lost to follow-up until age 22, when she stayed the hospital again for a week with a fever. She underwent redo AVR again with a 21 mm Edwards MIRA mechanical valve (Edwards Lifesciences, Irvine, CA, USA). She was discharged December 15, 2000, and was prescribed a regimen of an anti-coagulant, but the patient has not taken any warfarin since. However, she became pregnant twice and had an abortion and a birth without anticoagulation during this period.

The blood culture yielded growth of *Staphylococcus sanguis*, which was sensitive to the initial treatment regimen. Immediate transthoracic echocardiography and transesophageal echocardiography demonstrated vegetations (0.75×0.2 and 0.8×0.3 cm linear oscillating masses), which were observed on the left ventricular side of the prosthetic aortic valve (Fig.

1). The increased infection parameters, including fever, leukocytosis, and ESR, and the blood culture again showed the presence of *Staphylococcus sanguis* and a sensitivity to ceftriaxone, so the treatment was continued. However, a linear oscillating mass at the prosthetic aortic valve was observed despite the clinical control of the infection. Consequently, re-redo AVR was performed with a 25-mm St. Jude mechanical valve on the 25th day after the initiation of antibiotic treatment. Following successful surgery, the patient recovered well and was discharged after six weeks of postoperative antibiotic treatment without any signs of infective endocarditis.

In spite of advances in medical and surgical treatment, infective endocarditis is still regarded as a serious disease [1]. Patients with previous infective endocarditis are considered at high risk of recurrent endocarditis, so significant attention should be paid to prevent any recurrences [2-5]. A large number of female patients with valvular heart disease will be of childbearing age at some point. This case shows a serious complication concerning a pregnant patient with prosthetic heart valves. Also, this patient was uncooperative with our treatment, and had low social standings without the benefit of formal education. In this case, prosthetic aortic valve replacement was performed during the second episode of infective endocarditis, and the patient was three months pregnant when she was admitted to the hospital with a history of fever for a week. She should have taken warfarin diligently and gone for regular check-ups to prevent a third infection. However, she discontinued anticoagulant medication and follow-up examination as an outpatient. As a result, she needed an abortion in

*Department of Thoracic and Cardiovascular Surgery, College of Medicine, Yeungnam University

Received: March 17, 2011, Revised: April 5, 2011, Accepted: June 3, 2011

Corresponding author: Dong-Hyup Lee, Department of Thoracic and Cardiovascular Surgery, College of Medicine, Yeungnam University, 317-1, Daemyeong 5-dong, Nam-gu, Daegu 705-717, Korea
(Tel) 82-53-620-3883 (Fax) 82-53-626-8660 (E-mail) dhlee@med.yu.ac.kr

© The Korean Society for Thoracic and Cardiovascular Surgery. 2011. All rights reserved.

© This is an open access article distributed under the terms of the Creative Commons Attribution Non-Commercial License (<http://creativecommons.org/licenses/by-nc/3.0>) which permits unrestricted non-commercial use, distribution, and reproduction in any medium, provided the original work is properly cited.

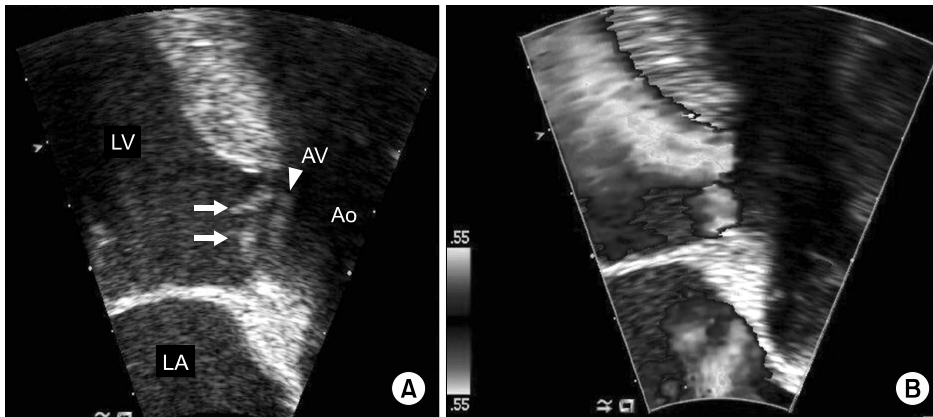


Fig. 1. Vegetations (arrow) were observed at the left ventricular side of the prosthetic aortic valve and aortic regurgitation was seen by TEE. LV= left ventricle; LA=Left atrium; AV= Aortic valve (arrow head); Ao=Aorta.

order to undergo re-redo aortic valve replacement due to the second episode of endocarditis.

Consequently, patients with prosthetic valves should be sufficiently educated about infective endocarditis before discharge, and preventive measures, such as effective personal hygiene, should be prescribed.

REFERENCES

1. Kim HW, Joo S, Kim HJ, et al. *Active prosthetic valve endocarditis: the clinical profile, laboratory findings and mid-term surgical results.* Korean J Thorac Cardiovasc Surg 2009;42:447-55.
2. Renzulli A, Carozza A, Romano G, et al. *Recurrent infective endocarditis: a multivariate analysis of 21 years of experience.* Ann Thorac Surg 2001;72:39-43.
3. Kuzman WJ. *Recurrent bacterial endocarditis due to Salmonella Newport and Diphtheroid bacillus. Report of a case with cure.* Dis Chest 1967;51:654-5.
4. Lutwick LI. *Recurrent streptococcal endocarditis.* South Med J 1979;72:1027-8.
5. Reinsch N, Plicht B, Lind A, et al. *Recurrent infective endocarditis with uncommon Gram-negative Pasteurella multocida and Pseudomonas aeruginosa: a case report.* J Heart Valve Dis 2008;17:710-3.