

Received: 2020.12.04  
Accepted: 2021.01.12  
Available online: 2021.01.20  
Published: 2021.02.01

# Primary Mature Teratoma of the Rectum: A Case Report

Authors' Contribution:  
Study Design A  
Data Collection B  
Statistical Analysis C  
Data Interpretation D  
Manuscript Preparation E  
Literature Search F  
Funds Collection G

ABCDEF **Kyung Han Nam**  
DEF **Bomi Kim**

Department of Pathology, Haeundae Paik Hospital, Inje University College of  
Medicine, Busan, South Korea

**Corresponding Author:** Kyung Han Nam, e-mail: h00300@paik.ac.kr  
**Conflict of interest:** None declared

**Patient:** Female, 68-year-old  
**Final Diagnosis:** Primary mature teratoma of the rectum  
**Symptoms:** Hematochezia  
**Medication:** —  
**Clinical Procedure:** Colonoscopy with polypectomy  
**Specialty:** Gastroenterology and Hepatology

**Objective:** Rare disease





**Background:** Teratomas are embryonal neoplasms that contain tissues derived from 1 or more of the 3 germ layers. They commonly are found in the sacrococcygeal-gonadal location, sometimes in midline locations such as the mediastinum, retroperitoneum, and head and neck region. Primary rectal teratomas are extremely rare. Extragenital teratomas can originate from pluripotent germ cells present in abnormal embryonic rests.

**Case Report:** Here, we report a rare case of a primary mature, solid teratoma of the rectum. A 68-year-old woman presented with hematochezia and denied any history of abdominal pain or a change in bowel habits. Colonoscopy revealed a 4-cm pedunculated polyp in the rectum. No hair was present on its surface. The polyp was completely removed by polypectomy. Histologically, the tumor consisted of mature components from all 3 germ layers. Its surface was covered by squamous epithelium with hair follicles and sweat glands. Adipose tissue, blood vessels, bone, and glandular epithelium were present inside the mass. No evidence was found of immature elements or malignant features.

**Conclusions:** When polypoid lesions are found in the rectum, teratoma should be considered in the differential diagnosis. Histopathological confirmation is necessary to diagnose teratoma. Primary rectal teratomas should be distinguished from other neoplastic polyps as well as from local spread of teratomas arising in adjacent organs. These neoplasms are usually mature (benign) but may undergo malignant transformation. Therefore, complete resection is recommended to alleviate symptoms and avoid the risk of malignancy.

**Keywords:** Endoscopy • Rectum • Teratoma

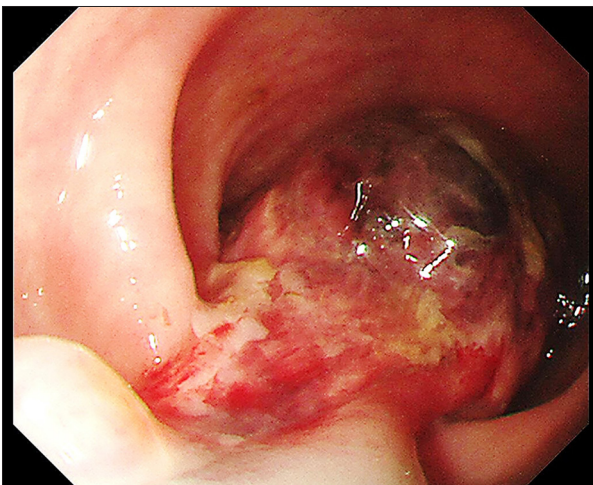
Full-text PDF: <https://www.amjcaserep.com/abstract/index/idArt/930272>

 1427   3  22



## Background

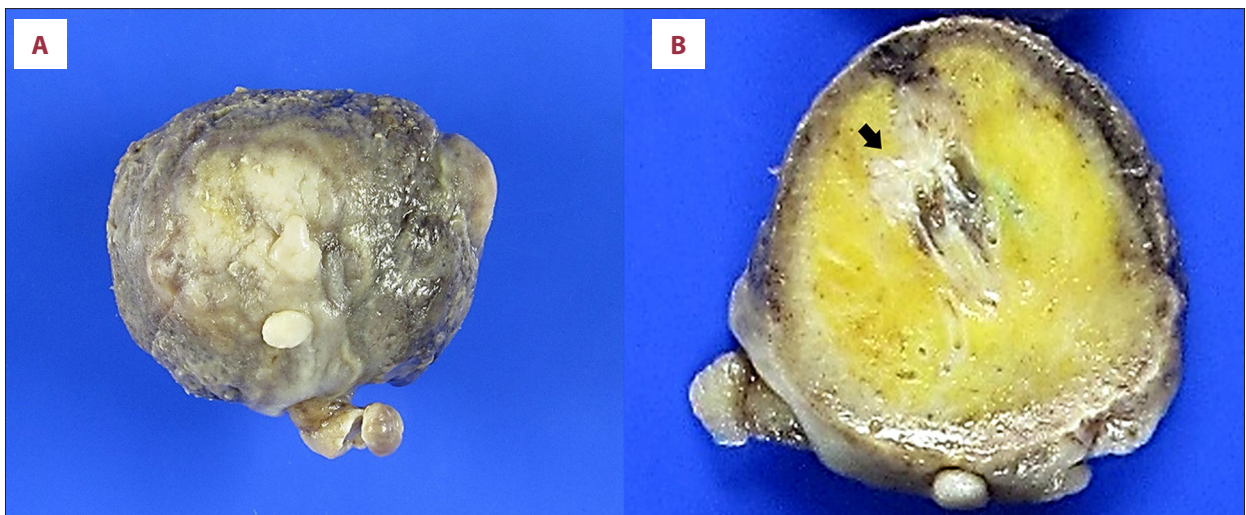
Teratomas are embryonal neoplasms that contain tissues derived from 1 or more of the 3 germ layers: ectoderm, mesoderm, and endoderm [1]. They are commonly found in the sacrococcygeal-gonadal area and sometimes in midline locations such as the mediastinum, retroperitoneum, and head and neck [1]. Primary rectal teratomas are extremely rare [2]. Most are mature and occur in women [3]. In most reported cases, teratomas have been pedunculated, which leads to symptoms such as prolapse of the mass or hair [3]. We report a case of a primary, mature, solid teratoma of the rectum that was a pedunculated polyp and which was successfully removed with endoscopic resection.



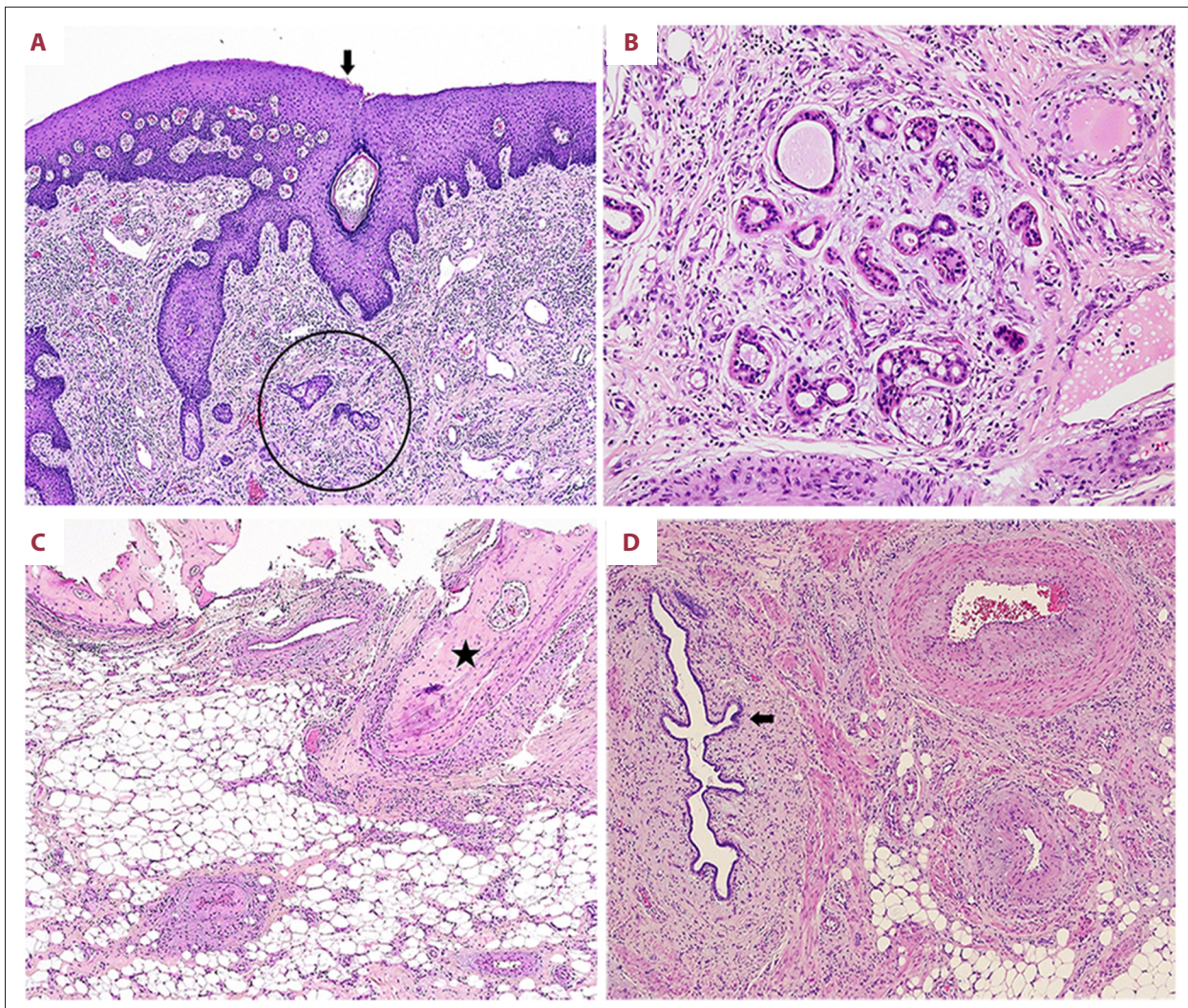
**Figure 1.** At colonoscopy, a pedunculated polyp measuring approximately 4 cm is found in the rectum.

## Case Report

A 68-year-old woman presented with hematochezia. She denied any history of abdominal pain, constipation, or weight loss. She had no significant history of medical problems, except for hypertension. Physical examination revealed no abnormalities. Colonoscopy revealed a 4-cm pedunculated polyp located approximately 15 cm from the anal verge (**Figure 1**). A large part of the outer surface of the polyp was ulcerated, and the remaining surface was covered with white-to-gray, wrinkled mucosa. Colonoscopy showed no evidence of other polyps. The polyp was clinically suspected to be an epithelial tumor such as an adenoma/carcinoma or a hamartomatous polyp. The mass was removed by polypectomy. On gross examination, the specimen measured 4.2×3.5×3.0 cm and had a 1.0-cm stalk (**Figure 2A**). The cut surface of the mass was solid, with yellow adipose and hard, bony tissue (**Figure 2B**). No hair or sebaceous material was found. On microscopic examination, the ulcerated part of the tumor surface showed inflamed granulation tissue with hemorrhage, whereas the intact part was covered by squamous epithelium (**Figure 3A**). Hair follicles and sweat glands were present below the surface (**Figure 3A, 3B**). Adipose tissue, blood vessels, bone, and glandular epithelium were present inside the mass (**Figure 3C, 3D**). There was no evidence of immature elements or malignant features. Based on these findings, a diagnosis of primary mature teratoma of the rectum was made. The patient recovered with no complications and will undergo an abdominal computed tomography (CT) scan at a follow-up visit.



**Figure 2.** Macroscopic findings for the specimen. (A) A large part of the surface is ulcerated and the remaining surface (center) is covered with white-to-gray, wrinkled mucosa. No hair is noted. (B) The cut surface of the mass reveals yellow adipose and hard bony tissue (arrow).



**Figure 3.** Microscopic findings for the mature teratoma. (A) Squamous epithelium (arrow) with hair follicles (circle) (hematoxylin & eosin [H&E], original magnification  $\times 40$ ). (B) Sweat glands (H&E, 100). (C) Adipose tissue and bone (asterisk) (H&E, original magnification  $\times 40$ ). (D) Glandular epithelium (arrow) and blood vessels (right side) (H&E, original magnification  $\times 40$ ).

## Discussion

Teratomas may have their origins in pluripotent germ cells, which are abundant in the gonads [1]; during embryogenesis, some primordial germ cells may follow abnormal migratory pathways and lodge in extragonadal sites. Stray germ cells usually degenerate, but in rare cases, they remain at ectopic locations and can develop into teratomas [4].

In 2009, Park et al reported on a case and reviewed 55 other cases of teratoma that had previously been reported worldwide [2]. In an extensive review of reports, we found 9 more case reports up until 2020, not including the present case [3,5-12]. In 65 cases, most primary rectal teratomas were mature (benign). Sixty-four were diagnosed in women [13], which is not surprising because germ cells from the ovaries can migrate

to the rectum [14]. The age range of patients with primary rectal tumors was 2 to 83 years, with most cases in individuals in their 20s to 40s [2,3,11]. In contrast, teratomas of the gastric and sacrococcygeal regions are mainly diagnosed in neonates and infants [1].

A review of the literature by Park et al [2] revealed that the most common symptoms of primary rectal teratomas were prolapse of the mass and/or hair (22 cases, 42.3%), hematochezia (18 cases, 34.6%), and constipation (10 cases, 19.2%). However, lower abdominal pain, abdominal mass, and low back pain occasionally has been reported. Among the 9 additional cases we found, there was a single patient with prolapse of a mass [12], 2 patients had hematochezia with pain [8,9], and 3 had constipation [3,6,11]. The patient in the present case presented with painless hematochezia. The differential diagnosis

for it includes colonic diverticulosis (the most common cause), angiodysplasias, nonsteroidal anti-inflammatory drug-associated ulcers, and colon polyps/neoplasms [15,16]. Most of the tumors we found were polypoid in shape and only 4 cases presented as submucosal cysts [17]. The polypoid masses were mostly pedunculated. The tumors ranged in size from 1.2 to 15 cm [3]. In the reported cases, the ovarian teratomas were almost always cystic, whereas primary rectal teratomas were frequently solid [3]. Histologically, most primary rectal teratomas are composed of derivatives from all 3 germ layers, but a few cases of dermoid cysts of the rectum have been reported [17,18]. Only 1 case of immature teratoma, found in a 2-year-old girl, has been reported [12].

When hair is identified on the tumor surface or squamous epithelium in a biopsy sample, suspicion should be high for teratoma [14]. In most of the reported cases of rectal teratoma, hairs were present on the surface. However, if hair is not present on the polyp, the diagnosis of teratoma is rarely considered because of its rarity in the rectum [14]. The differential diagnosis includes various adenomas, carcinomas, leiomyomas, lymphomas, carcinoid tumors, lipomas, and vascular neoplasms [19]. In our case, because the polyp was pedunculated with a well-defined stalk and there were no hairs seen on endoscopy, it was clinically suspected to be an epithelial tumor, such as an adenoma/carcinoma or a hamartomatous polyp. Polypectomy was then performed to make a diagnosis. Primary rectal teratoma also should be distinguished from local spread of teratomas arising in adjacent organs, which can be caused by spontaneous rupture or fistula formation [9,14]. Imaging studies are useful to visualize structures adjacent to the tumor [20,21].

Histologically, teratomas are classified as mature cystic or solid (benign), immature (malignant), or monodermal (eg, struma ovarii, carcinoid tumor) [1]. Mature cystic teratomas differentiate mainly along ectodermal lines to create a squamous-lined cyst that is filled with hair, sebaceous material, and teeth [20]. Ectodermal elements include the epidermis, skin appendage, and brain tissue. Monodermal tissue is represented by bone, cartilage, fat, and smooth muscle. Endodermal derivatives, such as the respiratory epithelium, gastrointestinal epithelium, and thyroid tissue, can be found. Mature solid teratomas probably have the same histogenetic origin as cystic teratomas, but they lack predominant differentiation into ectodermal tissue to form a squamous-lined cyst [20]. Solid regions raise concern for malignancy. Areas of necrosis in a solid tumor are consistent with immature teratomas but should not be found in mature solid teratomas [21]. Immature teratomas tend to be solid and contain areas that vaguely resemble normal tissues and small cysts. Microscopically, these tumors contain mature elements admixed with variable amounts of immature elements [21]. Histologic grading is based on the

amount of immature neuroepithelium identified. Therefore, rigorous sampling and careful histological examination are recommended to exclude immature elements in tumors with large solid components [21]. Malignant transformation can occur in 1% to 2% of mature cystic teratomas, and squamous cell carcinoma accounts for 80% of these cases [20,21]. In fact, no case of malignancy arising in a primary rectal teratoma has been reported [2]. However, identification of associated malignancies with adequate sectioning is important for management and prognosis.

Complete resection is optimal because most primary rectal teratomas are benign, and no reports exist of recurrence of primary rectal teratoma after curative resection [2,3,14]. Considering the occurrence of complications, such as rupture, bleeding, and malignant changes in gonadal teratomas, it is reasonable to remove rectal teratomas [2]. Endoscopic resection is indicated for a pedunculated polyp that measures <4 cm. If the diagnosis is unclear or malignancy cannot be excluded, surgical resection is preferable [3,17,22]. Occasionally, teratomas arising in the ovary or the presacral area extend to the rectal wall; that should be ruled out before surgery [9,22]. Because our patient's lesion was a pedunculated polyp measuring approximately 4 cm, endoscopic resection was performed to make a diagnosis.

Our case report has a limitation. Because the pedunculated polyp was successfully removed by endoscopy and it was diagnosed as a primary rectal teratoma, the patient did not undergo imaging at the time of diagnosis. In addition, she had no signs or symptoms after resection. However, imaging studies would be important to confirm that there are no other masses because the prognosis depends on timely resection [2,14,20]. Therefore, our patient will undergo an abdominal CT during a follow-up visit.

## Conclusions

Primary rectal teratomas are extremely rare. However, when polypoid lesions are found in the rectum, teratoma should be considered in the differential diagnosis. Using clinical findings and histologic examination, primary rectal teratomas should be distinguished from local spread of teratomas arising in adjacent organs as well as from other neoplastic polyps. Primary rectal teratomas are usually mature (benign) but can undergo malignant transformation. Therefore, complete resection of a rectal teratoma is recommended to ameliorate symptoms and avoid the risk of malignancy.

## Conflicts of Interest

None.

## References:

1. Kumar V, Abbas AK, Aster JC. Neoplasia. In: Kumar V, Abbas AK, Aster JC (eds.), Robbins & Cotran Pathologic Basis of Disease. 9<sup>th</sup> ed. Philadelphia: Elsevier, 2015;265-340
2. Park JH, Byeon JS, Jo JH, et al. Endoscopic polypectomy of primary rectal mature teratoma. A case report. *Clin Endosc*, 2009;39:308-12
3. Lee YM, Han JH, Lee HC. Primary rectal mature teratoma: A case report. *J Biomed Res*, 2013;14:249-52
4. Carlson BM. Getting ready for pregnancy. In: Carlson BM (eds.), Human Embryology and Developmental Biology. 6<sup>th</sup> ed: Elsevier, 2019;1-22
5. Yoshizaki T, Aoki Y, Okada A. primary pedunculated solid teratoma of the rectum. *Clin Gastroenterol Hepatol*, 2020;18:A29
6. Hamzaoui L, Kilani H, Bouassida M, et al. Endoscopic resection of a dermoid rectal cyst. *Presse Med*, 2015;44:554-55
7. Park HS, Hong SG, Jung SY, et al. A case of primary mature teratoma of the rectum. *Soonchunhyang Med Sci*, 2014;20:27-30
8. Singh O, Gupta SS, Mathur RK. A rare case of primary solid intrarectal dermoid. *Saudi J Gastroenterol*, 2011;17:74-76
9. Sharma R, Maliakkal B. Polypoid rectal mass in a 21-year-old woman with hematochezia. *Gastroenterology*, 2011;141:436-37,781
10. Terada T. Mature teratoma of the rectum. *Gastrointest Endosc*, 2010;71:1068-69
11. Hasebe Y, Honda R, Washizawa N, et al. A case of transsacally excised teratoma originating in the rectum. *J Jpn Pract Surg Soc*, 1988;49:2371-75
12. Govender D, Hadley GP, Bairstow S. Immature teratoma of the rectum presenting with prolapse per anum. *Pediatr Surg Int*, 1995;10:194-95
13. Aldridge MC, Boylston AW, Sim AJ. Dermoid cyst of the rectum. *Dis Colon Rectum*, 1983;26:333-34
14. Takao Y, Shimamoto C, Hazama K, et al. Primary rectal teratoma: EUS features and review of the literature. *Gastrointest Endosc*, 2000;51:353-55
15. Dumic I, Nordin T, Jecmenica M, et al. Gastrointestinal tract disorders in older age. *Can J Gastroenterol Hepatol*, 2019;2019:6757524
16. Rockey DC. Lower gastrointestinal bleeding. *Gastroenterology*, 2006;130:165-71
17. Sakurai Y, Uraguchi T, Imazu H, et al. Submucosal dermoid cyst of the rectum: Report of a case. *Surg Today*, 2000;30:195-98
18. Kumar B, Kumar M, Sen R, et al. Mature solid teratoma of the rectum: Report of a case. *Surg Today*, 2008;38:1133-36
19. Sharma D, Kumar S, Tandon A, et al. Primary rectal teratoma. *Surgery*, 2008;143:570-71
20. Ellenson LH, Pirog EC. The female genital tract. In: Vinay Kumar V, Abbas AK, Aster JC (eds.), Robbins & Cotran Pathologic Basis of Disease. 9<sup>th</sup> ed. Philadelphia. Elsevier, 2015;991-1042
21. Prat J. Ovarian germ cell tumors. In: Mutter GL, Prat J (eds.), Pathology of the female reproductive tract. 3<sup>rd</sup> ed: Elsevier Health Sciences, 2014;670-93
22. Federico A, Gravina AG, Tiso A, et al. Endoscopic diagnosis of secondary rectal teratoma in a young woman with constipation and positive fecal occult blood test. *Endoscopy*, 2010;42:E254-55