

# Progression of Hamate Hook Stress Reactions in Elite Baseball Players

Kyle R. Sochacki,\* MD, Shari R. Liberman,\* MD, Thomas L. Mehlhoff,<sup>†</sup> MD, Jaclyn M. Jones,\* BS, David M. Lintner,\* MD, and Patrick C. McCulloch,\*<sup>‡</sup> MD

*Investigation performed at Houston Methodist Orthopedics and Sports Medicine, Houston, Texas, USA*

**Background:** Hamate hook fractures can occur as a result of repetitive contact with the knob of the bat used in the sport of baseball. Hamate hook excision has resulted in excellent outcomes and return to sport (RTS) in elite baseball players. The ideal treatment for hamate stress response before the development of a fracture line is unknown.

**Purpose:** To report the outcomes of elite baseball players with hamate bone edema.

**Study Design:** Case series; Level of evidence, 4.

**Methods:** We reviewed the medical records of all elite baseball players with hamate bone edema consistent with a stress response at 2 institutions. Players were eligible for inclusion if they played collegiate or professional baseball at the time of initial injury, had magnetic resonance imaging (MRI) showing hamate bone edema, and had no radiographic evidence of acute fracture lines at initial presentation.

**Results:** A total of 4 players with a mean age of 22.8 years were included. All injuries occurred in the nondominant hand. All athletes had normal initial wrist radiographs and MRI showing hamate edema but no fracture line. Patients returned to play as tolerated and developed an acute injury at an average of 25.8 days (range, 10-56 days) from the initial presentation. Repeat radiographs demonstrated acute hamate hook fractures in all 4 (100%) athletes. All 4 athletes underwent hamate hook excision. There were no postoperative complications. All athletes returned to sport at their previous level of competition at a mean of 5.3 weeks (range, 3.6-7.3 weeks).

**Conclusion:** There is a high rate of hamate bone edema progression to acute hamate hook fracture in elite baseball players, with 100% RTS at preinjury level after hamate hook excision. We therefore recommend against prolonged rest. Continuation of play with hamate bone edema followed by hamate hook excision for acute fracture limits the time missed and obtains a faster RTS in elite baseball players.

**Keywords:** hamate fracture; baseball; surgery; outcomes

<sup>‡</sup>Address correspondence to Patrick C. McCulloch, MD, 6445 Main Street, Suite 2500, Houston, TX 77030, USA (email: pcmcculloch@houstonmethodist.org).

\*Houston Methodist Orthopedics and Sports Medicine, Houston, Texas, USA.

<sup>†</sup>Fondren Orthopedic Group, Texas Orthopedic Hospital, Houston, Texas, USA.

Final revision submitted January 13, 2020; accepted February 1, 2020.

One or more of the authors has declared the following potential conflict of interest or source of funding: D.M.L. has received educational support from Arthrex/MedInc of Texas and consulting fees from Zimmer Biomet. P.C.M. has received research support from Arthrex/MedInc of Texas and DePuy and speaking fees from Vericel/Aastron Biosciences. AOSSM checks author disclosures against the Open Payments Database (OPD). AOSSM has not conducted an independent investigation on the OPD and disclaims any liability or responsibility relating thereto.

Ethical approval for this study was obtained from the Houston Methodist Research Institute (study ID: Pro00019304).

The Orthopaedic Journal of Sports Medicine, 8(5), 2325967120919389

DOI: 10.1177/2325967120919389

© The Author(s) 2020

Hamate hook fractures account for 2% to 4% of all carpal fractures and are most frequently seen in sports that require a club, racquet, or bat.<sup>9,10</sup> In baseball, the fractures occur secondary to contact between the hamate hook and the knob of the bat.<sup>9,13</sup> During batting, the nondominant (low) hand is particularly vulnerable to injury, with 100% of hamate hook fractures occurring in this hand.<sup>2</sup>

Fractures of the hamate hook are typically treated non-operatively, with activity modification or cast immobilization in the general population.<sup>3,7,12</sup> Operative treatment with hook excision or internal fixation is used for patients with displaced fractures or nonunions. In baseball players, operative treatment of hamate hook fractures is recommended, as several studies<sup>1,2,4,5</sup> have reported excellent outcomes, with a 100% return to sport (RTS) rate after excision of the fragment. However, the ideal treatment of a stress response without a fracture line is unknown, as there is not yet a hook fragment to excise. Nonoperative treatment with rest, activity modification, and

TABLE 1  
Patient Characteristics<sup>a</sup>

Patient No.	Age, y	Position	Level of Play	Dominant Hand	Injured Hand	Mechanism of Injury	Time From Initial Injury to Complete Fracture, d	Initial Treatment	Time to Return to Sport After Surgery, wk
1	25	Outfield	MLB	Right	Left	Batting	10	None, continued to play	7.3
2	24	Catcher	MiLB (AAA)	Right	Left	Batting	56	Activity modification	3.6
3	20	Catcher	NCAA Division I	Right	Left	Batting	14	Activity modification	4.4
4	22	Catcher	MiLB (A)	Right	Left	Batting	23	Activity modification	6.0

<sup>a</sup>Triple A (AAA) is the highest level of MiLB and single A is 2 levels lower. MiLB, Minor League Baseball; MLB, Major League Baseball; NCAA, National College Athletic Association.

immobilization has been the standard. However, the optimal timing of returning to sport (batting specifically) is unknown, and even if the player is pain-free, resuming the same activity that led to the initial problem may lead to reinjury.

We have treated several of these players; however, there are limited published reports in the medical literature to guide such treatment decisions. The purpose of the current study was to report the outcomes of elite baseball players with hamate bone edema. We hypothesized that there would be a high rate of hamate bone edema progression to acute hamate hook fractures in elite baseball players, and 100% of athletes would RTS at the same level or higher after hamate hook excision.

## METHODS

Institutional review board approval was obtained for this retrospective case series, and STROBE (Strengthening the Reporting of Observational Studies in Epidemiology) guidelines were followed. Informed consent was obtained from all individual participants included in the study. The medical records of all elite baseball players with hamate bone edema at 2 institutions from January 1, 2012, to July 31, 2018, were reviewed. Players were eligible for inclusion if they played collegiate or professional baseball at the time of initial injury, had magnetic resonance imaging (MRI) showing isolated hamate bone edema, and had no evidence of acute fracture lines on MRI, computed tomography (CT), or radiographs at initial presentation.

Characteristic information was recorded for all included players. This included age at injury, level of sport participation (collegiate or professional), timing and mechanism of injury, symptoms, hand dominance, associated injuries, time from injury to surgery, postoperative complications, need for additional surgical procedures, rehabilitation, and time from surgery until full RTS participation.

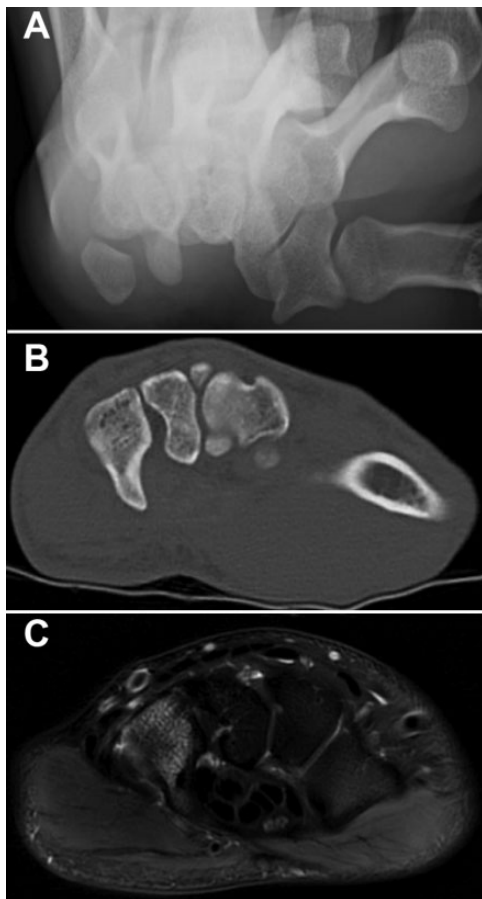
Players with hamate edema consistent with a stress response that progressed to an acute fracture of the hamate hook were treated with surgical excision. Two

fellowship-trained hand surgeons (S.R.L., T.L.M.) performed hamate hook excision by using the same technique. After inflation of the tourniquet, a longitudinal incision was made over the hamate hook. Dissection was carried down through the subcutaneous tissue into the Guyon canal, identifying and protecting the ulnar artery and ulnar nerve, with particular care to the motor branch of the ulnar nerve. The flexor tendons were retracted radially. The hamate hook was then exposed subperiosteally and excised. All the remaining rough edges were removed by using a rongeur. The flexor tendons were inspected, with no injury found in any case. The wound was then thoroughly irrigated and hemostasis achieved after deflation of the tourniquet. The incision was closed with a horizontal mattress 5-0 nylon suture. The hand was immobilized in a volar splint for 10 to 14 days followed by initiation of rehabilitation.

## RESULTS

A total of 4 athletes with a mean age of 22.8 years (range, 20-25 years) at the time of injury were included in the study (Table 1). All injuries occurred in the nondominant hand (low hand) during batting. The patients reported ulnar-sided wrist pain aggravated by gripping the bat, with no patient complaining of ulnar nerve paresthesia.

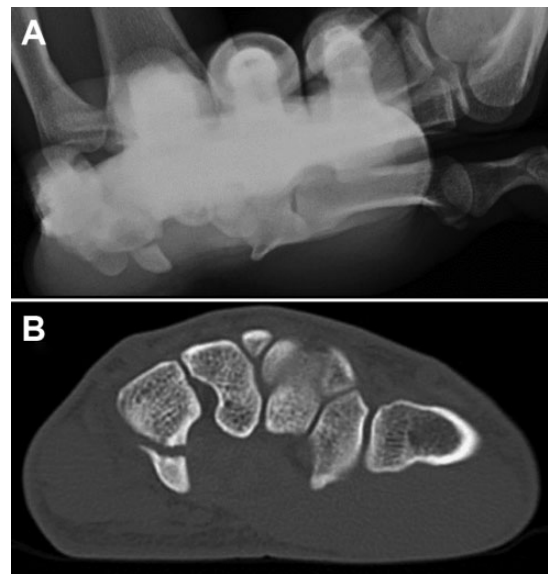
All athletes had normal wrist radiographs upon initial presentation (anteroposterior, lateral, and carpal tunnel views), and subsequent MRI (1.5- or 3-T noncontrast wrist MRI with standard sequences, including fast-spin echo and proton density) showed hamate bone edema (Figure 1). Two athletes (No. 1 and No. 3) also had CT performed at initial presentation because of the high index of suspicion for occult fracture, with no evidence of fracture (Figure 1). The return to batting was individualized based on symptoms and timing in the season. Three athletes (No. 2, No. 3, and No. 4) were treated with activity modification and held out of batting until they were symptom-free. One athlete (No. 1) continued to play with injury after missing less than 1 week.



**Figure 1.** Initial imaging of hamate on (A) normal radiograph, (B) computed tomography, and (C) magnetic resonance imaging showing hamate edema consistent with hamate bone contusion.

The 1 athlete who continued playing had increased pain while batting 10 days later. The other players returned to batting once they were pain-free and subsequently had an acute recurrence of their symptoms. Repeat radiographic imaging demonstrated acute hamate hook fractures in 4 of 4 (100%) athletes at an average of 25.8 days (range, 10-56 days) from the initial presentation (Figure 2). Three athletes (No. 1, No. 2, and No. 4) had incomplete hamate hook fracture and 1 athlete (No. 3) had complete hamate hook fracture on repeat CT imaging. All the players then underwent hamate hook excision at 31.8 days (range, 15-60 days) from the initial presentation. There were no postoperative complications.

All the athletes returned to sport at their previous level of competition: player No. 2 returned to sport at 3.6 weeks, player No. 3 returned at 4.4 weeks, player No. 4 returned at 6.0 weeks, and player No. 1 returned at 7.3 weeks postoperatively. The mean time to RTS was 5.3 weeks (range, 3.6-7.3 weeks). Player No. 2 was in Minor League Baseball (MiLB) at the time of injury and was promoted to Major League Baseball (MLB) the following year after his injury.



**Figure 2.** Follow-up imaging of hamate with hamate hook fracture on (A) radiograph and (B) computed tomography showing complete hamate hook fracture.

## DISCUSSION

The study hypothesis was confirmed, with 100% progression of hamate bone edema to acute fracture and 100% RTS after hamate hook excision in elite baseball players. This is similar to the finding of previous reports<sup>2,4</sup> about baseball players after hamate hook excision for acute fracture. However, in these studies, there was no documentation of hamate bone edema before acute fracture of the hamate hook in elite baseball players.

There are 2 case reports of successful nonoperative treatment in recreational tennis players. One was initially treated with cessation of playing tennis and wore a removable splint for 5 weeks. However, her symptoms continued, with repeat imaging demonstrating an incomplete nondisplaced fracture. She was then placed in a short arm cast for 6 weeks, with eventual resolution of symptoms and return to play.<sup>14</sup> Guha and Marynissen<sup>6</sup> reported on another recreational tennis player in whom bone edema had progressed to nondisplaced complete fracture. The fracture was initially treated with bracing for 3 weeks and then converted to a short arm cast for an additional 3 weeks, with resolution of symptoms and return to tennis. While nonoperative treatment once a complete fracture develops may be successful for recreational tennis, the high loads seen with batting in college and professional baseball hitters may be different.

The athletes in the present study followed a similar pattern of symptoms. Upon diagnosis of hamate bone edema, 3 of the 4 athletes stopped batting until resolution of symptoms. All the athletes then sustained an acute fracture of the hamate hook when they resumed batting. This occurred 14 to 56 days after the initial injury in players who refrained from batting and 10 days after injury in the 1 athlete who continued to play with symptoms. This leads

us to speculate that the bone edema that developed from repetitive stresses of batting would have eventually progressed to acute fracture regardless of the duration of the nonoperative treatment. In other words, once a hitter develops edema in the hamate, it will eventually break whether the player rested for several months or weeks or did not rest at all.

In this study, 3 of the 4 players included were catchers, with the injury occurring in their nondominant (glove) hand. This could be because of the additive effect of catching, which exposes the hamate to increased stress compared with other position players. As such, the combination of catching and hitting may place catchers at increased risk for hamate edema that eventually progresses to acute fracture of the hamate hook. This is a potentially significant observation that has not been previously described or discussed. If confirmed in other series, consideration should be given to additional protective equipment, such as the use of a donut pad to unload that area inside the catchers' glove.

In elite (professional or collegiate) baseball players, attempting prolonged nonoperative treatment of hamate bone edema with rest, activity modification, and splinting may unnecessarily increase the time missed from sport, as the players will likely progress to acute fracture upon return. In the current study, the athletes that attempted activity modification for hamate bone edema sustained an acute fracture 2 to 8 weeks after the initial presentation. This extra time missed could be detrimental to the team (number of wins) and player (game check or scouting exposure), with collegiate and professional teams playing an average of 4 games and 6 to 7 games per week, respectively.

This is evident in the case of player No. 2 in the current study. The athlete attempted nonoperative treatment of his hamate bone edema during the offseason and spring training (56 days) and still sustained an acute fracture after returning to batting practice. This ultimately led to hamate hook excision and an additional 3.6 weeks of missed playing time. He did not make it to the MLB roster that year and played an additional year in the MiLB.

Bachoura et al<sup>2</sup> and Devers et al<sup>4</sup> reported RTS times of 4.3 to 10.4 and 3 to 6 weeks, respectively, in athletes after hamate hook excision for complete hamate hook fracture. This is similar to the RTS time of 5.3 weeks (range, 3.6-7.3 weeks) after surgery in the current study. The reported complication rate after hamate hook excision is 3%, with ulnar nerve paresthesia being the most common adverse event.<sup>8,11</sup> However, there were no complications that occurred in the current study. Therefore, we believe that hamate hook excision is a safe and effective treatment for hamate hook fractures in elite baseball players.

In our opinion, there may be a role for prophylactic surgical excision of the hamate hook before fracture in patients with MRI-confirmed hamate edema in these players, depending on the timing in the season. Certainly, the players would have preferred to have had the surgery after the initial complaint, had they known that it would break and require surgery and more missed time later. However,

this is not without the potential for complications. Without a definitive fracture line, it may be difficult to determine the level of excision, leading to possible under- or over-resection of the hook. Under resection could lead to fracture of the remaining hook, while over resection may lead to fracture of the hamate body. Both instances may require further surgery and increased missed time from sport. There is also the potential risk of injury to the flexor tendons or the recurrent motor branch of the ulnar nerve, which can be devastating. Despite the potential negative outcomes, prophylactic excision may be a viable option depending on the timing, and it has been suggested by players themselves.

The limitations in this study are the small sample size and the retrospective study design, leading to a potential for selection bias. It is also possible that more athletes could have had hamate bone edema before acute fracture, but did not have an MRI or were asymptomatic or were unwilling to disclose their symptoms because of the fear of surgery and/or loss of playing time. This could also potentially lead to an underestimation of the time from initial hamate injury to acute fracture if the athlete failed to disclose the onset of symptoms.

There was a high rate of hamate bone edema progression to acute hamate hook fracture in elite baseball players in this series, with 100% RTS at preinjury level after hamate hook excision. We therefore recommend against prolonged treatment with rest and activity modification. Continuation of play with hamate bone edema followed by hamate hook excision for acute fracture limits the time missed and obtains a faster RTS in elite baseball players. There may be a role for prophylactic surgical excision of the hamate hook before fracture depending on the timing in the season. However, further studies are needed before making this recommendation.

## REFERENCES

1. Aldridge JM 3rd, Mallon WJ. Hook of the hamate fractures in competitive golfers: results of treatment by excision of the fractured hook of the hamate. *Orthopedics*. 2003;26(7):717-719.
2. Bachoura A, Wroblewski A, Jacoby SM, Osterman AL, Culp RW. Hook of hamate fractures in competitive baseball players. *Hand (N Y)*. 2013;8(3):302-307.
3. Carroll RE, Lakin JF. Fracture of the hook of the hamate: acute treatment. *J Trauma*. 1993;34(6):803-805.
4. Devers BN, Douglas KC, Naik RD, Lee DH, Watson JT, Weikert DR. Outcomes of hook of hamate fracture excision in high-level amateur athletes. *J Hand Surg Am*. 2013;38(1):72-76.
5. Futami T, Aoki H, Tsukamoto Y. Fractures of the hook of the hamate in athletes: 8 cases followed for 6 years. *Acta Orthop Scand*. 1993;64(4):469-471.
6. Guha AR, Marynissen H. Stress fracture of the hook of the hamate. *Br J Sports Med*. 2002;36(3):224-225.
7. Klausmeyer MA, Mudgal CS. Hook of hamate fractures. *J Hand Surg Am*. 2013;38(12):2457-2460.
8. Marchessault J, Conti M, Baratz ME. Carpal fractures in athletes excluding the scaphoid. *Hand Clin*. 2009;25(3):371-388.
9. Parker RD, Berkowitz MS, Brahms MA, Bohl WR. Hook of the hamate fractures in athletes. *Am J Sports Med*. 1986;14(6):517-523.
10. Rettig AC. Athletic injuries of the wrist and hand. Part I: traumatic injuries of the wrist. *Am J Sports Med*. 2003;31(6):1038-1048.

11. Smith P 3rd, Wright TW, Wallace PF, Dell PC. Excision of the hook of the hamate: a retrospective survey and review of the literature. *J Hand Surg Am.* 1988;13(4):612-615.
12. Stark HH, Chao EK, Zemel NP, Rickard TA, Ashworth CR. Fracture of the hook of the hamate. *J Bone Joint Surg Am.* 1989;71(8):1202-1207.
13. Trehan SK, Weiland AJ. Baseball and softball injuries: elbow, wrist, and hand. *J Hand Surg Am.* 2015;40(4):826-830.
14. Van Demark RE Jr, Van Demark RE, Helsper E. Stress fracture of the hook of the hamate: a case report. *S D Med.* 2015;68(4):157-159.