



Gemcitabine-induced thrombotic microangiopathy treated with eculizumab: a case report

Lisa Van den Eeckhaut^{1^}, Heidi Hannon¹, Marie Schurgers¹, Els Monsaert², Kathleen Claes^{3,4}

¹Department of Nephrology, AZ Maria Middelaes, Ghent, Belgium; ²Department of Gastroenterology, AZ Maria Middelaes, Ghent, Belgium;

³Department of Nephrology and Renal Transplantation, University Hospital Leuven, Leuven, Belgium; ⁴Department of Microbiology, Immunology and Transplantation, KU Leuven, Leuven, Belgium

Contributions: (I) Conception and design: L Van den Eeckhaut, H Hannon; (II) Administrative support: L Van den Eeckhaut, H Hannon; (III) Provision of study materials or patients: L Van den Eeckhaut, H Hannon, K Claes; (IV) Collection and assembly of data: L Van den Eeckhaut, H Hannon, K Claes; (V) Data analysis and interpretation: L Van den Eeckhaut, H Hannon, K Claes; (VI) Manuscript writing: All authors; (VII) Final approval of manuscript: All authors.

Correspondence to: Lisa Van den Eeckhaut. Buitening Sint-Denijs 30, 9000 Ghent, Belgium. Email: lvdeekhaut@outlook.com.

Background: Gemcitabine is a broadly used chemotherapeutic agent that can cause a rare but life-threatening complication called thrombotic microangiopathy (TMA). Early recognition is crucial as therapy options are limited.

Case Description: We report the case of a 46-year-old patient with pancreatic adenocarcinoma who presented with severe anemia and thrombocytopenia as well as acute kidney injury. A diagnosis of gemcitabine-induced TMA was made. He became rapidly transfusion and dialysis dependent. Despite discontinuation of gemcitabine and treatment with high-dose corticotherapy as well as plasmapheresis, no improvement in both renal and hematological parameters was seen. Treatment with eculizumab was initiated. One week after the first administration, the patient no longer required packed cells nor platelet transfusions and one month later, dialysis could be discontinued. After five doses, treatment with eculizumab was stopped. Four months later, his serum creatinine was 1 mg/dL.

Conclusions: This case report illustrates the promising beneficial effects of eculizumab in gemcitabine-induced TMA, both regarding transfusion dependence as well as improvement in renal function, thereby allowing further therapy options in patients with an active malignancy.

Keywords: Gemcitabine-induced thrombotic microangiopathy; eculizumab; hemolytic uremic syndrome; case report

Submitted May 24, 2022. Accepted for publication Oct 21, 2022.

doi: 10.21037/jgo-22-509

View this article at: <https://dx.doi.org/10.21037/jgo-22-509>

Introduction

Thrombotic microangiopathy (TMA) is characterized by the triad of thrombocytopenia, microangiopathic hemolytic anemia and organ injury, including acute kidney injury. The classification of TMAs is constantly evolving with the greater understanding of the molecular basis and the role of complement dysregulation (1). Several drugs have been thought to have an association with TMA, although

a definitive causality has been difficult to establish. Drug-induced TMA occurs through either immune-mediated damage or direct toxicity of the drug. Gemcitabine is a pyrimidine antimetabolite used for the treatment of several types of malignancies. The incidence of gemcitabine-induced TMA has been reported to be between 0.02% and 2.2% (2). Early recognition is crucial as mortality rates go up to 60% (3). Treatment of drug-induced TMA includes supportive therapy and withdrawal of the drug, but more

[^] ORCID: 0000-0001-5869-5763.

specific therapy options are lacking (1). Several case reports have been published in which patients are treated with eculizumab, a monoclonal antibody directed against the complement protein C5, that has already been approved for the treatment of complement-mediated TMA (2-15). Our objective is to present a patient with gemcitabine-induced TMA who was successfully treated by eculizumab, and to review current literature regarding this topic. We present the following article in accordance with the CARE reporting checklist (available at <https://jgo.amegroups.com/article/view/10.21037/jgo-22-509/rc>).

Case presentation

We report the case of a 46-year-old male patient with stage IV pancreatic adenocarcinoma who received neoadjuvant gemcitabine—nab-paclitaxel and underwent a pancreaticosplenectomy followed by adjuvant gemcitabine—nab-paclitaxel. The cumulative dose of gemcitabine was 27,500 mg and nab-paclitaxel 3,437.5 mg. Five days after the eighth cycle of chemotherapy, the patient presented at the Emergency Department with fatigue, recurrent epistaxis, headache and anorexia. Clinical examination showed a weakened and pale patient, with a normal blood pressure. Biochemically, we noticed severe anemia (hemoglobin of 6.4 g/dL), thrombocytopenia ($26.000 \times 10^3/\text{mm}^3$), signs of hemolysis [increased lactate dehydrogenase (LDH) of 956 U/L, low haptoglobin of <0.10 g/L] and an acute kidney injury (creatinine level of 1.88 mg/dL corresponding with an estimated glomerular filtration rate (eGFR) according to the Cockcroft-Gault equation of 42 mL/min/1.73 m² with baseline creatinine level of 0.79 mg/dL). White blood cell count was normal. Direct Coombs test was negative and peripheral blood smear showed the presence of schistocytes confirming the diagnosis of TMA. Reticulocyte level was initially decreased, probably as a result of bone marrow suppression due to recent chemotherapy. During the follow-up time the reticulocyte level was elevated. Testing for C3, C4, fibrinogen, prothrombin time (PT) and activated partial thromboplastin time (aPTT) were normal (0.94 g/L, 0.2 g/L, 280 mg/dL, 72% and 31.9 s respectively). Quantitative analysis of the complement alternative pathway [complement factor H (CFH), complement factor I (CFI), CD46/membrane cofactor protein (MCP), anti-factor H antibodies, ratio of degradation product of factor B and factor B (FBb/FB ratio)] demonstrated normal values. Urinalysis showed proteinuria and hematuria. The patient was started on high doses of intravenous corticotherapy (methylprednisolone 80 mg daily) as well as on daily plasmapheresis, which was

discontinued when ADAMTS13 deficiency was excluded (ADAMTS13 activity was 77%) and no improvement was seen after two days. Based on some supporting evidence showing a reduction of the concentration of ultra-large von Willebrand factor (VWF) multimers *in vitro* and in an animal model in thrombotic thrombocytopenic purpura (TTP), as well as a resolution of abnormal electrocardiogram (ECG) findings in a patient with ponatinib-associated drug-induced TMA affecting the coronary microvasculature, a trial with N-acetylcysteine (NAC; 8,000 mg daily after a loading dose of 12,000 mg) was done (16-18). Unfortunately, again without result and NAC was discontinued after two days. The patient's condition rapidly deteriorated and he became transfusion and dialysis dependent (due to volume overload and anuria). The required vaccinations before treatment with eculizumab were given. Access to eculizumab was granted through the company's Global Access to Medicines Program, and started four days after submitting a request. Treatment with eculizumab was initiated 19 days after presentation at a dose of 900 mg IV weekly for four doses, followed by 1,200 mg IV for the fifth dose. The second dose needed to be postponed by one week due to an abdominal infection, with improvement after empiric antibiotic therapy with broad-spectrum antibiotics (piperacillin-tazobactam). After only one cycle, the patient no longer required platelet and packed cells transfusion. CH50 level was low (7 U/mL), suggesting an effective complement inhibition. One month after the initiation of eculizumab, dialysis could be discontinued (*Figure 1*). The patient received five doses of eculizumab in total. Unfortunately, he developed progressive oncological disease necessitating second line chemotherapy. Second line treatment with liposomal irinotecan and 5-fluorouracil (modified de Gramont) was initiated. Creatinine level normalized to 1 mg/dL corresponding with an eGFR of 90 mL/min/1.73 m².

All procedures performed in this study were in accordance with the ethical standards of the institutional and/or national research committee(s) and with the Declaration of Helsinki (as revised in 2013). Written informed consent was obtained from the patient for publication of this case report and the accompanying image. A copy of the written consent is available for review by the editorial office of this journal.

Discussion

Eculizumab is a recombinant humanized monoclonal antibody that binds to C5 and prevents the formation of the proinflammatory C5a and membrane attack complex C5b9 in the alternative pathway of the complement system, thereby inhibiting inappropriate systemic coagulation (1,5). It has been

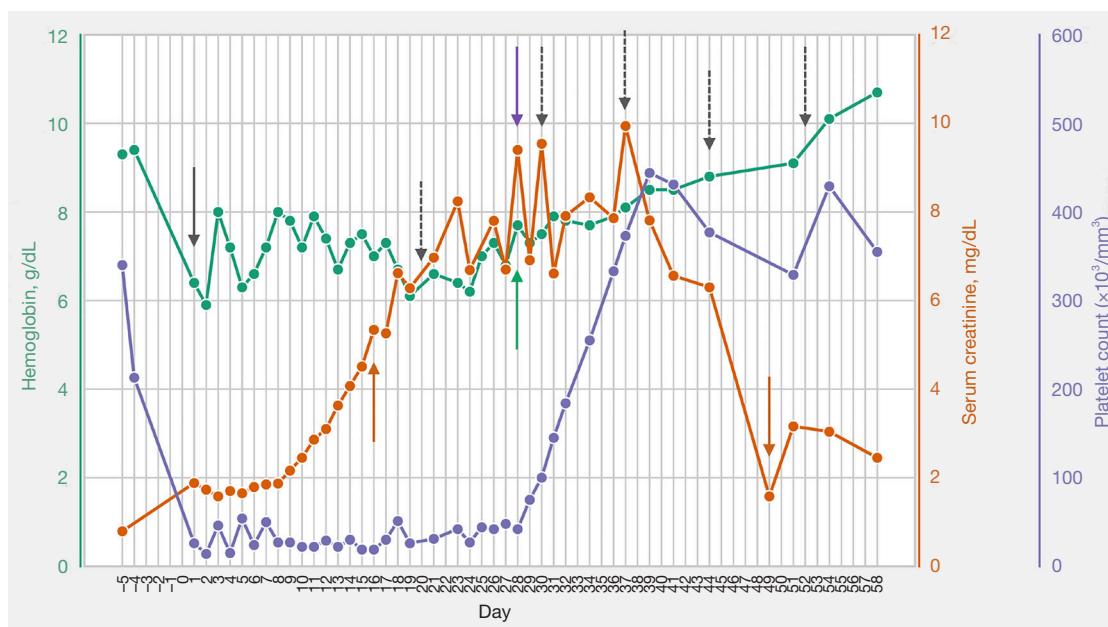


Figure 1 Trend of hemoglobin (g/dL), platelet count ($\times 10^3/\text{mm}^3$) and serum creatinine (mg/dL) with eculizumab. Black full arrow indicates presentation at the Emergency Department (day 1). Dashed arrows indicate administration of eculizumab (day 20, 30, 37, 44 and 52). Green full arrow indicates last transfusion of packed cells (day 28). Purple full arrow indicates last transfusion of platelets (day 28). Orange full arrows indicate initiation (day 16) and discontinuation (day 49) of hemodialysis.

approved for the treatment of complement-mediated TMA (1).

TMA occurring in a patient with a malignancy can be both malignancy or drug-induced. The exact pathophysiology of gemcitabine-induced TMA is not well established. In a recent retrospective study, deposits of C5b9 in kidney biopsies suggest an at least partial role of complement activation, which may result from a direct endothelial toxicity of the drug (4). This could also explain why treatment with eculizumab is potentially successful in this setting. Apart from drug-induced TMA through direct endothelial damage (type 1, dose dependent) or immune-mediated through the development of drug-dependent autoantibodies (type 2, none-dose dependent), the malignancy itself can also cause TMA (paraneoplastic TMA) (19). This can arise from metastases in the microvasculature or direct invasion of tumor cells in the bone marrow (2). In this case, it was more likely that the cause was drug-induced. At the time when the patient developed TMA, he showed no signs of progressive disease. It was only after discontinuation of chemotherapy and during eculizumab treatment that the patient showed disease progression. Furthermore, paraneoplastic TMA usually does not respond well to eculizumab and would more likely improve when there is a good response to

chemotherapy (19). Also, paraneoplastic TMA is most frequently seen in metastatic disease (91.8%), which was not the case in our patient (20). Gemcitabine has shown to have a causal association with TMA (1). Although TMA caused by nab-paclitaxel has been rarely reported, its potential role in causing drug-induced TMA cannot be denied. A recent article suggests a potential drug interaction between nab-paclitaxel and gemcitabine thereby increasing the risk of developing gemcitabine-induced TMA (21).

Aside from permanent discontinuation of gemcitabine and supportive care, the optimal treatment is not known (4). The use of eculizumab in gemcitabine-induced TMA is limited probably due to several factors. Firstly, optimal timing and exact duration of treatment as well as dose intervals to keep patients in remission is unknown. Secondly, treatment with eculizumab comes at a high cost (2). Thirdly, the impact of complement mediated treatment on tumor progression is not known. However, if it could keep the patient off dialysis, it might be more cost efficient than suspected and impose a significant impact on the patient's quality of life. Therefore, one could speculate that eculizumab should be instituted without delay, after balancing the patient's life expectancy and performance status against the risks of eculizumab (e.g., infectious complications) and benefits of improving TMA.

Currently in Belgium, eculizumab in drug-induced TMA is not reimbursed.

Current evidence is limited to case reports and case series. To our knowledge, 15 publications (including this case report) have described 33 patients in total with gemcitabine-induced TMA treated with eculizumab (2-15). *Table 1* illustrates the demographic factors and outcome parameters of these cases. A renal response and hematological response were seen in 26 patients (79%) and 28 patients (85%) respectively. Even though these findings seem promising, they should be interpreted with caution. Firstly, there might be publication bias. Secondly, a contributing role is suspected in hematological response when chemotherapy is temporarily discontinued. Also, the interpretation of these results is limited by the

heterogeneity of patient characteristics and small population groups. Furthermore, it cannot be excluded that patients showed a late response to treatment discontinuation while already receiving eculizumab. Unfortunately, we do not have data on complement activation (C5b9) or complement deposition in a renal biopsy because an elevated level would have added to the case of treatment with complement inhibition. Finally, it is to be suspected that the mortality rates of gemcitabine-induced TMA are inseparably related to the prognosis of the underlying malignancy.

Nonetheless, this case reports adds to limited literature on the successful use of terminal complement blockade by eculizumab for gemcitabine-induced TMA, with improvement in hematological and renal outcomes. Furthermore, as our case illustrates, our patient became

Table 1 Publications of eculizumab treatment for gemcitabine-induced TMA

Study	Year	Patient	Age/malignancy type	Unsuccessful treatments prior to eculizumab	Doses of eculizumab	Renal response to eculizumab	Hematological response to eculizumab
Al Ustwani <i>et al.</i> (5)	2014	1	75/lung	Drug cessation	8	Yes	Yes
		2	70/pancreatic	Drug cessation, corticotherapy	6	Yes	Yes
		3	73/choleangio	Drug cessation	6	Yes	NA
		4	69/lung	Plasmapheresis	5	Yes	Yes
Starck <i>et al.</i> (6)	2014	5	45/duodenal	Drug cessation, plasmapheresis, Rituximab	4	Yes	Yes
Rogier <i>et al.</i> (7)	2016	6	68/pancreatic	Drug cessation, plasmapheresis	7	Yes	Yes
Nanjappa <i>et al.</i> (8)	2017	7	56/pancreatic	Drug cessation, plasmapheresis	NA	No	Yes
Facchini <i>et al.</i> (3)	2017	8	3/medulloblastoma	Rituximab, defibrotide, immunoglobulins, plasmapheresis	7	Yes	Yes
Gosain <i>et al.</i> (9)	2017	9	54/pancreatic	Plasmapheresis	NA	Yes	Yes
López Rubio <i>et al.</i> (10)	2017	10	74/pancreatic	Drug cessation, plasmapheresis	7	Yes	Yes
Krishnappa <i>et al.</i> (11)	2018	11	64/pancreatic	Plasmapheresis, drug cessation	18 ^b	Yes	Yes
Martin <i>et al.</i> (12)	2019	12	56/pancreatic	Corticotherapy, plasmapheresis	10 ^b	Yes	Yes

Table 1 (continued)

Table 1 (continued)

Study	Year	Patient	Age/malignancy type	Unsuccessful treatments prior to eculizumab	Doses of eculizumab	Renal response to eculizumab	Hematological response to eculizumab
Daviet <i>et al.</i> (13)	2019	13	53–68/pancreatic and lung ^c	Plasmapheresis (n=4), drug cessation (n=1)	NA	Yes	Yes
		14	53–68/pancreatic and lung ^c	Plasmapheresis (n=4), drug cessation (n=1)	NA	No	Yes
		15	53–68/pancreatic and lung ^c	Plasmapheresis (n=4), drug cessation (n=1)	NA	No	Yes
		16	53–68/pancreatic and lung ^c	Plasmapheresis (n=4), drug cessation (n=1)	NA	No	Yes
		17	53–68/pancreatic and lung ^c	Plasmapheresis (n=4), drug cessation (n=1)	NA	No	No
Burns <i>et al.</i> (14)	2020	18	39/pancreatic	Drug cessation	1	Yes	Yes
Sethi <i>et al.</i> (2)	2021	19	67/pancreatic	Drug cessation	NA	Yes	NA
Efe <i>et al.</i> (15)	2021	20	29/cholangio	Drug cessation	6	Yes	Yes
Grall <i>et al.</i> (4)	2021	21	36/ovarian	Drug cessation ± plasmapheresis ^a	4	Yes	Yes
		22	64/ovarian	Drug cessation ± plasmapheresis ^a	3	No	No
		23	54/pancreatic	Drug cessation ± plasmapheresis ^a	22	Yes	Yes
		24	69/pancreatic	Drug cessation ± plasmapheresis ^a	3	No	No
		25	64/ovarian	Drug cessation ± plasmapheresis ^a	7	Yes	Yes
		26	68/pancreatic	Drug cessation ± plasmapheresis ^a	14	Yes	Yes
		27	59/lung	Drug cessation ± plasmapheresis ^a	5	Yes	Yes
		28	57/lung	Drug cessation ± plasmapheresis ^a	4	Yes	Yes
		29	52/uterine	Drug cessation ± plasmapheresis ^a	2	Yes	Yes
		30	50/pancreatic	Drug cessation ± plasmapheresis ^a	2	Yes	Yes
		31	56/ovarian	Drug cessation ± plasmapheresis ^a	3	Yes	Yes
32	55/ovarian	Drug cessation ± plasmapheresis ^a	4	Yes	Yes		
Van den Eeckhaut <i>et al.</i> (present study)	2022	33	46/pancreatic	Drug cessation, corticotherapy, plasmapheresis, N-acetylcysteine	5	Yes	Yes

^a, five patients received plasmapheresis, not mentioned which patients; ^b, not explicitly reported; number of doses was estimated based on reported schedule of eculizumab; ^c, not further specified. NA, not available.

independent of dialysis with a major effect on quality of life. It also highlights the importance of accurate diagnosis of TMA when a patient treated with chemotherapy presents with progressive acute kidney injury, hemolysis and thrombocytopenia.

Conclusions

This case report shows promising beneficial effects of eculizumab in gemcitabine-induced TMA, regarding transfusion dependence as well as improvement in renal function. It also shows that larger controlled studies are needed to confirm these effects.

Acknowledgments

Funding: None.

Footnote

Reporting Checklist: The authors have completed the CARE reporting checklist. Available at <https://jgo.amegroups.com/article/view/10.21037/jgo-22-509/rc>

Conflicts of Interest: All authors have completed the ICMJE uniform disclosure form (available at <https://jgo.amegroups.com/article/view/10.21037/jgo-22-509/coif>). KC has received consultancy fees from Alexion, Astellas, Sanofi. The other authors have no conflicts of interest to declare.

Ethical Statement: The authors are accountable for all aspects of the work in ensuring that questions related to the accuracy or integrity of any part of the work are appropriately investigated and resolved. All procedures performed in this study were in accordance with the ethical standards of the institutional and/or national research committee(s) and with the Declaration of Helsinki (as revised in 2013). Written informed consent was obtained from the patient for publication of this case report and the accompanying image. A copy of the written consent is available for review by the editorial office of this journal.

Open Access Statement: This is an Open Access article distributed in accordance with the Creative Commons Attribution-NonCommercial-NoDerivs 4.0 International License (CC BY-NC-ND 4.0), which permits the non-commercial replication and distribution of the article with

the strict proviso that no changes or edits are made and the original work is properly cited (including links to both the formal publication through the relevant DOI and the license). See: <https://creativecommons.org/licenses/by-nc-nd/4.0/>.

References

1. Brocklebank V, Wood KM, Kavanagh D. Thrombotic Microangiopathy and the Kidney. *Clin J Am Soc Nephrol* 2018;13:300-17.
2. Sethi A, Moses R. Atypical Hemolytic Uremic Syndrome: Cancer-Induced or Chemotherapy-Induced? *Cureus* 2021;13:e13260.
3. Facchini L, Lucchesi M, Stival A, et al. Role of eculizumab in a pediatric refractory gemcitabine-induced thrombotic microangiopathy: a case report. *J Med Case Rep* 2017;11:209.
4. Grall M, Daviet F, Chiche NJ, et al. Eculizumab in gemcitabine-induced thrombotic microangiopathy: experience of the French thrombotic microangiopathies reference centre. *BMC Nephrol* 2021;22:267.
5. Al Ustwani O, Lohr J, Dy G, et al. Eculizumab therapy for gemcitabine induced hemolytic uremic syndrome: case series and concise review. *J Gastrointest Oncol* 2014;5:E30-3.
6. Starck M, Wendtner CM. Use of eculizumab in refractory gemcitabine-induced thrombotic microangiopathy. *Br J Haematol* 2014;164:894-6.
7. Rogier T, Gerfaud-Valentin M, Pouteil-Noble C, et al. Clinical efficacy of eculizumab as treatment of gemcitabine-induced thrombotic microangiopathy: A case report. *Rev Med Interne* 2016;37:701-4.
8. Nanjappa S, Singh V, Uttamchandani S, et al. Thrombotic Microangiopathy in a Patient Treated With Gemcitabine. *Cancer Control* 2017;24:54-6.
9. Gosain R, Gill A, Fuqua J, et al. Gemcitabine and carfilzomib induced thrombotic microangiopathy: eculizumab as a life-saving treatment. *Clin Case Rep* 2017;5:1926-30.
10. López Rubio ME, Rodado Martínez R, Illescas ML, et al. Gemcitabine-induced hemolytic-uremic syndrome treated with eculizumab or plasmapheresis: two case reports. *Clin Nephrol* 2017;87:100-6.
11. Krishnappa V, Gupta M, Shah H, et al. The use of eculizumab in gemcitabine induced thrombotic microangiopathy. *BMC Nephrol* 2018;19:9.
12. Martin K, Roberts V, Chong G, et al. Eculizumab therapy

- in gemcitabine-induced thrombotic microangiopathy in a renal transplant recipient. *Oxf Med Case Reports* 2019;2019:omz048.
13. Daviet F, Rouby F, Poullin P, et al. Thrombotic microangiopathy associated with gemcitabine use: Presentation and outcome in a national French retrospective cohort. *Br J Clin Pharmacol* 2019;85:403-12.
 14. Burns ST, Damon L, Akagi N, et al. Rapid Improvement in Gemcitabine-associated Thrombotic Microangiopathy After a Single Dose of Eculizumab: Case Report and Review of the Literature. *Anticancer Res* 2020;40:3995-4000.
 15. Efe O, Goyal L, Galway A, et al. Treatment of Gemcitabine-Induced Thrombotic Microangiopathy Followed by Gemcitabine Rechallenge With Eculizumab. *Kidney Int Rep* 2021;6:1464-8.
 16. Chen J, Reheman A, Gushiken FC, et al. N-acetylcysteine reduces the size and activity of von Willebrand factor in human plasma and mice. *J Clin Invest* 2011;121:593-603.
 17. George JN, López JA, Konkle BA. N-Acetylcysteine: an old drug, a new insight, a potentially effective treatment for thrombotic thrombocytopenic purpura. *Transfusion* 2014;54:1205-7.
 18. Wu MD, Hodovan J, Kumar K, et al. Ponatinib coronary microangiopathy: novel bedside diagnostic approach and management with N-acetylcysteine. *Blood Adv* 2020;4:4083-5.
 19. Perrier Q, Noble J, Grangé S, et al. Atypical Evolution of Secondary Hemolytic Uremic Syndrome Defined as Paraneoplastic Syndrome under Eculizumab and Palbociclib Therapies. *Case Rep Oncol* 2021;14:676-80.
 20. Kheder El-Fekih R, Deltombe C, Izzedine H. Thrombotic microangiopathy and cancer. *Nephrol Ther* 2017;13:439-47.
 21. Allard J, Bonnet M, Laurent L, et al. Microangiopathy associated with gemcitabine: a drug interaction with nab-paclitaxel? A case series and literature review. *Eur J Clin Pharmacol* 2022;78:1087-93.

Cite this article as: Van den Eeckhaut L, Hannon H, Schurgers M, Monsaert E, Claes K. Gemcitabine-induced thrombotic microangiopathy treated with eculizumab: a case report. *J Gastrointest Oncol* 2022;13(6):3314-3320. doi: 10.21037/jgo-22-509