

## Research Article

# Effects of Soft Tissue Closure on Medication-Related Osteonecrosis of the Jaw in a Rabbit Model with Tooth Extraction: A Pilot Study

Ru Qing Yu,<sup>1</sup> Jing Wen Li ,<sup>1</sup> Jing Yi Wang ,<sup>1</sup> Lei Huo,<sup>2</sup> and Li Wu Zheng <sup>1</sup>

<sup>1</sup>Discipline of Oral & Maxillofacial Surgery, Faculty of Dentistry, The University of Hong Kong, Hong Kong SAR, China

<sup>2</sup>Department of Orthodontics, The First Affiliated Hospital of Zhengzhou University, Zhengzhou, Henan Province, China

Correspondence should be addressed to Li Wu Zheng; [lwzheng@hku.hk](mailto:lwzheng@hku.hk)

Received 27 July 2021; Revised 17 November 2021; Accepted 24 November 2021; Published 15 December 2021

Academic Editor: Gianmarco Saponaro

Copyright © 2021 Ru Qing Yu et al. This is an open access article distributed under the Creative Commons Attribution License, which permits unrestricted use, distribution, and reproduction in any medium, provided the original work is properly cited.

**Objectives.** The study investigated the effect of soft tissue closure after tooth extraction on the prevention of medication-related osteonecrosis of the jaw in a rabbit model. **Materials and Methods.** Twenty female New Zealand white rabbits were randomly assigned into the experimental group administrated with zoledronic acid (ZA) and control groups treated with saline. Bilateral lower premolar extraction was performed 4 weeks after ZA/saline administration. Immediately after extraction, the wound on the right mandible was closed by suture while the other side was left open. Animals were sacrificed 4 weeks and 8 weeks after tooth extraction. Fluorochrome labeling solutions were injected subcutaneously to evaluate the bone growth rates. The mandibles were harvested and subjected for microcomputed tomography, confocal microscope, and histomorphological examinations. **Results.** All extraction sites healed well without any signs of infection. Trabecular thickness (Tb.Th) was significantly higher in the ZA-treated group than in the control group at both week 4 and week 8, while no significant difference was detected in the rest of the assessed parameters. The bone growth rate in mandibles showed gradual reduction in the ZA-treated group. Histological analysis showed that at week 8, the animals in the ZA-treated group had significantly higher incidence of osteonecrosis than that in the control group, while no significance was revealed between the sutured and nonsutured side. **Conclusions.** ZA treatment significantly reduces bone growth rates but does not reveal a significant effect on bone mineral density and bone microarchitecture. Soft tissue closure of the extraction socket does not reduce the incidence of ONJ in the ZA-treated rabbit model.

## 1. Introduction

Bisphosphonates (BPs) are known to inhibit the activity of osteoclasts and thus reduce bone resorption and the subsequent bone remodeling. BPs are widely used against overactive osteoclasts in various bone diseases, such as osteoporosis, Paget's disease, and bone metastasizing malignant tumours, including multiple myeloma, breast cancer, and prostate cancer [1–3]. Medication-related osteonecrosis of the jaw (MRONJ) is a severe though rare complication after bisphosphonates and/or other antiresorptive or antiangiogenic medication treatment in a variety of malignant and benign bone diseases [4].

There are many risk factors associated with the development of MRONJ, including types, dosage, route of medication used, duration of therapy, dentoalveolar surgeries, age of the patients, systemic conditions, and genetic factors [4–7]. Among all the risks, the most common risk factor for MRONJ is tooth extraction [6, 8, 9].

MRONJ was described to occur exclusively in maxillofacial bones with a preference in mandible over maxilla [10–13]. One of the many explanations for this site-specific feature of MRONJ is that the oral microbes may cause inflammation or infection under the specific condition of oral wound [14–16]. However, how these oral microbes affect bone healing and whether an open oral wound puts

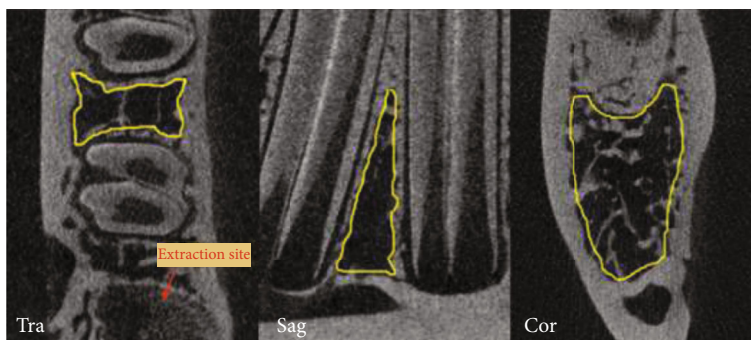


FIGURE 1: Region of interest (ROI), as outlined in the pictures, is selected at one tooth away from the extraction site. It is manually selected in the transverse view from the bottom layer (1<sup>st</sup> slice) to the 300<sup>th</sup> layer. The bottom layer is set at 100 slices above where the root was completely absent in the transverse view. The ROI is shown in three different planes here. Tra: transverse; Sag: sagittal; Cor: coronal.

an individual who is receiving IV BPs in a higher risk for developing osteonecrosis of the jaw remain unclear.

The objective of this study was to investigate the effect of soft tissue closure of tooth extraction on preventing MRONJ in a rabbit model treated with ZA.

## 2. Materials and Methods

**2.1. Study Design.** This study was approved by the Committee on Use Live Animal for Teaching and Research, The University of Hong Kong (CULATR No. 3774-15). The animal holding facility and the veterinary guidance were provided by Laboratory Animal Unit (LAU) of Li Ka Shing Faculty of Medicine, The University of Hong Kong.

Twenty adult female New Zealand white rabbits (3.2 kg to 4.2 kg) were randomly equally assigned into control and experiment groups. Five rabbits in each group were sacrificed at week 4 postoperatively as the short-term subgroups, and the other 5 rabbits were sacrificed at week 8 postoperatively as the long-term subgroups (the surgery day was set as the baseline of day 0). The rabbits in the experiment groups were given zoledronic acid subcutaneously three times per week with a dosage of 0.1 mg/kg for four weeks prior to surgery (rabbits underwent tooth extraction on mandible and dental implant placement on calvarial bone). The dental implant placement was for other investigation, and the results have been published [17]. The injection continued after the surgery and throughout the whole experiment until sacrifice. The control rabbits were given saline using the same regimen as that in the experimental group. In total, animals were injected 8 weeks and 12 weeks of zoledronic acid or saline in the short-term groups and long-term groups, respectively.

**2.2. Tooth Extraction.** All the tooth extraction procedures were performed under general anaesthesia. Heart rate, respiration rate, SpO<sub>2</sub>, and body temperature were monitored and recorded throughout the entire procedure. The rabbit was placed in a prone position with the head tilted slightly to the operating side. The gingival separator was used to separate the gingival tissue around the first premolar until touching the edge of the alveolar bone. Then, the root elevator was used to wedge between the root and alveolar bone

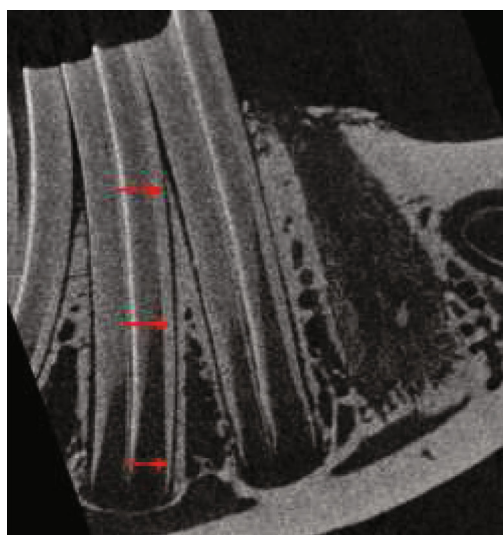


FIGURE 2: Periodontal ligament width is tested at 3 levels, neck, apical, and middle point between them. Both left and right first molars are measured.

lightly around the tooth and went slowly down as deep as possible. Lastly, the tooth was removed using a forcep. Tooth extraction was performed on the first premolars on both sides of the mandible. Curettage of the residual soft tissue in the tooth socket and irrigation of the surgical site were done subsequently. After confirming, there was no active bleeding of the wound, the wound of the extraction socket on the right side was sutured with a resorbable suture Vicryl (Ethilon Inc., Cornelia, GA), while the other side was left open. Postoperative analgesics and food care were provided under guidance. The food and water intake, body weight, behavior pattern, and daily activity were closely observed and recorded.

**2.3. Fluorochrome Labeling.** Three types of fluorochrome labeling solutions were prepared and were injected subcutaneously in a sequence using the protocol described in our recent publication [18, 19]. Briefly, calcein green (10 mg/kg, Sigma-Aldrich-C0875, St. Louis, USA), alizarin

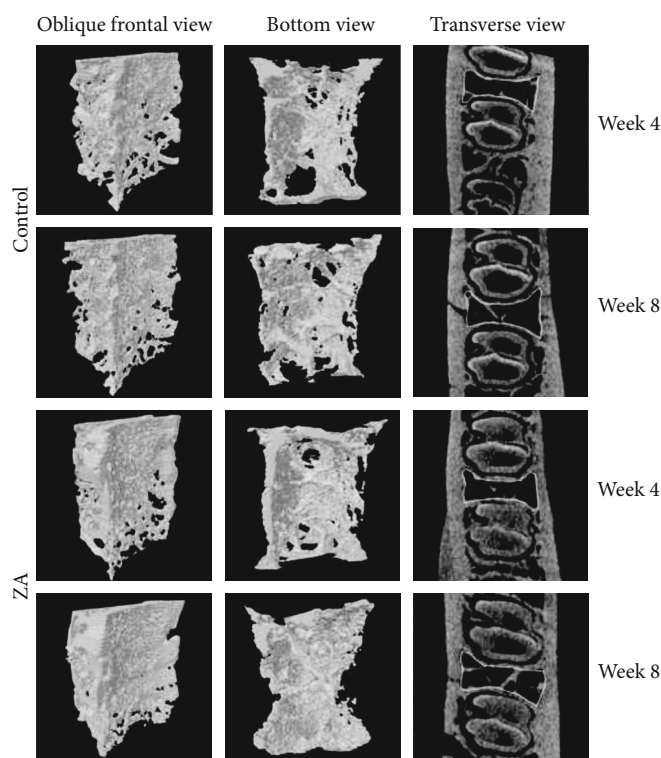


FIGURE 3: ROI demonstrated as three-dimensional models in oblique frontal view and bottom view. In transverse view also shows the ROI lined up in yellow.

complexone (30 mg/kg, Sigma-Aldrich -A3882, St. Louis, USA), and oxytetracycline (20 mg/kg, Sigma-Aldrich -O5875, St. Louis, USA) with an interval of one week or two weeks, in the short-term subgroups and the long-term subgroups, respectively.

**2.4. Sacrifice and Sample Collection.** Euthanization of the animals was conducted by intravenous injection of ketamine through the ear vein at week 4 and week 8 postoperatively. The mandible was retrieved and preserved in 10% neutral buffered formalin solution for future assessment.

**2.5. Microcomputed Tomography (Micro-CT) Examinations.** For evaluation of the bone mineral density (BMD), bone volume fraction (BV/TV), and microtrabecular architecture, the specimens were scanned at 88 kV and 100  $\mu$ A intensity with a resolution of 17.3  $\mu$ m pixel using micro-computed tomography scanning (SkyScan1076; Bruker, Kontich, Belgium). The reconstruction data were retrieved and analyzed with the CT analyzer software, version 1.9 (Skyscan, Kontich, Belgium). The trabecular bone tissue in between two teeth at one tooth away from the extraction socket was manually selected as the region of interest (ROI) in the transverse view (Figure 1). The bottom layer was set at 100 layers above where the root was completely absent in the transverse view. In total, 300 layers were selected. For morphometric analysis of trabecular architecture, BV (bone volume), TV (tissue volume), BV/TV [20], Tb.Th (trabecular thickness, 3D measures of the average thickness of the cancellous bone structure [21]), Tb.N (trabecular number,

the number of trabecular plates per unit length [20, 22]), and Tb.Sp (trabecular separation, average diameter of the marrow cavities [21]) were analyzed.

In addition, the width of periodontal ligament space of the first molars was measured at three levels: tooth neck, middle, and apical (Figure 2). Data were summarized and subjected to statistical analysis.

**2.6. Fluorochrome Labeling Analysis.** After Micro-CT assessment, the undecalcified specimens were embedded in Technovit® 9100 PMMA (Heraeus Kulzer GmbH, Germany) and proceed to ground sections preparation for fluorochrome labeling and histological analysis. Each section was grinded and polished to approximately 30  $\mu$ m thickness. Each specimen was able to make 2 to 3 optimal sections.

Zeiss LSM 710 Upright Confocal Microscope and the Zeiss LSM 780 Inverted Confocal Microscope (Carl Zeiss, Oberkochen, Germany) were used for fluorochrome labeling analysis. The distances between two sequenced fluorochrome labeling were manually measured using the ZEN lite software at five randomly selected spot.

Bone growth rates were calculated by measuring the average distance between the two sequenced fluorescent line and then dividing the distance by the interval days between two sequenced injections according to the protocol of our previous study [19].

**2.7. Histological Examinations.** Sections were proceeded to histomorphological examinations after laser confocal

TABLE 1: Statistical analysis result of bone mineral density (BMD) and bone microstructure indices (mean  $\pm$  SD).

Parameters	Groups				<i>P</i> value*	<i>P</i> value**
	Control long-term	Control short-term	ZA long-term	ZA short-term		
BV/TV	0.27 $\pm$ 0.08	0.30 $\pm$ 0.06	0.34 $\pm$ 0.02	0.35 $\pm$ 0.06	0.118	0.248
BMD	0.38 $\pm$ 0.09	0.41 $\pm$ 0.06	0.45 $\pm$ 0.02	0.46 $\pm$ 0.06	0.137	0.259
Tb.Th (mm)	0.17 $\pm$ 0.02	0.18 $\pm$ 0.01	0.21 $\pm$ 0.02	0.20 $\pm$ 0.01	0.012	0.019
Tb.N (1/mm)	1.53 $\pm$ 0.36	1.65 $\pm$ 0.27	1.63 $\pm$ 0.18	1.75 $\pm$ 0.27	0.638	0.582
Tb.Sp (mm)	0.59 $\pm$ 0.11	0.58 $\pm$ 0.11	0.55 $\pm$ 0.06	0.55 $\pm$ 0.11	0.546	0.722

BV/TV: bone volume/tissue volume; BMD: bone mineral density; Tb.Sp: trabecular separation; Tb.Th: trabecular thickness; Tb.N: trabecular number.  
\**P* value between control group and ZA group at week 8. \*\**P* value between control group and ZA group at week 4.

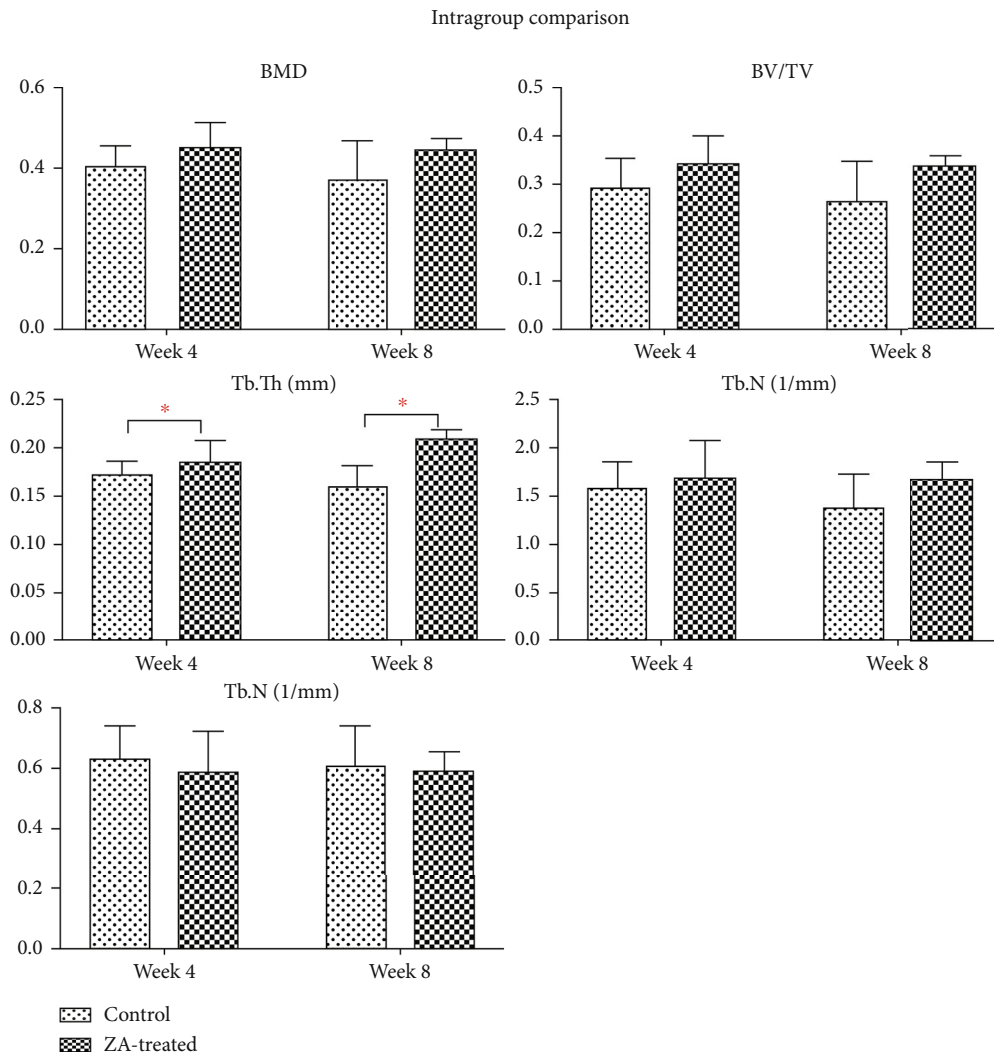


FIGURE 4: Intergroup comparison of BMD, BV/TV, Tb.Th, Tb.N, and Tb.Sp in the mandible between control and ZA-treated groups at time point of week 4 and week 8. Significant higher Tb.Th is seen in ZA-treated animals at both week 4 and week 8. No significant difference is detected in the rest of the assessed parameters.

imaging. Goldner's trichrome staining protocol was used to stain the sections [23].

Microscope images were obtained using the Eclipse LV100 POL (Nikon, Japan). Areas of osteonecrosis were defined by 8-10 adjacent empty osteocytic lacunae with the loss of osteocytes [24, 25]. Evaluation of osteonecrosis

was determined as either no osteonecrosis or osteonecrosis presenting in the ten randomly selected high-power fields (20 $\times$ ), the incidence of which was calculated by dividing the number of animals with osteonecrosis by the total number of animals in a group at each time point.

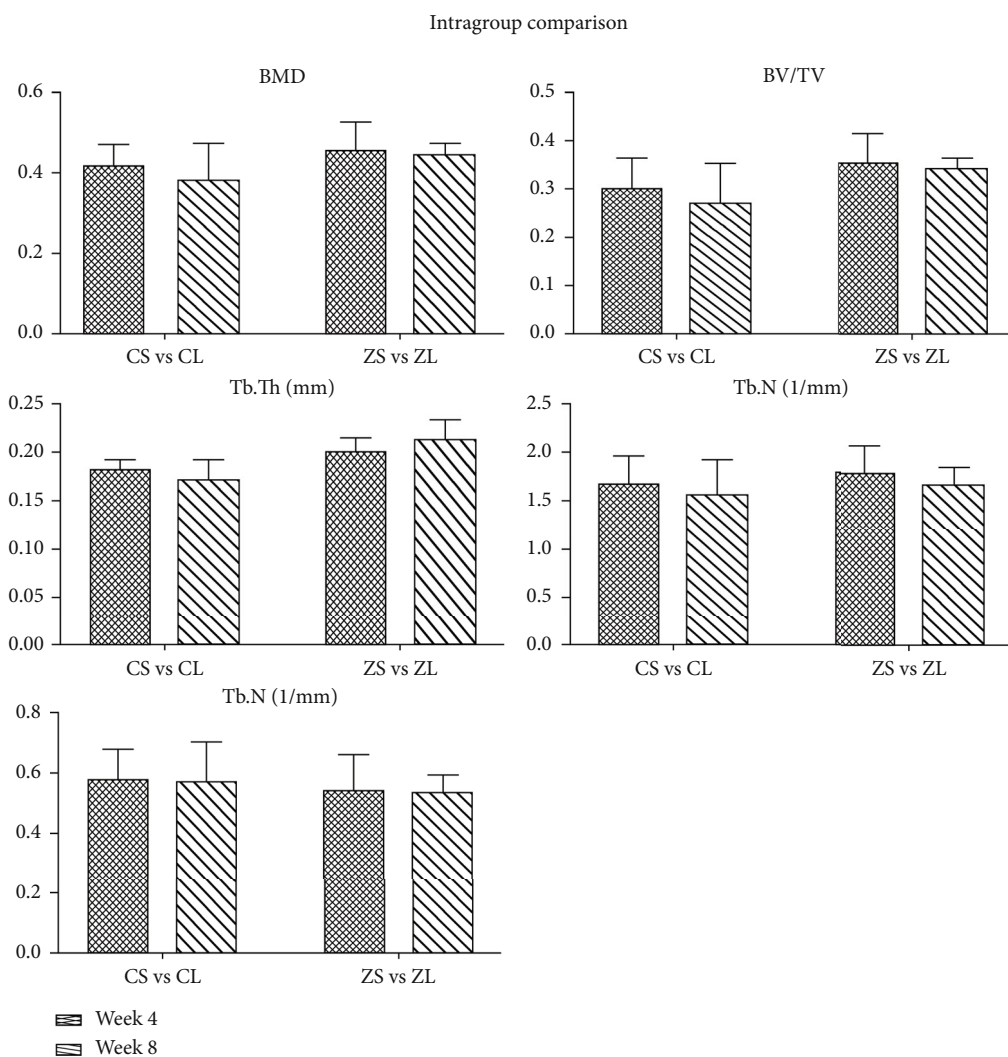


FIGURE 5: Intragroup comparison of BMD, BV/TV, Tb.Th, Tb.N, and Tb.Sp in the mandible between short-term subgroups (week 4) and long-term subgroups (week 8) in both control and ZA-treated groups. No significant difference is detected in any assessed parameters.

2.8. *Statistical Analysis.* IBM SPSS statistics software (version 24.0, IBM Corp, Armonk:NY, USA) was for statistical analysis. Comparison of BMD, microstructure, bone growth rates, and incidence of osteonecrosis between groups was performed by independent *t*-test and Fisher’s exact test at a significance level of 0.05.

### 3. Results

3.1. *Clinical Observations.* One rabbit in the ZA long-term group died one day after surgery, and the rest of the animals went through the whole experiment uneventfully. All extraction sites healed well without any signs of infection or inflammation (redness, swelling, etc.). No fistula or exposed bone was found.

3.2. *Micro-CT Assessment.* The reconstructed 3D images of ROI were shown in Figure 3. The results were displayed in the following Table 1 as mean ± SD. In the intergroup comparison, BMD, BV/TV, Tb.Th, and Tb.N in the ZA-treated

group were higher, and Tb.Sp was lower than the control group at both week 4 and week 8 (Figure 4). However, the differences were not significant except for Tb.Th, which was significantly higher in the ZA-treated animals than that in the control animals at both week 4 and week 8. In the intragroup comparison, BMD, BV/TV, and Tb.N showed decrease at week 8 compared to those at week 4 in both control and ZA-treated group, only the reduction was less in the ZA-treated group. Tb.Th was higher at week 8 than that at week 4 in the ZA-treated group, and Tb.Sp barely changed from week 4 to week 8 in the ZA-treated group (Figure 5). The changing trends of Tb.Th in the ZA-treated group were opposite from those in the control group. However, the differences between each time point were not statistically significant in both control and ZA-treated groups.

The data of periodontal ligament space in the control long-term group were not normally distributed; therefore, Mann-Whitney test was used when comparison involved this group. Independent sample *t*-test was used in the other comparisons. Periodontal ligament space in the ZA treated

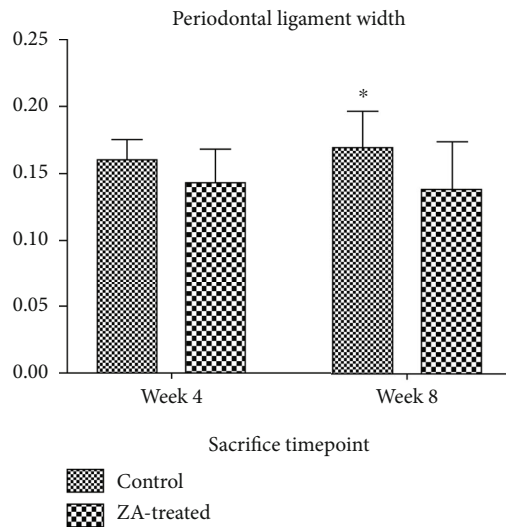


FIGURE 6: The ZA-treated groups showed thinner periodontal ligament space, more difference is shown in the comparison of control long-term group and ZA long-term group, but the difference is not statistically significant. Week 4, control short-term group, and ZA short-term group, which are sacrificed at week 4; week 8, control long-term group, and ZA long-term group, which are sacrificed at week 8. \*Control long-term group, median is shown in the chart as the data in this group are not normally distributed.

groups, both long-term subgroup and short-term subgroup, was thinner than that of the respective control groups. More decrease was shown in the long-term subgroups compared to the short-term subgroups (Figure 6). However, the differences were not significant. When comparing the results of the control short-term group and the control long-term group, slight increase in periodontal ligament width was seen in the control long-term group. Slight decrease was shown when comparing the ZA short-term group and ZA long-term group. Still, neither of these differences was statistically significant.

Periosteal reactions were seen in all groups except for in the control animals at week 8, as shown in Figure 7. Similarly, sequestra were seen in all groups except for in the control group at week 8 as well (Figure 8). Data were summarized in Table 2 describing the number of animals with periosteal reaction and sequestra formation in each group.

**3.3. Fluorochrome Labeling Analysis.** The fluorochrome labeling images were shown in Figure 9. The results of the averaging bone growth rates were illustrated in Table 3. Both ZA-treated groups demonstrated significant reduced bone growth rates compared to control groups. In the intergroup comparison at week 4, the ZA-treated group showed significantly lower bone growth rates in both time periods than that of control counterparts. Similar results were detected at week 8 (Figure 10).

Bone growth rates dropped markedly in week 4-6 compared to those in week 2-4 in the long-term subgroups. Similarly, bone growth rates reduced significantly in week 2-3 in

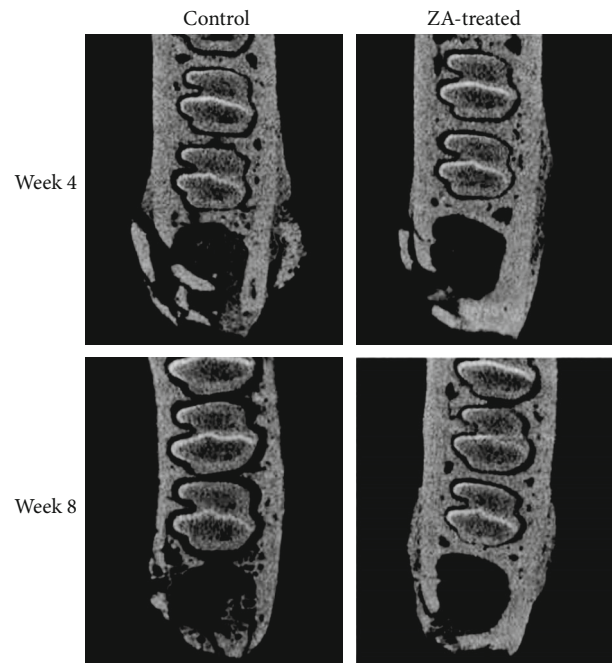


FIGURE 7: Micro-CT assessment of periosteal reaction after tooth extraction in the control and ZA groups at week 4 and 8.

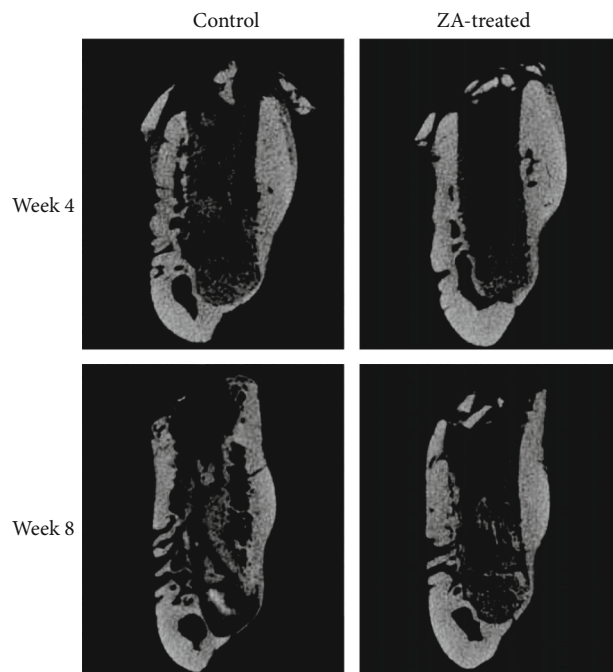


FIGURE 8: Micro-CT assessment of sequestra (coronal view) after tooth extraction in the control and ZA groups at week 4 and 8.

comparison with those in week 1-2 in the short-term subgroups. After averaging the bone growth rates of different time periods in each subgroup, intragroup comparison was conducted in both control groups and experiment groups separately. Significant differences were detected in both intragroup comparisons. Remarkable lower bone growth

TABLE 2: Radiographic and histologic observations.

Group	Week	No.	Micro-CT			Histology	
			Sequestra	Periosteal reaction	Sequestra	Histological osteonecrosis	
Control	4	5	1	4	3	2	
	8	5	0	0	0	0	
ZA	4	5	4	5	5	4	
	8	4	1	3	4	4	

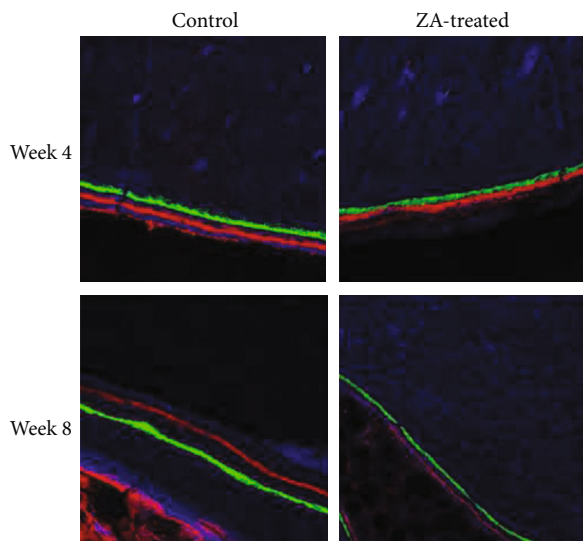


FIGURE 9: Fluorochrome labeling technique is used for evaluating the bone growth rates of mandibles.

TABLE 3: Bone growth rates measured by fluorochrome labeling.

Time	Bone growth rates ( $\mu\text{m}/\text{day}$ )			<i>t</i> -test Sig. (2-tailed)*
	Groups	N	Mean $\pm$ SD	
Week 1-2	CS	5	$3.32 \pm 0.64$	0.016
	ZS	5	$2.24 \pm 0.22$	
Week 2-3	CS	5	$4.21 \pm 0.68$	0.000
	ZS	5	$2.02 \pm 0.45$	
Week 2-4	CL	5	$2.00 \pm 0.24$	0.024
	ZL	4	$1.64 \pm 0.09$	
Week 4-6	CL	5	$1.56 \pm 0.19$	0.002
	ZL	4	$1.05 \pm 0.11$	

CS: control short-term group; ZS: ZA short-term group; CL: control long-term group; ZL: ZA long-term group. \**P* value.

rates were demonstrated in both long-term subgroups (Figure 10). When merging the data of the short-term subgroup and the long-term subgroup, as illustrated in Figure 11, the rate of bone growth in mandibles showed gradual reduction in the ZA-treated group. While in the control group, a sharp increase was seen at week 2-3, following by a remarkable and then slow decrease.

**3.4. Histomorphological Analysis.** One out of five rabbits (20%) in the control group was found with histological osteonecrosis defined as 8-10 adjacent empty osteocytic lacunae with the loss of osteocytes at week 4, while none was discovered at week 8. In the ZA-treated group, three out of five (60%) animals revealed histological osteonecrosis at week 4, while three out of four (75%) animals were found with histological osteonecrosis at week 8. The one histological osteonecrosis in the control group was found on the left side of the mandible which was the unsutured side. The sites of the osteonecrosis and the statistical analysis were summarized in Table 4. The one histological osteonecrosis in the control group was found on the left side of the mandible which was the unsutured side. Among the three histological osteonecrosis lesions in experimental group at week 4, two of them were on the sutured side. Similar results were seen in those at week 8, and two of the three identified histological osteonecrosis were on the sutured side. Fisher’s exact test was performed to evaluate the differences in the incidence of histological osteonecrosis between control and experimental groups at each time point. Intragroup comparison between two time points and between left and right side was also conducted using the Fisher’s exact test. Significant higher incidence (75%) of histological incidence was found in the ZA-treated group (0%) compared to the control group at week 8 ( $P = 0.048$ ). However, no significant difference was detected in all the other comparisons.

#### 4. Discussion

The position paper of the American Association of Oral and Maxillofacial Surgeons (AAOMS) has proposed the diagnostic criteria of MRONJ as current or precursory use of antiresorptive and antiangiogenic agents, nonhealing bone exposure or probable fistula in the maxillofacial area for at least 8 weeks without a history of radiation exposure [4]. Some studies suggested radiographic signs of osteonecrosis alone would be enough to diagnose MRONJ [26, 27], though not widely accepted. Bianchi et al. [28] found that computed tomography (CT) was very sensitive for abnormalities in the jaw bones and provide good accuracy in the outline of the pathologies in about 94% of the patients detected. In the same study, dental panoramic radiograph was demonstrated to be of limited use in assessing ONJ lesions. Some studies reported that magnetic resonance imaging (MRI) and CT scan were useful investigations in defining osteonecrotic lesions [29]. In accordance with these findings, Raje et al. [30] described bone sclerosis and fragmentation, periosteal new bone formation, and a big

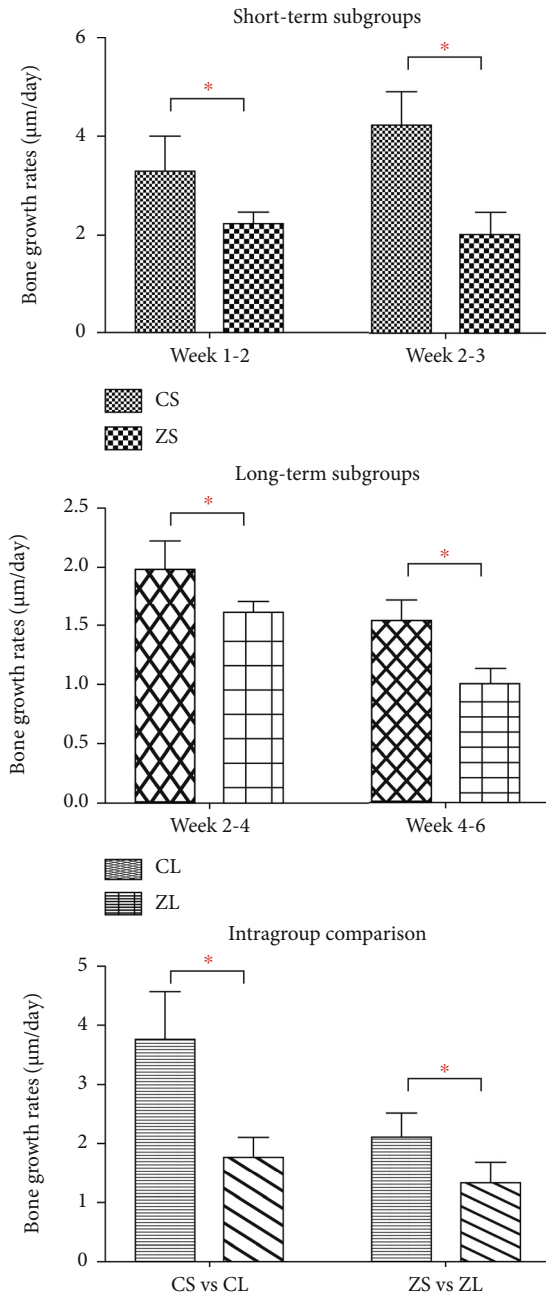


FIGURE 10: Inter- and intragroup comparison of bone growth rates ( $\mu\text{m}/\text{day}$ ) of the mandible. CS: control short-term subgroup; ZS: ZA short-term subgroup; CL: control long-term subgroup; ZL: ZA long-term subgroup. \*Statistically significant.

sequestrum in one case in the CT scans, therefore, concluded that radiographic findings were reasonably accurate in advanced, clinically established ONJ. However, the competence of CT for early detection of ONJ lesions remains unclear.

Radiographic findings of ONJ generally include osteosclerosis, osteolysis, a thickened lamina dura, periosteal bone deposition/proliferation, and sequestra formation [30, 31]. In our study, periosteal reaction and sequestra were observed in

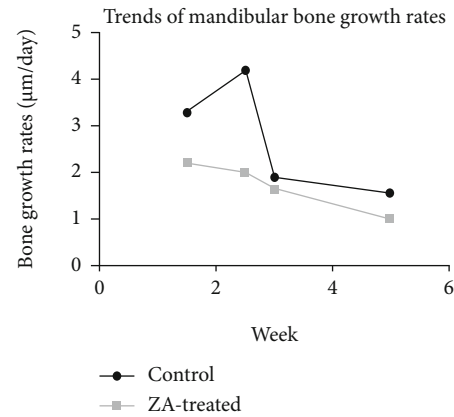


FIGURE 11: The rate of bone growth in mandibles shows gradual reduction in the ZA-treated group. While in the control group, a sharp increase is seen at week 2-3, following by a remarkable and then slow decrease.

the micro-CT scanning. Four out of five animals in the control group exhibited periosteal reaction at week 4 while none did at week 8. In the ZA group, all five animals at week 4 and three out of four of those at week 8 showed periosteal reaction. As for sequestra formation, one out of five control rabbits were detected at week 4 compared to none found at week 8; in contrast, four out of five rabbits were found with sequestra formation in the ZA group at week 4 while one out of four were identified at week 8. More cases of sequestra formation were found in ZA-treated animals compared with their control counterparts. While most animals exhibited periosteal reaction except in the control long-term subgroup. This was further confirmed by the histological examination that no periosteal bone deposition was observed in the control long-term group. In addition, there was no histological osteonecrosis detected in this subgroup.

Periosteal reaction may be caused by different insults, for instance, trauma, infection, and tumor [32]. The periosteal reaction observed in this study did not seem to relate to ZA treatments, in other words, the periosteal reaction was not the presentation of osteonecrosis lesions. In fact, it may be more reasonable to relate the periosteal reaction to the trauma caused during the extraction procedure.

In the micro-CT assessment, BMD, BV/TV, Tb.Th, Tb.N, and Tb.Sp demonstrated expected results in the ZA group when compared to the control group, though the differences in all parameters were not significant. The similar nonsignificant difference was also reported in other studies in healthy animals [33, 34]. However, this nonsignificant result may also be due to the small sample size in the study.

In this study, bone growth rates showed remarkable reduction in all time points in the ZA group when compared to the control group. ZA is a potent bisphosphonate that work mainly by inhibiting the osteoclasts' activity and then decreasing the bone turnover rates. The bone formation decrease was thought to follow the reduced bone resorption and the subsequent reduced bone remodeling rates [35]. The significant decrease in bone growth rates may explain why BMD and other microarchitecture parameters showed only



TABLE 4: The incidence of osteonecrosis of the control and experimental group on the mandible at week 4 and week 8.

Groups Time point	Control		ZA-treated		P value*	P value**
	Week 4	Week 8	Week 4	Week 8		
ONJ	2 (L * 1, R * 1)	0	4 (L * 2, R * 3)	4 (L * 2, R * 2)		
NON-ONJ	3	5	1	0		
N	5	5	5	4		
Incidence	40%	0%	80%	100%	0.524	0.008
P value***	—	—	1	—		
P value****	0.444		1			

\*Intergroup comparison of the incidence between control and ZA-treated groups at week 4; \*\*intergroup comparison of the incidence between control and ZA-treated groups at week 8, significant difference in the incidence of histological osteonecrosis was detected between control and ZA-treated group; \*\*\*intragroup comparison of the incidence at each time point in each group between left and right sides; \*\*\*\*intragroup comparison in the control and ZA-treated group.

slight increase or even decrease when a large dose of ZA was used and therefore the consequent expected strong inhibitory effect on bone resorption.

The main microscopic characteristics of MRONJ are necrotic bony trabeculae with empty osteocytic lacunae [36]. Commonly, the necrotic bone is enclosed by colonies of bacteria and demonstrates irregular resorption and notable reversal lines [37].

Areas of empty osteocytic lacunae (8-10 adjoining ones) with the loss of osteocytes were defined as the histological osteonecrosis in this study. When assessing the incidence of histological osteonecrosis, ZA-treated animals showed significantly higher incidence of histological osteonecrosis than the control counterparts at week 8. However, the incidence of histological osteonecrosis between the left and right side of the mandibles in both control and experimental groups exhibited no difference. Moreover, no exposed bone or probable fistula was identified in all animals. Therefore, it seemed that closing the extraction socket after tooth extraction did not have significant effect on the bone healing or the development of osteonecrosis.

Infection and inflammation have been proposed as a possible pathophysiology of MRONJ because this condition occurred exclusively to the jaw bones which are protected by a thin epithelium from the open oral cavity, which contains over 700 different species of microbes [38]. The jaw bones could be easily exposed to the bacteria after tooth extraction, trauma, or through the inflammatory dental diseases. The existence of some microorganisms that are distinct to the oral cavity has been found to be associated with the initiation or the progress of MRONJ. Cultures and biopsy from MRONJ patients have identified the presence of microbes including *Actinomyces*, *Fusobacterium*, *Staphylococcus*, *Eikenella*, *Bacillus*, and *Streptococcus* [39–43].

Clinical observation in this study exhibited no delayed wound healing on either the unsutured side or the sutured side in all animals. Moreover, histological assessment revealed no significant difference in the occurrence of histological osteonecrosis between the suture side and the open wound side. Indeed, an open wound would heal uneventfully even with the presence of normal oral microbes usually. However, the bone healing was hypothesized to be impeded

with bisphosphonates treatment due to the decreased bone resorption, which makes it difficult for the inflammatory cells to arrive at pathogens and thus the inflammation and/or infection might progress [44]. The cumulated bacterial toxins and the hyperoxide generated in the inflammation response will contribute to the development of bone necrosis [44]. This was supported by some animal experiments showing that inflammation or infection could promote osteonecrosis of the jaw in those treated with antiresorptive medications [45–50]. Furthermore, mucoperiosteal coverage after tooth extraction may reduce the risk for ONJ in a bisphosphonate-treated rat model [51].

Different from the theoretical hypothesis, our results showed that whether to close the extraction socket or not did not appear to affect the bone healing or the development of ONJ. Unlike mucoperiosteal coverage, simple closure of mucosa after tooth extraction seemed not to be an effective way to reduce the development of ONJ in the rabbit model. One potential issue which may affect the result is the use of prophylaxis antibiotics which lowers the chance of infection and thus reduces the effect of soft tissue closure on preventing potential infection.

In conclusion, bisphosphonates significantly reduce bone growth rates but do not reveal a significant effect on bone mineral density (BMD) and bone microarchitecture; Soft tissue closure of the extraction socket does not reduce the incidence of ONJ in bisphosphonates-treated rabbits. Future study with larger sample size and no prophylaxis antibiotics to investigate the effect of different surgical modification on the prevention of MRONJ shall be taken into consideration.

## Data Availability

The data used to support the findings of this study are included within the article.

## Ethical Approval

This article does not contain any studies with human participants performed by any of the authors. All applicable international, national, and/or institutional guidelines for

the care and use of animals are followed. This study was reviewed and approved by the Committee on Use Live Animal for Teaching and Research, the University of Hong Kong (CULATR No. 3774-15).

## Consent

For this type of study, formal consent is not required.

## Conflicts of Interest

The authors declare that there is no conflict of interest regarding the publication of this paper.

## Authors' Contributions

Dr. Ru Qing YU and Dr. Jing Wen LI contributed equally to this work.

## Acknowledgments

The work is supported by the Seed Fund for Basic Research (201611159015), the University of Hong Kong. The methodology in this study was reviewed by an independent statistician, Samantha Kar Yan Li (Faculty of Dentistry, The University of Hong Kong).

## References

- [1] H. Fleisch, *Bisphosphonates in Bone Disease: From the Laboratory to the Patient*, Academic Press, 2000.
- [2] N. B. Watts, J. P. Bilezikian, P. M. Camacho et al., "American Association of Clinical Endocrinologists Medical Guidelines for clinical practice for the diagnosis and treatment of postmenopausal osteoporosis: executive summary of recommendations," *Endocrine Practice*, vol. 16, no. 6, pp. 1016–1019, 2010.
- [3] R. Mhaskar, A. Kumar, B. Miladinovic, B. Djulbegovic, and Cochrane Haematological Malignancies Group, "Bisphosphonates in multiple myeloma: an updated network meta-analysis," *Cochrane Database of Systematic Reviews*, vol. 2017, no. 12, p. CD003188, 2017.
- [4] S. L. Ruggiero, T. B. Dodson, J. Fantasia et al., "American Association of Oral and Maxillofacial Surgeons Position Paper on Medication-Related Osteonecrosis of the Jaw—2014 Update," *Journal of Oral and Maxillofacial Surgery*, vol. 72, no. 10, pp. 1938–1956, 2014.
- [5] A. Bamias, E. Kastritis, C. Bamia et al., "Osteonecrosis of the jaw in cancer after treatment with bisphosphonates: incidence and risk factors," *Journal of Clinical Oncology*, vol. 23, no. 34, pp. 8580–8587, 2005.
- [6] A. Badros, D. Weikel, A. Salama et al., "Osteonecrosis of the jaw in multiple myeloma patients: clinical features and risk factors," *Journal of Clinical Oncology*, vol. 24, no. 6, pp. 945–952, 2006.
- [7] S.-H. Lee, S.-S. Chang, M. Lee, R.-C. Chan, and C.-C. Lee, "Risk of osteonecrosis in patients taking bisphosphonates for prevention of osteoporosis: a systematic review and meta-analysis," *Osteoporosis International*, vol. 25, no. 3, pp. 1131–1139, 2014.
- [8] G. Saia, S. Blandamura, G. Bettini et al., "Occurrence of bisphosphonate-related osteonecrosis of the jaw after surgical tooth extraction," *Journal of Oral and Maxillofacial Surgery*, vol. 68, no. 4, pp. 797–804, 2010.
- [9] T. Boonyapakorn, I. Schirmer, P. A. Reichart, I. Sturm, and G. Massenkeil, "Bisphosphonate-induced osteonecrosis of the jaws: prospective study of 80 patients with multiple myeloma and other malignancies," *Oral Oncology*, vol. 44, no. 9, pp. 857–869, 2008.
- [10] E. Merigo, M. Manfredi, M. Meleti et al., "Bone necrosis of the jaws associated with bisphosphonate treatment: a report of twenty-nine cases," *Acta Bio Medica Atenei Parmensis*, vol. 77, no. 2, pp. 109–117, 2006.
- [11] S. Woo, J. W. Hellstein, and J. R. Kallar, "Systematic review: bisphosphonates and osteonecrosis of the jaws," *Annals of Internal Medicine*, vol. 144, no. 10, pp. 753–761, 2006.
- [12] C. Walter, K. A. Grötz, M. Kunkel, and B. Al-Nawas, "Prevalence of bisphosphonate associated osteonecrosis of the jaw within the field of osteonecrosis," *Supportive Care in Cancer*, vol. 15, no. 2, pp. 197–202, 2007.
- [13] S. Khosla, D. Burr, J. Cauley et al., "Bisphosphonate-associated osteonecrosis of the jaw: report of a task force of the American Society for Bone and Mineral Research," *Journal of Bone and Mineral Research*, vol. 22, no. 10, pp. 1479–1491, 2007.
- [14] T. L. Aghaloo, A. L. Felsenfeld, and S. Tetradis, "Osteonecrosis of the jaw in a patient on Denosumab," *Journal of Oral and Maxillofacial Surgery*, vol. 68, no. 5, pp. 959–963, 2010.
- [15] R. Patini, "Oral microbiota: discovering and facing the new associations with systemic diseases," *Pathogens*, vol. 9, no. 4, p. 313, 2020.
- [16] R. Patini, "Culturomics: a new approach for the diagnosis of the oral microbiota," *Dental Hypotheses*, vol. 11, no. 3, p. 72, 2020.
- [17] R. Q. Yu, J. Y. Wang, N. J. Rao, L. Huo, and L. W. Zheng, "Effects of bisphosphonates on osseointegration of dental implants in rabbit model," *BioMed Research International*, vol. 2021, Article ID 6689564, 2021.
- [18] S. M. van Gaalen, M. C. Kruyt, R. E. Geuze, J. D. de Bruijn, J. Alblas, and W. J. Dhert, "Use of fluorochrome labels in vivo bone tissue engineering research," *Tissue engineering Part B: Reviews*, vol. 16, no. 2, pp. 209–217, 2010.
- [19] J. Y. Li, E. H. N. Pow, L. W. Zheng, L. Ma, D. L. W. Kwong, and L. K. Cheung, "Dose-dependent effect of radiation on titanium implants: a quantitative study in rabbits," *Clinical Oral Implants Research*, vol. 25, no. 2, pp. 260–265, 2014.
- [20] A. M. Parfitt, M. K. Drezner, F. H. Glorieux et al., "Bone histomorphometry: standardization of nomenclature, symbols, and units: report of the ASBMR Histomorphometry Nomenclature Committee," *Journal of Bone and Mineral Research*, vol. 2, no. 6, pp. 595–610, 1987.
- [21] T. Hildebrand and P. Rüeggsegger, "A new method for the model-independent assessment of thickness in three-dimensional images," *Journal of Microscopy*, vol. 185, no. 1, pp. 67–75, 1997.
- [22] A. Parfitt, C. Mathews, A. Villanueva, M. Kleerekoper, B. Frame, and D. Rao, "Relationships between surface, volume, and thickness of iliac trabecular bone in aging and in osteoporosis. Implications for the microanatomic and cellular mechanisms of bone loss," *The Journal of Clinical Investigation*, vol. 72, no. 4, pp. 1396–1409, 1983.

- [23] L. G. Luna, *Histopathologic Methods and Color Atlas of Special Stains and Tissue Artifacts*, American Histolabs, Gaithersburg, MD, 1992.
- [24] D. L. Basi, P. J. Hughes, V. Thumbigere-Math et al., "Matrix Metalloproteinase-9 Expression in Alveolar Extraction Sockets of Zoledronic Acid-Treated Rats," *Journal of Oral and Maxillofacial Surgery*, vol. 69, no. 11, pp. 2698–2707, 2011.
- [25] J. Yamashita, K. Koi, D.-Y. Yang, and L. K. McCauley, "Effect of zoledronate on oral wound healing in rats," *Clinical Cancer Research*, vol. 17, no. 6, pp. 1405–1414, 2011.
- [26] A. Bedogni, V. Fusco, A. Agrillo, and G. Campisi, "Learning from experience. Proposal of a refined definition and staging system for bisphosphonate-related osteonecrosis of the jaw (BRONJ)," *Oral Diseases*, vol. 18, no. 6, pp. 621–623, 2012.
- [27] M. Schiodt, J. Reibel, P. Oturai, and T. Kofod, "Comparison of nonexposed and exposed bisphosphonate-induced osteonecrosis of the jaws: a retrospective analysis from the Copenhagen cohort and a proposal for an updated classification system," *Oral Surgery, Oral Medicine, Oral Pathology, and Oral Radiology*, vol. 117, no. 2, pp. 204–213, 2014.
- [28] S. D. Bianchi, M. Scoletta, F. B. Cassione, G. Migliaretti, and M. Mozzati, "Computerized tomographic findings in bisphosphonate-associated osteonecrosis of the jaw in patients with cancer," *Oral Surgery, Oral Medicine, Oral Pathology, Oral Radiology and Endodontics*, vol. 104, no. 2, pp. 249–258, 2007.
- [29] J. Beltran and O. Opsha, "MR imaging of the hip: osseous lesions," *Magnetic Resonance Imaging Clinics*, vol. 13, no. 4, pp. 665–676, 2005.
- [30] N. Raje, S.-B. Woo, K. Hande et al., "Clinical, radiographic, and biochemical characterization of multiple myeloma patients with osteonecrosis of the jaw," *Clinical Cancer Research*, vol. 14, no. 8, pp. 2387–2395, 2008.
- [31] K. Arce, L. A. Assael, J. L. Weissman, and M. R. Markiewicz, "Imaging findings in bisphosphonate-related osteonecrosis of jaws," *Journal of Oral and Maxillofacial Surgery*, vol. 67, no. 5, pp. 75–84, 2009.
- [32] R. S. Rana, J. S. Wu, and R. L. Eisenberg, "Periosteal reaction," *American Journal of Roentgenology*, vol. 193, no. 4, pp. W259–W272, 2009.
- [33] E. Perilli, V. Le, B. Ma, P. Salmon, K. Reynolds, and N. L. Fazzalari, "Detecting early bone changes using in vivo micro-CT in ovariectomized, zoledronic acid-treated, and sham-operated rats," *Osteoporosis International*, vol. 21, no. 8, pp. 1371–1382, 2010.
- [34] E. Won, L. Wise-Milestone, M. K. Akens et al., "Beyond bisphosphonates: photodynamic therapy structurally augments metastatically involved vertebrae and destroys tumor tissue," *Breast Cancer Research and Treatment*, vol. 124, no. 1, pp. 111–119, 2010.
- [35] G. A. Rodan and H. A. Fleisch, "Bisphosphonates: mechanisms of action," *The Journal of Clinical Investigation*, vol. 97, no. 12, pp. 2692–2696, 1996.
- [36] R. Chaisuparat and B. C. Jham, "Histopathology of medication-related osteonecrosis of the jaw," in *Medication-Related Osteonecrosis of the Jaws: Bisphosphonates, Denosumab, and New Agents*, S. Otto, Ed., pp. 131–137, Springer Berlin Heidelberg, Berlin, Heidelberg, 2015.
- [37] R. S. Weinstein, P. K. Roberson, and S. C. Manolagas, "Giant osteoclast formation and long-term oral bisphosphonate therapy," *New England Journal of Medicine*, vol. 360, no. 1, pp. 53–62, 2009.
- [38] D. Santini, B. Vincenzi, G. Avvisati et al., "Pamidronate induces modifications of circulating angiogenetic factors in cancer patients," *Clinical Cancer Research*, vol. 8, no. 5, pp. 1080–1084, 2002.
- [39] R. E. Marx, Y. Sawatari, M. Fortin, and V. Broumand, "Bisphosphonate-induced exposed bone (osteonecrosis/osteopetrosis) of the jaws: risk factors, recognition, prevention, and treatment," *Journal of oral and maxillofacial surgery: official journal of the American Association of Oral and Maxillofacial Surgeons*, vol. 63, no. 11, pp. 1567–1575, 2005.
- [40] T. Hansen, M. Kunkel, A. Weber, and K. C. James, "Osteonecrosis of the jaws in patients treated with bisphosphonates—histomorphologic analysis in comparison with infected osteoradionecrosis," *Journal of Oral Pathology & Medicine*, vol. 35, no. 3, pp. 155–160, 2006.
- [41] T. Hansen, M. Kunkel, E. Springer et al., "Actinomycosis of the jaws—histopathological study of 45 patients shows significant involvement in bisphosphonate-associated osteonecrosis and infected osteoradionecrosis," *Virchows Archiv*, vol. 451, no. 6, pp. 1009–1017, 2007.
- [42] P. P. Sedghizadeh, S. K. Kumar, A. Gorur, C. Schaudinn, C. F. Shuler, and J. W. Costerton, "Identification of microbial biofilms in osteonecrosis of the jaws secondary to bisphosphonate therapy," *Journal of Oral and Maxillofacial Surgery*, vol. 66, no. 4, pp. 767–775, 2008.
- [43] F. S. O'Ryan, S. Khoury, W. Liao et al., "Intravenous bisphosphonate-related osteonecrosis of the jaw: bone scintigraphy as an early indicator," *Journal of Oral and Maxillofacial Surgery*, vol. 67, no. 7, pp. 1363–1372, 2009.
- [44] T. Ikebe, "Pathophysiology of BRONJ: drug-related osteoclastic disease of the jaw," *Oral Science International*, vol. 10, no. 1, pp. 1–8, 2013.
- [45] T. L. Aghaloo, B. Kang, E. C. Sung et al., "Periodontal disease and bisphosphonates induce osteonecrosis of the jaws in the rat," *Journal of Bone and Mineral Research*, vol. 26, no. 8, pp. 1871–1882, 2011.
- [46] J. I. Aguirre, M. P. Akhter, D. B. Kimmel et al., "Oncologic doses of zoledronic acid induce osteonecrosis of the jaw-like lesions in rice rats (*Oryzomys palustris*) with periodontitis," *Journal of Bone and Mineral Research*, vol. 27, no. 10, pp. 2130–2143, 2012.
- [47] B. Kang, S. Cheong, T. Chaichanasakul et al., "Periapical disease and bisphosphonates induce osteonecrosis of the jaws in mice," *Journal of Bone and Mineral Research*, vol. 28, no. 7, pp. 1631–1640, 2013.
- [48] H. Mawardi, N. Treister, P. Richardson et al., "Sinus Tracts—An Early Sign of Bisphosphonate-Associated Osteonecrosis of the Jaws?," *Journal of Oral and Maxillofacial Surgery*, vol. 67, no. 3, pp. 593–601, 2009.
- [49] P. López-Jornet, F. Camacho-Alonso, A. Martínez-Canovas, F. Molina-Miñano, F. Gómez-García, and V. Vicente-Ortega, "Perioperative antibiotic regimen in rats treated with pamidronate plus dexamethasone and subjected to dental extraction: a study of the changes in the jaws," *Journal of Oral and Maxillofacial Surgery*, vol. 69, no. 10, pp. 2488–2493, 2011.
- [50] J. Gotcher and W. Jee, "The progress of the periodontal syndrome in the rice rat," *Journal of Periodontal Research*, vol. 16, no. 4, pp. 441–455, 1981.
- [51] J. Abtahi, F. Agholme, and P. Aspenberg, "Prevention of osteonecrosis of the jaw by mucoperiosteal coverage in a rat model," *International Journal of Oral and Maxillofacial Surgery*, vol. 42, no. 5, pp. 632–636, 2013.