



Multilocular True Ulnar Artery Aneurysm in a Pediatric Patient

Mark W. Stalder, MD
Christopher Sanders, MD
Mary Lago, BS
Hugo St. Hilaire, DDS, MD

Summary: Ulnar artery aneurysms are an exceedingly rare entity in the pediatric population and have no consistent etiologic mechanism. We present the case of a 15-year-old male with a multilocular ulnar artery aneurysm in the setting of no antecedent history of trauma, no identifiable connective tissue disorders, and no other apparent etiological factors. Furthermore, the patient's arterial palmar arch system was absent. The aneurysm was resected, and arterial reconstruction was successfully performed via open surgical approach with cephalic vein interposition graft. We believe this treatment modality should be considered as the primary approach in all of these pediatric cases in consideration of the possible pitfalls of less comprehensive measures. (*Plast Reconstr Surg Glob Open* 2016;4:e595; doi: 10.1097/GOX.0000000000000532; Published online 18 January 2016.)

Although true aneurysms of the ulnar artery are rare entities under any clinical circumstances, in the pediatric patient population, there are fewer than a dozen cases reported in the literature, with no consistent associated etiology.^{1,2} The reported causes of these lesions vary widely from a single traumatic event, to connective tissue disorders, to idiopathic congenital aneurysms.³⁻⁶ We present the case of a true ulnar artery aneurysm in a 15-year-old male with no antecedent traumatic events or identifiable pathologic etiology.

CASE REPORT

A right hand dominant 15-year-old male presented for evaluation of a mass on the volar surface of his right wrist. The patient reported a gradual increase in size of the mass over the previous year, and that it had recently become visibly pulsatile. There was no reported history of any penetrating

or blunt trauma to that area of his upper extremity. Physical examination revealed a palpable, pulsatile, 2 cm mass just proximal to the wrist crease on the right hand. Computed tomography angiography demonstrated a 2.3 × 1.5 cm ulnar artery aneurysm at the volar surface of the ulnar-carpal junction, a second 0.5 cm aneurysm just proximal to the hook of the hamate, and a third 1.5 × 1.2 cm aneurysm in the palm (Fig. 1). No superficial or deep palmar arch system was identified, although a persistent median artery was present. An extensive medical work-up revealed no autoimmune or connective tissue disorders that could be associated with the genesis of the lesion.

The decision was made to proceed with resection of the aneurysm. An incision was made along the volar aspect of the wrist and palm over the pulsatile lesion, and the aneurysm exposed and excised, with care taken to identify and preserve the adjacent ulnar nerve (Fig. 1). The cephalic vein of the ipsilateral forearm was harvested and used as a reversed interposition graft for reconstruction of the artery (Fig. 1). Pathologic examination confirmed the presence of a true aneurysm of the artery, with involvement of all layers of the vessel. Six months after surgery the patient has adequate perfusion and asymptomatic function of his right hand.

From the Division of Plastic and Reconstructive Surgery, Louisiana State University, Health Sciences Center, New Orleans, La.

Received for publication April 13, 2015; accepted September 9, 2015.

Copyright © 2016 The Authors. Published by Wolters Kluwer Health, Inc. on behalf of The American Society of Plastic Surgeons. All rights reserved. This is an open-access article distributed under the terms of the Creative Commons Attribution-Non Commercial-No Derivatives License 4.0 (CCBY-NC-ND), where it is permissible to download and share the work provided it is properly cited. The work cannot be changed in any way or used commercially.

DOI: 10.1097/GOX.0000000000000532

Disclosure: *The authors have no financial interest to declare in relation to the content of this article. The Article Processing Charge was paid for by the authors.*

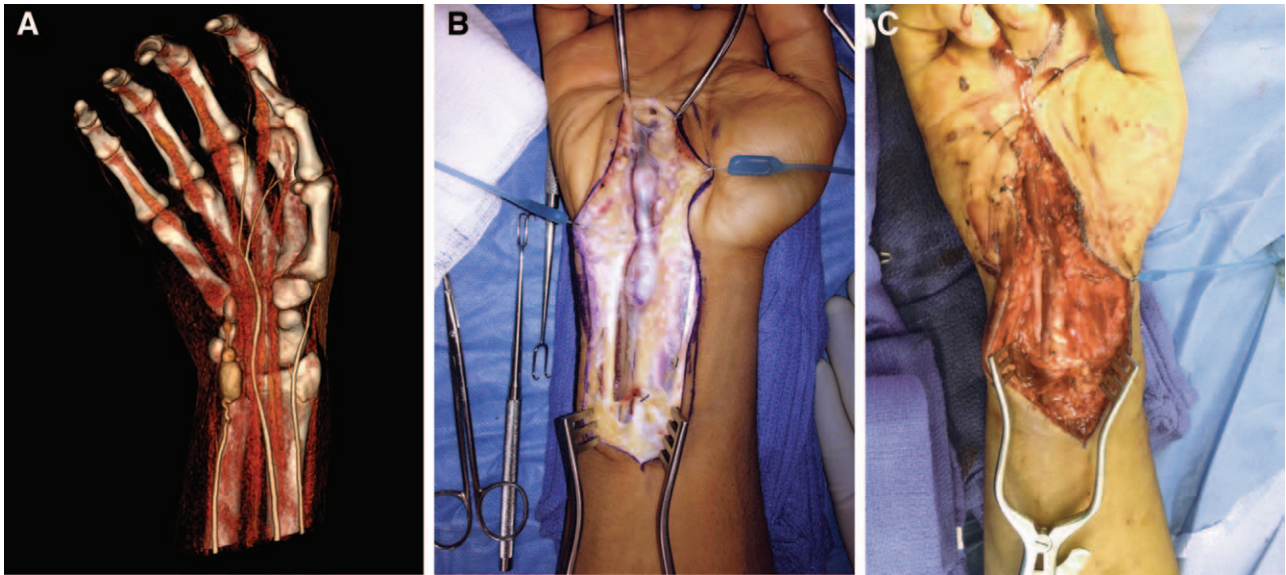


Fig. 1. Computed tomography angiogram (A) demonstrating the presence of a multilocular ulnar artery aneurysm, a persistent median artery, and absence of the palmar arterial arch system. Under tourniquet, the aneurysm was approached with a direct incision, exposing the entirety of the lesion from the mid-forearm proximally to the mid-palm distally (B). After resection of the lesion, the ulnar artery was reconstructed with a reversed cephalic vein graft harvested from the ipsilateral forearm (C).

DISCUSSION

Though rare in adults, the pathogenesis of ulnar artery aneurysms in that patient population can generally be attributed to repetitive stress on the artery secondary to the peculiarities of its anatomy. The ulnar artery passes through Guyon's canal where it lies adjacent to the hook of the hamate and can be subjected to the transferred forces of external trauma.² The typical presentation is that of a laborer who has suffered repetitive trauma to the ulnar aspect of the palm over a long period of time, such as that experienced in carpentry or mechanical repair. The repetitive damage weakens the medial wall, resulting in expansion and aneurysm formation.⁷

In the pediatric population, however, ulnar artery aneurysms are exceedingly rare phenomenon. Several possible etiologies have been reported, including connective tissue and autoimmune disorders such as Ehlers–Danlos syndrome, Marfan syndrome, and Kawasaki disease; singular traumatic events have been reported as the inciting insult, and the occurrence of congenital ulnar artery aneurysms are also found in the literature.^{4,6,8}

On examination there is generally a palpable volar mass in the area of Guyon's canal, as well as possible signs and symptoms of digital ischemia including pain, cyanosis, pallor, and ulceration. And though history and physical examination are essential to diagnosis, advanced imaging is frequently employed. Classically, invasive contrast-arteriography has been used to delineate aneurysm morphology, but poses a risk for

distal embolization.⁸ Duplex ultrasonography is a useful noninvasive technique that can assess perfusion via arterial-brachial index, evaluate for thrombus, and can be readily performed in infants.⁸ However, advances in computed tomography angiography provide excellent sensitivity and specificity in delineating aneurysmal disease and allow for a practical noninvasive option to accurately evaluate the superficial and deep arterial systems of the hand, making it particularly useful in the pediatric population.⁹

Although there is no consensus treatment algorithm for managing these patients, several principles and trends can be garnered from the existing published accounts. Despite the fact that patients may be asymptomatic, intervention in these cases is always warranted because of the risk for embolic events and the potential sequelae.^{5,10,11} Although selective endovascular embolization is theoretically possible, questions about the adequacy of arterial perfusion to the hand following ablation of the aneurysm have resulted in most authors addressing these lesions with an open surgical approach.^{3–5,8,12,13}

Although a comprehensive preoperative plan must be formulated based on available examination and imaging data, collateral perfusion to the hand and digits can be more completely assessed intraoperatively, and a more informed decision can be made at that time whether arterial reconstruction is warranted. This lends credence to the prevailing trend of an open surgical approach in these cases, and most authors have opted for default ulnar artery reconstruction in pediatric patients as a hedge against possible complications

that could arise from any future insults to the remaining collateral arterial inflow.¹³ In the case presented here, the patient did not have identifiable superficial or deep palmar arch systems on imaging, and subsequently, an open approach was absolutely indicated to reconstruct the involved artery.

Though a variety of reconstructive techniques have been described, there has been no apparent consensus strategy. Although synthetic grafts tend to have lower long-term patency rates and may pose additional problems in pediatric patients with growth, arterial interposition grafts are easy to handle intraoperatively and demonstrate excellent long-term patency.² However, vein grafts from the forearm, dorsum of the foot, or the saphenous system is readily available, have demonstrated excellent outcomes, and are the most common approach in these patients.^{2,8,10} And though long-term studies are not available in the pediatric population because of the low incidence of disease, no significant postoperative complications have been described. We believe this treatment modality should be considered as the primary approach in these cases because of the potential pitfalls of less invasive and less comprehensive measures.

Hugo St. Hilaire, DDS, MD

Division of Plastic and Reconstructive Surgery
Louisiana State University
School of Medicine
1542 Tulane Ave. Room 758A
New Orleans, LA 70112
E-mail: hsthil@lsuhsc.edu

REFERENCES

1. Ferris BL, Taylor LMJ, Oyama K, et al. Hypothenar hammer syndrome: proposed etiology. *J Vasc Surg.* 2000;31:104–113.
2. McClinton MA. Reconstruction for ulnar artery aneurysm at the wrist. *J Hand Surg Am.* 2011;36:328–332.
3. Cron J, Saliou C, Fabiani JN. Traumatic aneurysm of the ulnar artery in a child. *Injury* 1997;28:401–403.
4. Iyer RS, Hanel DP, Enriquez BK, et al. Ulnar artery aneurysm causing palmar mass in 5-month-old girl. *Pediatr Radiol.* 2012;42:1401–1404.
5. Nguyen DQ, Murison M. Ulnar artery aneurysm in a patient with Marfan's syndrome. *J Plast Reconstr Aesthet Surg.* 2006;59:1131–1132.
6. Sarkar R, Coran AG, Cilley RE, et al. Arterial aneurysms in children: clinicopathologic classification. *J Vasc Surg.* 1991;13:47–56; discussion 56.
7. Cohen-Kashi KJ, Leeman J, Rothkopf I, et al. Traumatic ulnar artery aneurysm secondary to basketball dunk: a case report and review. *Vascular* 2012;20:96–99.
8. Al-Omran M. True ulnar artery aneurysm of the hand in an 18-month-old boy: a case report. *J Vasc Surg.* 2007;45:841–843.
9. Dalman RL. Upper extremity arterial bypass distal to the wrist. *Ann Vasc Surg.* 1997;11:550–557.
10. Amjad I, Murphy T, Zahn E. Diagnosis and excision of an ulnar artery aneurysm in a two-year-old boy. *Can J Plast Surg.* 2010;18:e15–e16.
11. Witt PD, Bowen KA, Johansen K. True ulnar artery aneurysm of the hand in an 8-year-old boy. *Plast Reconstr Surg.* 2003;111:2475–2476.
12. Memetoğlu ME, Memetoğlu ME, Erbasan O. An unusual clinical state: true ulnar artery aneurysm in a five-year old girl. *Interact Cardiovasc Thorac Surg.* 2012;14:675–676.
13. Offer GJ, Sully L. Congenital aneurysm of the ulnar artery in the palm. *J Hand Surg Br.* 1999;24:735–737.