

## CASE REPORT

# The dilemma of juvenile fibrous dysplasia versus chronic osteomyelitis of the posterior mandible: A case report

Ebtihal Zain-Alabdeen<sup>1</sup>  | Ashraf Abdelfattah<sup>2</sup> | Osama Kordi<sup>2</sup> | Ra'ed Al-Sadhan<sup>3</sup>

<sup>1</sup>Department of Oral Clinical and Basic Sciences, College of Dentistry, Taibah University, Almadinah Almunawwarah, Saudi Arabia

<sup>2</sup>Department of Oral and Maxillofacial surgery, King Fahad General Hospital, Almadinah Almunawwarah, Saudi Arabia

<sup>3</sup>Department Oral Medicine and Diagnostic Sciences, King Saud University, Riyadh, Saudi Arabia

## Correspondence

Ebtihal Zain-Alabdeen, Department of Oral Clinical and Basic Sciences, College of Dentistry, Taibah University, Almadinah Almunawwarah, Saudi Arabia.  
Email: [ebtihalh@gmail.com](mailto:ebtihalh@gmail.com)

## Abstract

The clinical and radiographic dilemma of fibrous dysplasia versus osteomyelitis is highlighted in this case of a 4-year-old girl with a bony hard swelling in mandibular body and ramus. Rather than relying on histopathological appearance alone, dental professionals should be familiar with the radiographic differences between the two conditions.

## KEYWORDS

craniofacial growth, juvenile fibrous dysplasia, mandible, recurrent osteomyelitis

## 1 | INTRODUCTION

Fibrous dysplasia (FD) is a type of hamartoma in which the medullary bone is replaced by immature and poorly calcified bone,<sup>1</sup> whereas osteomyelitis is an infection. Distinguishing between the two conditions is difficult when there is no trauma and no systemic disease. Various authors have reported that despite numerous similarities, useful radiographic differences do exist that help distinguish chronic osteomyelitis from FD.<sup>2-4</sup>

Here, we present a case in which we highlight this clinical and radiographic dilemma and describe the differences used to establish diagnosis and administer treatment.

## 2 | CASE REPORT

A 4-year-old girl was referred to a maxillofacial surgeon for swelling over the left angle of the mandible, the patient has

received general clinical examination to exclude any systemic involvement and to ensure that the complaint is localized to the orofacial region. Suspected to be an abscess or a tumor. The parents reported that the whole family was recovering from flu-like symptoms likely to be COVID-19 and that the swelling started after the patient became infected. It was possible, however, that the parents only noticed the swelling at that time, although it was, in fact, there beforehand.

## 3 | CLINICAL EXAMINATION

The extraoral examination showed a painless unilateral bone swelling and facial asymmetry due to swelling of the body and ramus of the left mandible. The swelling was bony hard with no clear signs of paresthesia or inflammation such as fever or redness. A solitary palpable lymph node, movable and tender, was noted in the submandibular area measuring approximately 1 cm in diameter.

This is an open access article under the terms of the [Creative Commons Attribution-NonCommercial-NoDerivs](https://creativecommons.org/licenses/by-nc-nd/4.0/) License, which permits use and distribution in any medium, provided the original work is properly cited, the use is non-commercial and no modifications or adaptations are made.

© 2022 The Authors. *Clinical Case Reports* published by John Wiley & Sons Ltd.

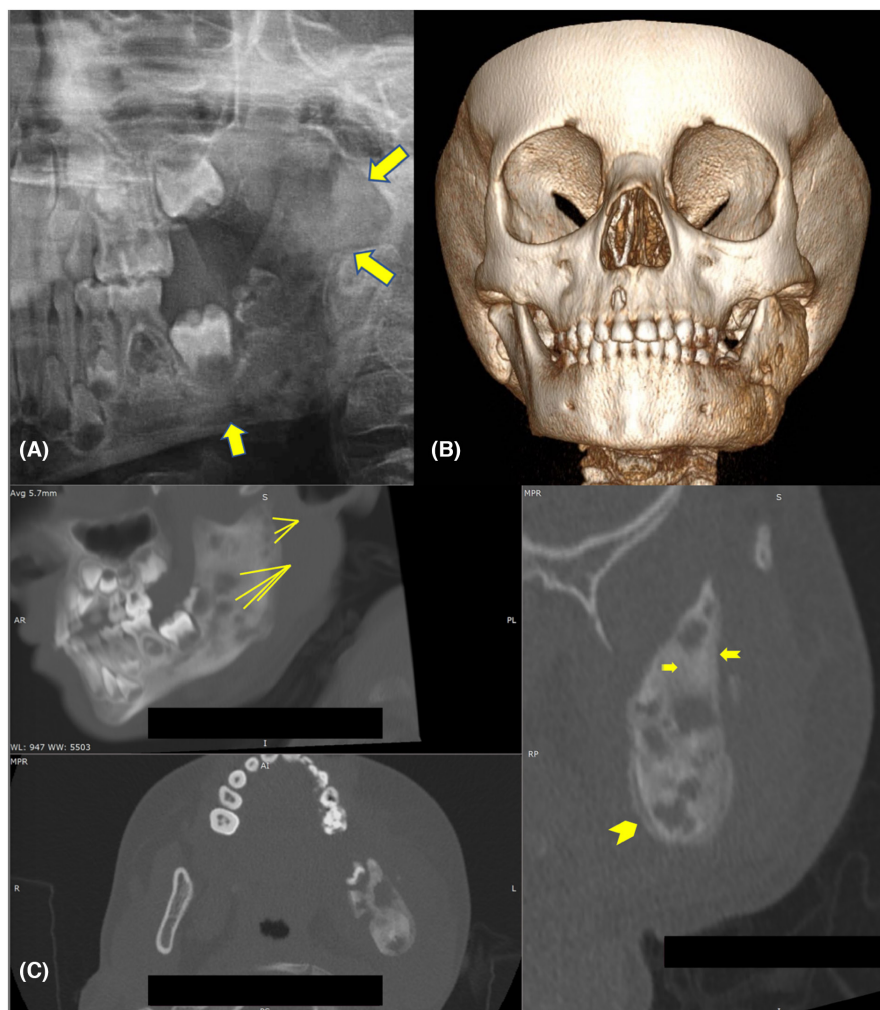
A panoramic radiographic examination was made with difficulty because of excessive patient movement. The radiograph showed intact and sound primary dentition with no signs of pulpal or periodontal inflammatory lesions. Computed tomography (CT) scan were obtained to rule out malignancy or infection, as well as to monitor craniofacial or soft tissue involvement.<sup>5</sup>

#### 4 | RADIOGRAPHIC INTERPRETATION

The cropped panoramic radiograph (Figure 1A) showed overall enlargement of the left side of the mandibular body and ramus with an abnormal bone pattern and an ill-defined lesion extending from the area of the developing mandibular left first permanent molar to the ramus and reaching the coronoid process. The internal structure was heterogeneous, with mixed radiolucency and radiopacity, or a ground glass appearance, having a granular bone pattern with a haphazard distribution. The lesion did not seem to be centered in the alveolar ridge and

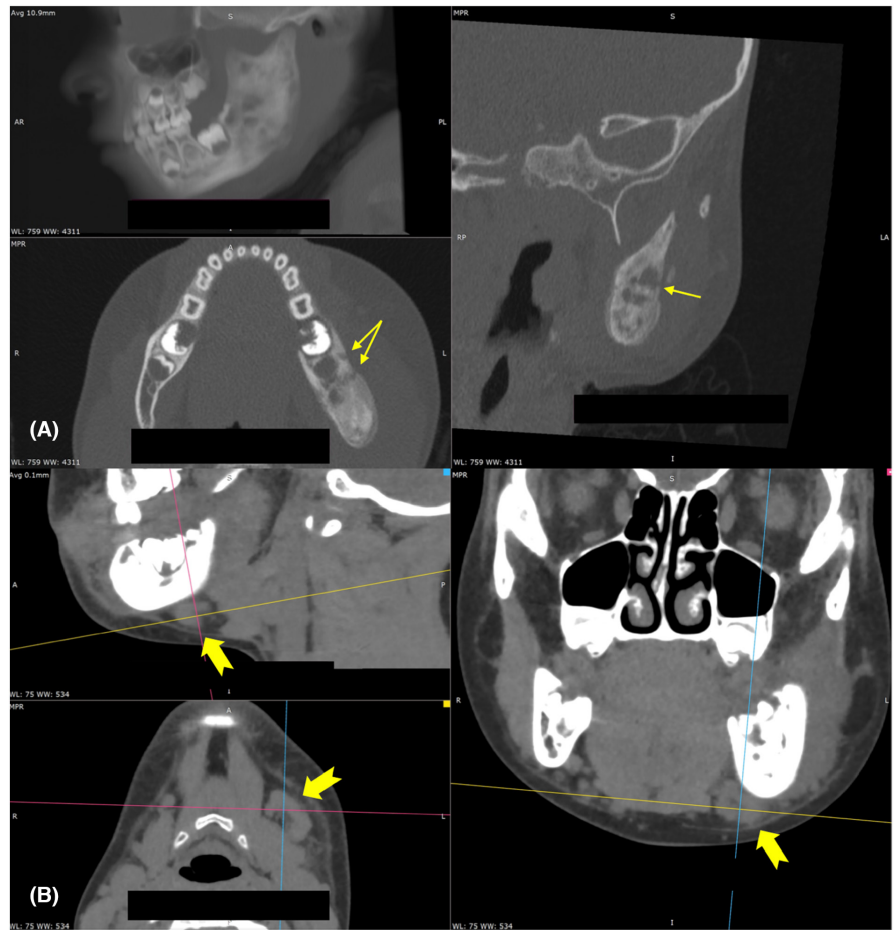
involved bone inferior to the mandibular canal; the teeth appeared to be intact. The volumetrically rendered CT images (Figure 1B) showed expansile disease affecting the left side of the mandible (body and ramus), causing asymmetry in the lower third of the face. The multiplanar view (Figure 1C) showed a well-defined radiopaque expansile lesion from the buccal and lingual aspects (axial view) and a moth-eaten appearance accompanied by ground glass attenuation occupying the left ramus and part of the body of the mandible (sagittal view), as well as thinning of cortices and an abnormal bone pattern (axial and cross-sectional views). The expansile lesion in the medullary space showed variable attenuation with mixed radiolucency and radiopacity, loss of trabecular bone architecture, and periosteal new bone formation on the lingual side of the mandible (Figure 1C, cross-sectional view).

The multiplanar view of the “bone window” (Figure 2A) showed a cloaca in the cross-sectional and axial views, which is the beginning formation of a draining fistula; the well-defined break in the outer cortex is an involucrum, which allows drainage of purulent and necrotic material out of dead bone. The multiplanar view of the “soft tissue



**FIGURE 1** (A) Cropped panorama: ill-defined lesion from the periapical region of the mandibular left first molar to the ramus, reaching the coronoid process. (B) volumetrically rendered radiograph showing left mandible enlargement. (C) Multiplanar view: sagittal, axial, and cross-sectional views with radiographic characteristics of osteomyelitis, lines show moth-eaten appearance, arrow show loss of trabecular bone architecture, notched arrow show cortical bone loss, chevron shows periosteal new bone formation.

**FIGURE 2** (A) Multiplanar view of the “bone window”: sagittal, axial, and cross-sectional views showing a cloaca (arrows), which is characteristic of osteomyelitis. (B) Multiplanar view of the “soft tissue window”: sagittal, axial, and cross-sectional views showing submandibular lymph node involvement (notched arrows).



window” (Figure 2B) showed submandibular lymph node enlargement in the sagittal, axial, and coronal views.

All of these radiographic features are associated with osteomyelitis and may sometimes be associated with severe fibro-osseous lesions.<sup>6</sup> The extensively dysplastic bone and limited blood supply in a compact mandible that already has less collateral circulation than the maxilla will produce an ischemic condition that may result in such a presentation, especially in a very young patient. In light of the chief concern, patient history, extra- and intra-oral examination, and radiographic investigations, a diagnosis needed to be confirmed histologically. The patient’s parents were informed about the surgical plan, and informed consent was obtained. Inflammatory markers were measured, and the results of blood investigations were all well within the normal range. Mandibular shaving was performed, and a biopsy sample taken; there was no pus and no culture was done.

## 5 | HISTOPATHOLOGICAL EXAMINATION

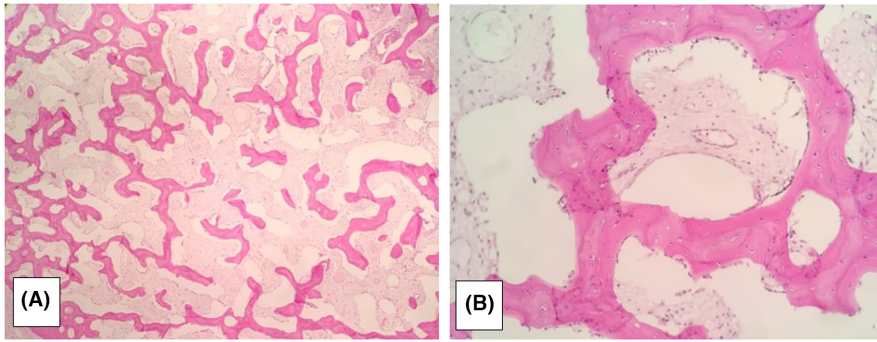
The following results of the histological examination were obtained (Figure 3):

- bone tissue exhibiting branching and anastomosing irregular trabeculae of woven bone with no conspicuous osteoblastic rimming
- intervening fibrous stroma containing cytologically bland spindle cells
- no mitotic figures

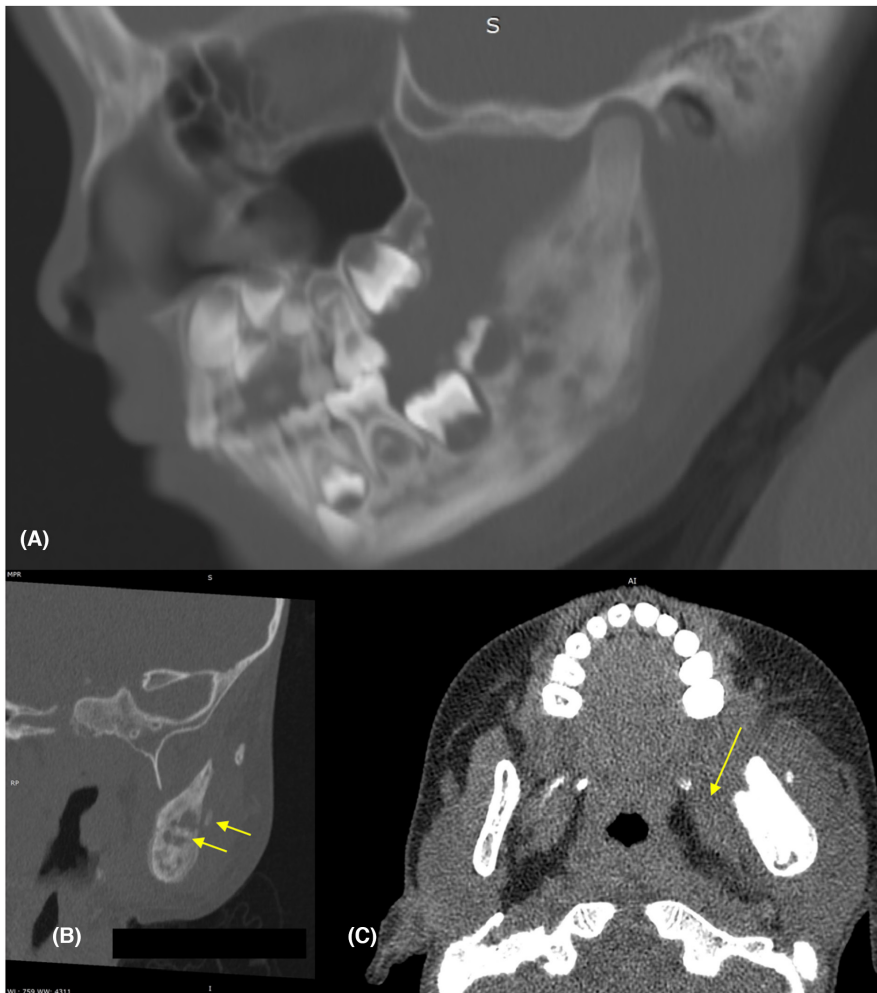
The final diagnosis was fibrous dysplasia.

A few months later, the patient returned with a relapse of the lesion accompanied by pain. Another CT scan showed the same radiographic appearance that was seen in the first and second CT scans: a sequestrum, an involucrum, and periosteal new bone formation surrounding the sequestrum, in addition to periosteal reaction thickening (periostitis) and fistula formation (cloaca), highly suggestive of osteomyelitis and inconsistent with FD. A CT scan 3 months later showed wider involvement of the mandible that is getting closer to the condylar head (Figure 4A), an increase in the size and number of lytic lesions, more sequestrum formation (Figure 4B), and swelling and blurring of normal soft tissue planes (Figure 4C). The patient has been followed up since October 2020, her most recent follow-up being in January 2021.





**FIGURE 3** (A) Trabecular pattern in fibrous stroma seen in (5X) magnification. (B) The (30X) magnification shows “Chinese letter” trabecular pattern.



**FIGURE 4** (A) Sagittal view showing the spread of the lesion to the condyle. (B) Cross-sectional view showing the sequestrum. (C) Axial view of the “soft tissue window,” showing soft tissue swelling and loss of normal planes of fascia between medial pterygoid muscles.

## 6 | DISCUSSION

FD lesions typically manifest during the first and second decade of life, and cases have been reported as early as 3 years of age.<sup>7</sup> Monostotic FD affects the mandible, typically the unilateral posterior area with no specific sex predilection.<sup>8</sup> The bone becomes enlarged but maintains its overall shape, an ill-defined border gradually blends with surrounding bone, and the lesion bone pattern may have a ground glass, cotton wool, or dense amorphous appearance. The lesions usually begin growing at a young age

and stop at the end of somatic growth. In the present case, the radiographic appearance of the lesions was typically mixed radiolucency and radiopacity, producing a characteristic ground glass appearance, but this depends on the stage of the disease, as early lesions tend to be radiolucent and become more opaque as they progressively calcify.<sup>9,10</sup> Although the FD margins were generally poorly defined on CT for the mandibular lesions, one factor could be the relatively thick (5 mm) sections. CT images of FD on bone windows can display a range of opacification observed on plain radiographs, such as radiolucency, ground glass, and cotton wool.<sup>11</sup>

Chronic sclerosing osteomyelitis, an inflammatory bone condition of uncertain origin, was suggested in the differential diagnosis, as it is generally believed to be an infection of etiological significance, and recurrent pain and swelling of long duration are commonly reported symptoms. However, on occasion, mild and often nonspecific symptoms make a definitive diagnosis difficult.<sup>12</sup> A study reported that chronic sclerosing osteomyelitis involves the ramus in 16.9% of cases and both the body and the ramus in 14.3% of cases.<sup>13</sup> Painful swelling was reported in only 13.8% of patients,<sup>14–16</sup> trismus in 15.1%,<sup>17</sup> and fever in 7.7%.<sup>13</sup> The left mandibular side seems to be slightly more affected (54.0% of cases) than the right side (41.5% of cases). Systemic signs such as body temperature, white blood cell count, and erythrocyte sedimentation rate are either within normal range or slightly elevated,<sup>12,18</sup> similar to those our case. Obtaining a positive culture for the responsible microorganisms from the lesion may be either difficult or nonrepresentative because of contamination with skin or oral microflora.

In our case, the histopathological appearance was of a typical “Chinese letter” trabecular pattern. However, studies have shown that the histopathological appearance of osteomyelitis can feature replacement of normal marrow with fibrous connective tissue, sometimes accompanied by an inflammatory cell infiltrate, new bone formation, and the presence of bony sequestra. The inflammatory cell infiltrate is sparse or difficult to detect. Occasionally, the appearance is similar to that seen in FD or osteogenic sarcoma.<sup>18,19</sup>

Chronic non-suppurative osteomyelitis with proliferative periostitis (PP) was also suggested in the differential diagnosis, as there was no demonstrable cause.<sup>13,20</sup> A hypothesis was therefore raised to explain our case: that the infection was caused by a local low-virulence bone infection, such as COVID-19. However, investigations could not confirm this hypothesis. Suggestive of osteomyelitis of unknown origin were sequestra and laminated “onion-skin” periosteal new bone as seen in Figure 1C; mixed sclerosis and bone destruction as seen in Figure 1A,C, loss of normal fat as seen in Figure 4C, the presence of a submandibular lymph node on the same side as seen in Figure 3B, and the presence of a cloaca and sinus tract as seen in Figure 3A.

Many classifications of chronic osteomyelitis have been proposed, depending on clinical aspect or origin (bacterial or inflammatory). Newly formed periosteal bone was organized, at early stages of the disease, in different aspects, either with an “onion skin” appearance (33.8% of cases), lamellae duplication (12.3% of cases), or sunburst aspect (3% of cases).<sup>13</sup> PP occurred predominantly on the buccal side of the mandible (85%

of cases). In the present case, PP was present buccally and lingually.

According to Bisseret et al.,<sup>21</sup> the appearance of the underlying cortex in a periosteal reaction is an important criterion to assess the aggressiveness of osteomyelitis and is more useful than the pattern of the periosteal reaction. Thus, the destruction of the cortex and a “moth-eaten” appearance, as seen in Figure 1C, denotes aggressive disease.

FD is not a condition in which tissue is added to the surface as in periostitis; consequently, the cortex may preserved in either condition, and when the bone of the jaw sometimes reveals evidence of non-odontogenic disease, the possibility of other than pyogenic infection should be borne in mind, for instance, tuberculosis.<sup>12</sup>

## 7 | DIFFERENTIAL DIAGNOSES

Before making a diagnosis of chronic non-suppurative osteomyelitis with PP, numerous other causes of periostitis should be considered, in particular if no obvious etiological factor exists. Juvenile mandibular chronic osteomyelitis and chronic osteomyelitis should be excluded. A differential diagnosis must then be made with isolated periostitis associated with osseous benign lesions, such as giant cell granuloma, FD, or osteoid osteoma.<sup>21</sup> Malignant tumors, such as Ewing’s sarcoma, chondrosarcoma, and osteosarcoma, usually present more aggressive symptoms and soft tissue involvement. In these pathologies, a periosteal reaction radiographically resembles a “sun ray” or an “onion skin” pattern.<sup>21</sup>

Systemic diseases that may be responsible for secondary periostitis in pediatric patients should be excluded such as metabolic disorders, hematologic malignancies (leukemia, lymphoma, Langerhans cell histiocytosis), sickle cell anemia, and vasculitis.<sup>22</sup> Bacterial mandibular osteomyelitis lesions are characterized by suppuration, osteolytic radiographic changes with lamellar-type periosteal reaction, and an impressive response to antibiotic administration.

Although primary chronic osteomyelitis is not age related, most of the relevant published data refer to adult patients, and only case reports or small series of patients with early-onset of the disease during childhood or adolescence are encountered in the literature. Heggie et al.<sup>23</sup> and Baltensperger et al.<sup>24</sup> observed a high incidence and uniformity of features of the disease among children and adolescents, respectively, proposing that the pediatric “variation” should be regarded as a separate clinical entity and suggesting the term “juvenile chronic osteomyelitis” for its description.<sup>25</sup>

## 8 | CONCLUSION

Jaw lesion specially in children should be established as early as possible to prevent adverse treatment outcomes and to improve prognosis,<sup>26</sup> there should be multidisciplinary approach in achieving diagnosis of oral lesions specially jaw lesions and practitioners should seek expert advice from other specialist in histopathology and radiology to implement the necessary diagnostic methods to achieve diagnosis.

### AUTHOR CONTRIBUTIONS

**Ebtihal Zain-Alabdeen** involved in introduction, discussion, data collection. **Ashraf Abdelfattah** involved in clinical and pathological examination, biopsy. **Osama Kurdi** involved in past medical history and histopathology. **Ra'ed Al-Sadhan** involved in radiographic interpretation and figures selection.

### ACKNOWLEDGMENTS

English language editing was provided by Barbara Every, ELS, of BioMedical Editor.

### FUNDING INFORMATION

This research did not receive any specific grant from funding agencies in the public, commercial, or not-for-profit sectors.

### CONFLICT OF INTEREST

The authors have no conflict of interest to declare.

### DATA AVAILABILITY STATEMENT

The data that support the findings of this study are available on request from the corresponding author. The data are not publicly available due to privacy or ethical restrictions.

### CONSENT

Written informed consent was obtained from the patient to publish this report in accordance with the journal's patient consent policy. I confirm that the patient consent has been signed and collected in accordance with the journal's patient consent policy. I will retain the consent form and will provide it if requested.

### ORCID

Ebtihal Zain-Alabdeen  <https://orcid.org/0000-0001-7413-8748>

### REFERENCES

- Assiri KI. Monostotic fibrous dysplasia involving the mandible: a case report. *SAGE Open Med Case Rep*. 2020;8:2050313X20936954.
- Mohan RPS, Verma S, Gupta N, Ghanta S, Agarwal N, Gupta S. The radiological versatility of fibrous dysplasia: an 8-year retrospective radiographic analysis in a north Indian population. *Indian J Dent*. 2014;5(3):139-145.
- Punyani SR, Srivastava S, Jasuja VR. Craniofacial fibrous dysplasia report of a case with diverse radiological spectrum. *Clin Cases Miner Bone Metab*. 2016;13(3):249-252.
- Gupta D. Osteomyelitis of the mandible mimicking fibrous dysplasia: a radiographic controversy. *Clin Dent*. (0974-3979). 2013;7(3).
- Schulze D, Blessmann M, Pohlenz P, Wagner K, Heiland M. Diagnostic criteria for the detection of mandibular osteomyelitis using cone-beam computed tomography. *Dentomaxillofac Radiol*. 2006;35(4):232-235.
- Chen Wongworawat Y, Jack D, Inman JC, et al. Regional lymph node enlargement in clinically severe cherubism. *Clin Pathology*. 2019;12:2632010X19861107.
- Burke AB, Collins MT, Boyce AM. Fibrous dysplasia of bone: craniofacial and dental implications. *Oral Dis*. 2017;23(6):697-708.
- De Melo WM, Sonoda CK, Hochuli-Vieira E. Monostotic fibrous dysplasia of the mandible. *J Craniofac Surg*. 2012;23(5):e452-e454.
- Davidova LA, Bhattacharyya I, Islam MN, Cohen DM, Fitzpatrick SG. An analysis of clinical and histopathologic features of fibrous dysplasia of the jaws: a series of 40 cases and review of literature. *Head Neck Pathol*. 2020;14(2):353-361.
- Suluk-Tekkesin M, Sinanoglu A, Selvi F, Cakir Karabas H, Aksakalli N. The importance of clinical and radiological findings for the definitive histopathologic diagnosis of benign fibrous lesions of the jaws: study of 276 cases. *J Stomatol Oral Maxillofac Surg*. 2021;123(3):364-371.
- MacDonald-Jankowski DS, Yeung R, Li TK, Lee KM. Computed tomography of fibrous dysplasia. *Dentomaxillofac Radiol*. 2004;33(2):114-118.
- Worth HM. *Principles and Practice of Oral Radiologic Interpretation*. Year Book Medical Publishers; 1963.
- Taihi I, Radoi L. Chronic non-suppurative mandibular osteomyelitis with proliferative periostitis: a review. *Quintessence Int*. 2018;49(3):219-226.
- Gonçalves M, Gonçalves A. Garre's osteomyelitis associated with a fistula: a case report. *J Clin Pediatr Dent*. 2002;26(3):311-313.
- Kannan S, Sandhya G, Selvarani R. Periostitis ossificans (Garre's osteomyelitis) radiographic study of two cases. *Int J Paediatr Dent*. 2006;16(1):59-64.
- Lincoln TA, Webber SJ. An extremely unusual case of Garre's osteomyelitis of the mandibular condyle after surgical removal of third molars. *J Oral Maxillofac Surg*. 2012;70(12):2748-2751.
- Seok H, Kim S-G, Song J-Y. Proliferative periostitis of the mandibular ramus and condyle: a case report. *J Korean Assoc Oral Maxillofac Surg*. 2015;41(4):198-202.
- Orpe E, Lee L, Pharoah M. A radiological analysis of chronic sclerosing osteomyelitis of the mandible. *Dentomaxillofac Radiol*. 1996;25(3):125-129.
- Chang Y-C, Shieh Y-S, Lee S-P, et al. Chronic osteomyelitis with proliferative periostitis in the lower jaw. *J Dent Sci*. 2015;10(4):450-455.
- Kawai T, Hiranuma H, Kishino M, Murakami S, Sakuda M, Fuchihata H. Gross periostitis ossificans in mandibular osteomyelitis: review of the English literature and radiographic

- variation. *Oral Surg Oral Med Oral Pathol Oral Radiol Endod.* 1998;86(3):376-382.
21. Bisseret D, Kaci R, Lafage-Proust M-H, et al. Periosteum: characteristic imaging findings with emphasis on radiologic-pathologic comparisons. *Skelet Radiol.* 2015;44(3):321-338.
  22. Cheon J-E, Kim I-O, Kim WS, Yeon KM. Isolated periostitis as a manifestation of systemic vasculitis in a child: imaging features. *Pediatr Radiol.* 2010;40(1):116-119.
  23. Heggie A, Shand J, Aldred M, Talacko A. Juvenile mandibular chronic osteomyelitis: a distinct clinical entity. *Int J Oral Maxillofac Surg.* 2003;32(5):459-468.
  24. Baltensperger M, Grätz K, Bruder E, Lebeda R, Makek M, Eyrich G. Is primary chronic osteomyelitis a uniform disease? Proposal of a classification based on a retrospective analysis of patients treated in the past 30 years. *J Craniomaxillofac Surg.* 2004;32(1):43-50.
  25. Theologie-Lygidakis N, Schoinohoriti O, Iatrou I. Surgical management of primary chronic osteomyelitis of the jaws in children: a prospective analysis of five cases and review of the literature. *Oral Maxillofac Surg.* 2011;15(1):41-50.
  26. Zain-Alabdeen EH, Al-Sadhan RI, AlSuhaim FS, AlMutairi KM. Delayed diagnosis in the maxillofacial region: two case reports. *J Taibah Univ Med Sci.* 2017;12(6):548-554.

**How to cite this article:** Zain-Alabdeen E, Abdelfattah A, Kordi O, Al-Sadhan R. The dilemma of juvenile fibrous dysplasia versus chronic osteomyelitis of the posterior mandible: A case report. *Clin Case Rep.* 2022;10:e06379. doi: [10.1002/ccr3.6379](https://doi.org/10.1002/ccr3.6379)