




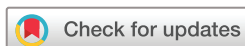

# openheart Contemporary use of excimer laser in percutaneous coronary intervention with indications, procedural characteristics, complications and outcomes in a university teaching hospital

Muhammad Jawad-UI-Qamar <sup>1,2</sup> Harish Sharma <sup>1,2</sup>  
 Vincenzo Vetrugno <sup>1,3</sup> Kully Sandhu,<sup>1</sup> Peter F Ludman <sup>1</sup> Sagar N Doshi,<sup>1</sup>  
 Jonathan N Townend,<sup>1</sup> Mohammed Osheiba,<sup>1</sup> Alex Zaphiriou,<sup>1</sup> Sohail Q Khan <sup>1,2</sup>

**To cite:** Jawad-UI-Qamar M, Sharma H, Vetrugno V, *et al*. Contemporary use of excimer laser in percutaneous coronary intervention with indications, procedural characteristics, complications and outcomes in a university teaching hospital. *Open Heart* 2021;**8**:e001522. doi:10.1136/openhrt-2020-001522

Received 20 December 2020  
 Revised 22 February 2021  
 Accepted 2 March 2021



© Author(s) (or their employer(s)) 2021. Re-use permitted under CC BY. Published by BMJ.

<sup>1</sup>Department of interventional cardiology, Queen Elizabeth Hospital Birmingham, Birmingham, UK

<sup>2</sup>Institute of Cardiovascular Sciences, University of Birmingham, Birmingham, UK  
<sup>3</sup>Cardiology Division, Azienda Ospedaliero-Universitaria di Modena Ospedale Civile di Baggiore, Modena, Italy

## Correspondence to

Dr Sohail Q Khan; sohail.khan@uhb.nhs.uk

## ABSTRACT

**Background** Excimer laser coronary atherectomy (ELCA) can be used as an adjunctive percutaneous coronary intervention treatment for challenging, heavily calcified lesions. Although previous studies have documented high rates of complication and restenosis, these predate the introduction of the smaller 0.9 mm laser catheter. As the coronary complexity has increased, there has been a renewed interest in the ELCA. This study investigates the indications, procedural characteristics, complications and outcomes of ELCA in a contemporary coronary interventional practice.

**Methods** This single-centre study retrospectively analysed 50 patients treated with ELCA between January 2013 and January 2019.

**Results** Patients had a mean age of 67.9±11.4 years with a male predominance (65.3%). 25 (50%) cases were performed in patients with stable angina. Failure to deliver the smallest available balloon/microcatheter was the most frequent indication in 32 (64%) cases for ELCA use. 30 (60%) of the procedures were performed via radial access. The 0.9 mm X-80 catheter was used in 41 (82%) of cases, delivering on average 9000±3929 pulses. ELCA-related complications included 2 coronary dissections and 1 perforation, all of which were covered with stents. No major complications could be directly attributed to the use of ELCA. There was one death and one case of stent thrombosis within 30 days of the procedure.

**Conclusion** ELCA can be performed safely via the radial approach with a 0.9 mm catheter with a high success rate by suitably trained operators. The low procedure-related complications with contemporary techniques make this a very useful tool for complex coronary interventions, especially for difficult to dilate lesions and chronic total occlusion vessels.

## Key questions

### What is already known about this subject?

- ▶ Coronary laser atherectomy is a useful but underused treatment modality in treatment of calcified difficult to cross lesions.
- ▶ There have been mixed earlier reports of success with this modality and relatively high procedural complications mostly with the bulky 1.4 mm laser catheter.

### What does this study add?

- ▶ Our work shows that laser atherectomy via radial approach using 0.9 mm laser catheter is safe and convenient with good periprocedural outcomes.

### How might this impact on clinical practice?

- ▶ These results are expected to encourage other centres involved in complex coronary intervention to take up coronary laser atherectomy more frequently in calcified, difficult to dilate lesions and chronic total occlusions.

## INTRODUCTION

Percutaneous coronary intervention (PCI) in patients with heavily calcified vessels is challenging. Severely calcified lesions account for up to 12% of patients undergoing coronary angiography<sup>1</sup> and can prevent the crossing of balloons and even wires. Even if the lesion can be crossed with a wire, calcified or heavily fibrotic plaques may resist high-pressure non-compliant balloon inflations and cutting balloons. Attempting stent implantation within such lesions risk stent malapposition, underdeployment and increase risk of coronary dissection, perforation and stent

Table 1 Baseline data	
Variable	Mean ( $\pm$ SD) number (%)
Age, years	67.9 ( $\pm$ 11.4)
Gender	
Male	32 (65.3%)
Female	17 (34.7%)
BMI, kg/m <sup>2</sup>	29.1 ( $\pm$ 5.8)
Previous CVA	2 (4.1%)
Peripheral vascular disease	4 (8.2%)
Non-cardiac surgery	2 (4.1%)
Previous MI	23 (46.9%)
Previous CABG	11 (22.4%)
Previous PCI	24 (29%)
Diabetes	
Not diabetic	27 (55.1)
Diet controlled	1 (2)
Oral medicine	12 (24.5)
Insulin dependent	9 (18.4%)
Clinical syndrome	
Stable angina	25 (50%)
UA/NSTEMI	17 (34%)
STEMI	8 (16%)
Cardiogenic shock (consequence of STEMI)	3 (6%)
Target vessel	
LMS/LAD	21 (42%)
LCX/RCA	26 (52%)
SVG	3 (6%)
Procedure urgency	
Elective	23 (46%)
Urgent	19 (38%)
Emergency	8 (16%)
LV function	
Good (EF >50%)	31 (63.3)
Moderate (EF 30%–50%)	8 (16.3)
Poor (EF <30%)	4 (8.2)
Unknown	6 (12.2)
Diagnostic devices	
None	38 (76%)
IVUS/OCT	7 (14%)
Pressure wire	2 (4%)
Procedural indications	
Heavily calcified lesion	22 (44%)
CTO (failure to cross)	10 (20%)
High thrombus burden	11 (22%)
In-stent restenosis	7 (14%)
6 Fr guide catheter	41 (82%)

Continued

Table 1 Continued	
Variable	Mean ( $\pm$ SD) number (%)
Arterial access	
Radial (right/left)	30 (60%)
Femoral	16 (32%)
Combined (radial/femoral)	4 (8%)
Glycoprotein IIb/IIIa (eptifibatide)	8 (16%)

BMI, body mass index; CABG, coronary artery bypass grafting; CTO, chronic total occlusion; EF, ejection fraction; IVUS, intravascular ultrasound; LAD, left anterior descending artery; LCX, left circumflex artery; LMS, left main stem; LV, left ventricle; MI, myocardial infarction; NSTEMI, non-ST-elevation myocardial infarction; OCT, optical coherence tomography; PCI, percutaneous coronary intervention; RCA, right coronary artery; STEMI, ST-elevation myocardial infarction; SVG, saphenous vein grafts; UA, unstable angina.

thrombosis. Specialised techniques and equipment are therefore required for such cases.

Atheroablation by excimer laser coronary atherectomy (ELCA) can be helpful in these circumstances. Excimer lasers use a mixture of rare gas and halogen to generate brief pulses of high-frequency ultraviolet (UV) light. The UV laser can disrupt hard atherosclerotic plaque through several mechanisms, including breaking molecular bonds (photochemical), plaque cell rupture by heat generated at the catheter tip (photothermal) and disruption of intravascular material as vapour bubbles rapidly expand and implode (photomechanical).<sup>2</sup> The fragments released are small (<10  $\mu$ m) and thus do not obstruct the coronary microcirculation.<sup>3</sup> The short wavelength (308 nm) ensures minimal penetration of thermal energy beyond the intended target.

Compared with rotational atherectomy (RA), excimer catheters offer unique advantages including a short monorail segment, easing delivery over a standard 0.014" guidewire. Additionally, the most widely used 0.9 mm X-80 catheter is deliverable via a 6 Fr guide catheter, allowing ELCA to be performed via the radial approach. However, severely calcified plaques may require treatment with both ELCA and RA in combination, referred to as a 'RASER' procedure.<sup>4</sup>

Laser atherectomy has been used as an adjunct to percutaneous coronary intervention since the early 1980s.<sup>5</sup> Early studies have documented high complication rates and restenosis.<sup>6</sup> However, these studies predate the introduction of the smaller 0.9 mm catheter, which is now the most frequently used laser catheter for coronaries.<sup>7</sup> Although the efficacy of ELCA has been assessed in a variety of clinical cohorts, there is a paucity of clinical outcome data in a real-world mixture of patients presenting with and without acute myocardial infarction. In this study, we present indications, procedural characteristics, complications and outcomes of ELCA in a contemporary coronary interventional practice in a single large quaternary UK hospital over 6 years.

**Table 2** Procedural data

Variable	Mean ( $\pm$ SD) number (%)	Variable	Mean ( $\pm$ SD) number (%)
Size of laser catheter (mm)		Fluence	
0.9	41 (82 %)	80	16 (32%)
1.4	3 (6%)	40–80	13 (26%)
Unknown	6 (12%)	Unknown	21 (42%)
Frequency (Hz)		Adjunctive rotational atherectomy	11 (22%)
80	18 (36%)	Size of burr	
40–80	12 (24%)	1.25 mm	4 (8%)
Unknown	20 (40%)	1.5–2 mm	5 (10%)
Number of pulses	9000 ( $\pm$ 3929)	>2 mm	2 (4%)

Hz, Hertz; mm, Millimeter.

## METHODS

### Study population

Fifty consecutive patients treated with ELCA from 1 January 2013 to 31 January 2019 at the Queen Elizabeth Hospital, Birmingham, UK. Patients were identified using a prospectively maintained British Cardiovascular Interventional Society database.

As it was an all comers cohort, the indications ranged from elective PCI in the setting of stable angina to emergency acute coronary syndromes with cardiogenic shock without any exclusion criteria. Laser was used if the lesion was angiographically assessed as heavily calcified and the inability of the smallest balloon or microcatheter to cross the lesion. For those lesions that were assessed with intravascular ultrasound or optical coherence tomography, laser was used if the imaging suggested a very high thrombus burden or in calcified lesions a  $\geq 270$  degree of calcium arc, with  $\geq 0.5$  mm thickness and  $\geq 40$  mm of length of calcified lesion.

### Outcomes

Immediate procedural success was defined as thrombolysis in myocardial infarction (TIMI) III flow in the target vessel with  $< 50\%$  pre-angioplasty luminal stenosis. Major adverse cardiac and cerebrovascular event (MACCE) were defined as all-cause death, myocardial infarction or stroke and was recorded during hospital stay and at 30-day follow-up.

### ELCA procedure details

The excimer laser system (Spectranetics CVX-300) uses xenon chloride medium to generate UV light and produces a monochromatic single wavelength—308 nm fluence of 20–80 mJ/mm<sup>2</sup> and pulse repetition rate of 40–80 Hz. Vascular access was obtained using 6 or 7 Fr sheaths in the radial or femoral arteries. In some cases, both radial and femoral access were required. The laser catheter used was of 0.9 mm or 1.4 mm in diameter. Saline flush and bathe technique was used to clear the blood and dye during delivery of the therapy and the catheter was advanced in small increments with 10 s bursts of lasing.

## RESULTS

### Baseline characteristics

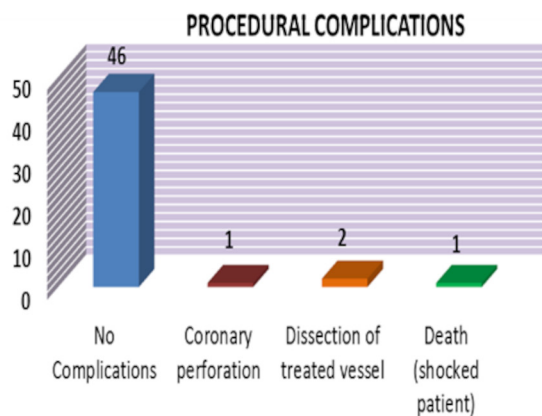
Patients had a mean age of 67.9 $\pm$ 11.4 years and a male preponderance 32/50 (64%). The majority of patients (72%) had previous revascularisation with either PCI or coronary artery bypass grafting. Twelve (24%) patients had adjuvant coronary fractional flow reserve/coronary imaging at the same time. Twenty-three (46%) patients were treated electively and 8 (16%) patients were treated as emergencies for ST-elevation MI, among whom 3 (6%) patients were in cardiogenic shock. Laser atherectomy was used as an adjuvant to coronary RA in 11 (22%) cases and thrombus aspiration was performed in 6 (12%) patients. Glycoprotein IIb/IIIa inhibitor was used in eight (16%) cases. Thirty (60%) cases were performed by radial (left/right) approach without the need to change the access site. Only 16 (32%) cases were performed via the femoral approach and a further 4 (8%) used both radial and femoral approach. One of the main indications of ELCA was the failure of balloon tracking due to a calcified lesion or chronic total occlusion (CTO) occurred, which was seen in 32 (64%) cases (table 1).

### Laser technical data

The majority of cases (82%) were performed using the 0.9 mm diameter ELCA catheter. A frequency of 80 Hz was used in 18 (36%) cases and 40–80 Hz in another 12 (24%) cases. The data were not available for the rest of the cases. The mean number of laser pulses were 9000 $\pm$ 3929 (table 2).

### Procedure outcomes

There were no periprocedural complications in 46 (92%) patients (figure 1). Laser atherectomy was successful in crossing all uncrossable lesions where the smallest balloon or microcatheter could not cross. A coronary perforation occurred in one case and was treated by a covered stent. The perforation was attributed to use of RA. Two cases of coronary dissection were seen and were treated successfully with a drug-eluting stent. These complications were not directly attributable to the use of ELCA.



**Figure 1** Immediate periprocedural complications while the patient was in the cardiac catheter lab.

One death occurred during the procedure in a patient with cardiogenic shock in the context of a late presenting MI. Apart from one mortality, all patients had immediate procedural success with <50% residual stenosis and TIMI III flow in the target vessel. The mean stented segment length was 41 mm (SD 9 mm) and diameter was 3.1 mm (SD 4.2 mm). Within 30 days of the procedure, there was one transient ischaemic attack and one stent thrombosis leading to MI and both these patients made full recovery (table 3).

## DISCUSSION

This study documents the 6-year experience of a single large quaternary centre using ELCA to treat non-crossable, heavily calcified coronary artery lesions. Presence of CTO and very calcified lesion was the main indication in about two-thirds of the cases in our cohort. The results from this retrospective study found that ELCA was associated with high rates of procedural success and low rates of periprocedural complications. The majority of PCI procedures are performed via the radial artery and on finding non-crossable lesions, ELCA can be performed without the need for changing access site. While previous studies report up to 48%<sup>4</sup> transradial ELCA, in this study 60% of cases were performed via the transradial approach alone without compromising success or complication rate.

This study demonstrates a low rate of coronary dissection compared with other studies. In trials excluding patients with acute MI, the rate of angiographic dissection

**Table 3** 30-Day MACCE (for death, myocardial infarction and stroke/TIA)

Variable	N (%)
No complication	47 (94%)
Death	1 (2%)
Myocardial infarction (subacute stent thrombosis)	1 (2%)
TIA	1 (2%)

MACCE, major adverse cardiac and cerebrovascular event; TIA, transient ischaemic attack.

following ELCA use has been reported as up to 13%.<sup>8</sup> In another study of 151 post-MI patients treated with ELCA,<sup>9</sup> major dissection occurred in 5% of cases, compared with only 2% in the present study. Other studies have corroborated that low rates of coronary dissection can be achieved. The multicentre CORAL trial demonstrated that the procedural success of ELCA in the treatment of patients with saphenous vein grafts was lower (82%) than comparative studies in native coronary vessels, however, the rate of major dissection was just under 1% and lower 30-day MACE as compared with control population from the Saphenous vein graft Angioplasty Free of Emboli Randomized (SAFER) trial.<sup>10</sup>

With an ageing population, heavily calcified coronary lesions and in-stent restenosis (ISR) are likely to be encountered with increasing frequency. ELCA is expected to become more widely adopted over time. The use of ELCA to treat patients with ISR has been assessed in several studies. Applying laser to five types of stainless-steel coronary stents did not impact stent endurance or release significant particulate matter. ELCA in the setting of ISR has similar rates of procedural success, complications and long-term clinical outcomes as balloon angioplasty alone,<sup>11</sup> and RA.<sup>12</sup> The combination of ELCA and balloon angioplasty produces greater stent expansion than balloon angioplasty alone.<sup>13</sup>

While RA remains the main treatment modality for heavily calcified lesions, it relies on a 0.009-inch RotaWire be advanced distal to the lesion. Case series have demonstrated that RASER can facilitate revascularisation where the RotaWire could not traverse the lesion.<sup>4</sup> In this study, ELCA was combined with RA in 22% of cases, which is higher than previous work by Badr *et al.*<sup>14</sup>

## Limitations

ELCA is a specialised coronary adjunctive treatment which is performed only in a relatively small number of centres with expertise. This retrospective study is therefore limited by the small number of ELCA procedures performed despite assessing a 6-year timeframe. Furthermore, while 30-day MACCE data are presented, long-term data have not been compiled. Another limitation has been the relatively low use of intracoronary imaging used. This could be explained by the presence of some cases with acute MI and high thrombus burden in which flow restoration and clinical stability was the first priority of management. Moreover, the accepted standard of use of intracoronary imaging in the highly calcified vessels was not as widespread in the earlier half of the dataset.

## CONCLUSIONS

ELCA can be performed safely via the radial approach in most patients with a 0.9 mm catheter with a high success rate. The low procedure-related complications with contemporary techniques make this a very useful tool for complex coronary interventions, especially for difficult to dilate lesions or CTO vessels.

**Twitter** Muhammad Jawad-Ul-Qamar @Jawadulqamar and Mohammed Osheiba @mosheiba

**Acknowledgements** We thank the broader cardiology team at the Queen Elizabeth hospital for their help in the clinical cases included in the manuscript.

**Contributors** SQK started the original idea and supervised the project. MJUQ collated the data and performed the original analysis. MJUQ, HS, SQK and VV drafted the paper. SQK, KS, PFL, JNT, SND, MO and AZ provided expert review of the paper, especially in the methods, results and discussion.

**Funding** The authors have not declared a specific grant for this research from any funding agency in the public, commercial or not-for-profit sectors.

**Competing interests** None declared.

**Patient consent for publication** Not required.

**Ethics approval** The British Cardiovascular Interventional Society (BCIS) formally collects the data for all coronary interventional procedures performed in the UK with regard to the clinical characteristics, procedural details and outcomes as part of a robust National Institute of Cardiovascular Research (NICOR) audit. The mortality data are tracked with the help of Office of National Statistics using the linked National Health Service number for patients in England and Wales. As all data collected as part of the BCIS database is managed by the NICOR registry as part of the national audit initiative and is anonymised for purposes of research, hence, a formal local ethical approval is not needed.

**Provenance and peer review** Not commissioned; externally peer reviewed.

**Data availability statement** All data relevant to the study are included in the article. Original dataset is available on reasonable request.

**Open access** This is an open access article distributed in accordance with the Creative Commons Attribution 4.0 Unported (CC BY 4.0) license, which permits others to copy, redistribute, remix, transform and build upon this work for any purpose, provided the original work is properly cited, a link to the licence is given, and indication of whether changes were made. See: <https://creativecommons.org/licenses/by/4.0/>.

#### ORCID iDs

Muhammad Jawad-Ul-Qamar <http://orcid.org/0000-0001-6336-0327>

Harish Sharma <http://orcid.org/0000-0002-0525-3520>

Vincenzo Vetrugno <http://orcid.org/0000-0002-1765-8146>

Peter F Ludman <http://orcid.org/0000-0002-7237-0946>

Sohail Q Khan <http://orcid.org/0000-0001-9951-4885>

#### REFERENCES

- Mintz GS, Popma JJ, Pichard AD, *et al*. Patterns of calcification in coronary artery disease. A statistical analysis of intravascular

- ultrasound and coronary angiography in 1155 lesions. *Circulation* 1995;91:1959–65.
- Oraevsky AA, Jacques SL, Pettit GH, *et al*. XeCl laser ablation of atherosclerotic aorta: optical properties and energy pathways. *Lasers Surg Med* 1992;12:585–97.
- Rawlins J, Din JN, Talwar S, *et al*. Coronary intervention with the excimer laser: review of the technology and outcome data. *Interv Cardiol* 2016;11:27–32.
- Fernandez JP, Hobson AR, McKenzie D, *et al*. Beyond the balloon: excimer coronary laser atherectomy used alone or in combination with rotational atherectomy in the treatment of chronic total occlusions, non-crossable and non-expandable coronary lesions. *EuroIntervention* 2013;9:243–50.
- Lee G, Ikeda RM, Kozina J, *et al*. Laser-dissolution of coronary atherosclerotic obstruction. *Am Heart J* 1981;102:1074–5.
- Baumbach A, Bittl JA, Fleck E, *et al*. Acute complications of excimer laser coronary angioplasty: a detailed analysis of multicenter results. *J Am Coll Cardiol* 1994;23:1305–13.
- Bittl JA, Chew DP, Topol EJ, *et al*. Meta-analysis of randomized trials of percutaneous transluminal coronary angioplasty versus atherectomy, cutting balloon atherotomy, or laser angioplasty. *J Am Coll Cardiol* 2004;43:936–42.
- Litvack F, Eigler N, Margolis J, *et al*. Percutaneous excimer laser coronary angioplasty: results in the first consecutive 3,000 patients. The ELCA Investigators. *J Am Coll Cardiol* 1994;23:323–9.
- Topaz O, Ebersole D, Das T, *et al*. Excimer laser angioplasty in acute myocardial infarction (the CARMEL multicenter trial). *Am J Cardiol* 2004;93:694–701.
- Giugliano GR, Falcone MW, Mego D, *et al*. A prospective multicenter registry of laser therapy for degenerated saphenous vein graft stenosis: the COronary graft Results following Atherectomy with Laser (CORAL) trial. *Cardiovasc Revasc Med* 2012;13:84–9.
- Giri S, Ito S, Lansky AJ, *et al*. Clinical and angiographic outcome in the laser angioplasty for restenotic stents (LARS) multicenter registry. *Catheter Cardiovasc Interv* 2001;52:24–34.
- Mehran R, Dangas G, Mintz GS, *et al*. Treatment of in-stent restenosis with excimer laser coronary angioplasty versus rotational atherectomy: comparative mechanisms and results. *Circulation* 2000;101:2484–9.
- Mehran R, Mintz GS, Satler LF, *et al*. Treatment of in-stent restenosis with excimer laser coronary angioplasty: mechanisms and results compared with PTCA alone. *Circulation* 1997;96:2183–9.
- Badr S, Ben-Dor I, Dvir D, *et al*. The state of the excimer laser for coronary intervention in the drug-eluting stent era. *Cardiovasc Revasc Med* 2013;14:93–8.