

# Effect of three-dimensional reconstruction-assisted 23G micro-invasive vitrectomy in patients with proliferative diabetic retinopathy

MIN FU, XIAOHE LU, HUIJUN HU, SONGFU FENG, WEI WU, XIAOYUN KE, XIAOPING XU,  
XIAOHONG CHEN and HUIQIAO HAI

Department of Ophthalmology, Zhujiang Hospital of Southern Medical University, Guangzhou, Guangdong 510280, P.R. China

Received May 10, 2016; Accepted February 17, 2017

DOI: 10.3892/etm.2017.4339

**Abstract.** In the present study, we investigated the effect of optical coherence tomography (OCT) three-dimensional reconstruction-assisted 23G micro-invasive vitrectomy (abbreviated to '23G') in patients with proliferative diabetic retinopathy (PDR). A total of 66 PDR patients (66 eyes) were continuously selected and randomly divided into the control and observation groups with 33 patients in each group. Patients in the control group were treated with routine OCT examination while the patients in the observation group were treated with OCT three-dimensional retinal reconstruction. The 23G surgical method was applied to the two groups, and a comparison was made on the clinical effects in the two groups. The follow-up visits lasted for approximately 6 months, and it was found that the operative time, occurrence rate of intraoperative complications and postoperative complications as shown in the observation group were significantly less than those in the control group ( $P < 0.05$ ). The best corrected visual acuity (BCVA) was improved, the intraocular pressure was increased and retinal thickness was decreased after the treatment. The BCVA of patients in the observation group was significantly greater than that of patients in the control group while the intraocular pressure and retinal thickness of patients in the observation group were significantly less than those of patients in the control group ( $P < 0.05$ ). In conclusion, the effect of 23G surgical method in PDR patients can be improved and corresponding complications can be reduced under the assistance of OCT three-dimensional reconstruction.

## Introduction

Diabetic retinopathy (DR) is a common diabetic complication and leading cause of blindness (1). When DR progresses to proliferative DR (PDR), some complications occur including recurrent vitreous hemorrhage, epimacular membrane hyperplasia, fractional detachment of retina, thus any patients with PDR need to be treated with vitreous retinal surgery (2).

From 20G micro-invasive vitrectomy to the present 27G micro-invasive vitrectomy, the application of 27G micro-invasive vitrectomy in the clinic is characteristic of less trauma and greater effects (3). When compared with 25G instruments, 23G transconjunctival sutureless surgery is characteristic of better rigidity, flexible operation and high cutting efficiency (4). When compared with 20G micro-invasive vitrectomy, 23G transconjunctival sutureless surgery is characteristic of less trauma and wider application space (5). The optical coherence tomography (OCT) is an important means to detect fundus oculi disease and can conduct harmless bio-assay on human body, thus acquiring the high resolution section image of the microstructure inside the organization and playing an important role in guiding the operation (6). However, the disadvantage of two-dimensional image sequence is that the physicians fail to identify the relationship between the former sequence and latter sequence visually. By contrast, three-dimensional OCT can indicate the features of fundus retinopathy in a more detailed manner in order to guide the scope of surgery and evaluate the effect of surgery (7). In comparison to the mature three-dimensional fundus ultrasound image reconstruction, three-dimensional OCT possesses the quantitative evaluation on harmless an high-quality images, thus decreasing the anthropogenic bias (8). To the best of our knowledge, there are few studies on the application of 23G surgery method in PDR patients under the guidance of three-dimensional OCT.

In the present study, we investigated the effect of OCT three-dimensional reconstruction-assisted 23G in patients with PDR. It was found that the effect of 23G surgical method in PDR patients can be improved and corresponding complications can be reduced under the assistance of OCT three-dimensional reconstruction.

---

*Correspondence to:* Dr Min Fu, Department of Ophthalmology, Zhujiang Hospital of Southern Medical University, 253 Industrial Road, Guangzhou, Guangdong 510280, P.R. China  
E-mail: fumin@vip.sina.com.cn; min\_fu1212@163.com

*Key words:* optical coherence tomography, three-dimensional reconstruction, proliferative diabetic retinopathy, 23G micro-invasive vitrectomy

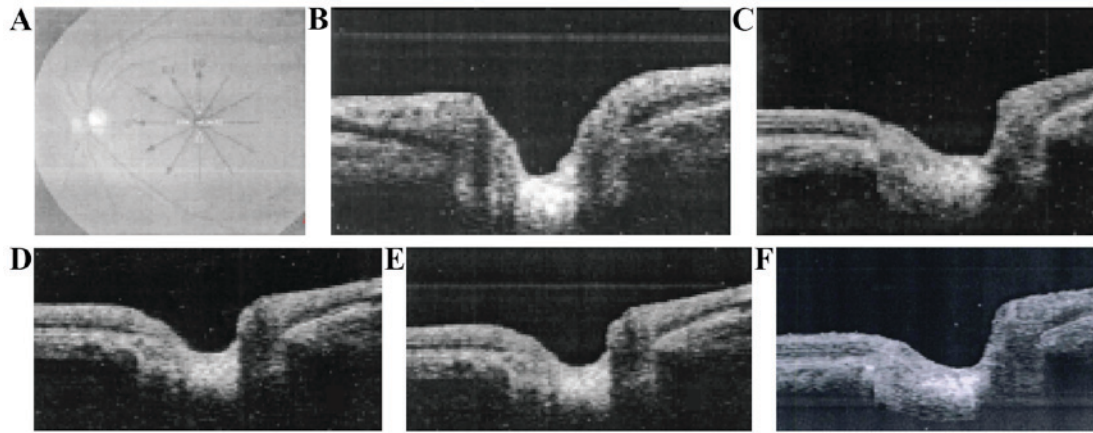


Figure 1. Optical coherence tomography (OCT) three-dimensional reconstruction procedures. (A) Macular radioactive scanning; (B) graph after segmentation; (C) registration reference diagram; (D) pre-registration graph; (E) registration results; and (F) graph acquired by the scanning line of 23°.

## Patients and methods

**Patient information.** Sixty-six patients admitted to the Zhujiang Hospital of Southern Medical University (Guangdong, China), who were diagnosed with PDR from January 2014 to June 2015, were continuously selected. Blood glucose was maintained at the level of 9 mmol/l and blood pressure  $\leq 140/90$  mmHg, and the patients had surgical indications but no obvious surgical contraindications. The exclusion criteria included any patients with corneal refractive surgery history, vitreous retinal surgery history and ocular trauma history; patients with other eye diseases, for instance, uveitis; patients who did not tolerate operation due to poor general conditions; as well as patients with poor compliance or incomplete clinical data.

Informed consent was obtained from the Ethics Committee of the Zhujiang Hospital of Southern Medical University as well as the patients and their family members. According to the order of admission, the patients were divided into the control and observation groups at random according to the random number table, with 33 patients in each group. There were 19 male and 14 female patients in the control group. The age range was 56-73 years, with  $64.8 \pm 10.5$  years as an average age. There were 15 patients of stage IV, 13 patients of stage V and 5 patients of stage VI. According to the Gregorian scale CS of marks of 3-6, the average score was  $4.8 \pm 1.2$ . There were 18 male and 15 female patients in the observation group, and the age range was 55-72 years with  $65.3 \pm 11.4$  years as average age. There were 14 patients of stage IV, 15 patients of stage V and 4 patients of stage VI. According to the CS of marks of 3-6, the average score was  $4.9 \pm 1.3$ . According to the scoring comparison on gender, age, PDR staging and severity of patients between the two groups, the difference was not statistically significant ( $P > 0.05$ ).

**Therapeutic method.** The patients in the control group were treated with routine OCT examination and the patients in the observation group were treated with OCT three-dimensional retinal reconstruction, and the 23G surgical method was used to treat the patients in the two groups. As for the routine OCT examination, the preoperative examination and operation preparations were not completed. The 23G micro-invasive vitrectomy system was produced by Alcon Laboratories,

Inc. (Fort Worth, TX, USA). It comprised these instruments: Constellation all-in-one vitrectomy phaco machine, TSV 23G high-speed vitreous tip, TSV 23G trocar cannula kit, TSV 23G light guiding fibres and corresponding instruments (intraocular forceps and flute needle). As for OCT examination, and the Cirrus™ FD-OCT produced by Carl Zeiss, Inc. (Oberkochen, Germany).

**Main surgery procedures of 23G.** The drapes were disinfected routinely, and 2% of lidocaine + 0.75% of bupivacaine injection was used to carry out retrobulbar block and peribulbar infiltration for the anesthesia of operative eyes with 2 ml in each medicine. The eye speculum was used to open the eyelid, and the tractive conjunctiva was used to dislocate the conjunctival and scleral incisions. The 23G paracentesis knife (with cannula) was used to puncture the three-channel operation area of standard vitrectomy which was 3.5 mm away from the back of corneal limbal. The paracentesis knife was kept 10° away from the scleral tangent in order that the conjunctiva on the surface of sclera can migrate in a misplaced manner, and tunnel-type puncture sclera can enter the eyeball and the vitreous cavity perpendicular to the eyeball after entering the scleral incision. The physicians established an infusion tube below the temple and used the surgical instruments to enter and moved out of the body from two incisions above the nose and temple. Additionally, the physicians conducted entire vitreous body cutting during the operation to coordinate with the external scleral top pressure. According to the patients' condition, the physicians used heavy water to flatten the retina, to peel the internal limiting membrane, to exchange the laser and gas liquid and use perfluoropropane gas (C<sub>3</sub>F<sub>8</sub>) for padding. Subsequently, microscope forceps were used to clip the incision after pulling the cannula out at the end of operation, and then an opposor or cotton bud was used to massage the incision repeatedly. The physicians can judge whether there is leakage in the scleral incision or not by observing whether there is bubble under the sclera. If the incision still failed to be completely sutured through repeated massage on incision, 8-0 patients had their scleral incision and conjunctival incision sutured by suture lines, and the patients were in prone position after the operation.



Table II. Comparison of the BCVA, intraocular pressure and retinal thickness in macular area.

| Groups         | BCVA          |                              | Intraocular pressure (mmHg) |                              | Retinal thickness ( $\mu\text{m}$ ) |                              |
|----------------|---------------|------------------------------|-----------------------------|------------------------------|-------------------------------------|------------------------------|
|                | Preoperation  | 6 months after the operation | Preoperation                | 6 months after the operation | Preoperation                        | 6 months after the operation |
| Control        | 2.6 $\pm$ 1.2 | 3.8 $\pm$ 1.4                | 13.8 $\pm$ 2.9              | 18.2 $\pm$ 3.3               | 182.4 $\pm$ 15.6                    | 173.2 $\pm$ 13.4             |
| Observation    | 2.7 $\pm$ 1.3 | 4.9 $\pm$ 1.6                | 13.9 $\pm$ 2.7              | 16.5 $\pm$ 3.2               | 185.2 $\pm$ 16.4                    | 156.5 $\pm$ 12.7             |
| t ( $\chi^2$ ) | 0.326         | 5.524                        | 0.632                       | 5.954                        | 0.765                               | 6.457                        |
| P-value        | 0.421         | 0.036                        | 0.728                       | 0.031                        | 0.829                               | 0.023                        |

BCVA, best corrected visual acuity.

*Comparison of the BCVA, intraocular pressure and retinal thickness in macular area.* According to the comparison on the BCVA, intraocular pressure and retinal thickness in macular area as shown in the two groups before the treatment was not statistically different ( $P>0.05$ ). The BCVA in the two groups was improved following treatment, and the intraocular pressure increased as the retinal thickness decreased, and the BCVA as observed in the observation group was improved as compared to that in the control group. Additionally, the intraocular pressure and retinal thickness as observed in the observation group were significantly less than those as observed in the control group ( $P<0.05$ ) (Table II).

## Discussion

In consideration of the features of OCT optic disk image, some physicians utilized the edge extraction algorithm to effectively extract the edges on the upper surface of the optic disk, to attain the goals of automatic and correct segmentation of image sequences (9). The radioactive scanning was conducted by taking the concave center of optic disk as the center to acquire the images, and the physicians first made the concave center of image sequence aligned and then conduct rigid registration on images by combining the method of curve fitting on upper boundary of images (10). In order to establish a three-dimensional form model of optic disk and to polish the surface of the said model, the physicians first adopted cubic spline interpolation algorithm to conduct slice interpolation among various neighboring images, and then employed the Bresenham-based linear interpolation algorithm to conduct inter-site interpolation among images after transforming the images to the cylindrical coordinate system. Finally, a three-dimensional form model of fundus optic disk was established based on the above-mentioned data points to segment and extract the images at any angle by taking the concave center of optic disk as the center (11). The main task for three-dimensional reconstruction was to realize three-dimensional visualization display, operation and analysis so as to provide medical image data for the diagnosis and treatment of diseases (12). In the present study, an increasing number of three-dimensional images were applied in the plastic, artificial limb surgery, virtual surgery and dissection education. Additionally, three-dimensional images are necessary as more precise requirements for ophthalmic fundus surgery are identified.

New blood vessels of PDR gradually grow from the inside of retina to its surface, and if they adhere to the posterior vitreous cortex, vitreous hemorrhage and retinal detachment can occur. After the surgical resection of the vitreum, the course of disease can be blocked, and may be used to effectively treat macular shift and edema caused by progressive fiber proliferation and posterior fiber proliferation membrane pulling. Intraocular hypertension is relatively common after operation due to the chamber angle, postoperative filling materials and operative inflammatory stimulation. Vitreous haemorrhagia 1 day after the operation may be associated with incomplete cleaning of hematocoele during the operation and bleeding leakage during suture of scleral incision; while hemorrhage is more common 1 week to 1 month after the operation, which may be related to incomplete membrane stripping during the operation, dispersion of blood into visual axis area and chronic bleeding of new bleeding vessels on the retina (13).

The surgical incision left by 23G surgery was 0.72 mm, and the surgical instruments, which were of good rigidity, moved the eyeball during the operation, operated flexibly and had a higher cutting efficiency than 25G surgery. Thus, the physicians were not required to cut bulbar conjunctiva apart during the surgery, and the sclerotomy sites can close by themselves without need of suture lines. The physicians may place the temporary micro-cannula during the surgery to reduce the injuries caused by the repeated run-ins of surgical instruments to the vitreous base and retinal ora serrata area, thus avoiding the vitreous incarceration in the incision position, proliferator endogeny and other complications to a large extent (14). As both the infusion tube and corneal contact lens do not have to be fixed by suture lines, the impact of suture lines stimulation on the ocular surface and corneal curvature is reduced (15). The early 23G incision of 25-30° is transformed to the biplanar tunnel of 90°, and the present 23G vitrectomy adopts biplanar tunnel incision of 10-15° or 5°/30°, and the improvement of surgical incision avoids a series of complications resulting from postoperative wound leakage to a large extent (16). With the continuous improvement of cutting system-related surgical instruments, 23G surgery was applied in a wider scope, including soft cataract, lens luxation in anterior chamber, vitreous hemorrhage, intraocular foreign body, endophthalmitis, retinal detachment and other diseases (17). 23G surgery is the hotspot of research carried out in the field of ophthalmology at present, and the rate for the application of 23G surgery in ocular posterior segment eye disease as

adopted by part of hospitals both at home and abroad is as close as 100% (18).

We concluded that the operative time and occurrence rate of intraoperative and postoperative complications as shown in observation group were significantly less than those as shown in control group. The BCVA of patients in the observation group after the treatment was greater than that of patients in control group, and the intraocular pressure and retinal thickness of patients in observation group were significantly less than those of patients in control group. In conclusion, the effect of 23G surgical method in PDR patients can be improved and corresponding complications can be reduced under the assistance of OCT three-dimensional reconstruction.

## References

- Gardner TW and Chew EY: Future opportunities in diabetic retinopathy research. *Curr Opin Endocrinol Diabetes Obes* 23: 91-96, 2016.
- Sassa Y, Yoshida S, Ishikawa K, Asato R, Ishibashi T and Kono T: The kinetics of VEGF and MCP-1 in the second vitrectomy cases with proliferative diabetic retinopathy. *Eye (Lond)* 30: 746-753, 2016.
- Sano M, Inoue M, Itoh Y, Hirota K, Koto T and Hirakata A: Efficacy of higher cutting rates during microincision vitrectomy for proliferative diabetic retinopathy. *Eur J Ophthalmol*: Dec 17, 2015 (Epub ahead of print).
- Wang ZY, Zhao KK, Li JK, Rossmiller B and Zhao PQ: Four-port bimanual 23-gauge vitrectomy for diabetic tractional retinal detachment. *Acta Ophthalmol*: Feb 8, 2016 (Epub ahead of print).
- Browning DJ: Vitrectomy for proliferative diabetic retinopathy: does anyone know the complication rate? *JAMA Ophthalmol* 134: 86-87, 2016.
- Park YG and Roh YJ: New diagnostic and therapeutic approaches for preventing the progression of diabetic retinopathy. *J Diabetes Res* 2016: 1753584, 2016.
- Zhang M, Wang J, Pechauer AD, Hwang TS, Gao SS, Liu L, Liu L, Bailey ST, Wilson DJ, Huang D, *et al*: Advanced image processing for optical coherence tomographic angiography of macular diseases. *Biomed Opt Express* 6: 4661-4675, 2015.
- Nakao F: Instant stent-scentuated 3-dimensional optical coherence tomography of struts pulled up by pulling stuck wire and folded by kissing balloon dilation. *JACC Cardiovasc Interv* 8: e125-e126, 2015.
- Chen H, Chen X, Qiu Z, Xiang D, Chen W, Shi F, Zheng J, Zhu W and Sonka M: Quantitative analysis of retinal layers' optical intensities on 3D optical coherence tomography for central retinal artery occlusion. *Sci Rep* 5: 9269, 2015.
- Aoki T, Rodriguez-Porcel M, Matsuo Y, Cassar A, Kwon TG, Franchi F, Gulati R, Kushwaha SS, Lennon RJ, Lerman LO, *et al*: Evaluation of coronary adventitial vasa vasorum using 3D optical coherence tomography - animal and human studies. *Atherosclerosis* 239: 203-208, 2015.
- Su R, Ekberg P, Leitner M and Mattsson L: Accurate and automated image segmentation of 3D optical coherence tomography data suffering from low signal-to-noise levels. *J Opt Soc Am A Opt Image Sci Vis* 31: 2551-2560, 2014.
- Yang PS, Ha J, Kim JS, Park S, Bae J, Shin DH, Kim BK, Ko YG, Choi D, Jang Y, *et al*: Eccentric morphology of jailed side-branch ostium after stent crossover in coronary bifurcation lesions: a three-dimensional optical coherence tomographic analysis. *J Cardiol* 65: 3015-310, 2015.
- Fang L, Li S, Kang X, Izatt JA and Farsiu S: 3-D adaptive sparsity based image compression with applications to optical coherence tomography. *IEEE Trans Med Imaging* 34: 1306-1320, 2015.
- Eckardt C: Transconjunctival sutureless 23-gauge vitrectomy. *Retina* 25: 208-211, 2005.
- Yokota R, Inoue M, Itoh Y, Rii T, Hirota K and Hirakata A: Comparison of microincision vitrectomy and conventional 20-gauge vitrectomy for severe proliferative diabetic retinopathy. *Jpn J Ophthalmol* 59: 288-294, 2015.
- Grandinetti AA, Kniggenndorf V, Moreira LB, Moreira Junior CA and Moreira AT: A comparison study of corneal topographic changes following 20-, 23-, and 25-G pars plana vitrectomy. *Arq Bras Oftalmol* 78: 283-285, 2015.
- Shao Y, Dong LJ, Zhang Y, Liu H, Hu BJ, Liu JP and Li XR: Surgical induced astigmatism correlated with corneal pachymetry and intraocular pressure: transconjunctival sutureless 23-gauge versus 20-gauge sutured vitrectomy in diabetes mellitus. *Int J Ophthalmol* 8: 528-533, 2015.
- Toussaint BW, Appenzeller MF, Miller DM, Petersen MR, Foster RE, Osher RH, Snyder ME, Hunt CK, Sisk RA and Riemann CD: Stability of the acrylic toric intraocular lens in combined cataract surgery and transconjunctival sutureless vitrectomy. *Retina* 35: 1065-1071, 2015.