

Received: 2016.12.15  
Accepted: 2017.04.12  
Published: 2017.08.28

ISSN 1941-5923  
© Am J Case Rep, 2017; 18: 931-936  
DOI: 10.12659/AJCR.902860

# Stress Induced Cardiomyopathy Triggered by Acute Myocardial Infarction: A Case Series Challenging the Mayo Clinic Definition

Authors' Contribution:  
Study Design A  
Data Collection B  
Statistical Analysis C  
Data Interpretation D  
Manuscript Preparation E  
Literature Search F  
Funds Collection G

ABDEF 1 **Georgios Christodoulidis**  
BDE 2 **Vishwa Kundoor**  
ADE 1 **Edo Kaluski**

1 Department of Cardiology, The Guthrie Clinic/Robert Packer Hospital, Sayre, PA, U.S.A.  
2 Department of Internal Medicine, The Guthrie Clinic/Robert Packer Hospital, Sayre, PA, U.S.A.

**Corresponding Author:** Georgios Christodoulidis, e-mail: [Christodoulidis\\_georgios@guthrie.org](mailto:Christodoulidis_georgios@guthrie.org)  
**Conflict of interest:** None declared

## Case series

**Patient:** Male, 56 • Female, 70 • Female, 55 • Female, 55  
**Final Diagnosis:** Stress induced cardiomyopathy  
**Symptoms:** Chest pain • shortness of breath  
**Medication:** —  
**Clinical Procedure:** Cardiac catheterization  
**Specialty:** Cardiology

**Objective:** Unusual clinical course

**Background:** Various physical and emotional factors have been previously described as triggers for stress induced cardiomyopathy. However, acute myocardial infarction as a trigger has never been reported.

**Case Report:** We describe four patients who presented with an acute myocardial infarction, in whom the initial echocardiography revealed wall motion abnormalities extending beyond the coronary distribution of the infarct artery. Of the four patients identified, the mean age was 59 years; three patients were women and two patients had underlying psychiatric history. Electrocardiogram revealed ST elevation in the anterior leads in three patients; QTc was prolonged in all cases. All patients had ≤ moderately elevated troponin. Single culprit lesion was found uniformly in the proximal or mid left anterior descending artery. Initial echocardiography revealed severely reduced ejection fraction with relative sparing of the basal segments, whereas early repeat echocardiography revealed significant improvement in the left ventricular function in all patients.

**Conclusions:** This is the first case series demonstrating that acute myocardial infarction can trigger stress induced cardiomyopathy. Extensive reversible wall motion abnormalities, beyond the ones expected from angiography, accompanied by modest elevation in troponin and marked QTc prolongation, suggest superimposed stress induced cardiomyopathy.

**MeSH Keywords:** Heart Failure, Systolic • Myocardial Infarction • Takotsubo Cardiomyopathy

**Full-text PDF:** <https://www.amjcaserep.com/abstract/index/idArt/902860>

 1730

 2

 2

 14



## Background

Stress induced cardiomyopathy (SIC) is a form of acute heart failure that commonly presents with signs and symptoms that mimic acute coronary syndrome [1]. It usually presents in elderly females after an emotional or physical trigger, although cases have been reported with no obvious trigger [2]. The classic echocardiographic appearance is apical to mid segment hypokinesia/akinesia with hyper contractile basal segments; however, more recently, other variations have been described [3,4]. Typically, wall motion abnormalities (WMAs) are transient with subsequent resolution of the left ventricular (LV) function within weeks [3].

The most widely accepted criteria for diagnosing SIC is the Mayo Clinic criteria that consist of the following parameters (all should be present): (a) transient WMA that extends beyond a single vessel distribution; (b) absence of obstructive coronary artery disease (CAD) or angiographic evidence of acute plaque rupture; (c) electrocardiographic changes or mild elevation in cardiac troponin; and (d) absence of pheochromocytoma or myocarditis. Stressful event is often but not always present [2]. Although these criteria are the most commonly used for diagnosing SIC, subsequent reports have challenged them, especially with regards to the mandatory absence of obstructive CAD [5–7]. Adding to the controversy, we present the first case series of patients presenting with acute myocardial infarction (AMI) triggering SIC.

## Case Report

We report on four patients who presented with an AMI, in whom the initial echocardiography revealed WMA extending beyond the coronary distribution of the infarct artery, consistent with the classic form of SIC. The mean age of these four patients was 59 years; three patients were women and two patients had underlying psychiatric history. Electrocardiography (ECG) revealed ST elevation in the anterior leads in three patients and QTc was prolonged in all cases. Of note, none of the patients was on any QT prolonging medications. All patients had only ≤ moderately elevated troponin. The single culprit lesion was in the proximal to mid left anterior descending artery (LAD) in all cases. Early repeat echocardiography revealed significant improvement in the left ventricular (LV) function in all patients (Table 1). Overall, our patients' characteristics correspond to the Mayo Clinic criteria for diagnosing SIC with the exception of the mandatory absence of acute plaque rupture (Table 2).

### Case 1

A 56-year-old male with no significant past medical history (PMH) was admitted with sudden onset chest pain radiating to his left arm. On arrival to the emergency department the patient had ventricular fibrillation which was successfully managed by electrical defibrillation. His ECG revealed ST elevations in the anterior leads. Emergent cardiac catheterization revealed 98% thrombotic occlusion of the mid LAD that was successfully treated with a bare metal stent. There was no other obstructive CAD (Figure 1A, 1B). The patient was admitted to the intensive care unit in stable condition and chest pain free. Initial

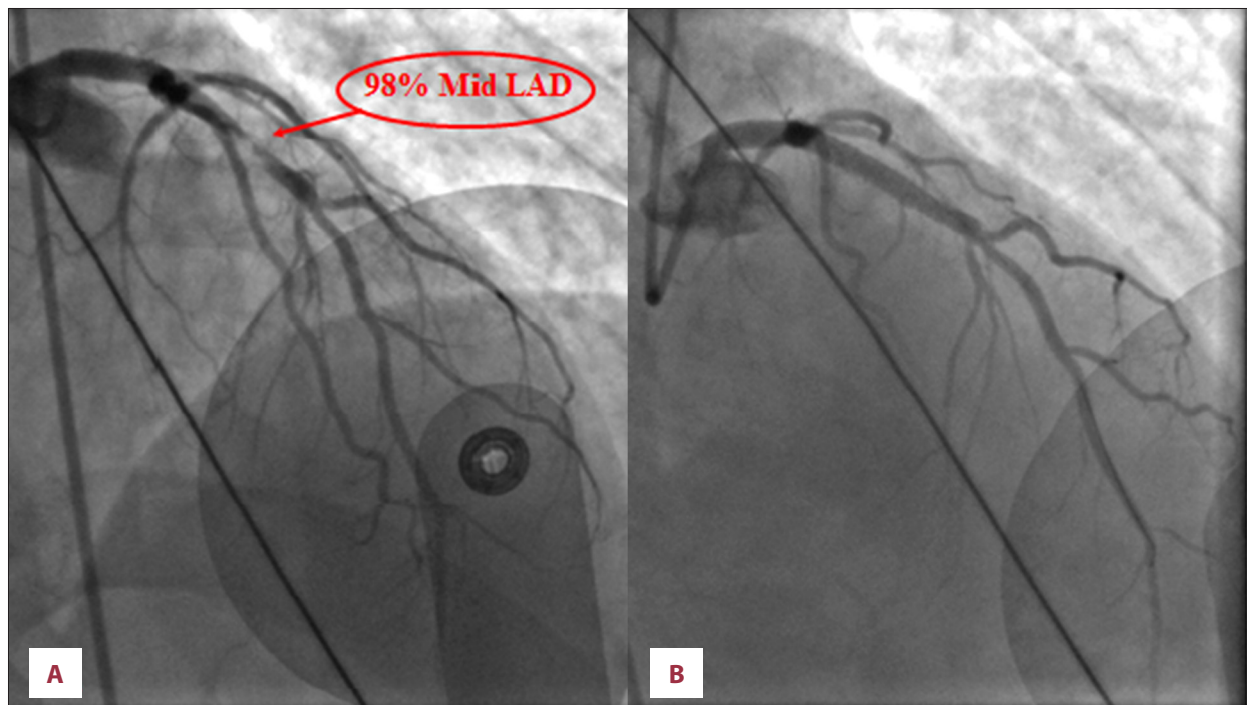
**Table 1.** Clinical characteristics of patients with AMI complicated by SIC.

	Patient 1	Patient 2	Patient 3	Patient 4
Age (years)	56	70	55	55
Gender	Male	Female	Female	Female
Psychiatric history	None	None	Depression, generalized anxiety disorder	Domestic abuse
QTc on ECG	561 ms*	525 ms	525 ms	609 ms
Peak troponin	29.8 ng/mL	3.67 ng/mL	6.48 ng/mL	15.6 ng/mL
Culprit lesion	Mid LAD**	Mid LAD	Proximal LAD	Mid LAD
Initial echocardiogram	LVEF*** 25% Global hypokinesia	Severe reduction in LVEF Hypokinesia of all apical segments	LVEF 35–40%. Akinesia of mid anterior, mid antero-septal, mid infero-septal and all apical segments	LVEF 25–30% akinesia in all segments except basal inferior and anterior
Follow-up echocardiogram	Normalization of the LVEF	LVEF of 45–50%, Improvement in WMA	LVEF of 50% Improvement in WMA	LVEF 50–55% Improvement in WMA

\* Ms – millisecond; \*\* LAD – left anterior descending, \*\*\* LVEF – left ventricular ejection fraction.

**Table 2.** Comparison of Mayo Clinic criteria and case series patients' characteristics.

Mayo Clinic Criteria	Case series patients' characteristics
Transient wall motion abnormalities of mid ventricular segments with or without apical involvement	Present in all patients
Wall motion abnormalities extend beyond a single vessel distribution	Present in all patients
Presence of stressful trigger	Present in all patients; we propose that the myocardial infarction is the stressful trigger
Electrocardiographic changes or mild elevation in cardiac troponin levels	Present in all patients
Absence of pheochromocytoma or myocarditis	No evidence pheochromocytoma or myocarditis in any of the patients
Absence of angiographic evidence of acute plaque rupture or obstructive coronary disease	All patient had acute plaque rupture involving the left anterior descending artery; we propose that this may be the actual stressful trigger



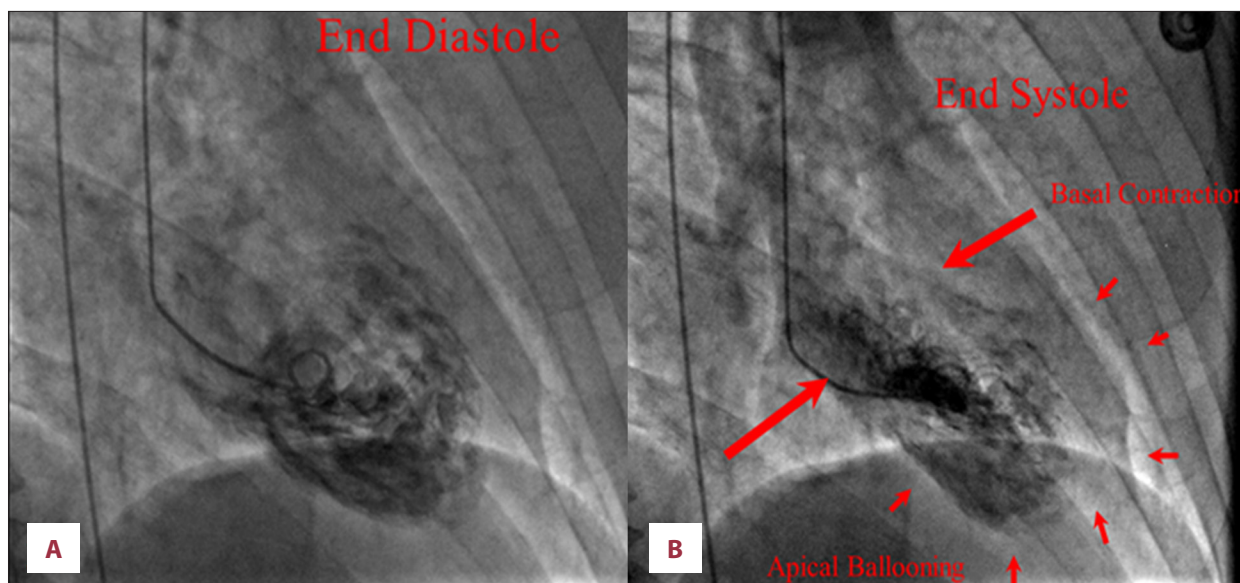
**Figure 1.** (A) Cardiac catheterization revealed 98% thrombotic occlusion of the left anterior descending artery. (B) Lesion was successfully treated with a bare metal stent.

transthoracic echocardiography (TTE) showed left ventricular ejection fraction (LVEF) of 45% with apical hypokinesia. On the second day of admission, the patient became hypotensive. His ECG revealed diffuse T-wave inversions and QTc prolongation (561 ms). A follow-up TTE showed global LV-dysfunction with LVEF of 25%. Repeat coronary angiography showed patent stent to the LAD. The LV gram was consistent with SIC (Figure 2A, 2B).

### Case 2

A 70-year-old female with no significant PMH presented with sudden onset chest pressure occurring at rest with associated

dyspnea. Her initial ECG revealed antero-lateral ST segment elevations. Emergency cardiac angiography showed 99% stenosis in the mid LAD (culprit lesion) and 90% stenosis in the proximal portion of the obtuse marginal branch. Both lesions were successfully treated with drug eluting stents. Post-procedure, the patient was pain free and was transferred to the telemetry unit for observation. Her troponin level was mildly elevated at 2.2 ng/mL. Overnight she developed repeat episodes of chest pain with associated nausea. Repeat ECG revealed diffuse T-wave inversions with prolonged QTc interval of 484 ms. Bedside TTE revealed akinesia of all apical segments with sparing of the basal segments and severely reduced ejection



**Figure 2.** (A) Left ventriculogram in end diastole. (B) Left ventriculogram in end systole revealing mid to apical hypokinesis.

fraction. Follow-up ECG the next day revealed diffuse T-wave inversions with further prolongation of QTc interval to 525 ms. Subsequent TTE three days later revealed that her LVEF had improved to 45–50%.

### Case 3

A 55-year-old female with PMH of depression and generalized anxiety disorder was admitted with complaints of intermittent episodes of chest pressure radiating to the left shoulder for one day. Her initial ECG did not show any acute ischemic changes. Laboratory data was remarkable for an NT-pro BNP of 6,730 pg/mL and troponin of 6.3 ng/mL. TTE revealed akinesia of mid anterior, mid antero-septal, mid infero-septal and all apical segments with LVEF of 35–40%. Coronary angiography revealed 98% stenosis in the proximal LAD that was treated with drug eluting stent. There was no other obstructive CAD. Her procedure was uneventful; however, 30 minutes later she complained of nausea and became hypotensive requiring fluids and inotropes. Her emergent repeat TTE was unchanged from her prior TTE. Serial ECGs did not reveal any ischemic changes but were notable for marked prolongation of QT interval >500 ms. Prior to discharge, TTE was repeated showing significant improvement of the LVEF to 50%. QT interval normalized within the next week.

### Case 4

A 55-year-old female with a 30 pack per year smoking history and history of domestic abuse was admitted with an episode of acute onset precordial chest pain radiating to the left arm and neck for six hours. ECG revealed significant ST elevation in leads V2-V5 and initial troponin was 0.532 ng/mL.

Subsequent coronary angiography revealed complete occlusion of mid LAD treated successfully with a drug eluting stent. Angiography was also remarkable for 50% stenosis of the proximal right coronary artery and 50% stenosis of the proximal left circumflex (which were not intervened). Her TTE was significant for severely reduced LVEF of 25–30% with akinesia in all segments except for the basal inferior and basal anterior. This case was also suspicious for LV thrombus and the patient was hence placed on warfarin. Subsequent ECGs were remarkable for markedly prolonged QT interval of 609 ms. Repeated TTE one month later revealed improvement in systolic function to an LVEF of 50–55%.

## Discussion

To our knowledge this is the first case series reporting SIC triggered by AMI. This condition should be considered when initial TTE reveals WMA extending beyond what is expected from angiography. Dramatic improvement of LV function in subsequent TTE in conjunction with only mild elevation in troponin and marked QTc prolongation on ECG confirm the presence of SIC.

The baseline characteristics of our patients (three out of four patients were women and two patients had underlying psychiatric history) are in concordance with the ones reported by the International Takotsubo Registry [3]. While AMI as a physical trigger was been described by the registry (the presence of CAD was actually an exclusion criteria), physical triggers were actually the most frequent precipitating factor [3]. Laboratory evaluation revealed only mild troponin elevation and ECG showed prolonged QTc in all of our patients; which was consistent with prior reports [2,3,8]. The initial TTEs in

our patients were consistent with the classic (and most common) form of SIC, the apical type [3]. Finally, the severely reduced LVEF noted in all of our patients with subsequent dramatic improvement favors the diagnosis of SIC, as previously described [3,9].

The mandatory absence of CAD for diagnosing SIC is a subject of controversy. While the Mayo Clinic criteria state that the presence of CAD or angiographic evidence of acute plaque rupture effectively excludes the diagnosis of SIC [2], subsequent reports have challenged this criterion [5–7]. Gaibazzi et al. reported a case series of seven patients with SIC (out of a cohort of 20 confirmed cases of SIC at their center) with concomitant obstructive CAD [6]. All patients in that series met all the other criteria for SIC (other than obstructive CAD) and cardiac magnetic resonance imaging (MRI) did not show myocardial late gadolinium enhancement that would be expected if myocardial infarction or myocarditis were present [6,10]. Adding to that, the Takotsubo Italian Network Registry, which included 450 patients with SIC from 26 centers, reported a prevalence of obstructive CAD of 9.6% (43 patients) [7]. While our case series agrees with the aforementioned reports with regards to the presence of CAD in SIC, these reports refer to stable obstructive CAD coincidentally found in patient with SIC, whereas our report refers to an AMI as the actual physical trigger for SIC.

The differential diagnosis may include stunned or hibernating myocardium. However, stunned myocardium tends to peak immediately after an AMI and not hours afterwards and typically affects the function of the previously ischemic myocardium [11]. The WMA observed in our patients extended beyond the ones expected from the culprit related artery and were more consistent with the classic WMA of SIC. Moreover, stunned myocardium is not associated with the typical modest QTc prolongation and mild enzyme rise noted in our patients.

## References:

1. Tsuchihashi K, Ueshima K, Uchida T et al: Transient left ventricular apical ballooning without coronary artery stenosis: A novel heart syndrome mimicking acute myocardial infarction. *Angina Pectoris-Myocardial Infarction Investigations in Japan. J Am Coll Cardiol*, 2001; 38(1): 11–18
2. Prasad A, Lerman A, Rihal CS: Apical ballooning syndrome (Tako-Tsubo or stress cardiomyopathy): A mimic of acute myocardial infarction. *Am Heart J*, 2008; 155(3): 408–17
3. Templin C, Ghadri JR, Diekmann J et al: Clinical features and outcomes of Takotsubo (stress) cardiomyopathy. *New Engl J Med*, 2015; 373(10): 929–38
4. Barbaryan A, Bailuc SL, Patel K et al: An emotional stress as a trigger for reverse Takotsubo cardiomyopathy: A case report and literature review. *Am J Case Rep*, 2016; 17: 137–42
5. Winchester DE, Ragosta M, Taylor AM: Concurrence of angiographic coronary artery disease in patients with apical ballooning syndrome (tako-tsubo cardiomyopathy). *Catheter Cardiovasc Interv*, 2008; 72(5): 612–16
6. Gaibazzi N, Ugo F, Vignali L et al: Tako-Tsubo cardiomyopathy with coronary artery stenosis: A case-series challenging the original definition. *Int J Cardiol*, 2009; 133(2): 205–12
7. Parodi G, Citro R, Bellandi B et al: Tako-tsubo cardiomyopathy and coronary artery disease: a possible association. *Coron Artery Dis*, 2013; 24(6): 527–33
8. Roshanzamir S, Showkathali R: Takotsubo cardiomyopathy a short review. *Curr Cardiol Rev*, 2013; 9(3): 191–96
9. Citro R, Rigo F, Ciampi Q et al: Echocardiographic assessment of regional left ventricular wall motion abnormalities in patients with tako-tsubo cardiomyopathy: Comparison with anterior myocardial infarction. *Eur J Echocardiogr*, 2011; 12(7): 542–49
10. Ricciardi MJ, Wu E, Davidson CJ et al: Visualization of discrete microinfarction after percutaneous coronary intervention associated with mild creatine kinase-MB elevation. *Circulation*, 2001; 103(23): 2780–83

The treatment of patients with SIC remains unclear. The American College of Cardiology recommends treating patients with SIC as any other patient with heart failure reduced ejection fraction by using beta blockers and angiotensin-converting enzyme inhibitor (ACEI) or angiotensin-receptor blocker (ARB) [12]. Retrospective analysis of outcomes from the International Takotsubo Registry suggested that the use of ACEI or ARB was indeed associated with improved one-year survival. However, the use of beta blockers did not have any additional survival benefit [3]. Patients with SIC triggered by AMI, like our patients, present a unique fraction of SIC patients where the use of beta blockers is unequivocally indicated (unless contraindicated) as a secondary prevention measure after an AMI [13], in addition to the use of ACEIs.

## Limitations

Cardiac MRI can be very helpful when trying to differentiate SIC from other types of cardiomyopathy [14] and would have been invaluable in our case study. Unfortunately, a cardiac MRI was not performed for our patients to confirm our hypothesis. However, even in the absence of cardiac MRI, we believe that the body of evidence seen in our patients strongly indicated the presence of SIC superimposed on AMI.

## Conclusion

AMI can trigger SIC. Extensive reversible wall motion abnormalities, beyond the ones expected from an angiography, accompanied by modest elevation in troponin and marked QTc prolongation suggests SIC superimposed on AMI. If this can be proven in further studies, especially with concomitant use of cardiac MRI, the criteria for SIC should be modified.

## Conflict of interest

None.

11. Braunwald E, Kloner RA: The stunned myocardium: Prolonged, postischemic ventricular dysfunction. *Circulation*, 1982; 66(6): 1146–49
12. Yancy CW, Jessup M, Bozkurt B et al: 2013 ACCF/AHA guideline for the management of heart failure: A report of the American College of Cardiology Foundation/American Heart Association Task Force on Practice Guidelines. *J Am Coll Cardiol*, 2013; 62(16): e147–239
13. O’Gara PT, Kushner FG, Ascheim DD et al: 2013 ACCF/AHA guideline for the management of ST-elevation myocardial infarction: A report of the American College of Cardiology Foundation/American Heart Association Task Force on Practice Guidelines. *J Am Coll Cardiol*, 2013; 61(4): e78–140
14. Eitel I, von Knobelsdorff-Brenkenhoff F, Bernhardt P et al: Clinical characteristics and cardiovascular magnetic resonance findings in stress (takotsubo) cardiomyopathy. *JAMA*, 2011; 306(3): 277–86