

Outpatient Treatment for Pneumothorax Using a Portable Small-Bore Chest Tube: A Clinical Report

Won Gi Woo, M.D., Seok Joo, M.D., Geun Dong Lee, M.D., Seok Jin Haam, M.D., Sungsoo Lee, M.D., Ph.D.

Background: For treatment of pneumothorax in Korea, many institutions hospitalize the patient after chest tube insertion. In this study, a portable small-bore chest tube (Thoracic Egg; Sumitomo Bakelite Co. Ltd., Tokyo, Japan) was used for pneumothorax management in an outpatient clinic. **Methods:** Between August 2014 and March 2015, 56 pneumothorax patients were treated using the Thoracic Egg. **Results:** After Thoracic Egg insertion, 44 patients (78.6%) were discharged from the emergency room for follow-up in the outpatient clinic, and 12 patients (21.4%) were hospitalized. The mean duration of Thoracic Egg chest tube placement was 4.8 days, and the success rate was 73%; 20% of patients showed incomplete expansion and underwent video-assisted thoracoscopic surgery. For primary spontaneous pneumothorax patients, the success rate of the Thoracic Egg was 76.6% and for iatrogenic pneumothorax, it was 100%. There were 2 complications using the Thoracic Egg. **Conclusion:** Outpatient treatment of pneumothorax using the Thoracic Egg could be a good treatment option for primary spontaneous and iatrogenic pneumothorax.

Key words: 1. Pneumothorax
2. Chest tubes
3. Outpatients

INTRODUCTION

Pneumothorax is categorized as primary (without any precipitating factor), secondary, iatrogenic, and traumatic. Usually, primary spontaneous pneumothorax (PSP) is caused by subpleural bleb rupture without underlying lung disease [1]. Secondary pneumothorax has underlying lung disease, such as chronic obstructive pulmonary disease, emphysema, asthma, and others, and iatrogenic pneumothorax is usually caused by needle puncture of the lung parenchyma during acupuncture, central line catheterization, etc. [1].

For treatment of pneumothorax, there is some controversy over PSP, but for recurrent pneumothorax, many institutions

usually recommend video-assisted thoracoscopic surgery (VATS) [2]. For PSP, British guidelines recommend needle aspiration first, as this may minimize hospitalization and reduce the cost to the patient [2]. According to the guidelines of the American College of Chest Physicians, clinically stable patients with a large pneumothorax should usually undergo drainage by a small-bore catheter (≤ 14 Fr) or a 16–22 Fr chest tube, and hospitalization is recommended [3]. The Japan Society for Pneumothorax and Cystic Lung Diseases Guidelines Committee describe many options, but There is not definite consensus on the treatment for PSP [4]. In this study, we focus on outpatient treatment for pneumothorax. We used a portable small-bore chest tube (9 Fr) and evaluated its efficacy.

Department of Thoracic and Cardiovascular Surgery, Gangnam Severance Hospital, Yonsei University School of Medicine

Received: August 17, 2015, Revised: September 30, 2015, Accepted: October 1, 2015, Published online: June 5, 2016

Corresponding author: Sungsoo Lee, Department of Thoracic and Cardiovascular Surgery, Gangnam Severance Hospital, Yonsei University School of Medicine, 211 Eonju-ro, Gangnam-gu, Seoul 06273, Korea
(Tel) 82-2-2019-3381 (Fax) 82-2-3461-8282 (E-mail) CHESTLEE@yuhs.ac

© The Korean Society for Thoracic and Cardiovascular Surgery. 2016. All right reserved.

© This is an open access article distributed under the terms of the Creative Commons Attribution Non-Commercial License (<http://creativecommons.org/licenses/by-nc/4.0>) which permits unrestricted non-commercial use, distribution, and reproduction in any medium, provided the original work is properly cited.

METHODS

We prospectively collected medical records of pneumothorax patients who underwent portable small-bore chest tube (9 Fr, Thoracic Egg; Sumitomo Bakelite Co. Ltd., Tokyo, Japan) insertion from August 2014 to March 2015 (Fig. 1). Fifty-six patients were followed in the outpatient clinic or admitted. After pneumothorax was resolved, we did not recommend regular outpatient division (OPD) visits. The indication for a portable small-bore chest tube (9 Fr) was a hemodynamically stable patient without a large pleural effusion or hemothorax on chest X-ray, showing costophrenic angle

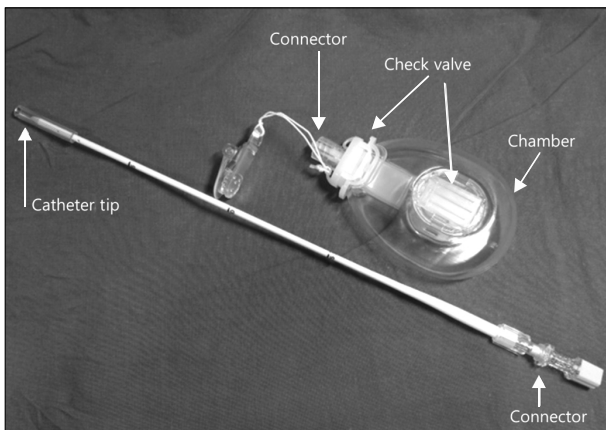


Fig. 1. Thoracic Egg catheter.

blunting, regardless of the cause of pneumothorax (Fig. 2).

To audibly confirm air leakage, we squeezed a plastic chamber, and by dipping the chamber in sterile water, we could hear and also see air bubbles emerging. However, these methods are inconvenient, so if a lung did not expand at follow-up X-ray after 3 to 7 days, we interpreted this to represent persistent air leakage. Therefore, discharged patients usually visited the outpatient clinic after one week to evaluate improvement in the pneumothorax. If the lung did not show full expansion, we recommend surgery as a response to persistent air leakage.

In all patients with an indication for the insertion of a portable thoracic drainage device, we used a Thoracic Egg. A Thoracic Egg consists of a flexible 9 Fr silicone catheter with two one-way Heimlich valves and a small plastic chamber. Under local anesthesia, a 5-mm skin incision was made. After a test puncture, a catheter was inserted in the third to fifth intercostal space in the anterior axillary line. After pleural puncture, the needle in the catheter was removed, and the catheter was inserted into the thoracic cavity. The catheter was fixed to the chest wall and connected to a plastic chamber with adhesive tape.

After insertion of the Thoracic Egg, we examined a chest X-ray after 30 minutes to 1 hour. We discharged patients when (1) the catheter position in the thoracic cavity was confirmed, (2) symptoms had resolved, and (3) expansion of the

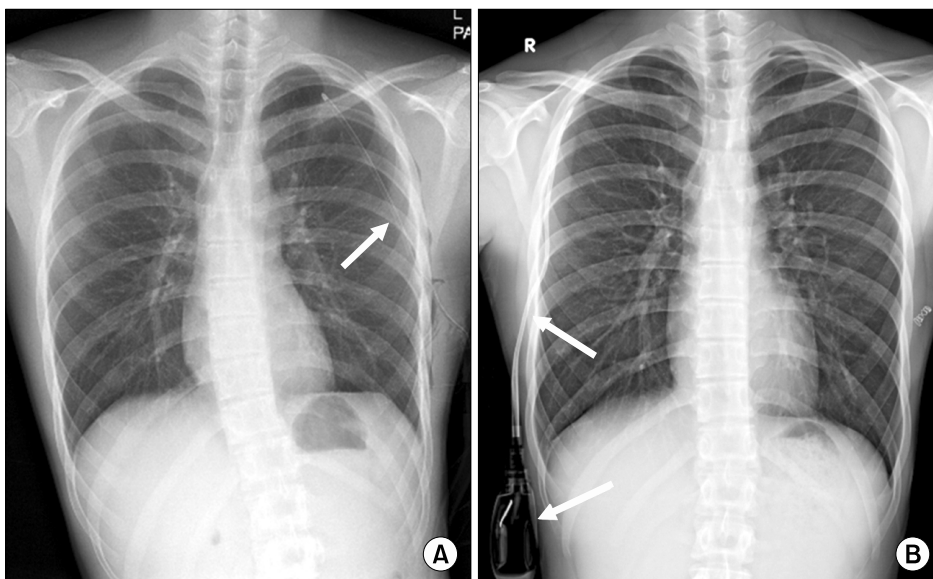


Fig. 2. Chest X-ray with (A) 12 Fr chest tube insertion (arrow) and (B) Thoracic Egg (arrows).

Table 1. Demographic data of the patients

| Demographic data | Value |
|--|---------------------|
| Sex (male:female) | 47:9 |
| Age (yr) | 31 (15-80) |
| Pneumothorax classification | |
| First spontaneous pneumothorax | 37 (66.1) |
| Recurrent pneumothorax | 10 (17.9) |
| Traumatic pneumothorax | 1 (1.8) |
| Secondary pneumothorax | 2 (3.6) |
| Iatrogenic pneumothorax | 6 (10.6) |
| Site of pneumothorax | |
| Left:right | 24:32 |
| Outpatient:inpatient | 44 (78.6):12 (21.4) |
| Duration of Thoracic Egg insertion (day) | 4.8 (1-9) |

Values are presented as number, mean (range), or number (%), unless otherwise stated.

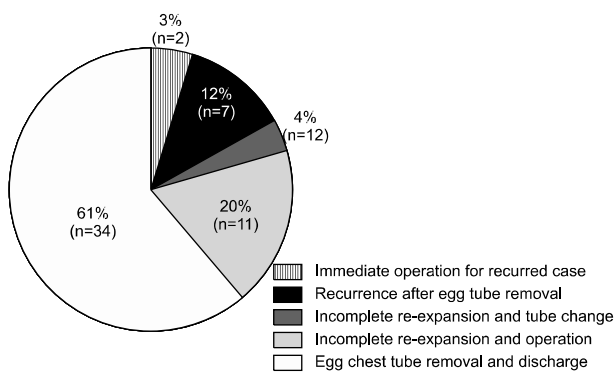


Fig. 3. Treatment results with Thoracic Egg.

lung was confirmed. Usually, we recommended that patients visit the outpatient clinic within one week, but we permitted admission if a patient preferred inpatient care.

RESULTS

A total of 56 patients were included in this study. Patient characteristics are documented in Table 1. The median age was 31 years, and 37 (66.0%) were under 30 years old. The majority were male (84.0%). By classification of pneumothorax, a first episode of PSP occurred in 37 patients (66.0%), recurrent PSP in 10 (17.8%), iatrogenic pneumothorax in 6 (10.7%), a secondary pneumothorax in 2 (3.6%), and a traumatic pneumothorax in one (1.8%). Left side pneumothorax occurred in 42.9% (n=24) and right side in 57.1% (n=32).

Table 2. Treatment for primary spontaneous pneumothorax (n=37)

| Primary spontaneous pneumothorax | Number |
|--|--------|
| No recurrence after Thoracic Egg removal | 23 |
| Recurrence after Thoracic Egg removal | 5 |
| Video-assisted thoracoscopic surgery due to incomplete expansion | 9 |

Table 3. Treatment for recurrent pneumothorax (n=10)

| Recurrent pneumothorax | Number |
|--|--------|
| No recurrence after Thoracic Egg removal | 4 |
| Recurrence after Thoracic Egg removal | 2 |
| Video-assisted thoracoscopic surgery due to incomplete expansion | 2 |
| Immediate operation for recurrent case | 2 |

Forty-four patients (78.6%) were discharged from the emergency room (ER) for follow-up in the outpatient clinic, and 12 patients (21.4%) were hospitalized because of individual needs. The mean duration of Thoracic Egg chest tube placement was 4.8 days. Treatment results with the Thoracic Egg are shown in Fig. 3, with a success rate of 73.0%, which was indicated by full expansion at the first OPD visit.

Among first episode PSP patients (n=37), 28 showed full expansion of the lung, and the chest tube was removed (Table 2). Nine patients did not show full expansion and progressed to VATS surgery. We were able to identify ruptured bullae in every patient who underwent surgery [2].

In recurrent pneumothorax patients (n=10), 6 patients showed resolution after Thoracic Egg insertion, while 2 patients showed incomplete lung expansion and underwent surgery. Two patients underwent immediate VATS, because we usually recommend surgery for recurrences (Table 3).

Iatrogenic pneumothorax patients (n=6) all showed resolution at the OPD visit. The causes of iatrogenic pneumothorax were needle aspiration biopsy, acupuncture, and lung injury during central line insertion.

The traumatic pneumothorax patient visited the ER with chest pain after falling down from 1 m. Because there was not much pleural effusion and the amount of pneumothorax was less than <50%, we used a Thoracic Egg and admitted the patient because of the possibility of delayed hemothorax. After 6 days, the patient was discharged without complication

following the removal of the Thoracic Egg.

In addition, two secondary pneumothorax patients, who had underlying chronic obstructive pulmonary disease, changed to a large chest tube 20 Fr or 24 Fr after 3–5 days following Thoracic Egg insertion. After 3 days, the patients were discharged without residual pneumothorax.

In summary, of 56 patients who underwent Thoracic Egg chest tube insertion, 73.2% (n=41) showed a resolved pneumothorax at the first OPD visit, and 23.2% (n=13) showed a residual pneumothorax and underwent surgery (n=11) or replacement with a larger tube (n=2) (Fig. 3).

DISCUSSION

Many studies have evaluated the efficacy of small-bore chest tubes (7 Fr, 12 Fr, etc.). In a study comparing the efficacy of 24 Fr and 12 Fr chest tubes, there was no difference in hospital stay (5.6 ± 1.9 days for the 24 Fr group and 5.2 ± 1.5 days for the 12 Fr group) or rate of conversion to surgery (35.0% for the 24 Fr group and 25.0% for the 12 Fr group) [5]. Other studies have reported excellent success rates ranging from 84.5% to 97.0% using small-bore catheters (5.5–9.4 Fr) for spontaneous pneumothorax [6,7]. In our study, we used a 9 Fr small bore chest tube, and the overall success rate was 73.0%.

Some studies have attempted outpatient treatment for pneumothorax. One small, randomized, controlled study compared a 12 Fr chest tube with needle aspiration for the treatment of PSP [8]. Among 48 patients, 23 underwent needle aspiration. Of these, 11 were discharged, and 12 were admitted after OPD visits. Of 25 patients who received a 12 Fr chest tube insertion with Heimlich valves, 18 were discharged. In this study, 60.0% of PSP patient were treated in the OPD.

In our study, the admission rate was 21.4%. Because some iatrogenic pneumothorax patients were already inpatients, the admission rate was an overestimate. Patients discharged with the Thoracic Egg could continue school and social activities. It will give patients social and economic benefits with reduced costs due to hospitalization. With the small size of the catheter, patients also felt more comfortable.

Use of a small bore catheter may lead to kinking or blockage [9]. There were two complications in this study. One pa-

tient had worsening of the pneumothorax because of catheter kinking, and another experienced a tension pneumothorax because of disconnection of the catheter from the plastic chamber. These two patients ultimately showed full expansion of the lung after management of the catheter and chamber. There were no other complications.

A similar study in Japan for treatment of PSP using the Thoracic Egg showed a success rate of 95.8%; 32.9% of the patients had a recurrent pneumothorax and received other treatments. In that study, the only indication for Thoracic Egg insertion was PSP [9].

In our study design, we used the Thoracic Egg regardless of pneumothorax type, except in patients with large effusions or a hemothorax. For first-episode PSP patients, the success rate was 75.6% (28/37); 37.8% (14/37) had recurrent pneumothorax and 24.0% (9/37) underwent VATS. In iatrogenic pneumothorax, the Thoracic Egg success rate was 100.0%. For recurrent pneumothorax patients, it was 60.0%. In addition, among patients with incomplete expansion of the lung after Thoracic Egg insertion, all had bullae on VATS inspection.

This study had several limitations. Because most patients were young, they were able to continue daily social activities with the Thoracic Egg. However, it was difficult to calculate the socioeconomic effect or cost savings. Moreover, some physicians did not favor use of the Thoracic Egg, resulting in some bias.

A portable small-bore chest tube, the Thoracic Egg, shows comparable results with other studies managing pneumothorax after hospitalization. In our institution, we provided initial treatment options to pneumothorax patients. The majority were young, and preferred to be discharged with the Thoracic Egg, enabling them to continue work and other activities. Thus, Thoracic Egg insertion can provide social and economic benefits for patients.

In conclusion, there are many treatment options for pneumothorax. This study showed comparable results with OPD treatment using the Thoracic Egg, with fewer complications. And most patients could continue daily activity with the Thoracic Egg. In this aspect, the treatment may have social and economic benefits. Therefore, the Thoracic Egg may be a good treatment option for pneumothorax.

CONFLICT OF INTEREST

No potential conflict of interest relevant to this article was reported.

ACKNOWLEDGMENTS

This study was supported by a Grant of the Samsung Vein Clinic Network (Daejeon, Anyang, Cheongju, Cheonan; Fund No.KTCS04-045).

REFERENCES

1. Sahn SA, Heffner JE. *Spontaneous pneumothorax*. N Engl J Med 2000;342:868-74.
2. MacDuff A, Arnold A, Harvey J; BTS Pleural Disease Guideline Group. *Management of spontaneous pneumothorax: British Thoracic Society Pleural Disease Guideline 2010*. Thorax 2010;65 Suppl 2:ii18-31.
3. Baumann MH, Strange C, Heffner JE, et al. *Management of spontaneous pneumothorax: an American College of Chest Physicians Delphi consensus statement*. Chest 2001;119:590-602.
4. Kurihara M, Kataoka H, Ishikawa A, Endo R. *Latest treatments for spontaneous pneumothorax*. Gen Thorac Cardiovasc Surg 2010;58:113-9.
5. Park SH, Shin YC, Chee HK, Kim EJ, Kim KI, Park JU. *Efficacy of 12 Fr. closed thoracostomy drainage in management of primary spontaneous pneumothorax*. Korean J Thorac Cardiovasc Surg 2004;37:983-6.
6. Conces DJ Jr, Tarver RD, Gray WC, Percy EA. *Treatment of pneumothoraces utilizing small caliber chest tubes*. Chest 1988;94:55-7.
7. Peters J, Kubitschek KR. *Clinical evaluation of a percutaneous pneumothorax catheter*. Chest 1984;86:714-7.
8. Ho KK, Ong ME, Koh MS, Wong E, Raghuram J. *A randomized controlled trial comparing minichest tube and needle aspiration in outpatient management of primary spontaneous pneumothorax*. Am J Emerg Med 2011;29:1152-7.
9. Karasaki T, Shintomi S, Nomura Y, Tanaka N, Saito H, Yoshida Y. *Outcomes of outpatient treatment for primary spontaneous pneumothorax using a small-bore portable thoracic drainage device*. Thorac Cardiovasc Surg 2014;62:516-20.