

Congenital malformations potentially affecting respiratory function: multidisciplinary approach and follow-up

Valentina Fainardi¹, Laura Nicoletti¹, Cristiano Conte¹, Serena Massa¹, Lisa Torelli¹, Alberto Attilio Scarpa², Emilio Casolari², Susanna Esposito¹, Giovanna Pisi¹

¹Pediatric Clinic, Dept of Medicine and Surgery, Pietro Barilla Children's Hospital, University of Parma, Italy;

²Pediatric Surgery Unit, Pietro Barilla Children's Hospital, Parma, Italy

Abstract. *Background and aim.* Congenital malformations such as oesophageal atresia (OA) and tracheoesophageal fistula (TOF), congenital pulmonary airway malformations (CPAMs), congenital diaphragmatic hernia (CDH) and vascular rings (VRs) can affect lung development and respiratory function. This observational study describes our multidisciplinary approach and respiratory follow-up of children with such congenital malformations. *Methods.* Clinical data of children followed at the Pediatric Respiratory Unit of Parma University Hospital (Italy) between January 2015 and January 2020 were collected. *Results.* Twenty-three patients with congenital malformation affecting lung development were identified. Almost half of our patients were diagnosed with fetal ultrasound. Children attended the clinic at a mean age of 3 (3.7) years and follow-up visits were scheduled every 6 months average. More than half of our patients were hospitalized for lower respiratory tract infections. Six out of 9 children able to perform spirometry showed anomalies in lung function. Chest physiotherapy was recommended especially in children with OA. *Conclusions.* Children with congenital malformations affecting lung development are at risk of short and long-term respiratory complications, especially in the first years of life. OA was the malformation more associated to respiratory problems. Multidisciplinary approach and appropriate personalized follow-up are recommended for the best management of these children. (www.actabiomedica.it)

Key words: congenital malformation, respiratory follow-up, multidisciplinary follow-up, lung function, diaphragmatic hernia, oesophageal atresia, vascular rings, congenital pulmonary airway malformations

Introduction

Congenital malformations such as oesophageal atresia (OA) and tracheoesophageal fistula (TOF), congenital pulmonary airway malformations (CPAMs), congenital diaphragmatic hernia (CDH) and vascular rings (VRs) can affect lung development and respiratory function with a significant burden of respiratory morbidity in infancy and childhood. Among these congenital malformations, the most frequent is OA with a prevalence of 1/2,500-3,500 live births (1). Depending on the anatomical defect, 5 types of OA have been classified (2) and all are characterized by a

congenital interruption in the continuity of the esophagus. Type C is the most common form (85-90%) and includes distal TOF (2).

CPAMs are a heterogeneous group of anomalies of the lower respiratory tract characterized by hamartomatous or dysplastic tissue in the context of normal lung parenchyma (3). The prevalence is between 1 out of 10,000 and 1 out of 35,000 births (4). According to embryological origin and histological characteristics, the classification of CPAMs includes 5 types. Type 1 is the most common type (60-65% of cases) and has the best prognosis. Pathologically, type 1 CPAM is characterized by single or multiple cysts of 2-10

cm in diameter that originate from distal bronchi or proximal bronchioli (5, 6). CDH is a developmental defect of the diaphragm which causes the herniation of abdominal viscera into the chest with various degrees of abnormal lung development and pulmonary hypoplasia. Most commonly, a left posterolateral hernia is identified. The prevalence is 1-4/10.000 live births (7). The term VRs refers to a variety of embryological abnormalities of the great arteries which results in the trachea and esophagus being encircled by vascular structures. Clinical symptoms may be barky cough, noisy breathing and dysphagia (8). VRs are rare with an incidence of 2-10/10.000; the most common VR is double aortic arch (9).

All these malformations represent a diagnostic and a therapeutic challenge from the fetal period because prenatal detection is not always easy and some patients may require corrective surgery in the first days of life and thereafter a long-term multidisciplinary approach. However, recommendations about the follow-up plan of these patients are lacking. This observational study describes our approach in the management of patients with congenital malformations affecting lung development.

Methods

This is a retrospective study of patients with congenital malformations affecting airways development followed at the Pediatric Respiratory Unit of Parma University Hospital (Italy) between January 2015 and January 2020. Age at diagnosis, gender, surgical interventions, number of hospital admissions and antibiotic courses for respiratory exacerbations, chronic pharmacological treatment and frequency of follow-up visits were collected from medical records. When available lung function tests were also recorded. Patients with congenital heart disease were not included in the study. The study was approved by the Ethics Committee of Area Vasta Emilia Nord (Italy) and parents provided their written informed consent for participation in the study and data publication.

Results

Congenital malformations affecting lung development were found in 23 patients. Related data are reported in Table 1.

Table 1. Characteristics of patients with congenital malformations affecting lung development on follow-up at the Pediatric Respiratory Unit of Parma University Hospital (Italy). Data are expressed as number (%), median (range) or mean (SD).

Malformation	n (%)	Males (%)	Prenatal diagnosis	N patients treated with surgery (%)	Age at first follow-up (years)	Age at last follow-up (years)	N visits/year
Oesophageal atresia (OA)	8 (34,8%)	4 (50 %)	0	8 (100%)	3,9 (0,5-8,9)	6,3 (2,1-14,3)	2,5 (±1,4)
Congenital pulmonary airway malformations (CPAMs)	7 (30,4%)	5 (71,4%)	6 (85,7%)	5 (71,4%)	1 (0,1-2)	4,6 (0,8-16,2)	2,5 (±1,1)
Congenital diaphragmatic hernia (CDH)	6 (26,1%)	4 (66,7%)	4 (66,7%)	6 (100%)	4,2 (0,1-14,5)	5,9 (0,6-15,5)	2,6 (±1,3)
Vascular malformations - double aortic arch - right aortic arch with mirror image branching	2 (8,7%)	2 (100%)	0	2 (100%)	2,9 (2,3-3,6)	3,6 (3,3-3,8)	2,5 (±2,1)

Oesophageal atresia (OA)

Eight children were followed-up in our outpatient clinic for type-C OA. All were diagnosed because of feeding problems in the early postnatal period and underwent surgical repair by thoracotomy within the 5th day of life. Most patients had primary repair by oesophageal anastomosis and closure of TOF; only one neonate underwent a two-step surgical approach due to a long-gap OA. Post-surgical complications were: anastomotic stricture (n=2), ectasia of the oesophageal tract (n=1), pneumonia (n=1), leakage of the anastomosis (n=2) and recurrence of the fistula (n=1). Patients with OA were seen for the first time at a mean age of 4 (standard deviation [SD] 3.3) years and followed-up every 6 months average. Only one patient underwent Palivizumab prophylaxis.

Tracheomalacia was found in five patients (62.5%) during fiberoptic endoscopy performed because of “dying spells” acute episodes with oxygen desaturation (n=3), reduced exercise tolerance (n=1), chronic cough (n=1) and respiratory distress (n=1). Furthermore, all children suffered from recurrent respiratory infections (5.5 ± 3.5 episodes per year needing antibiotic course).

Regardless of the finding of tracheomalacia, patients with OA reported poor growth (n=2), gastroesophageal reflux (n=1) and dysphagia (n=1). Five children (62.5%) (1 atopic) showed preschool episodic wheezing. One patient was diagnosed with allergic asthma at the age of 7. All patients but one were admitted to the hospital for pneumonia at least once (63% in the first 3 years of life) with a mean number of hospitalizations of 1.1 (0.7) per year; 2 patients (25%) required intensive support in the intensive care unit (ICU). Fifty percent of patients showed 3 or more episodes of pneumonia in their lifetime. The mean number of respiratory infections treated by antibiotic courses was 4.8 (± 3.5) per year. One child was admitted to the hospital 7 times in the first 2 years of life for persistent wheezing, croup and severe gastroesophageal reflux. Spirometry was performed in 4 patients (mean age 7.7 ± 2.1 years) (FEV₁ 90% ± 7, FVC 91 ± 9.5, FEV₁/FVC 100.6% ± 15.6, FEF₂₅₋₇₅ 87.6% ± 28.5), one of them showing mild restrictive ventilatory pattern and another one flattening of the expiratory curve suggesting tracheomalacia. Most

patients (62.5%) regularly performed respiratory physiotherapy with PEP-mask. All children with preschool wheezing were treated with leukotriene receptor antagonist, inhaled corticosteroids (ICS) and short-acting beta-2 agonists (SABA). The boy with asthma was on ICS and long-acting beta-2 agonists (LABA).

Over the years, 4 patients (50%) stopped the follow-up visits (two had resolution of respiratory symptoms, one preferred attending a respiratory unit closer to home and one was lost at follow-up).

Congenital pulmonary airway malformations (CPAMs)

Almost all children with CPAMs (6 out of 7) were diagnosed prenatally by fetal ultrasound, confirmed in 2 cases by fetal magnetic resonance imaging (MRI). Overall, 3 out of 7 children (42.9%) showed respiratory distress at birth. Of note, one girl was born extremely preterm at 26 + 6 weeks of gestational age. Babies with a known prenatal diagnosis had a radiological confirmation by chest X-rays the first day of life; the only patient without prenatal diagnosis underwent a chest X-rays following respiratory distress at birth. In order to achieve a better anatomical characterization of the pulmonary defect, 5 patients (71.4%) were investigated by a chest high resolution computed tomography (HRCT) scan at a median age of 11 days (1-400 days).

Five children (71.4%) underwent surgery at a median age of 7 months (0.5-16.5 months) by video assisted thoracoscopic (VATS) (n=3) or thoracotomic approach (n=2); atypical lung resection was performed in 4 patients while lobectomy was preferred in 1. Post-surgical complications included pleural effusion with subcutaneous emphysema (n=2) and residual diaphragm elevation (n=1). The histopathological examination performed on the removed lung tissues revealed that 3 out of the 5 operated patients had a type 2 CPAM and one had a type 3; in one case the histological result was not available. Follow-up visits started one month apart from birth in patients who received prenatal diagnosis in our hospital (n=3) and between 12 and 24 months in other patients (n=4). Follow-up visits were scheduled every 6 months. Palivizumab was administered to 3 patients. Two patients continued

the follow-up elsewhere in a centre closer to their hometown after a follow-up period of 14 years and 6 months, respectively.

Considering the five operated children, two, both atopic, experienced episodic preschool wheezing and were treated with maintenance ICS, one of whom was hospitalized for an episode of wheezing during respiratory infection at 1 year of age.

Two patients did not undergo surgery. One boy was referred to our Centre at 16 years of age and at CT scan the pulmonary parenchyma revealed fibrotic septa and multiple bronchiectasis with reduction of the right lung volume; he suffered from recurrent respiratory infections (on average 2 per year). A 12 months-old boy with right CPAM was asymptomatic at last follow-up evaluation and surgery was scheduled within the following 3 months.

Pulmonary function tests (PFTs) were available only for 2 children because other patients were too young to perform spirometry at time of data collection. In patient with untreated bilateral CPAMs, PFTs performed at the age of 14 years showed a mixed disventilatory defect with obstruction and restriction (FEV_1 36%, FVC 64%, FEV_1/FVC 54%, FEV_{25-75} 17%). Spirometric values were normal at the age of 5 years in the boy who underwent atypical resection of the CPAMs in the left lower lobe (FEV_1 102.8%, FVC 87.9%, FEV_1/FVC 111%, FEV_{25-75} 107%).

Congenital diaphragmatic hernia (CDH)

The 6 patients with CDH showed a posterolateral defect (through the foramen of Bochdalek). Four patients (66.6%) had a prenatal diagnosis and underwent surgical correction within 48 hours. One patient was diagnosed at birth and operated at 2 months of age. In one child, CDH was diagnosed at 20 months of age by a chest X-ray performed for recurrent respiratory infections and poor growth.

Respiratory follow-up started after the corrective surgery and continued every 6 months in all patients but one who attended for the first time the clinic at the age of 14 years because of allergic asthma. One girl was discharged after a first examination following spontaneous resolution of respiratory symptoms 2 months after surgery. Palivizumab was administered to 3 patients.

Four patients were hospitalized: two children for asthma exacerbation at 8 and 14 years old, respectively, and two for pneumonia in preschool age. On average patients with CDH needed 1.3 (0.6) courses of antibiotics per year.

Two children could perform spirometry (mean age 12.1 ± 4.7 years) and showed a restrictive pattern (FEV_1 $61.9\% \pm 0.1$, FVC 55.5 ± 3.5 , FEV_1/FVC $100.3\% \pm 17.8$, FEF_{25-75} $67.7\% \pm 25.1$). One was on continuous ICS plus LABA and leukotriene receptor antagonist.

Vascular rings (VRs)

Two patients with complete VRs (double aortic arch and right aortic arch with mirror image branching) were followed-up at our center. In both cases, diagnosis was made in the first 3 years of life (2 yrs/4 months, 3 yrs/7 months) by chest CT-angiography during investigations (chest X-rays, barium-X-rays of upper gastrointestinal tract and doppler-color flow echocardiography) required for wheezing, stridor and poor weight gain. Both patients underwent corrective surgery within one year with complete resolution of the respiratory symptoms. Therefore, after an initial respiratory follow-up with a mean of two visits per year, they were discharged from the respiratory clinic and continued with the yearly cardiological follow-up.

Discussion

Over the last 5 years, 23 patients with congenital malformation affecting lung development have been followed-up in the Pediatric Respiratory Unit of Parma University Hospital. The most common anomaly was OA with TOF (n=8) followed by CPAMs (n=7), CDH (n=6) and VRs (n=2). Mean age at assessment in our unit was 3 (3.7) years; follow-up visits were scheduled on average every 6 months.

Almost half of our patients (43.5%) were diagnosed with fetal ultrasound between the 18th and 22nd week of gestation. CPAMs are usually identified in prenatal era (4) and in our study this malformation was detected before birth in almost all patients (6 out of 7). More than 60% of newborns with CDH usually have a prenatal diagnosis (10) and the same percentage

has been reported in our cohort (66%). Post-natal diagnosis of CDH usually occurs in mild cases when respiratory or gastrointestinal symptoms motivate further investigations (11). Conversely, prenatal identification of OA remains challenging (12) and detection occurs in less than one third of cases (13). Most patients are diagnosed following swallowing problems in early life. Also VRs can be very difficult to diagnose, a recent Canadian cohort study reported prenatal diagnosis only in 26% of cases (14). The 2 patients of our cohort with VRs were diagnosed with chest CT-angiography but after several investigations performed for unexplained respiratory symptoms and failure to thrive. Bronchoscopic examination can suspect the malformation in case of extrinsic pulsatile compression of the trachea (15) and echocardiography can be useful in demonstrating whether the aortic arch is left-sided or right-sided. With prenatal diagnosis the malformation can be usually described in terms of dimension and morphology, potential complications at time of delivery can be predicted and, when needed, a multidisciplinary team can be engaged. In selected cases, fetal MRI is recommended to better describe the lesion (16). Multidisciplinary counselling, including neonatologists, pediatric surgeons and pediatric pulmonologists or gastroenterologists, can provide parents with information about management, prompt surgery if needed, possible issues and outcomes.

More than half of our patients (61%) were hospitalized for lower respiratory tract infections (LRTI) with an average of 3.9 (3.3) LRTI in lifetime. Respiratory infections were particularly frequent in children with OA with up to 5 courses of antibiotics per year and at least one admission to the hospital in the first 3 years of life. Furthermore, compared to other anomalies, children with OA were at higher risk of respiratory complications with two kids admitted to ICU for severe respiratory distress (25% vs 0% in other congenital malformations). The residual tracheomalacia observed in 75% of our patients with OA is a common complication of surgical correction (17) and may be a risk factor for recurrent respiratory infections and respiratory failure (18, 19). Tracheomalacia is associated to impaired clearance of respiratory secretions (20) that can expose patients to acute respiratory obstructions sometimes leading to life-threatening episodes of

apnea, the so-called “dying spells”(17). This was experienced by 3 of our 5 patients with OA. In severe cases extreme treatments such as temporary stents may be considered (21).

In children with CPAMs, the incidence of respiratory infection is lower with up to 10% of patients reporting such complication (22). In our cohort most patients (5 out of 7) were operated in early infancy and only one of these was hospitalized for a respiratory infection. None of the untreated two patients required hospital admission for respiratory exacerbations but one reported frequent LTRI with need of oral courses of antibiotics. Since little is known about the natural history of CPAMs, there are different strategies of management. Symptomatic lesions in the neonatal period are surgically removed without debate, while asymptomatic children may be treated differently depending on the referral centre. A previous retrospective study described that 70% of resected CPAMs worldwide were associated to malignant transformation or recurrent infections (23, 24). Conversely, a large case series of untreated patients with CPAMs with a median follow-up of 10 years reported no cases of malignancy and a risk of recurrent infections in less than 10% of cases with a further decrease after the second year of life (22). In a comparison analysis, children operated for CPAMs had a significantly lower lung function than those treated with a conservative approach (25) but compensatory lung growth after pulmonary lobectomy in infancy has been reported (26). Considering the increasing incidence of these malformations in prenatal age, each case deserves a careful multidisciplinary approach and in selected asymptomatic cases a conservative approach may be an option although excising asymptomatic lesions is safe with minimal complications.

Four out of 6 children operated with CDH were hospitalized for respiratory infections. Respiratory infections affect 34-55% of patients operated for CDH (27, 28). In a Polish study of 50 children operated for CDH, 70% showed ipsilateral lung hypoplasia at scintigraphy (27), a condition that may increase the risk of frequent lung infections and reduced respiratory function (29). We did not perform scintigraphy in our patients, but we could suspect lung hypoplasia in three: one baby boy had a radiological picture soon

after surgery consistent with residual lung hypoplasia and two kids showed a restrictive spirometric pattern suggestive of lung hypoplasia. When investigated longitudinally, children with previous CDH showed a significant impairment in lung function and exercise performance at 5 years of age (28).

Almost all patients aged <12 months who started follow-up at our outpatient clinic underwent immunoprophylaxis with Palivizumab against Respiratory Syncytial Virus (RSV) until the age of two. Among the patients who did not receive the prophylaxis, two developed RSV infection with need of hospitalization: one was diagnosed with the malformation too late to start the injections and one started respiratory follow-up after 2 years of age. RSV causes approximately 20% of all respiratory infections in children under 5 years of age (30). Compared to children who received prophylaxis with Palivizumab for approved indications, those with congenital airway abnormalities present a greater risk of about 2-fold of hospitalization for RSV respiratory infections (31). In a recent review, experts from Canada, Europe and Israel recommended extending the use of Palivizumab to children with congenital pulmonary malformations until 24 months of age (32). However, local guidelines approve the prophylaxis for children with severe tracheo-bronchial malformations including CDH only until 12 months of age. Furthermore, we recommend annual influenza vaccination for all patients 6 months and older.

Spirometric monitoring in patients with congenital malformation affecting lung development highlights a variable impairment of respiratory function compared to healthy controls. In preschool children operated for OA bronchial hyperresponsiveness can persist into adulthood (33, 34). Asthma is frequently observed in these survivors but it is still debated whether an obstructive or a restrictive pattern prevails (17, 19, 35, 36). Similarly, no specific spirometric pattern has been associated with CPAMs. Most children with asymptomatic CPAMs present respiratory function values within normal limits, while those with extensive surgical lung removal may experience lower lung function values compared to healthy children. This seems to be more related to the mass effect of the CPAMs and the associated alterations of the adjacent lung tissue, rather than to the loss of lung parenchyma

determined by surgical resection (25, 37). Some studies performed on children operated for CDH showed mild to moderate pulmonary functional impairment with scarce or no symptoms such as higher functional residual capacity in infancy (38), greater airway resistance and restriction or obstruction at spirometry in childhood (39). Moreover, more than 50% of adults operated in early life for CDH shows impaired pulmonary function tests with restrictive and obstructive patterns in similar prevalence (40). We could not measure lung function in patients with VRs because both interrupted follow-up in consideration of the successful surgical result. However, even a successful surgical airway decompression can rarely result in residual tracheobronchial malacia, particularly in children with double aortic arch (15). A close monitoring of these patients is therefore important to exclude this complication.

Five patients with OA and one with CDH were regularly treated with respiratory physiotherapy. Airway clearance techniques (ACTs) may significantly improve mucociliary clearance and gas exchange especially during respiratory tract infections and may reduce pulmonary complications. In clinical practice, the most used ACT is positive expiratory pressure (PEP) with mask. This generates a positive pressure that stabilizes the peripheral airways and facilitates the removal of the respiratory secretions (41). As a referral center for cystic fibrosis, our policy recommends chest physiotherapy in patients with recurrent infections and/or anatomical anomalies such as bronchiectasis, lung hypoplasia or tracheomalacia. Although studies on the effectiveness of physiotherapy for patients with tracheomalacia in reducing lower respiratory tract infections are lacking (42), PEP-mask is usually recommended. One study reported that a PEP of 5–10 cmH₂O during cough can improve tracheal collapse and enhance cough effectiveness (43).

This retrospective study presents several limitations. The cohort is small and for 15 (65%) children follow-up duration was only 5-year long. However, most of the respiratory complications occurred within the first years of life and we can speculate that our cohort can be representative of the short-term clinical outcome of patients with congenital malformations affecting lung development. Because of the young mean

age of our patients, only 39% [(9/23, mean age 11.6 (5) yrs] performed spirometry and no further lung function tests were performed. Therefore, we are unable to describe residual lung function in younger patients [n 14, mean age 3.8 (2.5) yrs] after the surgical intervention. The absence of a control group with congenital malformations who has never fulfilled pneumological follow-up prevents from drawing conclusions about the role of the respiratory clinician in limiting respiratory complications. However, attending a respiratory unit in a tertiary pediatric centre allows, when needed, the involvement of a multidisciplinary team including neonatologist, pediatric surgeon, pediatric radiologist, pediatric gastroenterologist and physiotherapist with possible advantages in terms of clinical outcome.

Conclusions

Children with congenital malformations affecting lung development are at risk of short and long-term respiratory complications. About 60% of our cohort

was hospitalized for respiratory infections and more than one third for pneumonia. The respiratory burden is particularly high in the first years of life with OA being the most problematic malformation. Since some congenital malformations are surgically treated, a close collaboration with surgeons is essential for a personalized follow-up. Respiratory issues can negatively impact on children's and families' quality of life and all children with congenital anomalies affecting lung development should be referred to a tertiary paediatric respiratory center for a full multidisciplinary assessment, further investigations and appropriate follow-up. A proposed approach is illustrated in Figure 1. More long-term studies are needed to optimize the management of these patients and find strategies to improve respiratory outcome.

Conflicts of interest: Each author declares that he or she has no commercial associations (e.g. consultancies, stock ownership, equity interest, patent/licensing arrangement etc.) that might pose a conflict of interest in connection with the submitted article.

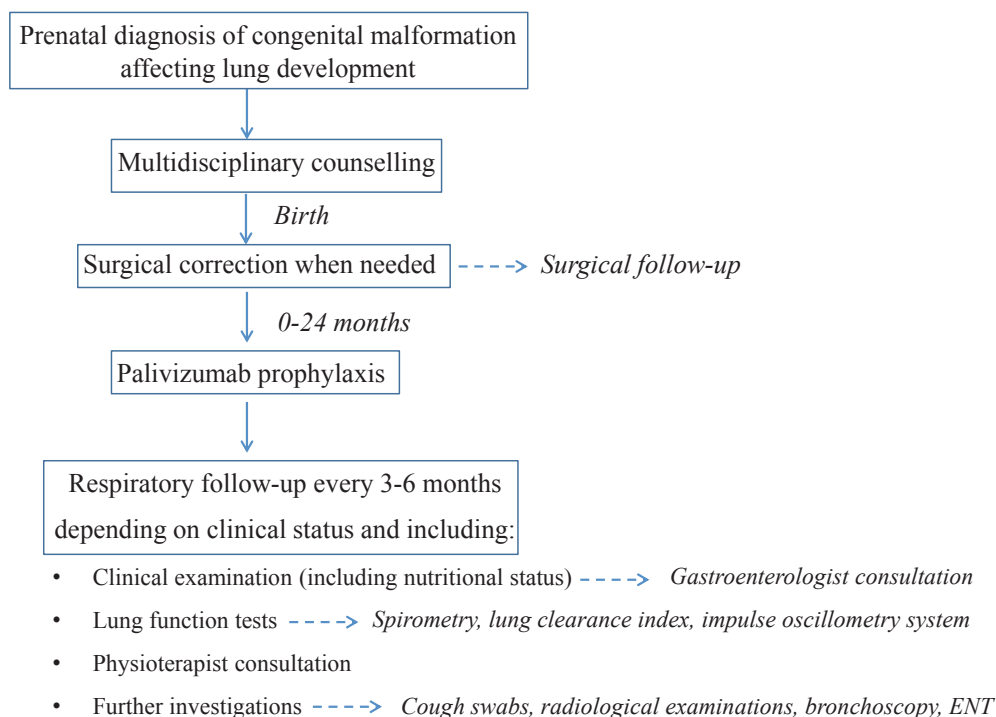


Figure 1. Flow-chart of multidisciplinary approach for children with congenital malformation affecting lung development. ENT, ear nose and throat specialist

References

1. Garabedian C, Vaast P, Bigot J, Sfeir R, Michaud L, Gottrand F, et al. Atrésie de l'œsophage: prévalence, diagnostic anténatal et pronostic. *Journal de Gynécologie Obstétrique et Biologie de la Reproduction*. 2014;43(6):424–30
2. Achildi O, Grewal H. Congenital anomalies of the esophagus. *Otolaryngol Clin North Am*. 2007;40(1):219–44
3. Meyyappan M, Praveen Sharma K, Aslam M. Antenatally Diagnosed Congenital Pulmonary Airway Malformation with Postnatal Follow-up. *J Appl Sci Res*. 2019;8(12)
4. Mehta PA, Sharma G. Congenital Pulmonary Airway Malformation. In: *StatPearls* [Internet]. Treasure Island, FL: StatPearls Publishing; 2020. Updated December 4, 2019.
5. Disu EA, Kehinde OA, Anga AL, Ubuane PO, Itiola A, Akinola IJ, et al. Congenital pulmonary airway malformation: A case report of a rare cause of neonatal respiratory distress and review of the literature. *Niger J Clin Pract*. 2019;22(11):1621–5
6. Alshamiri KM, Abbod HB. Congenital cystic adenomatoid malformation. *Int J Pediatr Adolesc Med*. 2017;4(4):159–60
7. Aly H, Bianco-Batlles D, Mohamed MA, Hammad TA. Mortality in infants with congenital diaphragmatic hernia: a study of the United States National Database. *Journal of Perinatology* 2010;(30):553–7
8. Hanneman K, Newman B, Chan F. Congenital Variants and Anomalies of the Aortic Arch. *RadioGraphics*. 2017;(37):32–51
9. François K, Panzer J, De Groote K, Vandekerckhove K, De Wolf D, De Wilde H, et al. Early and late outcomes after surgical management of congenital vascular rings. *European Journal of Pediatrics*. 2017;(176):371–7
10. Deprest J, Brady P, Nicolaides K, Benachi A, Berg C, Vermeesch J, et al. Prenatal management of the fetus with isolated congenital diaphragmatic hernia in the era of the TOTAL trial. *Semin Fetal Neonatal Med*. 2014;19(6):338–48
11. Elhalaby EA, Abo Sikeena MH. Delayed presentation of congenital diaphragmatic hernia. *Pediatr Surg Int*. 2002; 18(5-6):480–5
12. Pardy C, D'Antonio F, Khalil A, Giuliani S. Prenatal detection of esophageal atresia: A systematic review and meta-analysis. *Acta Obstet Gynecol Scand*. 2019;98(6):689–99
13. Garabedian C, Vaast P, Verpillat P, Sfeir R, Coulon C, Houfflin-Debarge V. Prenatal diagnosis of esophageal atresia: A case of triple negative screening. *J Gynecol Obstet Hum Reprod*. 2019;48(1):69–70
14. Young AA, Hornberger LK, Haberer K, Fruitman D, Mills L, Noga M, et al. Prenatal Detection, Comorbidities, and Management of Vascular Rings. *Am J Cardiol*. 2019 15;123(10):1703–8
15. Serio P, Nenna R, Fainardi V, Grisotto L, Biggeri A, Leone R, et al. Residual tracheobronchial malacia after surgery for vascular compression in children: treatment with stenting. *Eur J Cardiothorac Surg*. 2017;51(2):211–17
16. Annunziata F, Bush A, Borgia F, Raimondi F, Montella S, Poeta M, et al. Congenital Lung Malformations: Unresolved Issues and Unanswered Questions. *Front Ped*. 2019;7:239
17. Patria MF, Ghislanzoni S, Macchini F, Lelii M, Mori A, Leva E, et al. Respiratory Morbidity in Children with Repaired Congenital Esophageal Atresia with or without Tracheoesophageal Fistula. *Int J Environ Res Public Health* 2017;14(10)
18. van Lennep M, Singendonk MMJ, Dall'Oglio L, Gottrand F, Krishnan U, Terheggen-Lagro SWJ, et al. Oesophageal atresia. *Nat Rev Dis Primers*. 2019;5(1):26
19. Pedersen RN, Markow S, Kruse-Andersen S, Qvist N, Gerke O, Husby S, et al. Long-term pulmonary function in esophageal atresia-A case-control study. *Pediatr Pulmonol*. 2017;52(1):98–106
20. Sadreameli SC, McGrath-Morrow SA. Respiratory Care of Infants and Children with Congenital Tracheo-Oesophageal Fistula and Oesophageal Atresia. *Paediatr Respir Rev*. 2016;17:16–23
21. Serio P, Fainardi V, Leone R, Baggi R, Grisotto L, Biggeri A, et al. Tracheobronchial obstruction: follow-up study of 100 children treated with airway stenting. *Eur J Cardiothorac Surg*. 2014;45(4):e100–9
22. Cook J, Chitty LS, De Coppi P, Ashworth M, Wallis C. The natural history of prenatally diagnosed congenital cystic lung lesions: long-term follow-up of 119 cases. *Arch Dis Child*. 2017;102(9):798–803
23. Stanton M, Njere I, Ade-Ajayi N, Patel S, Davenport M. Systematic review and meta-analysis of the postnatal management of congenital cystic lung lesions. *J Pediatr Surg*. 2009;44(5):1027–33
24. Thakkar HS, Durell J, Chakraborty S, Tingle B-L, Choi A, Fowler DJ, et al. Antenatally Detected Congenital Pulmonary Airway Malformations: The Oxford Experience. *Eur J Pediatr Surg*. 2017;27(4):324–9
25. Hijkoop A, van Schoonhoven MM, van Rosmalen J, Tibboel D, van der Cammen-van Zijp MHM, Pijnenburg MW, et al. Lung function, exercise tolerance, and physical growth of children with congenital lung malformations at 8 years of age. *Pediatr Pulmonol*. 2019;54(8):1326–34
26. Laberge J-M, Bratu I, Flageole H. The management of asymptomatic congenital lung malformations. *Paediatr Respir Rev*. 2004;5 Suppl A:S305–12
27. Koziarkiewicz M, Taczalska A, Piaseczna-Piotrowska A. Pulmonary torsion as an atypical complication of congenital esophageal atresia repair-a case report and review of literature. *European J Pediatr Surg Rep*. 2014;2(1):43–5
28. Gischler SJ, van der Cammen-van Zijp MHM, Mazer P, Madern GC, Bax NMA, de Jongste JC, et al. A prospective comparative evaluation of persistent respiratory morbidity in esophageal atresia and congenital diaphragmatic hernia survivors. *J Pediatr Surg*. 2009;44(9):1683–90
29. Stefanutti G, Filippone M, Tommasoni N, Midrio P, Zucchetta P, Moreolo GS, et al. Cardiopulmonary anatomy and function in long-term survivors of mild to moderate congenital diaphragmatic hernia. *Journal of Pediatric Surgery*. 2004 (39);526–31
30. Resch B. Product review on the monoclonal antibody palivizumab for prevention of respiratory syncytial virus infection. *Hum Vaccin Immunother*. 2017;13(9):2138–49

31. Paes B, Kim D, Saleem M, Wong S, Mitchell I, Lanctot KL, et al. Respiratory syncytial virus prophylaxis in infants with congenital airway anomalies compared to standard indications and complex medical disorders. *Eur J Pediatr.* 2019;178(3):377–85
 32. Expert consensus on palivizumab use for respiratory syncytial virus in developed countries. *Paediatr Respir Rev.* 2020;33:35–44
 33. Leibovitch L, Zohar I, Maayan-Mazger A, Mazkereth R, Strauss T, Bilik R. Infants Born with Esophageal Atresia with or without Tracheo-Esophageal Fistula: Short- and Long-Term Outcomes. *Isr Med Assoc J.* 2018;20(3):161–6
 34. Mirra V, Maglione M, Di Micco LL, Montella S, Santamaria F. Longitudinal Follow-up of Chronic Pulmonary Manifestations in Esophageal Atresia: A Clinical Algorithm and Review of the Literature. *Pediatr Neonatol.* 2017;58(1):8–15
 35. Donoso F, Hedenström H, Malinowski A, E Lilja H. Pulmonary function in children and adolescents after esophageal atresia repair. *Pediatr Pulmonol.* 2020;55(1):206–13
 36. Sistonen S, Malmberg P, Malmström K, Haahtela T, Sarna S, Rintala RJ, et al. Repaired oesophageal atresia: respiratory morbidity and pulmonary function in adults. *Eur Respir J.* 2010;36(5):1106–12
 37. Maneenil G, Ruangnapa K, Thatrimontrichai A, Janjindamai W, Dissaneevate S, Anantasree W, et al. Clinical presentation and outcome in congenital pulmonary malformation: 25 year retrospective study in Thailand. *Pediatr Int.* 2019;61(8):812–6
 38. Spoel M, van den Hout L, Gischler SJ, Hop WCJ, Reiss I, Tibboel D, et al. Prospective longitudinal evaluation of lung function during the first year of life after repair of congenital diaphragmatic hernia. *Pediatr Crit Care Med.* 2012;13(3):e133–9
 39. Basek P, Bajrami S, Straub D, Moeller A, Baenziger O, Wildhaber J, et al. The pulmonary outcome of long-term survivors after congenital diaphragmatic hernia repair. *Swiss Med Wkly.* 2008;138(11-12):173–9
 40. Vanamo K, Rintala R, Sovijärvi A, Jääskeläinen J, Turpeinen M, Lindahl H, et al. Long-term pulmonary sequelae in survivors of congenital diaphragmatic defects. *Journal of Pediatric Surgery.* 1996 (31);1096–100
 41. Pisi G, Chetta A. Airway clearance therapy in cystic fibrosis patients. *Acta Biomed.* 2009;80(2):102–6
 42. Wallis C, Alexopoulou E, Antón-Pacheco JL, Bhatt JM, Bush A, Chang AB, et al. ERS statement on tracheomalacia and bronchomalacia in children. *Eur Respir J.* 2019;54(3)
 43. Sirithangkul S, Ranganathan S, Robinson PJ, Robertson CF. Positive expiratory pressure to enhance cough effectiveness in tracheomalacia. *J Med Assoc Thai.* 2010;93 Suppl 6:S112–8
-
- Received: 20 August 2020
Accepted: 4 September 2020
- Correspondence:**
Dr. Valentina Fainardi
Pediatric Clinic, Dept of Medicine and Surgery
Parma University Hospital, Parma, Italy
Via Gramsci, 14, 43125 Parma (Italy)
Tel. +39 0521 702198/2199
E-mail: valentina.fainardi@unipr.it