

## Immunohistochemical Analysis of the Role Connective Tissue Growth Factor in Drug-induced Gingival Overgrowth in Response to Phenytoin, Cyclosporine, and Nifedipine

A. J. Anand<sup>1</sup>, Sivaram Gopalakrishnan<sup>2</sup>, R. Karthikeyan<sup>1</sup>, Debasish Mishra<sup>3</sup>, Shreeram Mohapatra<sup>4</sup>

<sup>1</sup>Department of Periodontics, Tamil Nadu Government Dental College, <sup>2</sup>Department of Periodontics, Ragas Dental College and Hospitals, Chennai, Tamil Nadu,

<sup>3</sup>Department of Periodontics and Oral Implantology, Kalinga Institute of Dental Sciences, KIIT University, Bhubaneswar, <sup>4</sup>Department of Oral Medicine S.C.B. Dental College and Hospitals, Cuttack, Odisha, India

### ABSTRACT

**Objective:** To evaluate for the presence of connective tissue growth factor (CTGF) in drug (phenytoin, cyclosporine, and nifedipine)-induced gingival overgrowth (DIGO) and to compare it with healthy controls in the absence of overgrowth.

**Materials and Methods:** Thirty-five patients were chosen for the study and segregated into study (25) and control groups (10). The study group consisted of phenytoin-induced (10), cyclosporine-induced (10), and nifedipine-induced (5) gingival overgrowth. After completing necessary medical evaluations, biopsy was done. The tissue samples were fixed in 10% formalin and then immunohistochemically evaluated for the presence of CTGF. The statistical analysis of the values was done using statistical package SPSS PC+ (Statistical Package for the Social Sciences, version 4.01).

**Results:** The outcome of immunohistochemistry shows that DIGO samples express more CTGF than control group and phenytoin expresses more CTGF followed by nifedipine and cyclosporine.

**Conclusion:** The study shows that there is an increase in the levels of CTGF in patients with DIGO in comparison to the control group without any gingival overgrowth. In the study, we compared the levels of CTGF in DIGO induced by three most commonly used drugs phenytoin, cyclosporine, and nifedipine. By comparing the levels of CTGF, we find that cyclosporine induces the production of least amount of CTGF. Therefore, it might be a more viable drug choice with reduced side effects.

**KEYWORDS:** *Connective tissue growth factor, cyclosporine, drug-induced gingival overgrowth, nifedipine, phenytoin*

Received : 12-11-17.

Accepted : 25-12-17.

Published : 06-02-18.

### INTRODUCTION

Drug therapy for the treatment of any disease results in side effects based on the environment and host factors. One such side effect is gingival overgrowth, which is often seen in patients taking drugs such as phenytoin, cyclosporine, and nifedipine.

This abnormal growth creates considerable discomfort for a patient with increasing accumulation of debris in the oral cavity. It leads to halitosis and advanced periodontal damages.

Previous literature shows that increased levels of various cytokines as transforming growth factor- $\beta$  (TGF $\beta$ ), fibroblast growth factor, platelet-derived growth factor (PDGF), and connective tissue growth factor (CTGF) are elevated in drug-induced gingival

**Address for correspondence:** Dr. Debasish Mishra,

Department of Periodontics and Oral Implantology, Kalinga Institute of Dental Sciences, Campus 5, KIIT University, Bhubaneswar - 751 024, Odisha, India.  
E-mail: dr.deb@zoho.com

This is an open access article distributed under the terms of the Creative Commons Attribution-NonCommercial-ShareAlike 3.0 License, which allows others to remix, tweak, and build upon the work non-commercially, as long as the author is credited and the new creations are licensed under the identical terms.

For reprints contact: reprints@medknow.com

**How to cite this article:** Anand AJ, Gopalakrishnan S, Karthikeyan R, Mishra D, Mohapatra S. Immunohistochemical analysis of the role connective tissue growth factor in drug-induced gingival overgrowth in response to phenytoin, cyclosporine, and nifedipine. J Int Soc Prevent Communit Dent 2018;8:12-20.

### Access this article online

#### Quick Response Code:



Website: [www.jispcd.org](http://www.jispcd.org)

DOI: [10.4103/jispcd.JISPCD\\_403\\_17](https://doi.org/10.4103/jispcd.JISPCD_403_17)

overgrowth (DIGO). These cytokines play an active role in the development of DIGO.<sup>[1-4]</sup>

CTGF belongs to a recently discovered group of cytokines known as Cyr61 Ctgf Nov family of factors that are required for the biologic process of repair and differentiation.<sup>[4,5]</sup> CTGF was found to stimulate fibroblast and play a pivotal role in the growth of extracellular matrix synthesis.<sup>[6]</sup>

Extensive literature is explaining the pathogenesis of DIGO. However, there are yet insufficient numbers of research statistically analyzing the role of CTGF in DIGO.<sup>[7]</sup>

Therefore, the present comparative study has been undertaken to quantifiably assess the involvement of CTGF in DIGO with the help of immunohistochemistry. By this, the role of CTGF in DIGO will be clearer.

## MATERIALS AND METHODS

Patients attending the Department of Neurology, Cardiology, and Transplant Medicine, Madras Medical College and Government General Hospital, Chennai-3, undergoing medication with phenytoin, cyclosporine, and nifedipine were screened for gingival overgrowth and referred to the Department of Periodontics, Tamil Nadu Government Dental College, Chennai, for this study. The Institutional Review Board of Madras Dental College approved the study protocol via approval letter numbered DE/102/2004. Before conducting the study, the procedure was explained to all patients, and informed consent was obtained from each of the patients. The study was conducted for 6 months.

To select patients for the study, strict inclusion and exclusion criteria were followed. After consultation with a statistician, a sample size of minimum 30 patients was finalized to have statistically relevant data.

Therefore, based on above-mentioned factors, 35 patients were selected for the study and then separated into two groups: control and study groups.

The control group (10 patients) consisted of systemically healthy patients with clinical normal gingiva without any overgrowth.

The study group consists of Groups A, B, and C as follows:

- Group A: Phenytoin-induced gingival overgrowth (10 patients)
- Group B: Cyclosporine-induced gingival overgrowth (10 patients)
- Group C: Nifedipine-induced gingival overgrowth (5 patients).

## INCLUSION CRITERIA FOR CONTROL GROUP

1. The gingival tissue samples were obtained from systemically healthy patients who were treated for preprosthetic crown lengthening
2. Patients received no drug known to cause gingival overgrowth
3. Gingival overgrowth index (GOI) (Seymour) of zero.

## EXCLUSION CRITERIA FOR CONTROL GROUP

1. Pregnant women
2. Smokers
3. Patients with a history of systemic disease
4. Patients under any medication known to cause gingival overgrowth.

## INCLUSION CRITERIA FOR STUDY GROUP

1. Patients taking the drug (phenytoin, cyclosporine, and nifedipine) for a minimum period of 1 year and developed gingival overgrowth [Figures 1-3]
2. GOI (Seymour) of two or three.

## EXCLUSION CRITERIA FOR STUDY GROUP

1. Pregnant women
2. Gingival overgrowth caused by factors other than drug intake
3. Patients who were orthodontically treated.

## STUDY PROTOCOL

1. History, screening, consent
2. Clinical examination
3. Investigation
4. Fitness from a physician
5. Scaling
6. Biopsy
7. Immunohistochemistry
8. Statistics.

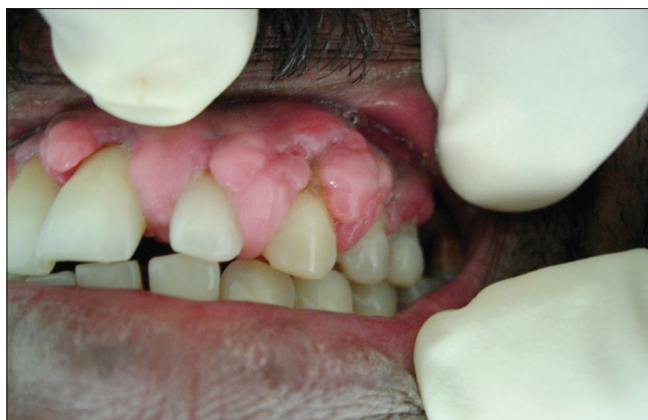Initial assessment of the selected patients was carried out by history taking. Clinical examination and assessment of gingival overgrowth were done in all patients using the index of Seymour.

GOI of 0 was taken for control and score 2 or 3 was taken for study groups done in the previous studies.

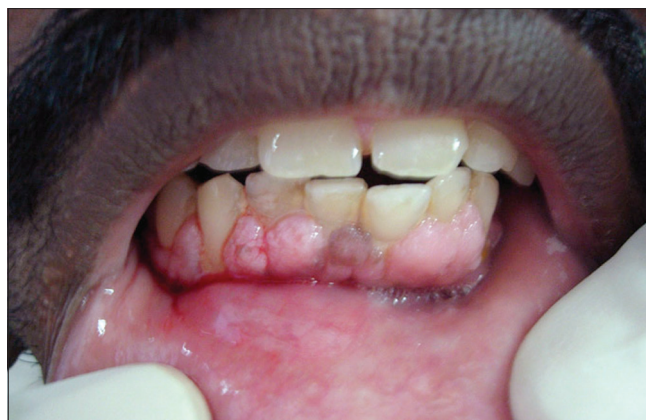## BIOPSY PROCEDURE

All the patients were made to undergo routine hematological and biochemical investigations. Before biopsy, fitness assessment and oral prophylaxis were also carried out for every patient.

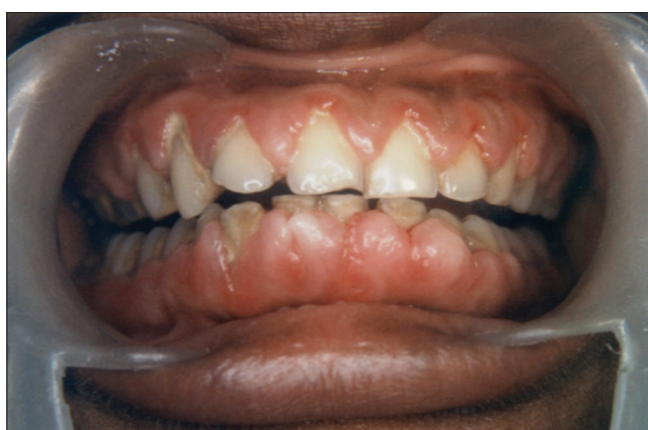After anesthetizing the sample site using 2% lignocaine hydrochloride, gingival biopsies were obtained using a Bard-Parker blade No 11 or 15. The gingival biopsy tissue samples comprised the interdental papilla, gingival margin, and attached gingiva [Figure 4]. Adequate care was taken not to damage the gingival tissue during



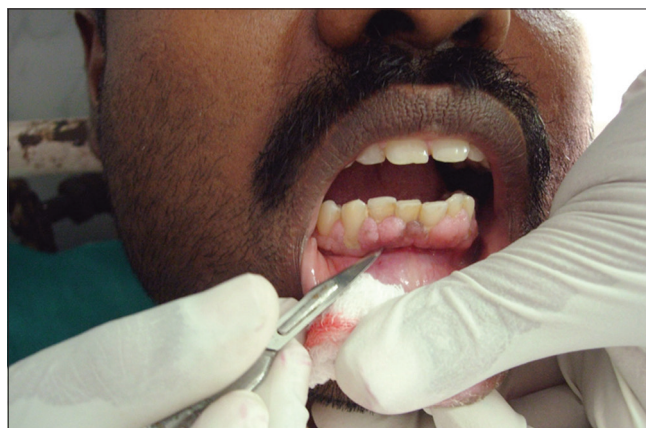**Figure 1:** Clinical case (Study Group A). Phenytoin-induced gingival overgrowth



**Figure 2:** Clinical case (Study Group B). Cyclosporine-induced gingival overgrowth



**Figure 3:** Clinical case (Study Group C). Nifedipine-induced gingival overgrowth



**Figure 4:** Biopsy procedure

biopsy. Immediately after excision, the gingival tissue samples were collected in sterile bottle with 10% formalin and labeled [Figure 5].

#### SLIDE PREPARATION

The tissue samples, which were fixed in 10% neutral-buffered formalin, were embedded in paraffin and mounted on wax blocks before slide preparation.

The glass slides were precoated with 1% poly-L-lysine in aqueous water solution and then air-dry. With the help of a microtome, tissue sections of 4  $\mu$  were sectioned from the paraffin-embedded, formalin-fixed tissue blocks. Numbering was done for all the slides for the control and study groups to prevent any bias. Two slides were made from tissue specimen; one slide for hematoxylin and eosin (H and E) staining and one slide for immunohistochemistry.

#### ANTIBODIES USED FOR IMMUNOHISTOCHEMISTRY

1. Primary antibody – CTGF antibody, from Gene Tex, USA; rabbit polyclonal to human CTGF; dilution – 1:400

2. Secondary antibody – Histostain-Plus kits; labeled streptavidin-biotin (LAB-SA) Detection System; from Zymed Laboratories; chromogen used – 3,3'-diaminobenzidine.

#### HEMATOXYLIN AND EOSIN STAINING PROCEDURES

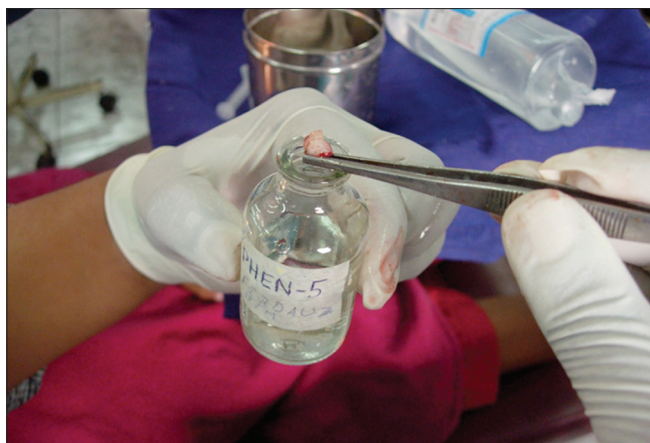
1. Dewax sections, hydrate through graded alcohols to water
2. Stain in hematoxylin for 5–10 min
3. Wash well in running tap water for 5 min
4. Differentiate in 1% acid alcohol for 5–10 s
5. Wash wells in tap water for 5 min
6. Stain in 1% eosin Y for 10 min
7. Wash in running tap water for 1–5 min
8. Dehydrate through alcohols; clear and mount.

H and E staining are carried out to investigate gingival hyperplasia and fibrosis under microscope.

The data collected by immunohistochemistry were analyzed statistically using Kruskal–Wallis and Mann–Whitney test.

#### STATISTICS ANALYSIS

The statistical package SPSS PC+ (Statistical Package for the Social Sciences, version 4.01, by IBM) was



**Figure 5:** Gingival tissue sample transferred into 10% formalin

used for statistical analysis. The mean values and test of significance were obtained using the Kruskal–Wallis ( $H$ -test) and Mann–Whitney test. The Kruskal–Wallis test is used to compare one group with several groups using the formula:

$$H = \frac{12}{N(N+1)} \sum_{j=1}^3 \frac{R_j^2}{n_j} - 3(N+1)$$

Where  $H$  is statistical significance,  $R_j$  is the sum of ranks of the sample,  $N_j$  is the size of sample  $j$ ,  $N$  is the size of the pooled sample.

Mann–Whitney test is used to compare the observations of two samples. Let  $n_1$  is the size of first sample,  $n_2$  the size of second sample,  $N = n_1 + n_2$ . Let  $R_1$  be the sum of ranks of observations of the first sample and  $R_2$  be the sum of the ranks of observations of the second sample. The mean is calculated using the formula:

$$\mu_U = \frac{n_1 n_2}{2}$$

$$\sigma_U^2 = \frac{n_1 n_2 (n_1 + n_2 + 1)}{12}$$

Where  $\mu_U$  is mean and  $\sigma_U^2$  is variance.

In the present study,  $P < 0.05$  was considered as the level of significance.

## RESULTS

Thirty-five patients selected for the study were divided into control (10) and study group (25). The study group was further divided into 10 patients in Group A (phenytoin), 10 patients in Group B (cyclosporine), and 5 patients in Group C (nifedipine).

H and E-stained sections were made from all study samples and reveal gingival hyperplasia with dense,

elongated, and thin rete pegs inserted in deep connective tissue. The fibrosis and CTGF-positive staining were more in study group than in control group. The phenytoin group (10 patients) was found to be more hyperplastic and fibrotic and also more positive for CTGF when compared with nifedipine (5 patients) and cyclosporine (10 patients).

Two qualified pathologists analyzed the results of immunohistochemistry, and all the slides were numbered to prevent any bias in the process.

Table 1 shows the immunohistochemical staining characteristic in control where few cases have taken negative and few positive staining, and none of them had taken strongly positive staining. Tables 2-4 show staining characteristic of phenytoin-, cyclosporine-, and nifedipine-induced gingival overgrowth taking positive and strongly positive staining, and very few cases had taken negative staining.

Table 5 depicts the mean values in control and study groups, by applying Kruskal–Wallis test and the  $P$  values indicating the statistical significance in study group when compared to control group.

Graph 1 shows the graphical expression of the data, wherein the study group (phenytoin, nifedipine, and cyclosporine) shows more CTGF expression in comparison to control group.

Table 6 [Graph 2] shows the outcome of Mann–Whitney test to compare the control and study Group A (phenytoin). A value of  $P < 0.05$  indicates that there is a statistical significance which is maximum in connective tissue, followed by epithelium and the blood vessel.

Similar to the previous, Table 7 [Graphs 3] and Table 8 [Graph 4] show the results of Mann–Whitney test made to compare control with study Group B (cyclosporine) and study Group C (nifedipine) respectively. The  $P$  values show that there is maximum significance of CTGF staining in phenytoin, followed by nifedipine and cyclosporine.

## DISCUSSION

The clinical appearance of gingival overgrowth is a common and well-documented side effect, following the prescribed use of calcium channel blockers, anticonvulsants, and immunosuppressant used, respectively, to manage hypertension, epilepsy, and organ transplant situations.

The fact that these drugs are extensively prescribed by doctors to manage common conditions such as hypertension and epilepsy makes the understanding of the role of CTGF in gingival overgrowth very important as a precise mode to manage the condition.

**Table 1: Staining characteristic for control group**

Serial number	Name	Age	Sex	Seymour index	Hematoxylin and eosin staining hyperplasia	Immunohistochemical staining		
						Epithelium	Connective tissue	Blood vessel
1	Case 1	31	Female	0	Absent	1	0	0
2	Case 2	21	Male	0	Absent	0	0	0
3	Case 3	19	Male	0	Absent	1	0	0
4	Case 4	21	Male	0	Absent	1	1	1
5	Case 5	19	Male	0	Absent	1	0	0
6	Case 6	24	Female	0	Absent	1	1	1
7	Case 7	26	Male	0	Absent	0	0	0
8	Case 8	31	Male	0	Absent	0	0	0
9	Case 9	31	Male	0	Absent	0	0	0
10	Case 10	34	Male	0	Absent	1	0	0

Interpretation of score: Negative=0, Positive=1, Strongly positive=2

**Table 2: Staining characteristic for study Group A (phenytoin)**

Serial number	Name	Age	Sex	Seymour index	Hematoxylin and eosin staining hyperplasia	Immunohistochemical staining		
						Epithelium	Connective tissue	Blood vessel
1	Case 11	53	Male	3	Present	2	1	1
2	Case 12	49	Female	3	Present	1	2	0
3	Case 13	43	Male	3	Present	2	2	1
4	Case 14	46	Male	2	Present	1	1	1
5	Case 15	37	Male	3	Present	1	1	1
6	Case 16	52	Female	3	Present	1	1	0
7	Case 17	43	Male	3	Present	1	1	1
8	Case 18	49	Male	2	Present	2	2	1
9	Case 19	49	Female	3	Present	1	1	1
10	Case 20	52	Male	3	Present	1	1	0

Interpretation of score: Negative=0, Positive=1, Strongly positive=2

**Table 3: Staining characteristic for study Group B (cyclosporine)**

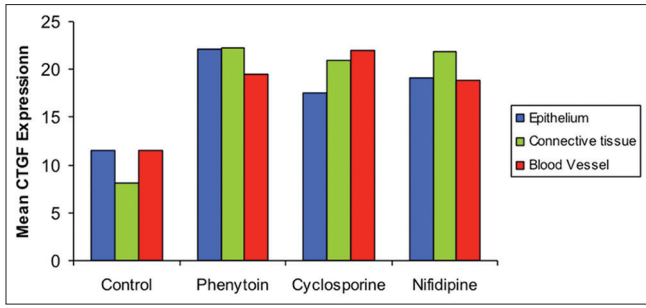
Serial number	Name	Age	Sex	Seymour index	Hematoxylin and eosin staining hyperplasia	Immunohistochemical staining		
						Epithelium	Connective tissue	Blood vessel
1	Case 21	19	Male	3	Present	1	2	1
2	Case 22	32	Male	3	Present	1	2	1
3	Case 23	19	Male	3	Present	1	2	1
4	Case 24	27	Male	2	Present	1	1	1
5	Case 25	28	Male	3	Present	1	1	1
6	Case 26	24	Male	2	Present	1	0	1
7	Case 27	29	Male	3	Present	1	0	0
8	Case 28	27	Male	2	Present	1	2	0
9	Case 29	33	Female	3	Present	1	1	1
10	Case 30	37	Male	3	Present	1	1	1

Interpretation of score: Negative=0, Positive=1, Strongly positive=2

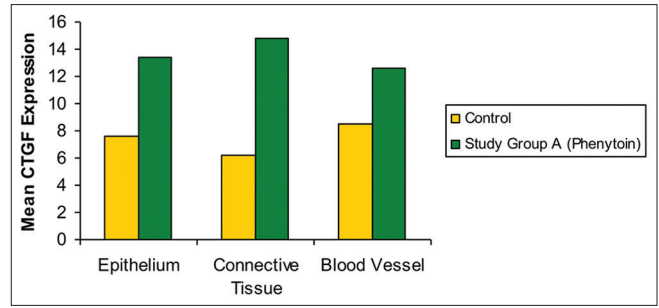
**Table 4: Staining characteristic for study Group C (nifedipine)**

Serial number	Name	Age	Sex	Seymour index	Hematoxylin and eosin staining hyperplasia	Immunohistochemical staining		
						Epithelium	Connective tissue	Blood vessel
1	Case 31	54	Female	2	Present	1	1	1
2	Case 32	49	Male	3	Present	2	2	1
3	Case 33	41	Male	3	Present	2	1	1
4	Case 34	52	Male	2	Present	1	1	1
5	Case 35	42	Male	3	Present	1	1	0

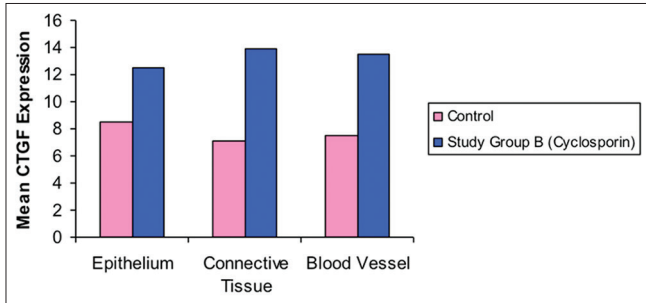
Interpretation of score: Negative=0, Positive=1, Strongly positive=2



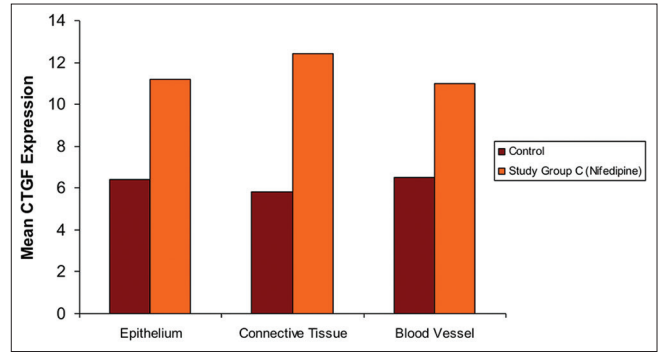
**Graph 1:** Comparative immunohistochemical staining between control and study groups



**Graph 2:** Comparative immunohistochemical staining between control and phenytoin (Group A)



**Graph 3:** Comparative immunohistochemical staining between control and cyclosporine (Group B)



**Graph 4:** Comparative immunohistochemical staining between control and nifedipine (Group C)

**Table 5: The mean value in control and study groups and their test of significance using Kruskal-Wallis test**

Group	Epithelium	Connective tissue	Blood vessel
Control group	11.50	8.10	11.50
Group A (phenytoin)	22.15	22.25	19.50
Group B (cyclosporine)	17.50	20.90	22.00
Group C (nifedipine)	19.10	21.90	18.90
<i>P</i>	0.0063	0.0015	0.0349

$P \leq 0.05$  means it is significant

**Table 6: The mean and *P* value of Mann-Whitney test of control and study Group A (phenytoin)**

	Control	Study Group A (phenytoin)	<i>P</i>
Epithelium	7.60	13.40	0.0096
Connective tissue	6.20	14.80	0.0004
Blood vessel	8.50	12.56	0.752

**Table 7: Mean and *P* value of Mann-Whitney test of control and study Group B (cyclosporine)**

	Control	Study Group B (cyclosporine)	<i>P</i>
Epithelium	8.50	12.50	0.293
Connective tissue	7.10	13.90	0.0051
Blood vessel	7.50	13.50	0.0089

In this study, our goal was to establish a relation between the use of these commonly prescribed drugs (phenytoin, cyclosporine, and nifedipine) and the increase in the concentration of CTGF in response to their usage, which

can lead to a better clinical application of the drugs and also the necessary drug changes.

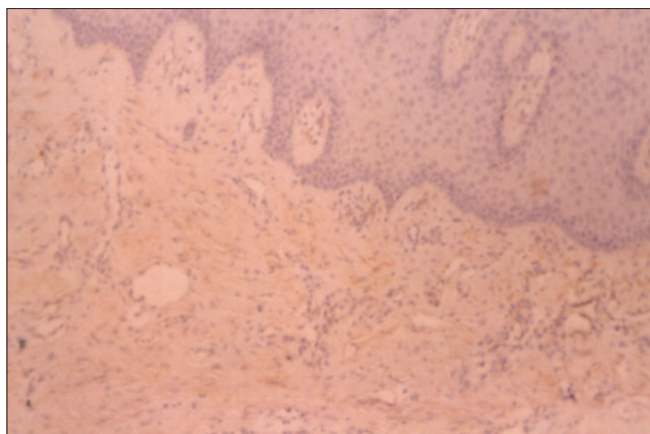
Several analyses<sup>[4,8]</sup> have indicated that, of the twenty drugs known to cause DIGO, phenytoin, cyclosporine, and nifedipine account for 90% of the gingival overgrowth associated to drug therapy. The pathogenic mechanism that induces DIGO has been studied by numerous authors.<sup>[9-12]</sup> It has resulted in a better understanding on the development of DIGO and its subsequent management.

Many authors<sup>[13,14]</sup> have documented alteration in the cytokines such as interleukin 2 (IL2), IL6, PDGF, TGFβ, and CTGF in DIGO.

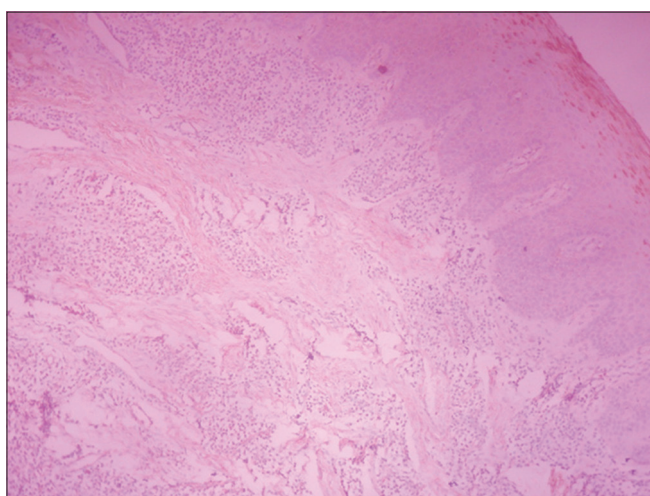
In concurrence with the current study, Uzel<sup>[4]</sup> *et al* stated about the elevated level of CTGF in DIGO in various fibrotic disorders. However, as the number of analysis to statistically document the role of CTGF in DIGO<sup>[1,3]</sup> has been limited, we undertook the present study to further strengthen the data on the role of CTGF in the expression of drug-induced gingival enlargement.

Similar to the previous studies,<sup>[1,3]</sup> the gingival samples for control group were taken from healthy patients who were treated for preprosthetic crown lengthening.

In the present study, GOI of Seymour<sup>[15]</sup> was used as it has been found to be more accurate and sensitive to assess DIGO.



**Figure 6:** Control group taking negative staining for connective tissue growth factor

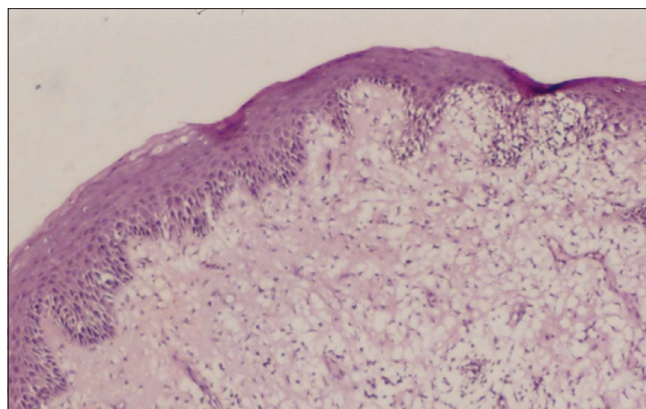


**Figure 8:** Study Group A (phenytoin) taking up positive staining for connective tissue growth factor (magnification X)

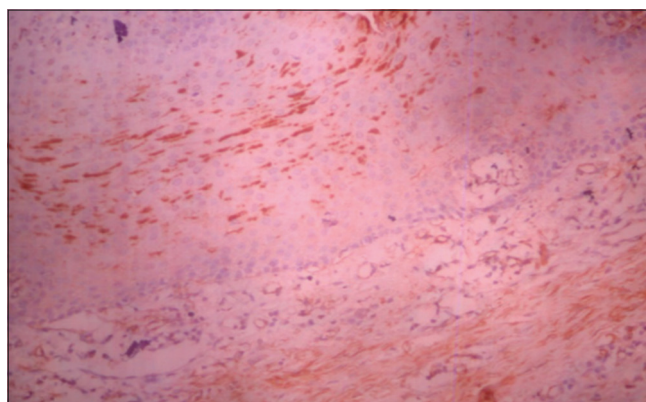
Of the various immunohistochemical methods, study with the second-generation LAB-SA is found to be more sensitive and has the least cross-reactivity and is more reliable. Hence, LAB-SA method has been used in the present study. Previous research<sup>[3]</sup> on the role of CTGF has used the first generation avidin-biotin method (ABC method).

Similar to the previous literature,<sup>[1,3]</sup> all tissues were stained with H and E. The sections reveal gingival hyperplasia with dense, elongated, and thin rete pegs inserted in deep connective tissue, which were more in phenytoin group followed by nifedipine and cyclosporine group. All control slides reveal histologically healthy gingiva in the absence of hyperplasia and fibrosis [Figures 6-15].

In the current study, the histochemical evaluation showed that CTGF staining using CTGF polyclonal antibody was more in the case of the study group compared to the control group. The study group showed a statistical



**Figure 7:** Hematoxylin and eosin staining of control group



**Figure 9:** Study Group A (phenytoin) taking up positive staining for connective tissue growth factor (magnification 3X)

**Table 8: Mean and P value of Mann-Whitney test of control and study Group C (nifedipine)**

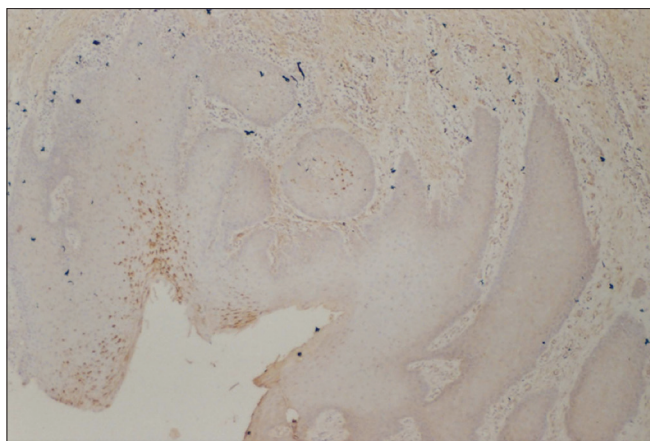
	Control	Study Group C (nifedipine)	P
Epithelium	6.40	11.20	0.0252
Connective tissue	5.80	12.40	0.0028
Blood vessel	6.50	11	0.0308

significance ( $P < 0.05$ ) in agreement with the previous study by Uzel *et al.*<sup>[3]</sup>

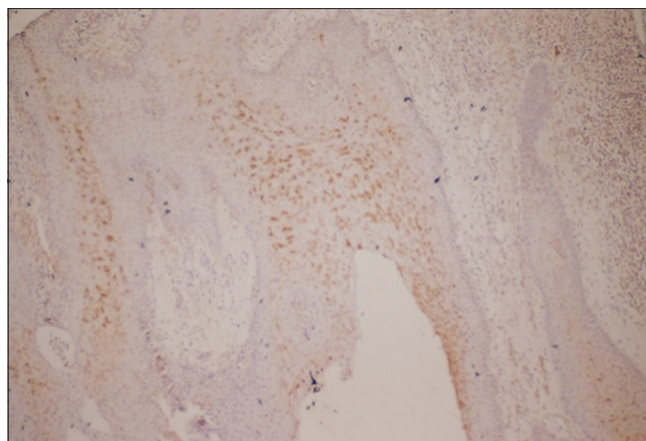
In the present study, statistical analysis was done using Kruskal–Wallis test and Mann–Whitney test as done in previous research.<sup>[3]</sup>

The intensity of CTGF staining was maximum in phenytoin followed by nifedipine and cyclosporine similar to the study by Uzel. In their study,<sup>[3]</sup> they have stated that cyclosporine-induced gingival overgrowth is more inflamed and less fibrotic; hence, it has minimal CTGF staining.

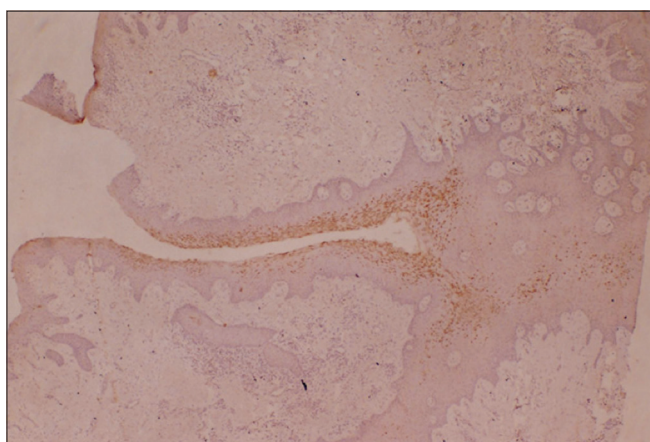
Since DIGO is attributed to alterations in profibrotic cytokines such as TGF $\beta$ , insulin growth factor I, CTGF, as well as other pro-inflammatory cytokines such as



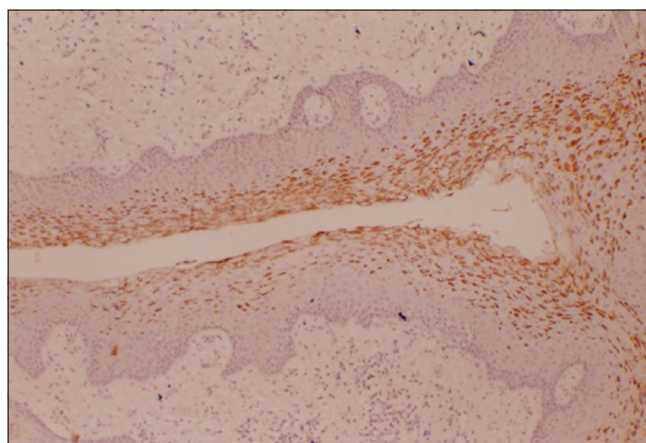
**Figure 10:** Study Group B (cyclosporine) taking positive staining for connective tissue growth factor (magnification X)



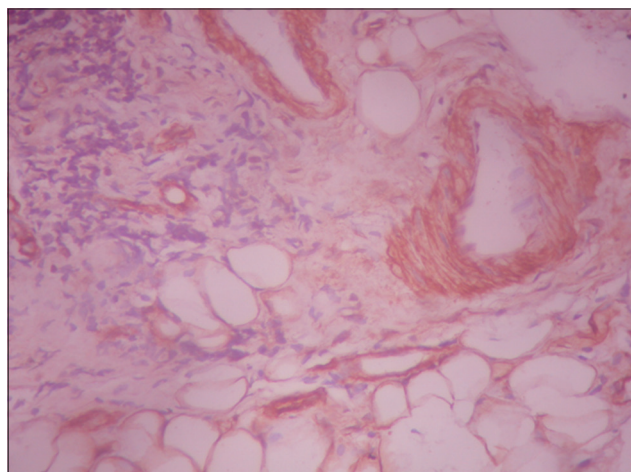
**Figure 11:** Study Group B (cyclosporine) taking positive staining for connective tissue growth factor (magnification 3X)



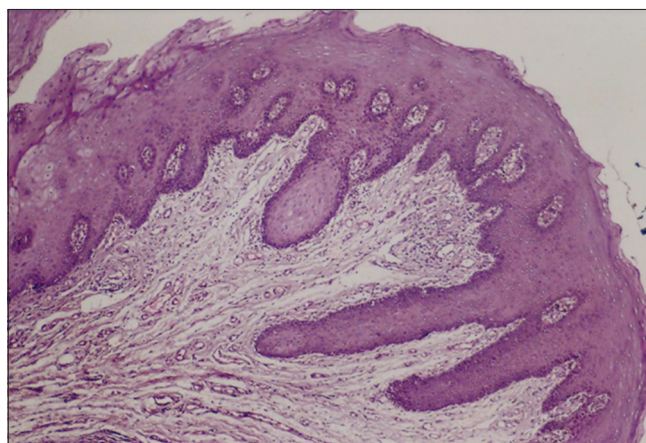
**Figure 12:** Study Group C (nifedipine) taking positive staining for connective tissue growth factor (magnification X)



**Figure 13:** Study Group C (nifedipine) taking positive staining for connective tissue growth factor (magnification 3X)



**Figure 14:** Blood vessel taking positive staining for connective tissue growth factor



**Figure 15:** Hematoxylin and eosin staining of phenytoin-induced gingival overgrowth

IL1 and IL6,<sup>[16,19]</sup> further multifactorial studies have to be done with more sample size so as to get an assertive knowledge about the role played by proinflammatory and profibrotic cytokines and the extent of DIGO.

## CONCLUSION

The expression of CTGF in the DIGO was maximum in phenytoin followed by nifedipine and cyclosporine.

The current study helps in shedding some light on the threshold of the drug quantity that can result in clinical



manifestation of DIGO. This knowledge is necessary as expression of DIGO many times depend on the susceptibility of the host to a particular drug and also the quantity of the drug being administered.

In the course of this study, with the help of immunohistochemical methods, we found that in the clinical cases of DIGO (study group), the concentration of CTGF was maximum in the case of patients using phenytoin followed by those using nifedipine and cyclosporine.

Though more elaborate and larger scale research can be carried out, the result of this study provides a clinical idea regarding which drug usage results in more CTGF production, thereby enabling the clinician to make more effective drug choice or changes.

Increasing the sample size and analyzing the response of growth factors to different drug combinations, in this regard, can further enhance our understanding on the management of DIGO. As stated previously, future research can be made more multifactorial in nature to provide a much wider and inclusive data on the clinical manifestation as well as management of DIGO.

#### DECLARATION OF PATIENT CONSENT

The authors certify that they have obtained all appropriate patient consent forms. In the form the patient(s) has/have given his/her/their consent for his/her/their images and other clinical information to be reported in the journal. The patients understand that their names and initials will not be published and due efforts will be made to conceal their identity, but anonymity cannot be guaranteed.

#### FINANCIAL SUPPORT AND SPONSORSHIP

Nil.

#### CONFLICTS OF INTEREST

There are no conflicts of interest.

#### REFERENCES

- Hong HH, Uzel MI, Duan C, Sheff MC, Trackman PC. Regulation of lysyl oxidase, collagen, and connective tissue growth factor by TGF-beta and detection in human gingiva. *Cytokines* 1999;79:1655-67.
- Bharti V, Bansal C. Drug-induced gingival overgrowth: The nemesis of gingiva unravelled. *J Indian Soc Periodontol* 2013;17:182-7.
- Ramírez-Rámiz A, Brunet-Llobet L, Lahor-Soler E, Miranda-Rius J. On the cellular and molecular mechanisms of drug-induced gingival overgrowth. *Open Dent J* 2017;11:420-35.
- Uzel MI, Kantarci A, Hong HH, Uygur C, Sheff MC, Firatli E, et al. Connective tissue growth factor in drug-induced gingival overgrowth. *J Periodontol* 2001;72:921-31.
- Hatahira H, Abe J, Hane Y, Matsui T, Sasaoka S, Motooka Y, et al. Drug-induced gingival hyperplasia: A retrospective study using spontaneous reporting system databases. *J Pharm Health Care Sci* 2017;3:19.
- Bradham DM, Igarashi A, Potter RL, Grotendorst GR. Connective tissue growth factor: A cysteine-rich mitogen secreted by human vascular endothelial cells is related to the SRC-induced immediate early gene product CEF-10. *J Cell Biol* 1991;114:1285-94.
- Brigstock DR. The connective tissue growth factor/cysteine-rich 61/nephroblastoma overexpressed (CCN) family. *Endocr Rev* 1999;20:189-206.
- Hunasgi S, Koneru A, Vanishree M, Manvikar V. Assessment of reactive gingival lesions of oral cavity: A histopathological study. *J Oral Maxillofac Pathol* 2017;21:180.
- Ponnaiyan D, Jegadeesan V. Cyclosporine A: Novel concepts in its role in drug-induced gingival overgrowth. *Dent Res J (Isfahan)* 2015;12:499-506.
- Sunil PM, Nalluswami JS, Sanghar SJ, Joseph I. Nifedipine-induced gingival enlargement: Correlation with dose and oral hygiene. *J Pharm Bioallied Sci* 2012;4:S191-3.
- Sharma PK, Misra AK, Chugh A, Chugh VK, Gonnade N, Singh S, et al. Gingival hyperplasia: Should drug interaction be blamed for? *Indian J Pharmacol* 2017;49:257-9.
- Ranga Rao S, Subbarayan R, Ajitkumar S, Murugan Girija D. Increased advanced oxidation protein products generation by cyclosporine-A and angiotensin II in human gingival fibroblasts – *Ex-vivo* study. *J Clin Diagn Res* 2017;11:ZC49-52.
- Seymour RA, Jacobs DJ. Cyclosporine and the gingival tissue. *J Clin Periodontol* 1992;19:1-11.
- Trackman PC, Kantarci A. Connective tissue metabolism and gingival overgrowth. *Crit Rev Oral Biol Med* 2004;15:165-75.
- Firs Kop T. Drug induced gingival overgrowth – Review. *BDJ* 1987;184:305-8.
- Iacopino AM, Doxey D, Cutler CW, Nares S, Stoeber K, Fojt J, et al. Phenytoin and cyclosporine A specifically regulate macrophage phenotype and expression of platelet-derived growth factor and interleukin-1 *in vitro* and *in vivo*: Possible molecular mechanism of drug-induced gingival hyperplasia. *J Periodontol* 1997;68:73-83.
- Modéer T, Domeij H, Andurén I, Mustafa M, Brunius G. Effect of phenytoin on the production of interleukin-6 and interleukin-8 in human gingival fibroblasts. *J Oral Pathol Med* 2000;29:491-9.
- Seymour RA, Ellis JS, Thomason JM. Risk factors for drug-induced gingival overgrowth. *J Clin Periodontol* 2000;27:217-23.
- Suneja B, Chopra S, Thomas AM, Pandian J. A clinical evaluation of gingival overgrowth in children on antiepileptic drug therapy. *J Clin Diagn Res* 2016;10:ZC32-6.