



## Case report

Skin and soft tissue infection caused by *Basidiobolus* spp. in Australia

Te-Yu Hung<sup>a,b,\*</sup>, Brooke Taylor<sup>a</sup>, Aijye Lim<sup>c</sup>, Robert Baird<sup>a</sup>, Joshua R. Francis<sup>b,e</sup>, Sarah Lynar<sup>d,e</sup>



<sup>a</sup> Department of Microbiology, Territory Pathology, Royal Darwin Hospital, 105 Rocklands Drive Tiwi, Northern Territory, 0810, Australia

<sup>b</sup> Department of Paediatrics, Royal Darwin Hospital, Northern Territory, 0810, Australia

<sup>c</sup> Department of Anatomical Pathology, Territory Pathology, Royal Darwin Hospital, Tiwi, Northern Territory, 0810, Australia

<sup>d</sup> Department of Infectious Diseases, Royal Darwin Hospital, Northern Territory, 0810, Australia

<sup>e</sup> Menzies School of Health Research, Charles Darwin University, Northern Territory, 0810, Australia

## ARTICLE INFO

## Article history:

Received 1 August 2019

Received in revised form 23 February 2020

Accepted 23 February 2020

## Keywords:

*Basidiobolus*

Entomophthorales

Entomophthoramycesis

## ABSTRACT

Fungi from the order Entomophthorales are rare but well recognized cause of tropical fungal infection, typically causing subcutaneous truncal or limb lesions in immunocompetent hosts. They may also mimic malignancy by causing intrabdominal mass, sometimes resulting in obstructive gastrointestinal or renal presentations. A 4-year-old female presented with a progressively growing abdominal wall lesion over several months, developing into acute inflammation of the abdominal wall with systemic symptoms. She underwent surgical debridement and fungal culture of subcutaneous tissue was positive for *Basidiobolus* spp with characteristic histopathological findings. Treatment with voriconazole followed by itraconazole over a total duration of 6 weeks led to complete resolution.

*Basidiobolus* spp is an unusual cause of infection with characteristic mycological and histopathological findings. Infection can present in a number of ways ranging from a slow-growing mass in the subcutaneous soft tissue to an invasive mass in the gastrointestinal tract. Identification of its unique beak-like zygosporangium and Splendore-Hoeppli phenomenon on histopathological specimens can be pathognomonic and could provide the key to early diagnosis. Review of the literature found that timely diagnosis and commencement of antifungal therapy can be curative with or without surgical treatment. Considering the rarity of this tropical infection, this case provides the opportunity for revision of the typical presentations and diagnostic findings of *Basidiobolus* spp. With early recognition and suitable treatment, outcomes are generally favorable.

© 2020 Published by Elsevier Ltd. This is an open access article under the CC BY-NC-ND license (<http://creativecommons.org/licenses/by-nc-nd/4.0/>).

## Introduction

Entomophthoramycesis, caused by fungi from the order Entomophthorales, is a known tropical fungal infection typically causing gastrointestinal or subcutaneous truncal and limb lesions in immunocompetent hosts. The organism is described as a commensal in the intestinal tracts of various insects, wood lice, frogs and small reptiles, and has been isolated from decaying vegetation and animal feces [1].

Two previous cases have been described in the Top End region of the Northern Territory of Australia, with other reports from tropical regions of Asia, Africa, North and South America [2–13]. The literature includes unusual presentations of *Basidiobolus* spp. causing intra-abdominal obstructive lesions of the gastrointestinal and renal tracts

(Table 1). Due to the rarity of disease, recognition of the microbiological and histopathological features can be challenging.

Here we present a third case in the Top End taking the opportunity to review the literature and discuss diagnostic challenges and recommended clinical management for this unusual tropical pathogen.

## Case report

A 4-year old girl from a remote community 950 km south-east of Darwin was transferred to a tertiary hospital with fever and painful swelling on the right lateral aspect of the abdominal wall. This had begun as a carbuncle-like lesion with a black center and had become progressively larger over several months. She was previously well with no significant past medical history and was on no regular medications. Her vaccinations were up to date as per the Australian National Immunization Schedule.

On arrival, she was febrile and physical examination revealed a woody, firm right-sided abdominal wall induration extending from

\* Corresponding author at: BC Children's Hospital, Oak Street, Vancouver, University of British Columbia, Canada.

E-mail address: [tyhung@telstra.com](mailto:tyhung@telstra.com) (T.-Y. Hung).

**Table 1**  
Summary of published case reports and series of *Basidiobolus* spp infections, clinical presentation, treatment and outcome.

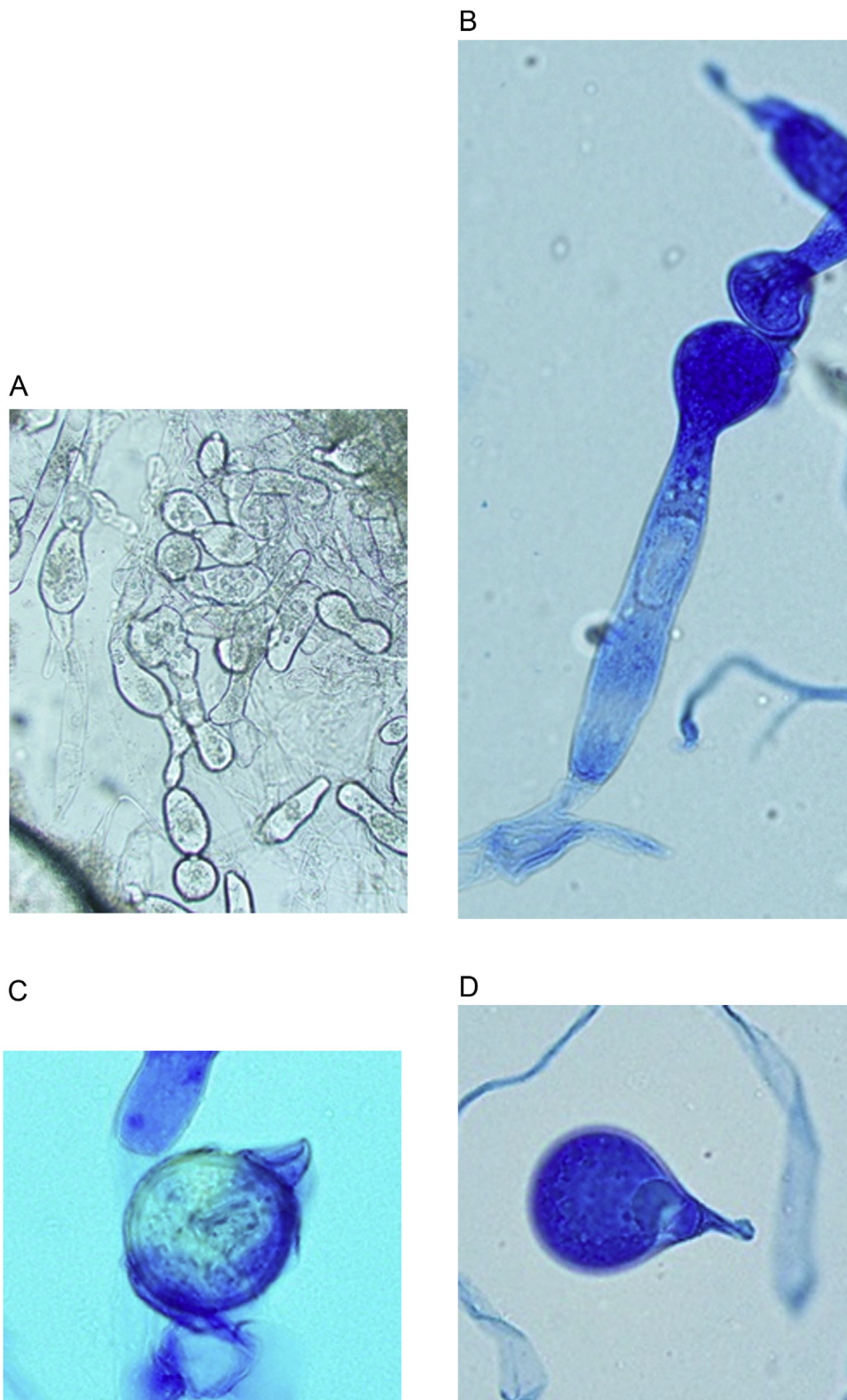
Reference	Year	Country	Age (years)/ Sex	Site of Infection	Surgery	Antifungal therapy/ route/ duration	Outcome
van den Berk GEL	2006	The Netherlands	61 M	Gastrointestinal	Colonoscopy, hemicolectomy	Amphotericin B	deceased
Singh R	2008	India	11 F	Nasal cavity with extension into ethmoid, maxillary sinuses and extradural extension	Nasal and sinus endoscopy with biopsy	Unknown	Lost to follow-up
Anand M	2010	India	3 M	Skin- thigh	Excision	Potassium iodide/oral/1 week then Itraconazole/oral/6 months	Complete resolution
Ezzedien Rabi M	2011	South Arabia	25 F	Gastrointestinal, intramural colonic mass	Subtotal colectomy, jejunal loop resection, ileosigmoid colostomy	Itraconazole/ oral/ unknown duration	Complete resolution
Al Jarie A.	2011	Saudi Arabia	6 M	Gastrointestinal, intrahepatic	Biopsy only	Amphotericin B then Itraconazole/oral/ unknown	Complete resolution
			13 F	Gastrointestinal Recurrence of intrabdominal mass	Laparotomy and mass resection Hemicolectomy and ileocolic anastomosis for recurrence	Initially declined antifungal therapy Recurrence treated with Amphotericin B then itraconazole/ oral/ 12 months	Complete resolution
			8 F	Gastrointestinal	Biopsy and cholecystojejunostomy	Amphotericin B then Itraconazole/ oral/ 18 months	Complete resolution
			8 M	Nasopharyngeal airway including maxillary and ethmoid sinuses	Biopsy Tracheostomy due to upper airway reconstruction	Amphotericin B then Itraconazole/ oral/ 12 months	Complete resolution
			10 M	Pulmonary	Bronchoscopy and biopsy	Amphotericin B then Voriconazole/ unknown/ unknown	Complete resolution
Gordon CL	2012	Australia	53 M	Right leg with inguinal lymphadenopathy	Skin biopsy, lymph node excision biopsy	Itraconazole/ oral/ 12 months	Complete resolution
			5 M	Right chest wall skin lesion	Skin biopsy	Terbinafine/ oral/ 12 months Fluconazole/ oral/ unknown duration	Lost to follow-up
Jayanth ST	2013	India	58 F	Skin soft tissue, right gluteal region	Excision	Potassium iodide/ oral/ 6 months	Complete resolution
Rose SR	2013	United States of America	67 M	Gastrointestinal	Biopsy, debulking	Fluconazole (unknown duration) Posaconazole/ oral/ 12 months	Complete resolution
Zabolinejad N	2014	Iran	3 M	Gastrointestinal	Laparotomy and resection	Posaconazole/ oral/ 3 months; then Itraconazole/ oral/ 12 months	Complete resolution
Albaradi BA	2014	Saudi Arabia	11 M	Gastrointestinal	Biopsy only	Voriconazole/ oral/ 12 months	Complete resolution
Saka B	2017	Togo	5 M	Skin over buttock, back and right flank	Biopsy	Ketoconazole/ oral/ 8 weeks	Complete resolution
Brun LVC	2018	Benin	3 F	Skin- right flank	Excision	None known	Complete resolution
			43 M	Skin- lower limb	Excision	None known	Deceased
			3 M	Skin- lower limb	Biopsy	None known	unknown cause deceased

the right flank anteriorly to the anterior midline, and into the suprapubic region. This was irregularly shaped and tender, with no discernible warmth on palpation. An ultrasound examination demonstrated the lesion to measure  $7 \times 2.5 \times 6$  cm in the subcutaneous layer, superficial to the abdominal wall musculature. There was no drainable fluid collection. She was commenced on empirical intravenous flucloxacillin for presumed cellulitis. Her initial full blood count showed a white cell count of 15000 cells/ $\mu$ L, normal range: 4000–11000 cells/ $\mu$ L, eosinophils 200 cells/ $\mu$ L (0–400 cells/ $\mu$ L), haemoglobin 8.4 g/dL (11–14 g/dL), platelet count 586000 cells/ $\mu$ L (150000–450000 cells/ $\mu$ L) and C-reactive protein (CRP) 8.92 mg/dL (0.0–5.0 mg/dL). Renal and liver function tests were within normal limits for age. Blood cultures and streptococcal serology were sent.

An initial tissue biopsy was taken on Day 1 of admission with no macroscopic pus found on surgical exploration. Gram stains were negative for bacterial and fungal elements and Ziehl-Nielsen stains were negative for acid-fast bacilli. Bacterial, mycobacterial and fungal cultures were all negative in the first 48 h. Initial histopathology reported non-specific chronic eosinophilic

panniculitis without granulomatous reaction. Despite empirical antibacterial therapy, the patient continued to spike high fevers up to 39 °Celsius and her CRP peaked at 16.7 mg/dL on day 11 of admission. Her abdominal wall lesion continued to enlarge, increasingly warm and tender on examination. Two further surgical debridement and tissue biopsies were performed on days 6 and 10 of admission. On Day 4 of incubation on Sabouraud dextrose agar at 30°C; one flat, radially folded grey colony was observed. With further incubation an off-white powdery mycelium became apparent, along with small satellite colonies surrounding the primary colony. This demonstrated the germinating conidia being forcibly ejected from the primary colony. This is typical of fungi from the Entomophthorales group.

Microscopic examination showed large irregular, non-septate hyphae with numerous smooth, round, thick-walled zygospores possessing a distinct beak-like appendage characteristic of *Basidiobolus* species (Fig. 1.A, B, C). Histopathology revealed characteristic Splendore-Hoeppli phenomenon on haematoxylin and eosin (H&E) staining, consisting of granulation tissue surrounding short or long, broad, ribbon-type sparsely septated hyphae, surrounded by

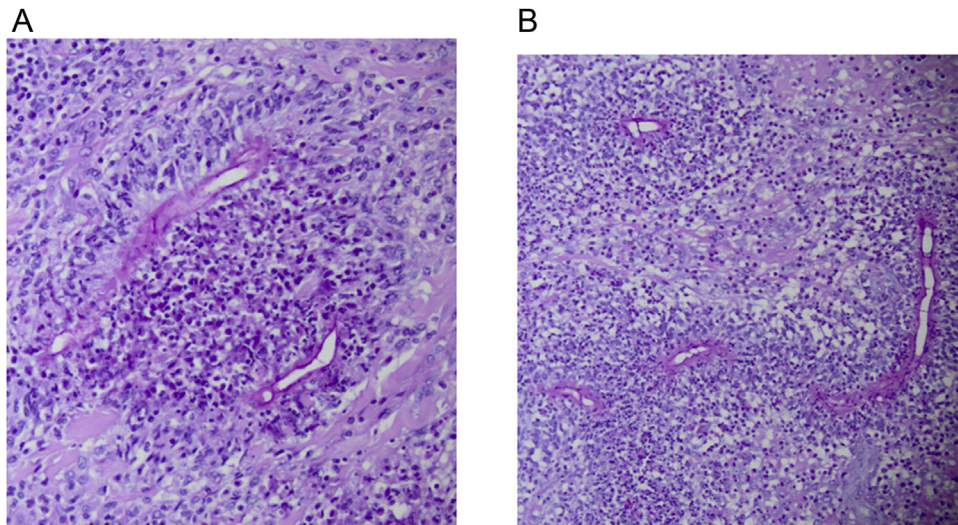


**Fig. 1.** A) This wet preparation mount is showing sporangiophore containing terminal sporangia which is forcibly discharged, a characteristic feature observed in *Basidiobolus* species. B) This lactophenol cotton blue stain is showing the same sporangiophore. C) Lactophenol cotton blue stain demonstrating the characteristic beak-like appendage of a thick-walled zygospore. D) Conidia may be primary or secondary.

eosinophils, lymphocytes and giant cells (Fig. 2.A–B). There was no evidence of angioinvasion on histological specimens.

Broad-spectrum antifungal therapy with liposomal amphotericin B (5 mg/kg daily) was commenced, then changed to intravenous

voriconazole after 24 h due to immediate hypersensitivity reaction causing lip and throat swelling. The patient defervesced within 24 h of commencing antifungal treatment, with marked improvement in skin induration, warmth and tenderness over 2 weeks of intravenous



**Fig. 2.** A and B) Histopathology with H&E stain is demonstrating the Splendore-Hoeppli phenomenon which is describing the intense eosinophilic inflammatory surrounding the ribbon-like hyphae which are sparsely septated.

voriconazole therapy (9 mg/kg 12 hourly for 1 week, then 6 mg/kg every 12 h for 1 week). There were no significant adverse effects noted while on voriconazole.

The patient was discharged home with oral itraconazole (5 mg/kg daily) and completed a total of 6 weeks of combined antifungal therapy. She had complete resolution of the abdominal wall induration by the end of treatment, and her surgical scars were well healed.

The fungal isolate was referred to the National Mycology Reference Laboratory in South Australia, where 18 s sequencing confirmed *Basidiobolus* species.

## Discussion

Entomophthoromycosis derives its origin from Greek meaning “insect destroyer” and refers to the ubiquitous nature of the spores in nature. Due to the zoonotic nature of the *Basidiobolus* and *Conidiobolus* genera, these were separated from their previous phylum of Zygomycota (since renamed). The newly created phylum Entomophthoromycota now comprises Basidiobolomycetes (*Basidiobolus* spp.), Neozygitomycetes (*Neozygites* spp.) and Entomophthoromycetes (including *Conidiobolus* spp., *Completozia* spp., and *Entomophthora* spp.) [15].

*Basidiobolus ranarum* was first described by Eidam in 1886 from frog excrement (1886) [1]. Since then, *Basidiobolus microspores*, *B. lacerate*, *B. haptosporus* (1947) and *B. meristosporus* (1956) have all been described as part of the *B. ranarum* species. Genomic sequencing analysis published by Henk and Fisher (2012) estimated the *B. ranarum* genome to be approximately 10 times larger than the average fungal pathogen at 700 Mb [18]. The authors postulate that *B. ranarum* may have mechanisms that favor the preservation of functional genes which overlap.

Both *Basidiobolus* and *Conidiobolus* spp. are thermophilic fungi and are commonly found on the skin of insects or animals in warm and humid environment [19]. Reported amongst the most aggressive pathogens of insects, *Basidiobolus* spp. invade the

whole insect body, at which point amphibians and reptiles acquire the fungus by insect ingestion. They are only occasional human pathogens, with acquisition via insect bites to the skin or by minor trauma.

In humans, *B. ranarum* typically causes subcutaneous infections involving the trunk, buttock, thigh and perineal areas. This is in contrast to *Conidiobolus* spp. which cause rhinoentomophthoromycosis involving the nasal and paranasal mucocutaneous tissues [17]. Gastrointestinal infections have also been described, leading to subacute or chronic obstruction, as well as renal tract obstruction. Infection can form slow-growing bulky tumors mimicking malignancy, often requiring surgical procedures to relieve obstruction or mass effect [2–13]. Other infectious differential diagnoses include sporotrichosis, actinomycosis, non-tuberculous *Mycobacterium* infection, invasive mucormycosis and cutaneous filariasis. However, the finding of angioinvasive disease in the setting of fungal growth can help confirm the diagnosis.

Diagnosis of *Basidiobolus* infection is typically by microbiological culture with associated typical histopathological features. Our wet mount preparation with lactophenol cotton-blue stain found the characteristic beaked-spores on fungal microscopy (Fig. 1.A and B). Two types of asexual conidia were observed: primary and secondary. The primary form of conidia was globose and single celled, being forcibly discharged from the swollen region of the sporophore just below the conidium. The sporophores releasing the secondary form of conidia did not possess a swollen area, indicating the conidia were being passively released. These secondary forms of conidia were clavate and single celled with a typical knob-like adhesive tip at their apex (Fig. 1.D). The secondary conidia act as sporangia where further sporangiospores may be produced.

On histopathological examination, the Splendore-Hoeppli phenomenon on H&E stains describes the unique pattern of inflammatory reaction charioting the fungal hyphae. The palisading and charioting of eosinophils around the ribbon-like hyphae

**Table 2**  
Antifungal susceptibility of *Basidiobolus* species (9 isolates) and *Conidiobolus* species (8 isolates) [16].

Geometric mean MICs (mg/L) (range)	Amphotericin B	Fluconazole	Flucytosine	Itraconazole	Ketoconazole	Miconazole
<i>Basidiobolus</i> spp	2.7 (0.5–16)	14.8 (2–128)	165.9 (64–256)	1.8 (0.25–32)	1.0 (0.25–4)	3.9 (0.5–8)
<i>Conidiobolus</i> spp	3.1 (0.5–8)	107.5 (32–128)	234.6 (128–256)	11.3 (0.25–32)	20.7 (4–32)	11.3 (4–16)

can also be interspersed with multinucleated giant cells (Fig. 2A & B). This is also seen in other fungal infections such as *Coccidioides immitis*, *Sporothrix schenckii* and those that cause mycetoma [14].

In 1999, Guarro and colleagues showed in-vitro susceptibility in 9 isolates of *Basidiobolus* spp. to amphotericin B, fluconazole, flucytosine, itraconazole, ketoconazole and miconazole by a broth microdilution method. All the *Basidiobolus* isolates demonstrated low minimum inhibitory concentrations (MICs) to the azole agents which were in contrast to the *Conidiobolus* species in the same study, which showed high MICs against all antifungals tested (Table 2).

Previous case reports (Table 1) describe resolution through treatment with antifungals and without surgical intervention in isolated subcutaneous lesions only [7]. Our patient underwent several surgical debridement procedures, not only for diagnosis but as a source control measure due to persistent high fever, pain, and increasing inflammatory markers.

The literature describes 3 fatal cases of *Basidiobolus* infections amongst the 19 cases described in Table 1. Two of the patients described were from a Buruli-ulcer endemic area and both had progressive disease without antifungal therapy, although cause of death was not directly attributable to the *Basidiobolus* spp. infection [13]. The third patient had a severe obstructive bowel lesion as well as a hepatic lesion and died of septic shock despite commencing broad-spectrum antifungal therapy prior to deterioration [2].

## Conclusion

*Basidiobolus* spp. are rare but important causes of fungal infection in the tropics which can present in a number of ways ranging from a slow-growing mass in the subcutaneous soft tissue to an invasive mass in the gastrointestinal tract. Diagnosis by fungal culture and histopathological examination is crucial to provide early diagnosis. Early antifungal therapy and appropriate surgical intervention generally achieves good curative rates.

## CRedit authorship contribution statement

**Te-Yu Hung:** Conceptualization, Writing - original draft, Visualization. **Brooke Taylor:** Investigation, Visualization. **Aijye Lim:** Investigation. **Robert Baird:** Supervision, Writing - review & editing. **Joshua R. Francis:** Investigation, Supervision. **Sarah Lynar:** Conceptualization, Writing - review & editing.

## Declaration of Competing Interest

The authors have no conflicts of interest to declare.

## Acknowledgments

We thank the patient and family for permission to reproduce this case and the local health clinic staff for assistance. We thank Mr Greg Haran for mentorship, teaching and guidance in mycology.

## References

- [1] Kidd S, Halliday C, Alexious H, Ellis D. Descriptions of medical fungi. third edition Adelaide: National Mycology Reference Centre; 2016. p. 28–9. <https://mycology.adelaide.edu.au/docs/fungus3-book.pdf>.
- [2] Van den Berk GEL, Noorduyt LA, van Ketel RJ. A fatal pseudo-tumour: disseminated basidiobolomycosis. *BMC Infect Dis* 2006;6:140.
- [3] Singh R, Kessw I, Ramavat AS, Arora R. Basidiobolomycosis: a rare case report. *Indian J Med Microbiol* 2008;26:265–7.
- [4] Anand M, Deshmukh SD, Pande DP, Naik S, Ghadage DP. Subcutaneous Zygomycosis due to *Basidiobolus ranarum*: a case report from Maharashtra, India. *J Trop Med* 2010;950390.
- [5] Ezzedien Rabi M, El Hakeen I, Al-Shraim M, Saad Al Skini M, Jamil S. Basidiobolomycosis of the colon masquerading as stenotic colon cancer. *Case Rep Surg* 2011;685460.
- [6] Al Jarie A, Al Azraki T, Al Mohsen I. Basidiobolomycosis: case series. *J de Mycol Med* 2011;21:37–45.
- [7] Gordon CL, Whiting S, Haran G, et al. Entomophthoromycosis caused by *Basidiobolus ranarum* in tropical northern Australia. *Pathology* 2012;44:4.
- [8] Jayanth ST, Gaikwad P, Promila M, Muthusami JC. The Sinus that breeds fungus: subcutaneous zygomycosis caused by *Basidiobolus ranarum* at the Injection Site. *Case Rep Infect Dis* 2013;534192.
- [9] Rose SR, Lindsley MD, Hurst SF, Paddock CD, Damodaran T, Bennett J. Gastrointestinal basidiobolomycosis treated with posaconazole. *Med Mycol Case Rep* 2013;2:11–4.
- [10] Zabolinejad N, Naseri A, Davoudi Y, Joudi M, Aelami MH. Colonic basidiobolomycosis in a child: report of a culture-proven case. *Int J Infect Dis* 2014;22:41–3.
- [11] Albaradi BA, Babiker AM, Al-Qahtani HS. Successful treatment of gastrointestinal basidiobolomycosis with voriconazole without surgical intervention. *J Trop Pediatr* 2014;60(6):476–9.
- [12] Saka B, Gnassingbe W, Mahamadou G, et al. Basidiobolomycosis simulating a *Mycobacterium ulcerans* infection in a Togolese Rural Child. *Case Rep Dermatol Med* 2017;6905783.
- [13] Brun LVC, Roux JJ, Sopoh GE, et al. Subcutaneous granulomatous inflammation due to basidiobolomycosis: case reports of 3 patients in buruli ulcer endemic areas in Benin. *Case Rep Pathol* 2018;1351694.
- [14] Larone Davise H. Medically important fungi- a guide to identification. 5th edition 2020.
- [15] Mendoza L, Vilela R, voelz K, et al. Human fungal pathogens of mucorales and entomophthorales. *Cold Spring Harbour Perspect Med* 2015;5:a019562.
- [16] Guarro J, Aguilar C, Pujol I. In-vitro antifungal susceptibilities of *Basidiobolus* and *Conidiobolus* spp. Strains. *J Antimicrob Chemother* 1999;44:557–60.
- [17] Shaikh N, Hussain KA, Petraitiene R, Schuetz AN, Walsh TJ. Entomophthoramycosis: a neglected tropical mycosis. *Clin Microbiol Infect* 2016;22:688–94.
- [18] Henk DA, Fisher MC. The Gut Fungus *Basidiobolus ranarum* has a large genome and different copy numbers of putatively functionally redundant elongation factor genes. *PLoS One* 2012;7(2):e31268.
- [19] El-Shabrawi MHF, Arnaout H, Madkour L, Kamal NM. Entomophthoromycosis: a challenging emerging disease. *Mycoses* 2014;57(Suppl. 3):132–7.