

Uterine and Tubal Lavage for Earlier Cancer Detection Using an Innovative Catheter

A Feasibility and Safety Study

Elisabeth Maritschnegg, MsC, PhD, Florian Heitz, MD,† Nina Pecha, MD,* Jiri Bouda, MD,‡ Fabian Trillsch, MD,§|| Christoph Grimm, MD,* Adriaan Vanderstichele, MD,¶ Christiane Agreiter, MSc,* Philipp Harter, MD,† Eva Obermayr, MSc, PhD,* Ignace Vergote, MD,¶ Robert Zeillinger, PhD,* and Paul Speiser, MD**

Objectives: Poor survival of high-grade serous pelvic cancer is caused by a lack of effective screening measures. The detection of exfoliated cells from high-grade serous pelvic cancer, or precursor lesions, is a promising concept for earlier diagnosis. However, collecting those cells in the most efficient way while fulfilling all requirements for a screening approach is a challenge. We introduce a new catheter for uterine and tubal lavage (UtL) and the clinical evaluation of its performance.

Methods/Materials: In study I, the clinical feasibility of the UtL using the new catheter was examined in 93 patients admitted for gynecologic surgery under general anesthesia. In study II, the safety of the UtL procedure was assessed. The pain during and after the UtL performed under local anesthesia was rated on a visual analog scale by 22 healthy women.

Results: In study I, the UtL was carried out successfully in 92 (98.9%) of 93 cases by 16 different gynecologists. It was rated as easy to perform in 84.8% of patients but as rather difficult in cancer patients (odds ratio, 5.559; 95% confidence interval, 1.434–21.546; $P = 0.007$). For benign conditions, dilatation before UtL was associated with menopause status (odds ratio, 4.929; 95% confidence interval, 1.439–16.884; $P = 0.016$). In study II, the pain during UtL was rated with a median visual analog scale score of 1.6. During a period of 4 weeks after UtL, none of the participants had to use medication or developed symptoms requiring medical attention. The UtL took 6.5 minutes on average. The amount of extracted DNA was above the lower limit for a sensitive, deep-sequencing mutation analysis in all cases.

Conclusions: Our studies demonstrate that the UtL, using the new catheter, is a safe, reliable, and well-tolerated procedure, which does not require elaborate training. Therefore, UtL fulfils all prerequisites to be used in a potential screening setting.

Key Words: Early diagnosis, High-grade serous cancer, Catheter, Uterine lavage, Feasibility study

*Molecular Oncology Group, Department of Obstetrics and Gynecology, Comprehensive Cancer Center–Gynecologic Cancer Unit, Medical University of Vienna, Vienna, Austria; †Department of Gynaecology and Gynaecologic Oncology, Kliniken Essen Mitte, Essen, Germany; ‡Department of Gynecology and Obstetrics, Faculty of Medicine and University Hospital in Pilsen, Charles University in Prague, Pilsen, Czech Republic; §Department of Gynecology and Gynecologic Oncology, University Medical Center Hamburg-Eppendorf, Hamburg; ||Department of Obstetrics and Gynaecology, University Hospital, LMU Munich, Munich, Germany; and ¶Department of Gynecologic

Copyright © 2018 by IGCS and ESGO
ISSN: 1048-891X
DOI: 10.1097/IGC.0000000000001361

Oncology, Leuven Cancer Institute, University Hospitals Leuven, KU Leuven, Leuven, Belgium.

Address correspondence and reprint requests to Paul Speiser, MD, Waehringerguertel 18-20, 5Q, 1090 Vienna, Austria. E-mail: paul.speiser@meduniwien.ac.at.

This work was supported by Jubilaeumsfond, Austrian National bank (No. 15641).

Paul Speiser owns the following patents related to the current manuscript: 2013113816 A1 titled “Non-invasive cancer diagnosis” and 20170128695 A1 titled “Three lumen balloon catheter apparatus”. He is co-founder and shareholder of OVARTEC GmbH. OVARTEC GmbH has licensed the patents mentioned above. All authors declare no conflict of interest.

Received May 17, 2018, and in revised form July 7, 2018.

Accepted for publication August 19, 2018.

(Int J Gynecol Cancer 2018;28: 1692–1698)

High-grade serous pelvic cancer (HGSC) is usually diagnosed at advanced stage with a 10-year survival rate of less than 30%.¹ This is caused by a lack of early symptoms and effective screening measures. All previous attempts to establish an effective screening strategy failed in both the general and the high-risk breast and ovarian cancer (HBOC) population, for example, *BRCA* germline mutation carriers.^{2,3} To date, risk-reducing salpingo-oophorectomy (RRSO) is still considered the only way for HBOC women to reduce their risk of HGSC development. However, RRSO results in serious adverse effects. In addition to the loss of reproductive capacity, these involve different problems associated with premature menopause.^{4,5}

A new, promising diagnostic concept based on the fact that the vagina, cervical canal, uterine cavity, fallopian tubes, ovarian surface, and peritoneal cavity form a communicating space was introduced by several groups. This concept aims at detecting exfoliated cells from HGSC and the precursor lesion, serous tubal intraepithelial carcinoma (STIC).⁶ So far, the collection of these shed cells was achieved through 3 different approaches: by the use of tampons, a liquid-based Papanicolaou test and a uterine and tubal lavage (UtL). The level of invasiveness of the approaches increases in the aforementioned order. However, the results of different studies suggest that the efficiency of target cell collection

increases in the same manner,^{7–9} most probably because UtL allows cells to be collected closest to their origin.

While establishing a protocol for UtL, we encountered several problems and none of the existing catheters were able to overcome those. Problems resulted from the fact that the uterine cavity is very small and that the anterior and posterior wall lie on top of each other. Therefore, fluid that was flushed into the cavity either immediately evacuated through the tubes, or a backflow of the fluid into the vagina was noticed. In either way, the total volume of the UtL could not be recovered. Furthermore, the tip of comparable catheters frequently got clogged, and the procedure could not be continued (data not published). An innovative catheter that overcomes these technical problems has recently been developed. To demonstrate the safety of the catheter and the clinical feasibility of this diagnostic approach, 2 studies were performed.

Study I aimed at assessing the clinical feasibility of the UtL approach using the new catheter. It was conducted as a multicenter trial, and 16 clinicians reported on their experiences while performing the UtL. Furthermore, this study aimed at evaluating whether the amount of DNA isolated from the UtL specimen would be sufficient for future HGSC and/or STIC detection by sequencing of *TP53*.

Study II aimed at investigating the practicality and safety of the UtL approach as a potential screening test. The

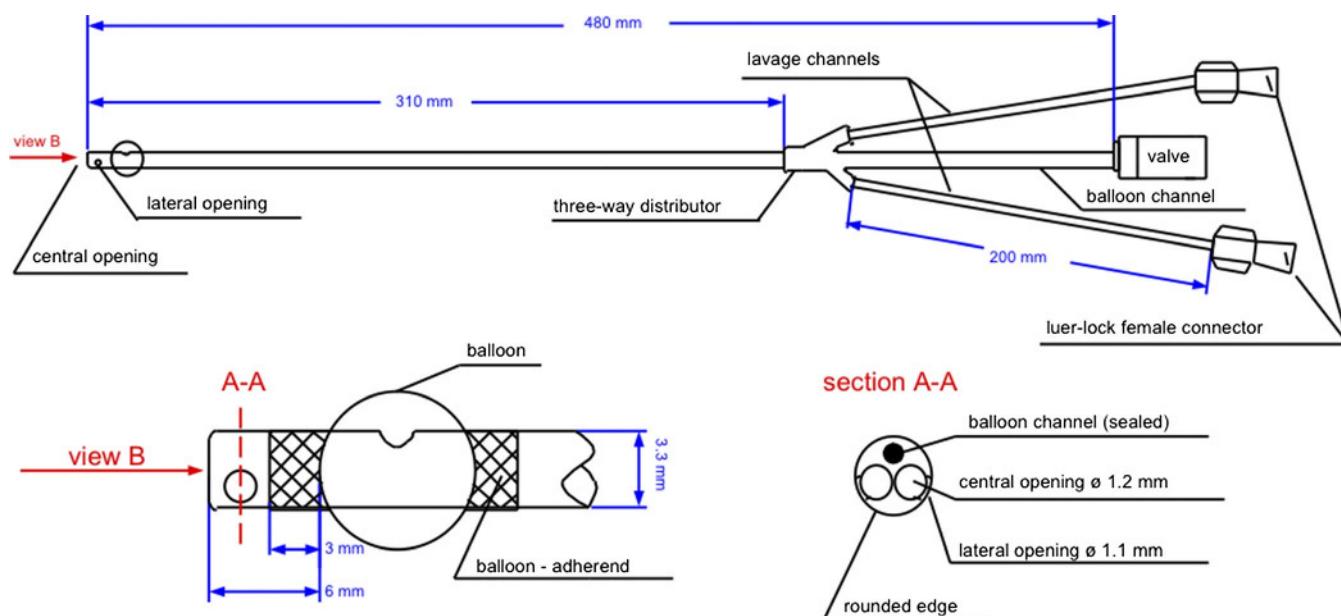


FIGURE 1. Sketch of the catheter for UtL (Medicoplast MF 13005). The 12F flexible polyurethane 3-way catheter comprises a polyurethane tube with 3 lumens. There are 2 lavage channels each with 2 openings, one on the tip of the catheter facing forward and one at the side. The third channel is the balloon tube carrying a valve, which is used to seal the cervical canal.

UtL was performed under local anesthesia (LA) only and compared with the placement of an intrauterine device (IUD). This comparison was chosen because IUD placement follows the same steps as the UtL; it is a procedure that is well known to gynecologists and broadly accepted by women.

MATERIALS AND METHODS

The used catheter for UtL (Fig. 1; MF 13005; Medicoplast, Illingen, Germany; developed in cooperation with the Katholieke Universiteit Leuven) is a proprietary 12F flexible 3-way catheter. It comprises a polyurethane tube with 3 lumens, which are separated into 3 tubes with a 3-way distributor. Two tubes function as lavage channels and carry a Luer-Lock female connector at the proximal end. Each of the lavage channels has 2 openings: one at the tip of the catheter facing forward and one at the side. The third tube is the balloon tube. The balloon channel carries a valve that enables blocking the balloon with fluid. The recommended volume of blocking fluid is 1 mL, resulting in a diameter of the balloon of 8 mm. The balloon is densely draped onto the catheter to allow for an easy insertion through the cervical canal. The distal end of the catheter is rounded, and its insertion through the cervical canal is atraumatic. To enable measuring the depth of the insertion, the catheter carries a length marking.

Gynecologists received a 1-page written instruction on the UtL procedure. The lavage can either be performed on a gynecologic examination chair in an outpatient setting, preferably under LA or in Lloyd-Davies position in the operating theater under general anesthesia. First, the cervix is

visualized using a speculum and cleaned with an antiseptic lotion. The cervix is grasped with a tenaculum at 12:00 o'clock. The catheter is inserted into the uterine cavity through the cervical canal, and the balloon is inflated. If the cervical canal is too narrow to pass the catheter, it is dilated to 4 mm with Hegar's dilators. Two 10-mL syringes, one of them containing 10 mL of phosphate-buffered saline at body temperature, are connected to the 2 tubes of the 3-way catheter. The patient is put into anti-Trendelenburg positioning. To initiate the lavage flow, 1 mL of the lavage fluid is flushed into the uterine cavity before aspiration is started through the other lavage channel. Subsequently, the remaining fluid is slowly flushed and simultaneously aspirated. Particularly at the beginning of the UtL procedure, attention should be paid not to lose any lavage fluid. In premenopausal women, the UtL should be performed in the late luteal phase, given the physiologic function of the fallopian tubes. After the lavage is finished, the balloon is deflated and the catheter is removed. After collection, the lavage sample was mixed with an alcohol-based stabilization solution and sent to the Medical University of Vienna. The lavage samples were filtered through a 100-µm pore size filter. The filtrate was centrifuged at 300g for 10 minutes at room temperature. The cell pellet was lysed and stored at -80°C until further processing. DNA was isolated using the QIAamp MinElute Media Kit (Qiagen, Hilden, Germany) and quantified using a Qubit fluorometer (ThermoFisher, Waltham, Massachusetts).

Local anesthesia was performed, following a protocol published by Rogstad et al.¹⁰ Xylocaine spray was first applied to the cervix. After 1 minute, xylocaine 2% with

TABLE 1. Key characteristics and evaluation criteria for study I and study II

Key Characteristics	Study I	Study II
Study population	Suspicious ovarian mass HBOC	Healthy women
Institutions	4	1
Gynecologists	16	1
Catheter lots	4	1
UtL	Immediately before surgery	4 wk before IUD placement
Anesthesia	General	Local*
Evaluation criteria	- UtL successfully performed Yes No - Catheter insertion Easy Complicated - Cervical dilatation Yes No - Collected UtL volume mL - DNA extracted µg	- Pain during UtL 0-10 - Pain during IUD insertion 0-10 - Pain in the interim period 0-10 - Side effects, complications Description - Time for UtL min - Time for IUD placement min

*Local anesthesia was applied in 18 of 22 women before UtL and IUD insertion; in 1 woman, LA was applied just before IUD. In 3 women, both UtL and IUD insertion was performed without LA.

TABLE 2. Characteristics of the study population included in study I and study II and the site of sample collection

	Study I	Study II
Diagnosis, n (%)	93 (100)	22 (100)
OC	33 (35.5)	0
Other cancer	6 (6.5)	0
Borderline tumor	4 (4.3)	0
HBOC	29 (31.2)	0
Benign	21 (22.6)	0
Healthy	0	22 (100)
Age, mean (range), y	51 (19–80)	30 (21–50)
Menopause status, n (%)		
Premenopausal	40 (43.0)	22 (100)
Postmenopausal	53 (57.0)	0
Center, n (%)		
Vienna	43 (46.2)	22 (100)
Essen	38 (40.9)	0
Hamburg	4 (4.3)	0
Pilsen	8 (8.6)	0

epinephrine was injected into the ectocervix at 6 and 12 o'clock using a 20G spinal needle. The first 1 to 2 mL are injected into the lymph vascular network of the most superficial submucosal layer of the ectocervix. Only then, the cervix is grasped with the tenaculum, and deep stromal infiltration to a depth of approximately 5 cm is performed, again at 6 and 12 o'clock.

The design and the primary outcome measures of study I are shown in Table 1. Between September 2014 and August 2015, 93 women from 4 different institutions were included: Medical University of Vienna (Austria), Kliniken Essen-Mitte (Germany), Charles University Pilsen (Czech Republic), and University Medical Center Hamburg-Eppendorf (Germany). All samples were collected in accordance with the institutional review boards (EK nos. 1152/2014, 1148/2011, NCT02039388, NCT02518256). Informed consent was obtained from each participant. All patients underwent surgery, either for removal of a suspicious ovarian mass (n = 64) or for RRSO (n = 29; Table 2). Uterine and tubal lavage was performed before surgery under general anesthesia. Inclusion criteria were age greater than 18 years, no pregnancy, and no prior tubal ligation. Within this study, 16 different gynecologists performed the UtL. Four different lots of the catheter were used.

As part of study I, the clinician performing the UtL was asked to report on the volume of retrieved lavage fluid, whether inserting the catheter was easy or complicated and whether cervical dilatation was applied. The rating "complicated" was used if access to and visualization of the cervix was difficult, for instance, in case of vaginal stenosis or distortion of anatomy by large benign or malignant tumors, or if problems during dilatation were experienced, like in cases of cervical occlusion. In the absence of any of the previously mentioned, the rating was "easy."

The design of study II is shown in Table 1. This study was carried out at the Medical University of Vienna between October 2015 and August 2016 and included 22 healthy women. It was conducted in accordance with the institutional review board (EK no. 1161/2015), and informed consent was obtained from each woman. The study involved 2 visits for each participant. At the first visit, a UtL was performed; at the second visit, 4 weeks later, an IUD was inserted. If needed, UtL and/or IUD insertion was performed under LA as described in the previous section.

Participants of study II were asked to report their subjective pain on a visual analog scale (VAS) ranging from 0 (no pain) to 10 (worst possible pain), experienced both during UtL and IUD procedure. Participants also reported on any possible pain, complications, or adverse effects experienced in the 4 weeks between the 2 visits. The following parameters

TABLE 3. Outcome evaluation of study I and study II

Study I	
Catheter performance	
Insertion	
Easy	78 (84.5%)
Complicated	15 (15.2%)
Dilatation	
Applied	40 (43.5%)
Not applied	52 (56.5%)
UtL sample collection	
Successful	92 (98.9%)
Not successful	1 (1.1%)
Sample material	
Sample volume	8.5 mL (range, 2.5–10.0 mL)
DNA amount	2.23 µg (range, 0.11–76.3 µg)
Study II	
VAS score	
UtL	
Without LA (n = 4)	2.9 (2.5–8.2)
With LA (n = 18)	1.6 (0.0–3.9)
IUD	
Without LA (n = 3)	4.0 (3.5–6.3)
With LA (n = 19)	1.0 (0.0–4.0)
Between UtL and IUD	
Without side effects (n = 15)	0
With side effects (n = 7)	2.2 (1.0–3.0)
Duration	
UtL	6.5 min (range, 5.0–10.0 min)
IUD	6.5 min (range, 4.0–8.0 min)
Complications	
None	22 (100%)
Any	0

were recorded: any use of analgesics or antibiotics, fever, and need for medical consultation. Furthermore, the duration of both procedures was noted.

The comparison of the catheter and lavage performance in postmenopausal and premenopausal women, as well as between the groups of women with different diagnoses, was performed using the χ^2 test. *P* values were calculated using either the 2-tailed *t* test or the Fisher exact test. All statistical analyses were performed using IBM SPSS Statistics for Windows, Version 21.0 (IBM Corp, Armonk, NY).

RESULTS

Characteristics of the study population of study I and study II are summarized in Table 2.

In study I, 16 different gynecologists in 4 centers performed a UtL in 93 women. An overview on the performance data is given in Table 3. Dilation was applied in 40 women, whereas a UtL could be performed without dilation in 52 women. Overall, catheter insertion was described as easy in 78 cases and complicated in 15 cases. The insertion was described as easy in all 52 cases without cervical dilatation and in 65% of those cases with cervical dilatation before UtL (Pearson χ^2 , 2-tailed, *P* < 0.001). The odds ratio (OR) of difficult insertion was almost 6-fold higher in cancer patients (*n* = 42) than in women with benign gynecologic diseases or those undergoing RRSO (*n* = 50; OR 5.559; 95% confidence interval [CI], 1.434–21.546; Pearson χ^2 , 2-tailed, *P* = 0.007). Ease of insertion was not associated with the menopause status neither in the cancer patients nor in the control group; however, cervical dilatation before UtL was significantly associated with postmenopausal status in the control group (OR, 4.929; 95% CI, 1.439–16.884; Fisher exact test, 2-tailed, *P* = 0.016) but not in the cancer patients.

In all but 1 case (92/93; 98.9%), it was possible to collect a UtL sample. The only exception was the case of a 68-year-old woman with a uterine carcinoma. A tumor mass present in the pelvis with a diameter of approximately 30 cm did not allow for visualizing the cervix, and as a result, UtL could not be

performed. The median volume of the lavage fluid, which could be retrieved, was 8.5 mL (range, 2.5–10.0 mL) of the 10 mL used for performing the lavage (Table 3). DNA was isolated from 86 of 93 UtL samples collected in the course of study I. The median absolute amount of DNA obtained was 2.23 μ g (range, 111 ng to 76.3 μ g; Table 3). There was no significant difference in the amount of DNA isolated from lavage samples depending on the patient's diagnosis.

Because the UtL follows all steps of the insertion of an IUD, their invasiveness is very similar. Therefore, the burden of both procedures was compared and patients were asked to report their subjective pain on a VAS scale immediately after UtL and IUD insertion (Table 3). Initially, 4 patients underwent a UtL without LA. The median VAS score reported by these women was 2.9. However, one of them experienced a high level of pain with a rating of 8.2. Because this seemed unacceptably high for a routine procedure, in all other cases, LA with xylocaine spray followed by xylocaine infiltration was introduced for both UtL and IUD insertion. Women who received LA before both procedures rated the pain experienced by UtL with a median VAS score of 1.6. The insertion of an IUD was rated with 1.0. In the period between the 2 procedures, none of the 22 women required analgesic or antibiotic treatment and none of them developed a fever or any other symptoms requiring medical attention.

Five of the participants had an IUD in place by the time the UtL was performed. This did not cause any problems, neither regarding performing the lavage nor regarding the IUD position, which was checked by vaginal ultrasound afterwards. Seven women had a vaginal delivery previously. The VAS score reported by these women was not significantly different from the score of nulliparous women.

The duration of both procedures from insertion to removal of the speculum was recorded for all of the 22 participants of study II. For both of the procedures, the median time to perform them was 6.5 minutes, ranging from 5 to 10 minutes for the UtL and 4 to 8 minutes for the IUD insertion (Table 3 and Fig. 2).

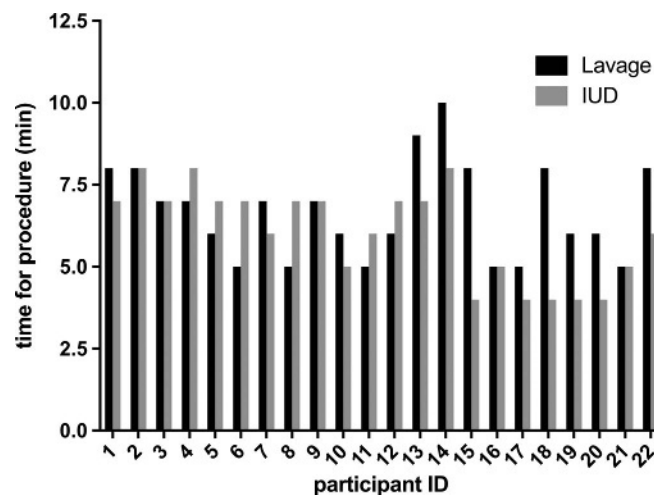


FIGURE 2. Time to perform the UtL and IUD insertion as part of study II measured from insertion to removal of the speculum. For both procedures, the median time was 6.5 minutes (range, 5–10 minutes for UtL and 4–8 minutes for IUD).

DISCUSSION

State-of-the-art diagnostic tests, namely, the assessment of the serum CA125 level and transvaginal ultrasonography, have already been implemented in 1988. Since then, they have not evolved substantially, despite lacking sensitivity and specificity.¹¹ The molecular analysis of UtL specimens holds great potential for earlier diagnosis of ovarian cancer (OC). The present studies are the first to assess the clinical feasibility and potential safety of the UtL approach using the newly developed catheter.

The special configuration of the tip of the catheter made it possible to overcome technical problems not yet solved before. The small size allows the tip to completely enter the uterine cavity even in postmenopausal and nulliparous women. The catheter performed very reliably, and in 92 of 93 cases, a sample could be collected with a median volume of 8.5 mL from the initial lavage volume of 10 mL. A written 1-page instruction was thus sufficient to enable gynecologists to handle the catheter and successfully perform the procedure. Difficulties experienced while inserting the catheter were mainly associated with the presence of a tumor mass.

As a result of the increasing awareness, more and more women decide to get tested for the presence of a germline *BRCA* mutation. The reported rates of RRSO among mutation carriers vary between 13% and 75%.^{12–20} In a study by Skytte et al,²¹ 41% of women (63/155) opted for an RRSO before their 40th birthday, although the recommended age for performing the procedure is between 35 and 40 years. Hence, for the remaining 59%, there is a strong unmet clinical need for a screening test. One of the prerequisites for such a test is being well tolerated. One of the participants of study II had a pain rating of 8.2 while performing the UtL without anesthesia. This is unacceptably high for a screening test. After introduction of LA, the median VAS scores were 1.6 for UtL and 1.0 for IUD insertion, which is why we recommend to use LA for all patients. For comparative reasons, median VAS scores for peripheral intravenous cannula insertion with or without lidocaine cream were reported to be 3.0 and 7.0, respectively.²² Our data compare favorably with a recent study applying conventional paracervical block for IUD insertion.²³ In this study, the median VAS score after IUD insertion in 47 women was 30.0 (95% CI, 20.0–58.0) on a 100-mm VAS. This difference can be explained by our technique for LA. Not only did we use a xylocaine spray first, but we also injected xylocaine into the ectocervix within a 2-step procedure. First, injection into the submucosal lymph-vascular space was performed, which results in hardly any resistance to the infiltration. In the second step, the deep stromal infiltration is performed. In the period between the 2 procedures, none of the patients required medical attention or medication, and the only side effect seen in 7 women was a mild dragging sensation in the lower abdomen on the day after UtL with a median VAS score of 2.2 (range, 1.0–3.0). Thus, our data clearly refute concerns regarding the invasiveness of the UtL approach and prove that it is well tolerated and only takes a median time of 6.5 minutes from insertion to the removal of the speculum.

Deep sequencing should be considered the method of choice for detecting low-level signatures of tumor-derived

mutations in liquid biopsies. The accuracy and sensitivity of these technologies have improved tremendously over the last years. Duplex sequencing, for example, reduced the error rate to less than 1 in 10 million nucleotides.²⁴ Taking that into account, a detection limit of 0.05% is feasible, when 100 ng of input DNA is used. All of the samples fulfilled this criterion.

In this article, we do not report on the sensitivity of OC detection based on UtL samples because it was not the goal of the particular studies. However, the findings of our earlier proof-of-concept study have been very encouraging, as we have been able to demonstrate the potentially high diagnostic power of the UtL approach for ovarian and endometrial cancer detection. In 24 (80%) of 30 patients with OC, specific mutations could be identified in the UtL sample, including 1 patient with occult HGSC. Currently, the UtL approach is studied in 3 different fields of scientific research, namely, as a possible screening tool for HGSCs and STICs (LUSTIC, NCT02039388), for type II endometrial carcinomas (LUDEC, NCT02387645), and for the differential diagnosis of suspicious adnexal masses (LUDOC II, NCT02518256). Early detection of ovarian cancer using uterine lavage and duplex sequencing is explored further within the frame of a National Cancer Institute (United States) grant (www.sbir.gov/sbirsearch/detail/1323913).

In conclusion, the studies presented here demonstrate that the UtL performed with the new catheter fulfills all prerequisites for a screening test. Uterine and tubal lavage specimens can be collected reliably, even after a short training. The procedure was proven to be safe and feasible to use in a clinical or outpatient setting. Only minimal pain was associated with the procedure and the duration was short, which allows for longitudinal measurements. A series of applications are conceivable and need to be proven in large, prospective trials, ranging from differential diagnosis of ovarian masses to HGSC screening in HBOC women and ultimately screening of the general population.

REFERENCES

1. Baldwin LA, Huang B, Miller RW, et al. Ten-year relative survival for epithelial ovarian cancer. *Obstet Gynecol*. 2012;120:612–618.
2. Rosenthal AN, Fraser LSM, Philpott S, et al. Evidence of stage shift in women diagnosed with ovarian cancer during phase II of the United Kingdom Familial Ovarian Cancer Screening Study. *J Clin Oncol*. 2017;35:1411–1420.
3. Jacobs IJ, Menon U, Ryan A, et al. Ovarian cancer screening and mortality in the UK Collaborative Trial of Ovarian Cancer Screening (UKCTOCS): a randomised controlled trial. *Lancet*. 2016;387:945–956.
4. Finch AP, Lubinski J, Møller P, et al. Impact of oophorectomy on cancer incidence and mortality in women with a *BRCA1* or *BRCA2* mutation. *J Clin Oncol*. 2014;32:1547–1553.
5. Domchek SM, Friebel TM, Singer CF, et al. Association of risk-reducing surgery in *BRCA1* or *BRCA2* mutation carriers with cancer risk and mortality. *JAMA*. 2010;304:967–975.
6. Bijron JG, Seldenrijk CA, Zweemer RP, et al. Fallopian tube intraluminal tumor spread from noninvasive precursor lesions: a novel metastatic route in early pelvic carcinogenesis. *Am J Surg Pathol*. 2013;37:1123–1130.

7. Maritschnegg E, Wang Y, Pecha N, et al. Lavage of the uterine cavity for molecular detection of müllerian duct carcinomas: a proof-of-concept study. *J Clin Oncol*. 2015;33:4293–4300.
8. Kinde I, Bettegowda C, Wang Y, et al. Evaluation of DNA from the Papanicolaou test to detect ovarian and endometrial cancers. *Sci Transl Med*. 2013;5:167ra4.
9. Erickson BK, Kinde I, Dobbin ZC, et al. Detection of somatic TP53 mutations in tampons of patients with high-grade serous ovarian cancer. *Obstet Gynecol*. 2014;124:881–885.
10. Rogstad KE, White DJ, Ahmed-Jushuf IH. Efficacy of lignocaine analgesia during treatment to the cervix. *Lancet*. 1992;340:942.
11. Jacobs I, Stabile I, Bridges J, et al. Multimodal approach to screening for ovarian cancer. *Lancet*. 1988;1:268–271.
12. Schwartz MD, Kaufman E, Peshkin BN. Bilateral prophylactic oophorectomy and ovarian cancer screening following BRCA1/BRCA2 mutation testing. *J Clin Oncol*. 2003;21:4034–4041.
13. Lerman C, Hughes C, Croyle RT. Prophylactic surgery decisions and surveillance practices one year following BRCA1/2 testing. *Prev Med*. 2000;31:75–80.
14. Meijers-Heijboer H, Brekelmans CT, Menke-Pluymers M. Use of genetic testing and prophylactic mastectomy and oophorectomy in women with breast or ovarian cancer from families with a BRCA1 or BRCA2 mutation. *J Clin Oncol*. 2003;21:1675–1681.
15. Meijers-Heijboer EJ, Verhoog LC, Brekelmans CT. Presymptomatic DNA testing and prophylactic surgery in families with a BRCA1 or BRCA2 mutation. *Lancet*. 2000;355:2015–2020.
16. Lodder LN, Frets PG, Trijsburg RW. One year follow-up of women opting for presymptomatic testing for BRCA1 and BRCA2: emotional impact of the test outcome and decisions on risk management (surveillance or prophylactic surgery). *Breast Cancer Res Treat*. 2002;73:97–112.
17. Scheuer L, Kauff N, Robson M. Outcome of preventive surgery and screening for breast and ovarian cancer in BRCA mutation carriers. *J Clin Oncol*. 2002;20:1260–1268.
18. Botkin JR, Smith KR, Croyle RT. Genetic testing for a BRCA1 mutation: prophylactic surgery and screening behavior in women 2 years post testing. *Am J Med Genet A*. 2003;118A:201–209.
19. Claes E, Evers-Kiebooms G, Decruyenaere M. Surveillance behavior and prophylactic surgery after predictive testing for hereditary breast/ovarian cancer. *Behav Med*. 2005;31:93–105.
20. Madalinska JB, van Beurden M, Bleiker EM, et al. Predictors of prophylactic bilateral salpingo-oophorectomy compared with gynecologic screening use in BRCA1/2 mutation carriers. *J Clin Oncol*. 2007;25:301–307.
21. Skytte AB, Gerdes AM, Andersen MK, et al. Risk-reducing mastectomy and salpingo-oophorectomy in unaffected BRCA mutation carriers: uptake and timing. *Clin Genet*. 2010;77:342–349.
22. McNaughton C, Zhou C, Robert L, et al. A randomized, crossover comparison of injected buffered lidocaine, lidocaine cream, and no analgesia for peripheral intravenous cannula insertion. *Ann Emerg Med*. 2009;54:214–220.
23. Akers AY, Steinway C, Sonalkar S, et al. Reducing pain during intrauterine device insertion: a randomized controlled trial in adolescents and young women. *Obstet Gynecol*. 2017;130:795–802.
24. Krimmel JD, Schmitt MW, Harrell MI, et al. Ultra-deep sequencing detects ovarian cancer cells in peritoneal fluid and reveals somatic TP53 mutations in noncancerous tissues. *Proc Natl Acad Sci U S A*. 2016;113:6005–6010.