

➤ **Case Report** ◀

# Percutaneous Direct Embolization for Pseudoaneurysm at the Gallbladder Fossa after Cholecystectomy

Kunihiro Yagihashi, MD,<sup>1,2</sup> Minobu Kamo, MD,<sup>1</sup> Tomoya Nishiyama, MD,<sup>1</sup> and Yasuyuki Kurihara, MD<sup>1</sup>

Postoperative pseudoaneurysm at the gallbladder fossa is a rare complication of cholecystectomy. The typical clinical presentations of this condition are intraparenchymal or intraperitoneal hemorrhage or rupture into the gastrointestinal tract, and this may be life-threatening. For the treatment of pseudoaneurysms, percutaneous transarterial embolization is considered first-line. We present a case of pseudoaneurysm at the gallbladder following cholecystectomy, which was successfully treated with echo-guided percutaneous transhepatic direct embolization using N-butyl cyanoacrylate, after the failure of transarterial embolization.

**Keywords:** pseudoaneurysm, percutaneous embolization, N-butyl-2-cyanoacrylate

## Introduction

Pseudoaneurysm at the gallbladder fossa is a potential complication of cholecystectomy. The formation of such pseudoaneurysms is due to mechanical or thermal injury to an artery.<sup>1)</sup> The usual clinical presentation of this condition is intraparenchymal or intraperitoneal hemorrhage or rupture into the gastrointestinal tract, and this may be life-threatening. Most cases of pseudoaneurysm formation are treated with an endovascular technique and more invasive surgical procedures are reserved for unsuccessful cases. We report a case of pseudoaneurysm at the gallbladder fossa, which was successfully treated with percutaneous direct embolization after the failure of transarterial embolization.

<sup>1</sup>Department of Radiology, St. Luke's International Hospital, Tokyo, Japan

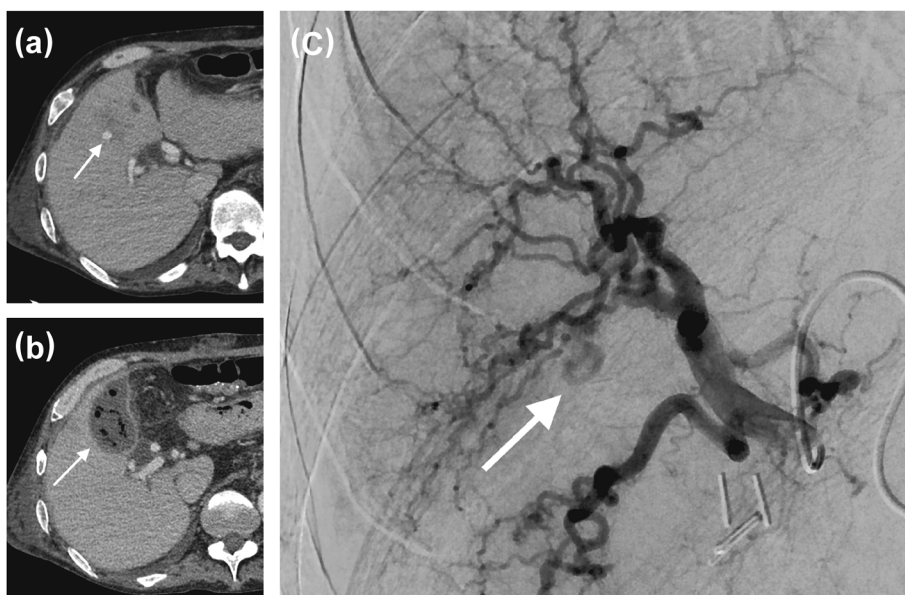
<sup>2</sup>Department of Radiology, St. Marianna University School of Medicine, Yokohama City Seibu Hospital, Yokohama, Kanagawa, Japan

Received: December 12, 2016; Accepted: March 22, 2017  
Corresponding author: Kunihiro Yagihashi, MD. Department of Radiology, St. Marianna University School of Medicine, Yokohama City Seibu Hospital, 1197-1, Yasashi-cho, Asahi-ku, Yokohama, Kanagawa 241-0811, Japan  
Tel: +81-45-366-1111, Fax: +81-45-366-8434  
E-mail: k2yagihashi@marianna-u.ac.jp

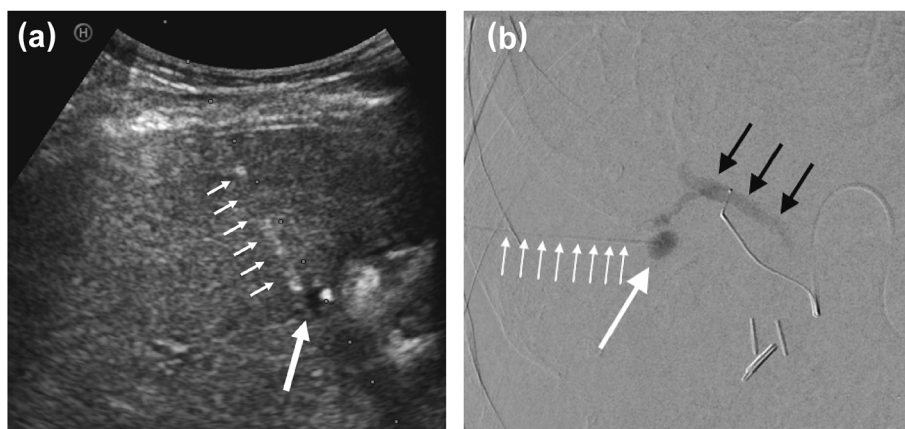
## Case Report

A 55-year-old man presented with abdominal pain and fever. He had a history of alcoholic liver cirrhosis, diabetes mellitus, and hypertension. Contrast-enhanced computed tomography (CT) of the abdomen showed thickening and distention of the gallbladder wall, which was consistent with acute cholecystitis. Subsequently, laparoscopic cholecystectomy was performed. During the operation, there was uncontrollable bleeding at the gallbladder fossa. The laparoscopic surgery was converted to open surgery and hemostasis was achieved. One week later, the patient developed fever and abdominal pain. A CT examination showed an approximately 5-mm, avidly-enhancing nodular lesion in the periphery of the liver parenchyma. This was suspected to be a pseudoaneurysm with associated fluid collection within the gallbladder fossa (Figs. 1a and 1b). The fluid collection contained gas and was presumed to be an abscess. A multidisciplinary review was held and the participants judged that transarterial embolization (TAE) would be better than laparotomy for treatment. Informed consent for the procedure was obtained from the patient and we performed emergent angiography to embolize the pseudoaneurysm. The procedure was performed under local anesthesia in an angiographic suite (Artis G, Siemens Medical Solutions, Erlangen, Germany) as follows: A 4-Fr sheath was introduced via the right femoral artery and a 4-Fr shepherd hook catheter was advanced to the celiac trunk. A 2.2-Fr microcatheter (Progreat, Terumo, Tokyo, Japan) with a 0.014-inch microwire (Chikai, Asahi Intecc, Aichi, Japan) was introduced into the right hepatic artery. Right hepatic angiography showed an approximately 5-mm pseudoaneurysm corresponding to that of the CT images (Fig. 1c). Subsequent retrograde visualization of the portal vein in the area showed a feeding vessel suspected to be a branch of the right hepatic artery. However, this feeding vessel was tortuous, mainly due to liver cirrhosis, and the microcatheter/microwire could not be advanced through it. As embolizing the proximal portion of the right hepatic artery may not completely occlude the pseudoaneurysm and also carries a risk of liver infarction/abscess formation owing to a broad embolization area, we





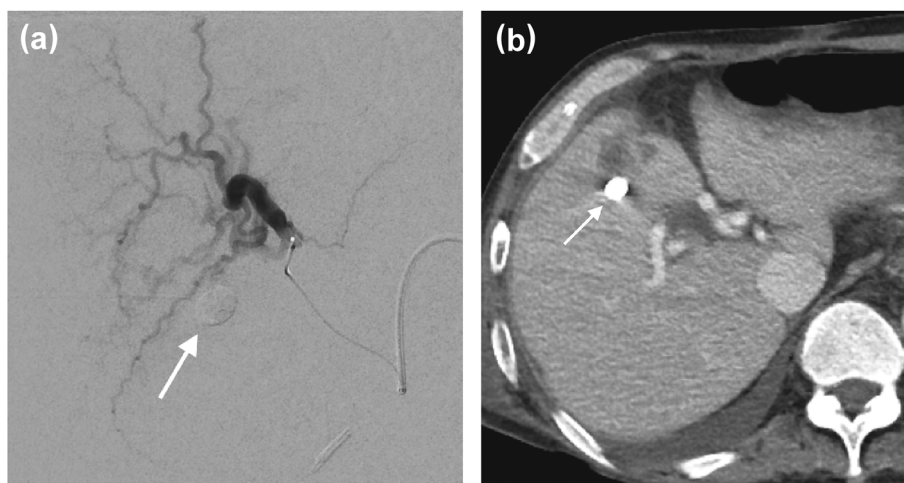
**Fig. 1** (a) Axial image from a CT scan of the abdomen with intravenous contrast demonstrates a 5-mm vascular nodule, which was suspected to be a pseudoaneurysm (arrow). (b) Axial image from CT of the abdomen with intravenous contrast shows a fluid collection containing gas, which is likely to be an abscess (arrow). (c) Hepatic angiogram shows a pseudoaneurysm arising off the right hepatic artery (arrow).



**Fig. 2** (a) Transabdominal ultrasound image shows a pseudoaneurysm (large white arrow) and the needle shadow (small white arrows). (b) Contrast study through a percutaneous needle (small white arrows) shows a pseudoaneurysm (large white arrow) with retrograde visualization of the portal vein (black arrows).

decided that it would be impossible to isolate the pseudoaneurysm with a transarterial approach. Instead, we decided to embolize the pseudoaneurysm using a percutaneous direct puncture method. Subsequently, ultrasound (HIVISION Avius, Hitachi, Tokyo, Japan) was performed, clearly showing the pseudoaneurysm. Therefore, under ultrasound guidance, the pseudoaneurysm was punctured with a 21-gauge needle (PTCD Two Step Drainage set, Hanaco Medical, Saitama, Japan) using a percutaneous transhepatic approach (Fig. 2a). After confirmation of backward blood flow, contrast material was injected

through the needle, and we were able to visualize the pseudoaneurysm and subsequent retrograde filling of the portal vein (Fig. 2b). A total of 0.3 mL of 50% N-butyl-2-cyanoacrylate (NBCA) (Histoacryl, B. Braun Melsungen AG, Tuttlingen, Germany) with ethiodized oil (Lipiodol, Guerbet, Aulnay-sous-Bois, France) was slowly injected into the pseudoaneurysm under fluoroscopy. After the aneurysm was filled with a mixture of NBCA and ethiodized oil, the needle was removed while embolizing the tract with this mixture. Subsequent right hepatic angiography showed complete occlusion of the pseudoaneurysm (Fig.



**Fig. 3** (a) Hepatic angiogram following embolization of the pseudoaneurysm shows complete occlusion of the pseudoaneurysm (arrow). (b) Axial image from a CT scan of the abdomen with intravenous contrast demonstrates complete occlusion of the pseudoaneurysm by a mixture of N-butyl-2-cyanoacrylate and ethiodized oil (white arrow).

3a). A percutaneous transhepatic abscess drainage at the gallbladder fossa was then performed.

The patient's fever and abdominal pain resolved thereafter. A follow-up CT showed complete occlusion of the pseudoaneurysm and a decrease in the size of the fluid collection at the gallbladder fossa (Fig. 3b).

## Discussion

We report successful percutaneous echo-guided direct embolization of a pseudoaneurysm at the gallbladder fossa after cholecystectomy using a mixture of NBCA and ethiodized oil injection. This was performed as an alternative treatment following the failure of TAE.

Pseudoaneurysm after laparoscopic cholecystectomy is a rare complication and has been reported infrequently. In a previous report, 9 of 1513 (0.6%) patients developed major upper gastrointestinal bleeding due to the rupture of a pseudoaneurysm after laparoscopic cholecystectomy.<sup>2)</sup> However, the true incidence of pseudoaneurysm rupture is likely unclear because asymptomatic pseudoaneurysms may remain undetected. The clinical presentation is usually with intraparenchymal or intraperitoneal hemorrhage or rupture into the gastrointestinal tract.<sup>3)</sup> The risk of rupture is correlated with the size of the pseudoaneurysm, with those larger than 5 cm having a 10-fold risk of rupture. Smaller pseudoaneurysms have less risk of rupture and may present with minimal symptoms.<sup>3)</sup> In our case, although the size of the pseudoaneurysm was small, our patient had an abscess adjacent to the pseudoaneurysm at the gallbladder fossa. Therefore, the aneurysm may have been eroded and may have ruptured into the gallbladder fossa or peritoneum, justifying treatment.

Most hepatic arterial pseudoaneurysms that develop following cholecystectomy are managed with the endovascular techniques of isolation or embolization of the aneurysm.<sup>4-6)</sup> Surgical treatment is reserved for cases involving a large pseudoaneurysm, failure of the endovascular procedure, or pseudoaneurysm recurrence.<sup>3)</sup> However, some reports have described treatment with percutaneous direct embolization as an alternative treatment, similar to our case.<sup>4,7)</sup> This percutaneous direct embolization method has several advantages: 1) the procedure is less invasive, with no requirements for general anesthesia, and there is less parenchymal injury compared with surgery; 2) By using the liver parenchyma as an echo window, pseudoaneurysms can often be easily identified with ultrasound; 3) With a transhepatic approach, the risk of rupture by direct puncture is decreased; 4) Combined hepatic artery angiography enables real time observation of the pseudoaneurysm and the needle with not only ultrasound but also fluoroscopy.

Embolization materials for pseudoaneurysms include coils, NBCA, thrombin, and gelatin sponges. Among these, NBCA is regarded as more technically demanding, as it requires an expert technique in experienced hands to control the range of embolization and carries a risk of adhesion to vessel walls or catheters. While thrombin has been used as the embolization material in previous reports,<sup>4,7)</sup> we used NBCA because in our case, arterial flow to the pseudoaneurysm subsequently drained to a branch of the portal vein in the area, as visualized retrogradely. We speculated that liquid embolization materials, such as thrombin, would easily leak into the portal vein. This could cause liver infarction by compromising the hepatic artery and the portal vein in the area. We determined that

a high concentration of NBCA, which has a high viscosity and short polymerization time, would be the best embolic material in that situation.

There are some disadvantages to percutaneous direct embolization with NBCA as follows: 1) skill is required to puncture the pseudoaneurysm under ultrasound guidance; 2) this method is not indicated for all cases (e.g., a large amount of ascites, bowels, or pleural space overlapping with the puncture line for the pseudoaneurysm); and 3) there can be severe complications, such as non-target embolization and catheter adhesion with NBCA injections.<sup>8,9)</sup> In performing the procedure, of course, it is essential to utilize both ultrasound and fluoroscopy and to use a meticulous technique when injecting NBCA.

## Conclusion

We describe a case of postoperative pseudoaneurysm after cholecystectomy with successful percutaneous direct embolization. When selective TAE is difficult, this percutaneous method can be considered as an alternative treatment approach.

## Acknowledgments

The authors are grateful to Jay Starkey, MD, for the revision of the English text.

## Disclosure Statement

All authors declare that they have no conflicts of interest.

## Author Contributions

Study conception: KY, MK  
Data collection: KY, MK, TN  
Analysis: KY, MK

Investigation: KY, MK, YK

Writing: KY

Funding acquisition: none

Critical review and revision: all authors

Final approval of the article: all authors

Accountability for all aspects of the work: all authors

## References

- 1) Beuran M, Chitoroiu AL, Avram M, et al. Management for pseudoaneurysm of cystic artery with an arterio-biliary fistula after laparoscopic cholecystectomy: a rare case of hemobilia. *Chirurgia (Bucur)* 2008; **103**: 689-94.
- 2) Nicholson T, Travis S, Ettles D, et al. Hepatic artery angiography and embolization for hemobilia following laparoscopic cholecystectomy. *Cardiovasc Intervent Radiol* 1999; **22**: 20-4.
- 3) Bulut T, Yamaner S, Bugra D, et al. False aneurysm of the hepatic artery after laparoscopic cholecystectomy. *Acta Chir Belg* 2002; **102**: 459-63.
- 4) Kumar A, Sheikh A, Partyka L, et al. Cystic artery pseudoaneurysm presenting as a complication of laparoscopic cholecystectomy treated with percutaneous thrombin injection. *Clin Imaging* 2014; **38**: 522-5.
- 5) Madanur MA, Battula N, Sethi H, et al. Pseudoaneurysm following laparoscopic cholecystectomy. *Hepatobiliary Pancreat Dis Int* 2007; **6**: 294-8.
- 6) Caminiti R, Rossitto M, Ciccolo A. Pseudoaneurysm of the hepatic artery and hemobilia: a rare complication of laparoscopic cholecystectomy; clinical case and literature review. *Acta Chir Belg* 2011; **111**: 400-3.
- 7) Ghazal A, Kheir E, Kotru A, et al. Hemoperitoneum secondary to rupture of cystic artery pseudoaneurysm. *Hepatobiliary Pancreat Dis Int* 2007; **6**: 321-3.
- 8) Mavili E, Donmez H, Ozcan N, et al. Endovascular treatment of lower limb penetrating arterial traumas. *Cardiovasc Intervent Radiol* 2007; **30**: 1124-9.
- 9) n-BCA Trail Investigators. N-butyl cyanoacrylate embolization of cerebral arteriovenous malformations: results of a prospective, randomized, multi-center trial. *AJNR Am J Neuroradiol* 2002; **23**: 748-55.