

RESEARCH ARTICLE

# Feasibility study for detection of retinal amyloid in clinical trials: The Anti-Amyloid Treatment in Asymptomatic Alzheimer's Disease (A4) trial

Jennifer Ngolab<sup>1</sup> | Michael Donohue<sup>2</sup> | Alison Belsha<sup>2</sup> | Jennifer Salazar<sup>2</sup> |  
Paula Cohen<sup>2</sup> | Sandhya Jaiswal<sup>2</sup> | Veasna Tan<sup>2</sup> | Devon Gessert<sup>2</sup> |  
Shaina Korouri<sup>1</sup> | Neelum T. Aggarwal<sup>3</sup> | Jessica Alber<sup>4</sup> | Ken Johnson<sup>5</sup> |  
Gregory Jicha<sup>6</sup> | Christopher van Dyck<sup>7</sup> | James Lah<sup>8</sup> | Stephen Salloway<sup>9</sup> |  
Reisa A. Sperling<sup>10</sup> | Paul S. Aisen<sup>2</sup> | Michael S. Rafii<sup>2</sup> | Robert A. Rissman<sup>1</sup>

<sup>1</sup> Department of Neurosciences, San Diego, School of Medicine, University of California, La Jolla, California, USA

<sup>2</sup> Alzheimer's Therapeutic Research Institute University of Southern California, San Diego, California, USA

<sup>3</sup> Department of Neurological Sciences and the Rush Alzheimer's Disease Center, Rush University Medical Center, Chicago, Illinois, USA

<sup>4</sup> George & Anne Ryan Institute for Neuroscience University of Rhode Island, Kingston, Rhode Island, USA

<sup>5</sup> NeuroVision Imaging Inc, Sacramento, California, USA

<sup>6</sup> Department of Neurology & the Sanders-Brown Center on Aging, University of Kentucky College of Medicine, Lexington, Kentucky, USA

<sup>7</sup> Alzheimer's Disease Research Unit, Departments of Psychiatry, Neurology, and Neuroscience, Yale School of Medicine, New Haven, Connecticut, USA

<sup>8</sup> Department of Neurology, Emory Goizueta Alzheimer's Disease Research Center, Emory University School of Medicine, Atlanta, Georgia, USA

<sup>9</sup> Memory and Aging Program, Butler Hospital, Providence, Rhode Island, USA

<sup>10</sup> Center for Alzheimer Research and Treatment, Brigham and Women's Hospital Massachusetts General Hospital, Boston, Massachusetts, USA

## Correspondence

Robert A. Rissman, Department of Neurosciences, UCSD School of Medicine, 9500 Gilman Drive, MTF 309, M/C 0624, La Jolla, CA 92093-0624, USA.  
Email: [rrissman@health.ucsd.edu](mailto:rrissman@health.ucsd.edu)

## Funding information

NIH/NIA, Grant/Award Numbers: AG062429, AG018440, AG010483, AG063689; Alzheimer's Association; Eli Lilly and Company; NeuroVision Inc.; Accelerating Medicines Partnership; GHR Foundation; Morton Plant Mease Foundation; an anonymous foundation and additional private donors

## Abstract

**Introduction:** The retina and brain exhibit similar pathologies in patients diagnosed with neurodegenerative diseases. The ability to access the retina through imaging techniques opens the possibility for non-invasive evaluation of Alzheimer's disease (AD) pathology. While retinal amyloid deposits are detected in individuals clinically diagnosed with AD, studies including preclinical individuals are lacking, limiting assessment of the feasibility of retinal imaging as a biomarker for early-stage AD risk detection.

**Methods:** In this small cross-sectional study we compare retinal and cerebral amyloid in clinically normal individuals who screened positive for high amyloid levels through positron emission tomography (PET) from the Anti-Amyloid Treatment in Asymptomatic Alzheimer's Disease (A4) trial as well as a companion cohort of individuals who exhibited low levels of amyloid PET in the Longitudinal Evaluation of Amyloid Risk and Neurodegeneration (LEARN) study. We quantified the number of curcumin-positive fluorescent retinal spots from a small subset of participants from both studies to determine retinal amyloid deposition at baseline.

This is an open access article under the terms of the [Creative Commons Attribution-NonCommercial-NoDerivs](https://creativecommons.org/licenses/by-nc-nd/4.0/) License, which permits use and distribution in any medium, provided the original work is properly cited, the use is non-commercial and no modifications or adaptations are made.

© 2021 The Authors. *Alzheimer's & Dementia: Diagnosis, Assessment & Disease Monitoring* published by Wiley Periodicals, LLC on behalf of Alzheimer's Association

**Results:** The four participants from the A4 trial showed a greater number of retinal spots compared to the four participants from the LEARN study. We observed a positive correlation between retinal spots and brain amyloid, as measured by the standardized uptake value ratio (SUVr).

**Discussion:** The results of this small pilot study support the use of retinal fundus imaging for detecting amyloid deposition that is correlated with brain amyloid PET SUVr. A larger sample size will be necessary to fully ascertain the relationship between amyloid PET and retinal amyloid both cross-sectionally and longitudinally.

#### KEYWORDS

Alzheimer's disease, amyloid, NeuroVision, positron emission tomography, retina, retinopathy

## 1 | INTRODUCTION

Biomarker developments have focused on detecting abnormal cerebral amyloid deposition at the preclinical stage of Alzheimer's disease (pAD). Identifying amyloid-positive asymptomatic subjects is critical for efforts designed to intervene in pAD therapeutically.<sup>1</sup> Even at this early preclinical stage, subtle cognitive decline is observed. Currently approved pAD biomarkers include amyloid-ligand positron emission tomography (PET) and cerebrospinal fluid (CSF) amyloid levels; both approaches have been used to identify individuals with preclinical and later-stage AD. The widespread use of such tests is limited currently due to the expense and invasiveness of such testing. The development of additional low-cost, non-invasive biomarkers to detect pAD pathologic changes is a priority in the field.

Coined the "window to the brain," the retina can develop similar pathologic features to those seen in the brain in neurodegenerative disease states, as they both originate from the same embryonic precursors.<sup>2</sup> Standard clinical retinal assessments in patients with neurodegenerative diseases, including AD, have shown alterations in the retinal tissue and vasculature, supporting this contention.<sup>3</sup> Multiple AD retinal imaging studies with clinically diagnosed patients have found AD-mediated retinal changes, such as retinal neuronal layer thinning and vascular alterations, through optical coherence tomography (OCT).<sup>4</sup> Studies in preclinical populations also observed retinal neuronal layer reduction associated with other biomarkers such as CSF amyloid and amyloid-PET.<sup>5,6</sup> In summary, these studies imply that the retina is susceptible to neurodegeneration in the AD state.

In addition to retinal thinning, AD-associated pathology such as extracellular amyloid plaques have been reported in *post mortem* AD retinal tissue through histological analysis.<sup>7,8</sup> As the retina can be monitored in a non-invasive manner, a few studies have sought to detect retinal pathology related to amyloid plaques in real-time through retinal fundal imaging. Retinal inclusion bodies were observed in a population with a family history of AD through BluePeak autofluorescence, with inclusion body surface area increasing as a function of amyloid-PET levels.<sup>9</sup> Hard drusen, often associated with age-related macular degeneration (AMD), were identified through ultra-widefield

retinal imaging in clinically diagnosed AD individuals and have also been shown to expand over time with disease progression.<sup>10</sup> Amyloid can be contained in drusen, as seen in AMD retinas.<sup>11</sup> These results imply that retinal deposits associated with amyloid may develop in AD patients. Curcumin, a fluorescent derivative of turmeric, binds to amyloid beta ( $A\beta$ ) plaques in *post mortem* AD brain tissues.<sup>12</sup> In vivo analysis from the Koronyo lab utilizing fundal imaging in persons pretreated with curcumin supplementation has identified curcumin-labeled deposits in the retinas of patients diagnosed with mild cognitive impairment (MCI) and mild to moderate AD.<sup>8,13</sup> To date, no other lab has replicated these observations, nor are there any other reports that have conducted retinal imaging studies to detect curcumin-labeled retinal amyloid plaques.

The Anti-Amyloid Treatment in Asymptomatic Alzheimer's Disease (A4) study is an active longitudinal trial including more than 1100 asymptomatic individuals identified using amyloid PET criteria for elevated fibrillar amyloid in the brain. Individuals who "screen-failed" out of the A4 study due to low levels of amyloid PET could opt into the Longitudinal Evaluation of Amyloid Risk and Neurodegeneration (LEARN) study, a longitudinal study running in parallel to the A4 trial that aims to further characterize preclinical AD compared to normal aging.<sup>14</sup> Participants in the LEARN study undergo the same clinical and cognitive tests as their A4 counterparts. While the trial's primary focus is testing the efficacy of an anti-amyloid intervention in a preclinical population, the trial also allows for novel biomarker development that can be supported by correlation with established AD biomarkers.<sup>15</sup> A recent report from the A4 cohort indicated that elevated amyloid PET levels corresponded with lower test performance, family history, and apolipoprotein E (APOE) status.<sup>14</sup>

Upon completing the double-blind portion, participants in the A4 trial can choose to continue treatment in an open-label extension phase, paralleled by extended observational follow-up in the LEARN cohort. The results from this extension will provide enhanced data on longer-term longitudinal outcomes and will further allow an extended period for discovery concerning both established and novel biomarkers for pAD.

The retinal imaging addendum to the A4 trial has three specific aims: (1) to characterize retinal amyloid in subjects with preclinical

AD prior to administration of the experimental treatment provided in the primary A4 study protocol, (2) to characterize the longitudinal trajectory of retinal amyloid in subjects with preclinical AD, and (3) to correlate retinal amyloid with brain amyloid and cognitive change. Approximately 50 A4 study participants across five A4 study sites elected to participate in the retinal imaging component, allowing for a thorough retinal assessment of pAD. Previous studies have used retinal fundus imaging to detect retinal amyloid in mildly cognitively impaired and clinically diagnosed AD patients, which are populations with demonstrated cognitive decline.<sup>8,13,16</sup> However, few studies have reported using this type of imaging to detect amyloid in the retina before the onset of behavioral and cognitive symptoms. The overall study is actively recruiting more participants from the A4 and LEARN trial to the retinal addendum, but the number of participants in this current study was limited as the retinal imaging addendum was approved when the main trial had started.

This small pilot study aims to (1) determine whether retinal amyloid expression can be detected in preclinical individuals and asymptomatic individuals and (2) ascertain the difference in retinal amyloid expression across individuals with elevated amyloid brain PET. Retinal scans from four A4 and four LEARN participants with similar demographic features were quantified regarding curcumin-laden retinal amyloid expression, and these results were compared to quantitative amyloid brain PET standardized uptake value ratio (SUVr) measurements. These scans were taken before randomization to quantify retinal amyloid at baseline without the influence of solanezumab.

## 2 | METHODS

### 2.1 | Study design

Subjects volunteering for the retinal amyloid imaging addendum were screened into the parent A4 or LEARN study based on amyloid PET results as previously described.<sup>15</sup> In this pilot study, participants with retinal scans prior to randomization were analyzed. Because the retinal imaging addendum was a late addition to the A4 trial, the number of participants in the current study was limited to four. Participants were excluded from the study if they had: any condition that might be harmed by retinal amyloid imaging; an allergy to curcumin; or any other condition that, in the opinion of the principal investigator, warranted exclusion. All participants in this study signed informed consent before participating in the addendum. Eligible participants underwent a baseline retinal amyloid scan after the fourth screening visit and before randomization. The previous published 10-day curcumin loading protocol was modified to a 2-day protocol. Curcumin concentrations in the blood and retinal deposit fluorescent intensity increased after 2 days of curcumin administration; therefore, the prescribed curcumin dose was adjusted to reach the previously reported curcumin concentrations.<sup>8</sup> Participants were instructed to consume 20 g (one packet) of Longvida curcumin twice daily (40 g/day) for 2 days (a total of 80 g) before the site visit and to avoid acidic food and liquid 1 hour before and after each dose to maximize absorption. The Longvida curcumin was mixed into

### RESEARCH IN CONTEXT

- 1. Systematic review:** Studies assaying retinal amyloid through fundus imaging with fluorescent probes have yielded promising results in clinically diagnosed dementia patients. However, to date no studies have used retinal fundus imaging to assess the progression of dementia. The Anti-Amyloid Treatment in Asymptomatic Alzheimer's Disease (A4) trial included a pilot retinal scanning protocol intended to investigate the diagnostic feasibility of retinal imaging for Alzheimer's disease (AD). In this pilot cross-sectional study, we analyzed retinal scans taken from four amyloid positron emission tomography (PET)-positive individuals and four amyloid PET-negative individuals for curcumin-labeled retinal deposits.
- 2. Interpretation:** We observed more retinal amyloid curcumin-labeled fluorescently positive deposits in four individuals with elevated amyloid PET levels compared to four individuals with low levels of amyloid PET. While a larger sample is necessary to establish the value of retinal amyloid for predicting amyloid PET or other methods of identifying the pathology of AD, our data suggest that amyloid is prevalent in the retinas of preclinical AD individuals.
- 3. Future directions:** Continuous retinal sampling of the A4 amyloid PET-positive population and Longitudinal Evaluation of Amyloid Risk and Neurodegeneration (LEARN) amyloid PET-negative population is necessary to fully assess the potential diagnostic applications of this approach to retinal imaging. Future studies focusing on the pathophysiology of the retinas of AD patients would inform the biological conditions required to form retinal amyloid deposits.

a liquid nutritional supplement such as Ensure and taken on an empty stomach. Although A $\beta$  plaques exhibit blue light autofluorescence,<sup>17,18</sup> curcumin binding to amyloid in vivo may increase the fluorescent signature, serving as a contrast reagent to highlight suspected retinal amyloid deposits. Previous studies have validated the use of Longvida curcumin as an in vivo tracer for retinal amyloid detection.<sup>8,19</sup> On the day of the retinal scanning session, individuals received one drop of 1% tropicamide and 2.5% phenylephrine in each eye and then sat in a darkened room until their pupils were dilated greater than 3.5 mm. Corrective lenses, such as spectacles or contact lenses, were removed during the examination to prevent reflection artifacts from obscuring the retinal scan. The RETIA 2 imaging system (EyeCare) is a Food and Drug Administration (FDA)-approved confocal scanning ophthalmoscope equipped to detect the fluorescence characteristics of curcumin in addition to naturally occurring fluorophores in the retina by

exciting with blue light at 450 nm and collecting emitted light above 500 nm.<sup>20</sup> Both eyes were scanned from each participant at the visit except in the case of cataracts impeding proper visualization of the retina. A minimum of six autofluorescent images was taken at three points in the central and superior regions of the retina, for a total of 18 autofluorescent images per region. An image was taken every 5 seconds to account for LED cycle time and a minimum of 90 seconds spent imaging each region. The superior regions are more likely to contain amyloid deposits, as demonstrated in the histologic evidence.<sup>6</sup> The A4 retinal imaging study is a subset of the parent A4 study; therefore, amyloid PET SUVR levels and thresholds were determined as previously described.<sup>14</sup>

## 2.2 | Sites

The A4 retinal imaging protocol was conducted across five A4 sites. Participants in this particular pilot study were pooled from the University of Kentucky and Butler Hospital Memory and Aging sites.

## 2.3 | Retinal image analysis

Retinal image analysis was performed as previously described.<sup>13,16</sup> Briefly, the set of retinal images was processed through an automated proprietary image analysis software system (NeuroVision Imaging, Inc.). The software algorithmically determined the quality of each set of retinal images, taking into account focus, contrast, variations in illumination, eye motion, obstruction, and fixation. The eight highest-scoring images from each set were further processed for quantification of retinal spots, referred to as spot count, as described previously.<sup>13,16</sup> A design of experiments exercise aiming to maximize measurement repeatability recognized that eight images were optimal using an 18-image study.

## 2.4 | Statistical analysis

Total spot count, amyloid PET SUVR, and age were summarized as medians and ranges and organized by amyloid positivity status.<sup>14</sup> The association between spot counts and amyloid PET SUVR was visualized with scatter plots, with separate linear regression trend lines for the left and right eyes and for the bilateral average of spot counts. The association between bilateral spot counts and amyloid PET SUVR was assessed using Pearson's correlation coefficient and its 95% confidence interval (CI). Spot counts were plotted by amyloid PET positivity status, and the difference in means between amyloid groups was provided along with the 95% CI. When spot counts from one eye were missing, the bilateral average from the other eye was used as the observed value. We also modeled bilateral spot counts using a linear mixed-effect (LME) model in which we included participant-specific random intercepts.<sup>21</sup> We considered two models: the first with a fixed effect for amyloid PET SUVR and the second with fixed effects for amyloid PET SUVR and side (left vs. right eye). We use the Akaike information criterion (AIC) to select the preferred model.

## 3 | RESULTS

Retinal scans from four participants in the A4 trial taken prior to randomization, along with four retinal scans from participants with similar demographics in the LEARN retinal imaging trial were analyzed. Participant information, amyloid PET SUVR, retinal spot counts, and APOE status are presented in Table 1. Right eye spot counts were missing for one amyloid-positive individual due to cataracts. In addition, the right eye scans of one amyloid-negative individual failed the quality check and were excluded from the analysis. Therefore, a total of 14 eyes were processed, 7 from each cohort. Equal numbers of female ( $n = 4$ ) and male ( $n = 4$ ) participants from the two cohorts were included in this pilot study. The minimum age was 65, the maximum age was 74, and the median age was 69 years. Two amyloid-positive individuals had an APOE genotype  $\epsilon 3/\epsilon 4$ , and the remaining two had APOE  $\epsilon 3/\epsilon 3$  and APOE  $\epsilon 2/\epsilon 3$ . All amyloid-negative individuals had an APOE  $\epsilon 3/\epsilon 3$  genotype. Individuals with SUVR values above 1.15 were designated amyloid-positive (median: 1.21, minimum: 1.16, maximum: 1.34), as previously described.<sup>14,22</sup> In contrast, the amyloid-negative individuals' SUVR values were below 1.15 (minimum: 0.90, maximum: 1.13, median: 1.01).

To evaluate the association between brain amyloid levels and retinal amyloid, we plotted retinal spot count against the SUVR values from all eight individuals. Total retinal spots varied between eyes in the same individual (Figure 1A). Both sides exhibited an increase in the number of spots that coincided with higher SUVR levels. The range of spot counts between eyes within a subject increased in individuals with SUVR values over 1.20, suggesting unequal amyloid expression in each retina. However, it is unclear if retinal amyloid accumulation favored a particular side (Figure 1B). Bivariate analysis indicated a modest positive association between SUVR values and total retinal spots (Pearson's  $r$ : 0.65, 95% CI: -0.093, 0.930; Figure 1C). Amyloid PET-negative individuals had fewer total spots (difference in means: -538, 95% CI: -979 to -97) compared to amyloid PET-positive individuals (Figure 1D). Furthermore, the range of the number of spots was greater for amyloid PET-positive individuals compared to amyloid PET-negative individuals. To account for the variance between samples, we implemented a LME<sup>21</sup> model in which we included subject-specific random intercepts. In addition to a fixed effect for amyloid PET SUVR, we also considered a fixed-effect covariate for side (left vs. right eye). The AIC preferred the model without the effect for side (AIC 189.6 vs. 191.6), which estimated the effect of amyloid PET SUVR to be 1611.5 spots per SUVR (95% CI -248.2 to 3471.1). The results from the LME are consistent with the ordinary least squares trend line and Pearson correlation shown in Figure 1C derived from bilateral averages (1608.1 spots per SUVR, 95% CI -246.2 to 3462.3).

## 4 | DISCUSSION

We provide evidence in this feasibility study that implies that retinal amyloid can be detected in the preclinical stage of AD and that such retinal pathology is associated with amyloid PET SUVR (Figure 1). All four individuals from the A4 trial exhibited more

**TABLE 1** Demographics of eight individuals from the A4 and LEARN retinal imaging cohorts

	Amyloid- (N = 4)	Amyloid+ (N = 4)	Total (N = 8)
Amyloid PET SUVR			
Median (range)	1.01 (0.90, 1.13)	1.21 (1.16, 1.34)	1.15 (0.90, 1.34)
Sex			
Female	2 (50.0%)	2 (50.0%)	4 (50.0%)
Male	2 (50.0%)	2 (50.0%)	4 (50.0%)
Age at consent			
Median (range)	69 (65, 74)	69 (65, 72)	69 (65, 74)
APOE			
$\epsilon 2/\epsilon 3$	0 (0.0%)	1 (25.0%)	1 (12.5%)
$\epsilon 3/\epsilon 3$	4 (100.0%)	1 (25.0%)	5 (62.5%)
$\epsilon 3/\epsilon 4$	0 (0.0%)	2 (50.0%)	2 (25.0%)
Spot count			
Median (range)	245.0 (178.5, 301.5)	750.2 (473.0, 1149.0)	387.3 (178.5, 1149.0)

Spot count values are the bilateral average of both eyes when data from both eyes are available.

Abbreviations: A4, Anti-Amyloid Treatment in Asymptomatic Alzheimer's Disease; APOE, apolipoprotein E; LEARN, Longitudinal Evaluation of Amyloid Risk and Neurodegeneration; PET, positron emission tomography; SUVR, standardized uptake value ratio.

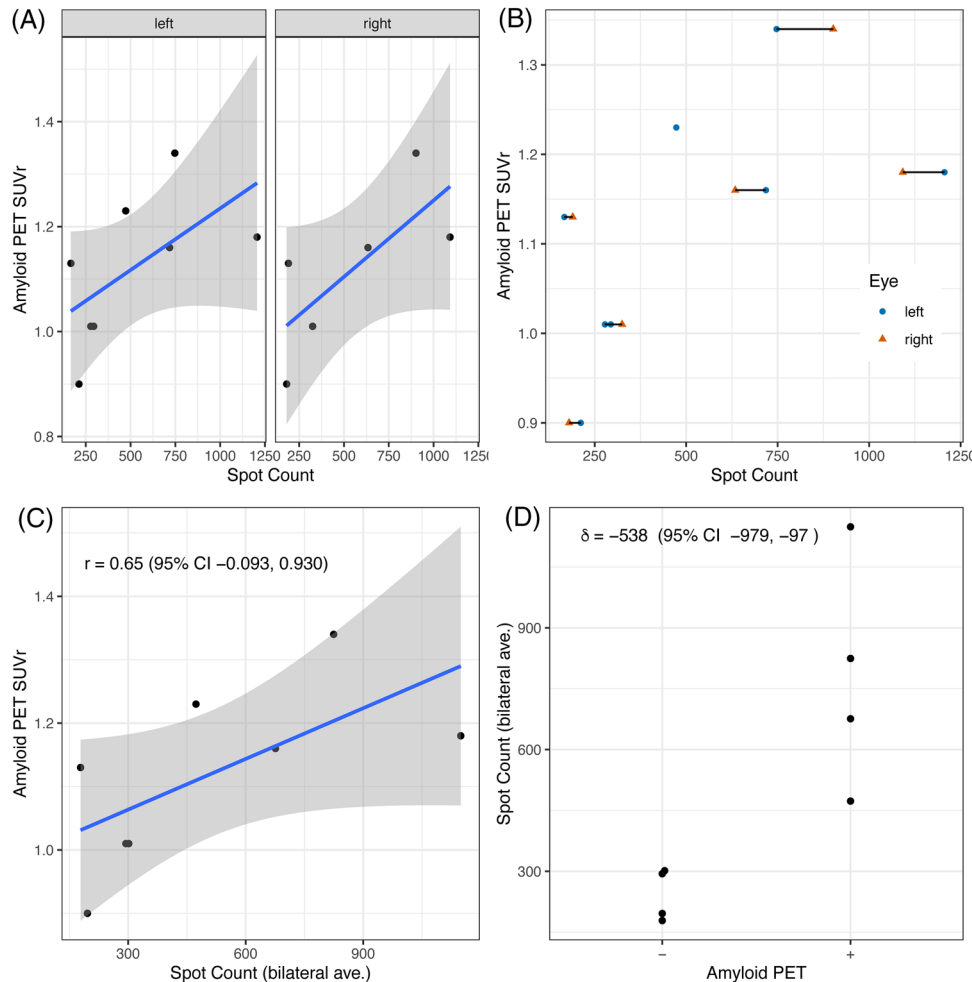
curcumin-positive spots in the retina compared to individuals from the LEARN trial, suggesting that a discernable difference exists between the two groups (Table 1). Previous studies into curcumin-labeled amyloid in the retina have studied clinically diagnosed individuals that exhibit cognitive deficits as early as MCI,<sup>8,10</sup> while retinal studies of preclinical cohorts have observed retinal inclusion bodies.<sup>9</sup> Our pilot study of the A4 retinal imaging prospective study extends the application of curcumin labeling, demonstrating that elevated levels of retinal curcumin-positive spots can be detected in amyloid PET-positive asymptomatic individuals. We aim to provide data in our feasibility study that can be used to design robust and well-powered retinal imaging studies.

OCT is the most common imaging modality used to study the AD patient retinas due to its widespread clinical use and availability, allowing a quantitative measure of retinal layer characteristics in real time. Although the degeneration of specific retinal layers has been suggested to reflect cortical atrophy in a single study,<sup>23</sup> other studies have observed no significant association with AD-mediated neurodegeneration.<sup>24</sup> Fundus imaging, while lacking axial resolution and potentially requiring contrast reagents, as in the present study, provides topological information about potential amyloid plaque accumulation that may be associated with brain amyloid accumulation.

Curcumin binds to amyloid *in vivo* and has been used as a contrast reagent to identify amyloid deposits in the retina of individuals diagnosed with MCI as well as mild to moderate AD.<sup>8,13</sup> While the total spots quantified in the Koronyo et al. study are lower than what is presented in our studies, this may be due to the use of different retinal imaging systems and quantification methods.<sup>8</sup> The algorithm-mediated analysis in the current study allows for unbiased, automated quantification of the retinal scans, reducing the likelihood of regional selection biases, inter-site and scan variability, and allowing for a standardized retinal amyloid quantification process. A recent reti-

nal study using a similar retinal fundus imaging system reported a region-specific increase of retinal spots in individuals diagnosed with MCI and AD, suggesting regional amyloid deposition may indicate disease progression.<sup>13</sup> The software used in this study is proprietary and may not be readily accessible, which may limit the feasibility of this study. However, a retinal imaging system's costs may be relatively small compared to the costs and infrastructure of PET imaging. Our curcumin loading protocol also differs from the Koronyo et al. study as we decreased the number of days required to take curcumin and compensated by increasing the amount of curcumin administered. While curcumin amounts were based on the 2017 Koronyo et al. study, a blood pharmacokinetic study would further confirm previous observations. Future studies should also include such analysis in their protocol. However, *in vivo* retinal curcumin labeling has confirmed amyloid deposits in the retina but is not essential for amyloid detection. Blue-light autofluorescence imaging without a contrast reagent was sufficient in detecting retinal amyloid deposits.<sup>9</sup> Contrast reagent-free quantification of retinal amyloid is currently under development, which may provide a more accessible method for retinal detection of pAD.

This study's limitations include small sample sizes and the fact that scans were obtained from different retinal imaging devices (albeit the same system) at different test sites. Due to the potential effects of solanezumab study treatment on amyloid PET SUVR and retinal spot counts, only participants with retinal scans prior to randomization were included in this study. Other factors such as cataracts and image quality further reduced the total number of eyes analyzed. While some of these variables are unavoidable, these issues must be considered in future studies when recruiting for a retinal imaging study. Advance screening of participants for potential cataracts before imaging would ensure that data are retrieved from both eyes. However, we believe that retinal trends are apparent and demonstrate a discernable



**FIGURE 1** Comparison of retinal amyloid to brain amyloid. A, Total retinal spot counts from each eye over amyloid positron emission tomography (PET) standardized uptake value ratio (SUVR; left eye:  $n = 8$ , right eye:  $n = 6$ ). B, Plot of total retinal spots from both eyes of each individual ( $n = 8$ ). C, Distribution of bilateral average retinal spots from all eyes ( $n = 8$ ) with Pearson's correlation ( $r$ ) and 95% confidence interval (CI). D, Distribution of bilateral average spots grouped by amyloid PET SUVR level (amyloid+:  $n = 4$ , amyloid-:  $n = 4$ ) and difference in means ( $\delta$ ) with 95% CI

difference that is worth reporting. More importantly, these data further align with previous retinal fundus imaging trials in AD patients. As the A4/LEARN retinal imaging trial is ongoing, we can expect to collect longitudinal data that will allow for a more comprehensive analysis of retinal amyloid changes over time. Larger sample sizes will allow us to look into the effects of sex and age on AD-associated retinal changes. A larger sample size allows for additional analysis to factor in effects from other AD cofactors such as family history, *APOE* status, and cognitive ability.

We observed a modest correlation between brain PET SUVR and retinal spot count, suggesting a pathologically relevant relationship between the brain and the retina. While a recent study suggests a relationship between the primary visual cortex and the inner plexiform layer of the retina,<sup>25</sup> multiple regions of the neocortex were measured to calculate SUVR in this current study. Future retinal imaging study designs may consider measuring other brain regions associated with the retina, such as the lateral geniculate and primary visual cortex. Measurements of other layered regions such as the hippocampus may

yield exciting results, as a recent curcumin retinal study observed an inverse correlation between retinal spots and hippocampal volume.<sup>13</sup>

We implement both bivariate and mixed model approaches in analyzing our data to demonstrate that even though our sample is small, we arrived at the same results regardless of the method chosen. Averaging values, especially in small data sets, may hide variations within the dataset. We achieved smaller confidence interval widths by using LME in our small dataset. While our conclusions remain the same regardless of the analysis in our study, future studies with larger datasets should undoubtedly consider implementing LME in their data analysis.

In summary, we detected elevated curcumin fluorescence levels suggesting that amyloid is present in the retinas of asymptomatic amyloid PET-positive individuals. The retinal imaging section of the A4 trial is actively recruiting individuals, which will provide data to characterize retinal amyloid pathogenesis. Determining the onset, spread, and morphology of AD will guide the use of retinal imaging as a biomarker for preclinical diagnosis.



## ACKNOWLEDGMENT

This project was supported by NIH/NIA grant AG070595 and funding for the substudy from NeuroVision Imaging, Inc. to the University of California, San Diego.

## CONFLICTS OF INTEREST

Ken Johnson is an employee at NeuroVision Imaging Inc.

## HUMAN INFORMED CONSENT STATEMENT

All participants in this study signed informed consent before participating in this study.

## REFERENCES

- Jack CR, Albert MS, Knopman DS, et al. Introduction to the recommendations from the National Institute on Aging-Alzheimer's Association workgroups on diagnostic guidelines for Alzheimer's disease. *Alzheimer Dement*. 2011;7:257-262.
- London A, Benhar I, Schwartz M. The retina as a window to the brain—from eye research to CNS disorders. *Nat Rev Neurol*. 2013;9:44-53.
- Nguyen CTO, Hui F, Charng J, et al. Retinal biomarkers provide "insight" into cortical pharmacology and disease. *Pharmacol Ther*. 2017;175:151-177.
- Alber J, Goldfarb D, Thompson LI, et al. Developing retinal biomarkers for the earliest stages of Alzheimer's disease: what we know, what we don't, and how to move forward. *Alzheimers Dement*. 2020;16:229-243.
- Asanad S, Ross-Cisneros FN, Nassisi M, Barron E, Karanjia R, Sadun AA. The retina in Alzheimer's disease: histomorphometric analysis of an ophthalmologic biomarker. *Invest Ophthalmol Vis Sci*. 2019;60:1491-1500.
- Santos CY, Johnson LN, Sinoff SE, Festa EK, Heindel WC, Snyder PJ. Change in retinal structural anatomy during the preclinical stage of Alzheimer's disease. *Alzheimer's Dement*. 2018;10:196-209.
- La Morgia C, Ross-Cisneros FN, Koronyo Y, et al. Melanopsin retinal ganglion cell loss in Alzheimer disease. *Ann Neurol*. 2015;79:90-109.
- Koronyo Y, Biggs D, Barron E, et al. Retinal amyloid pathology and proof-of-concept imaging trial in Alzheimer's disease. *JCI Insight*. 2017;2 16:e93621.
- Snyder PJ, Johnson LN, Lim YY, et al. Nonvascular retinal imaging markers of preclinical Alzheimer's disease. *Alzheimer's Dement*. 2016;4:169-178.
- Csincsik L, MacGillivray TJ, Flynn E, et al. Peripheral retinal imaging biomarkers for Alzheimer's disease: a pilot study. *Ophthalmic Res*. 2018;59:182-192.
- Dentchev T, Milam AH, Lee VMY, Trojanowski JQ, Dunaief JL. Amyloid- $\beta$  is found in drusen from some age-related macular degeneration retinas, but not in drusen from normal retinas 11 Edited by Hans E. Grossniklaus, MD. *Am J Ophthalmol*. 2003;136:787.
- Yang F, Lim GP, Begum AN, et al. Curcumin inhibits formation of amyloid  $\beta$  oligomers and fibrils, binds plaques, and reduces amyloid in vivo. *J Biol Chem*. 2004;280:5892-5901.
- Dumitrascu OM, Lyden PD, Torbati T, et al. Sectoral segmentation of retinal amyloid imaging in subjects with cognitive decline. *Alzheimer's Dement*. 2020;12:e12109.
- Sperling RA, Donohue MC, Raman R, et al. Association of factors with elevated amyloid burden in clinically normal older individuals. *JAMA Neurol*. 2020;77:735.
- Sperling RA, Rentz DM, Johnson KA, et al. The A4 study: stopping AD before symptoms begin? *Sci Transl Med*. 2014;6:228fs13-228fs13.
- Kile S, Au W, Parise C, et al. Reduction of amyloid in the brain and retina after treatment with ivig for mild cognitive impairment. *Am J Alzheimers Dis Other Dement*. 2020;35:153331751989980.
- Chan FTS, Pinotsi D, Gabriele S, et al. *Bio-nanoimaging*. Boston: Academic Press; 2014:147-155.
- Thal DR, Ghebremedhin E, Haass C, Schultz C. UV light-induced autofluorescence of full-length Abeta-protein deposits in the human brain. *Clin Neuropathol*. 2002;21:35-40.
- Kayabasi U, Sergott RC, Rispoli M. Retinal examination for the diagnosis of Alzheimer's Disease. *J Ophthalmic Pathol*. 2014;3(4).
- 510(k) Premarket Notification. US Food and Drug Administration n.d. <https://www.accessdata.fda.gov/scripts/cdrh/cfdocs/cfPMN/pmn.cfm?ID=K180293> (accessed April 8, 2021).
- Laird NM, Ware JH. Random-effects models for longitudinal data. *Biometrics*. 1982;38:963-974.
- Johnson KA, Sperling RA, Gidicsin CM, et al. Florbetapir (F18-AV-45) PET to assess amyloid burden in Alzheimer's disease dementia, mild cognitive impairment, and normal aging. *Alzheimers Dement*. 2013;9:S72-83.
- Shi Z, Zhu Y, Wang M, et al. The utilization of retinal nerve fiber layer thickness to predict cognitive deterioration. *J Alzheimers Dis*. 2015;49:399-405.
- den Haan J, Janssen SF, van de Kreeke JA, Scheltens P, Verbraak FD, Bouwman FH. Retinal thickness correlates with parietal cortical atrophy in early-onset Alzheimer's disease and controls. *Alzheimer Dement*. 2017;10:49-55.
- Jorge L, Canário N, Martins R, et al. The retinal inner plexiform synaptic layer mirrors grey matter thickness of primary visual cortex with increased amyloid  $\beta$  load in early Alzheimer's disease. *Neural Plast*. 2020;2020:8826087.

**How to cite this article:** Ngolab J, Donohue M, Belsha A, et al. Feasibility study for detection of retinal amyloid in clinical trials: The Anti-Amyloid Treatment in Asymptomatic Alzheimer's Disease (A4) trial. *Alzheimer's Dement*. 2021;13:e12199. <https://doi.org/10.1002/dad2.12199>