

CASE REPORT

Case report of myometrial window following fetoscopic treatment of twin-twin transfusion syndrome: indications of underlying collagen vascular disease?

Michael V. Zaretsky^{1,2} , David K. Manchester^{1,3}, Henry L. Galan^{1,2}, Nicholas J. Behrendt^{1,2}, Ahmed I. Marwan^{1,4}, Kenneth W. Liechty^{1,4} & Timothy M. Crombleholme^{1,4}

¹Colorado Fetal Center, Colorado Institute for Maternal and Fetal Health, Aurora, Colorado, USA

²Division of Maternal Fetal Medicine, Children's Hospital Colorado, University of Colorado School of Medicine, Aurora, Colorado, USA

³Division of Genetics, Children's Hospital Colorado, University of Colorado School of Medicine, Aurora, Colorado, USA

⁴Division of Pediatric General, Thoracic and Fetal Surgery, Children's Hospital Colorado, University of Colorado School of Medicine, Aurora, Colorado, USA

Correspondence

Michael V. Zaretsky, Colorado Fetal Care Center, 13123 East 16th Avenue, Aurora, Colorado 80045, USA. Tel: 214-868-8046; Fax: 720-777-7960; E-mail: Michael.Zaretsky@ucdenver.edu

Funding Information

No sources of funding were declared for this study.

Received: 31 October 2016; Revised: 31 January 2017; Accepted: 4 February 2017

Clinical Case Reports 2017; 5(6): 975–979

doi: 10.1002/ccr3.885

Introduction

Twin-twin transfusion syndrome (TTTS) is a complication of monochorionic/diamniotic twin gestation with an estimated incidence of 8–10% [1]. The diagnosis of TTTS is based on ultrasound criteria that involve amniotic fluid discordance, the appearance of the fetal bladder, and Doppler waveforms of the umbilical artery and vein and ductus venosus [2]. It results from unbalanced flow across vascular anastomoses within the shared placenta. If this unbalance is significant, it results in the donor twin developing oliguria, oligohydramnios, volume depletion, and fetal growth restriction. The recipient develops volume overload, polyuria, polyhydramnios, and hypertensive cardiomyopathy. Untreated TTTS has an 80% mortality rate and 6–18% risk of neurodevelopmental sequelae such as cerebral palsy in survivors without treatment [3, 4]. Fetoscopic laser ablation is widely accepted and the preferred treatment for TTTS [5].

Key Clinical Message

Intraperitoneal amniotic fluid leak is a known complication of fetoscopic procedures that usually resolves spontaneously with expectant management. Intraperitoneal amniotic fluid leak may persist after fetoscopic procedures due to a myometrial window as well as to persistent chorioamniotic membrane disruption, which may be amenable to surgical repair.

Keywords

Amniotic fluid leak, case report, complications, fetoscopy, intraperitoneal, myometrial defect, twin-twin transfusion syndrome.

Minimally invasive fetal procedures such as fetoscopic laser photocoagulation carry the potential for trocar-related complications as a result of traversing the myometrium, chorion, and amnion. In a study of fetoscopic complications by Habli and colleagues with 152 cases of fetoscopic laser ablation, there was a 10.5% incidence of membrane complications including chorioamniotic membrane separation, intertwin membrane disruption, amniotic banding, and peritoneal leak. This is in addition to the 25% rate of preterm premature rupture of membranes in their series [6]. Leaking of fluid into the peritoneum can result after introduction of a trocar into the amniotic sac especially in the setting of significant hydramnios where amniotic pressure is higher and an anterior placenta which requires more manipulation of the fetoscope resulting in backtracking of fluid along the path of the sheath. Fluid re-accumulation within the amniotic sac is almost always observed in a matter of days. We report a case of persistent intraperitoneal amniotic fluid leakage

without resolution necessitating operative repair to allow the completion of fetoscopic laser photocoagulation.

Case

A 29-year-old, gravida 2 para 1 presented at 19 weeks and 4 days for evaluation. Her past medical and surgical histories were uncomplicated. Her obstetric history is significant for a spontaneous vaginal delivery at 37 weeks of a 5 lb 11 oz female infant after spontaneous rupture of membranes. Ultrasound examination revealed a mono-chorionic/diamniotic twin gestation with a right-posterior placenta. The recipient twin was presenting and had normal umbilical artery, umbilical vein, and middle cerebral artery Doppler studies. The ductus venosus had a positive a wave with an elevated S/a ratio. The deepest vertical pocket of amniotic fluid (DVP) was 14 cm. The donor twin was located superior to the recipient and to the maternal left. A bladder was not visualized, and the umbilical artery Doppler demonstrated absent end-diastolic flow in one artery and intermittent absent end-diastolic flow in the other. The umbilical vein, ductus venosus, and middle cerebral artery Dopplers were normal. The DVP was 0.8 cm. A transvaginal cervical length measured 2.2 cm.

The fetal echocardiogram for the recipient demonstrated a monophasic tricuspid and mitral inflow patterns without tricuspid or mitral regurgitation. There was mildly depressed biventricular function with elevated myocardial performance indices (MPI) of 0.7 for the right ventricle and 0.5 for the left ventricle indicating severe TTTS cardiomyopathy. The donor fetus had a normal echocardiogram.

She was diagnosed with stage III Quintero/stage IIIC Cincinnati (IIIC indicating severe TTTS cardiomyopathy in the recipient twin) TTTS. She underwent selective fetoscopic laser photocoagulation at 19 weeks and 5 days under combined spinal/epidural regional anesthetic with sedation. The point of trocar insertion was chosen just inferior and to the right of the umbilicus. An 11-blade scalpel created a 4-mm stab wound in the skin through which a 3.3-mm fetoscopic port with pyramidal tip trocar (Karl Storz GmbH and Co, Tuttlingen, Germany), that has a lens port and two working ports, was directly inserted under ultrasound guidance into the recipient twin's amniotic sac. The telescope utilized was a miniature straight forward scope with 0° direction of view with outer diameter of 2 mm. Upon entry, we completely mapped the vascular anastomoses, but then there was an abrupt loss of visualization due to loss of amniotic fluid into the maternal peritoneal cavity and decompression of the recipient twin sac. Ultrasound imaging revealed marked fluid accumulation posterior to the uterus and

within the cul-de-sac. We abandoned the procedure secondary to inability to maintain adequate intramniotic fluid level to allow visualization of vessels on the placenta surface despite attempts of amnioinfusion with a level I infusion device (Smiths Medical, St. Paul, MN).

An immediate, postoperative transvaginal ultrasound demonstrated a shortened cervix to 1.7 cm for which a McDonald cerclage was performed. She was observed overnight and discharged to local accommodations with plan for biweekly follow-up with the expectation that the fluid within the recipient gestational sac will re-accumulate. After 2 weeks of ultrasound surveillance, there was no significant fluid re-accumulation and there was persistent fluid visualized in the cul-de-sac. The DVP of the recipient was 1.1 cm, and there was anhydramnios in the donor sac. During this time period, there was progression of recipient twin cardiomyopathy and development of twin anemia-polycythemia sequence (TAPS). The donor twin had a middle cerebral artery (MCA) peak systolic velocity (PSV) of >2.0 multiples of the median (MOM) and the recipient with MCA PSV <0.8 MOM. The patient denied leaking amniotic fluid from the vagina and speculum examination failed to reveal rupture of membranes. To confirm continued amniotic fluid leak into the abdomen, she underwent an ultrasound-guided amnioinfusion of 800 mL of normal saline into the recipient sac utilizing a 20-gauge spinal needle at 22-week and 1-day gestation. A possible thin, hypoechoic track through the myometrium inferior to the initial abdominal skin insertion site was visualized on ultrasound (Fig. 1). In addition, there was accumulation of fluid anterior and posterior to the uterus with no leakage of fluid vaginally. An intertwin membrane septostomy was suspected due to fluid accumulation in both the recipient and donor sacs. She was taken back to the operating room at 22-week and 2-day gestation, which was 17 days after the initial procedure, for an ultrasound-guided amnioinfusion, mini-laparotomy, and repeat fetoscopic procedure. Under regional anesthesia and sedation, a 1500 mL amnioinfusion was completed. A 4-cm mini-laparotomy was performed above the suspected area of leakage, which was located 4 cm below the original skin insertion site. Upon entry into the peritoneum, a one-centimeter myometrial defect with protruding membranes was easily identified (Fig. 2). A # 0-PDS purse-string suture was placed into the myometrium circumferentially around the defect while replacing the membranes back through the defect. Prior to and in addition to tying the suture, CoSeal (Baxter Healthcare Corp), a biocompatible polyethylene glycol polymer, was injected into the myometrial defect with the intent of an enhanced watertight seal. A second and third suture was utilized to imbricate the myometrium over the defect (Fig. 2).

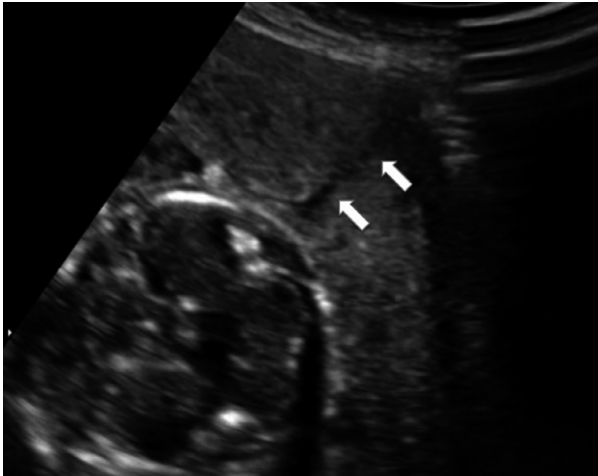


Figure 1. Suspected hypoechoic tract (arrows) seen on abdominal ultrasound through the myometrium following ultrasound-guided amnioinfusion located inferior to the initial abdominal skin incision.

Once we corrected the defect, a fetoscopic entry point was chosen just to the left and inferior to the umbilicus. Due to the noted septostomy, most of the fluid from the amnioinfusion was visualized within the donor sac with a DVP of 8 cm. For this reason, entry was made within the donor sac. Upon fetoscopic entry, the anastomoses previously mapped in the first procedure were identified and successfully laser photocoagulated. No decompression of amniotic fluid was experienced during this second entry perhaps secondary to lack of significant hydramnios. However, after removal of the fetoscope, the mini-laparotomy incision was utilized to inspect the fetoscopic entry site, which once again showed an open one-centimeter myometrial defect leaking amniotic fluid. A # 0-PDS suture was again utilized to place a purse-string suture

circumferentially around the defect to prevent further leaking. Once completed, the abdominal incision was closed.

She was observed in the hospital for two postoperative days with noted stabilization of DVPs in both sacs. Fluid within the peritoneal cavity was no longer visualized. She was discharged to local accommodations and for outpatient surveillance biweekly.

As a result of this unusual presentation, a medical geneticist evaluated the patient. She reported a history of bruising easily, but never considered herself loose jointed. In addition to the uterine findings, the patient's physical examination found only minor findings including a narrow nose and prominent venous pattern across her chest. As a precaution, a maternal echocardiogram was ordered and reported as normal. Additionally, maternal blood was sent for deletion/duplication analysis of the *COL3A1* gene for Ehler-Danlos type IV, vascular type, and was negative. This, however, did not preclude the possibility of another connective tissue disorder. Although sequencing of the *COL3A1* gene did not reveal any pathogenic mutation, we recommended further genetic testing to rule out collagen vascular disease including an Ehler-Danlos panel, which would test for 12 different genes. After further counseling regarding her options, the patient elected to forego any further testing.

Both TAPS and recipient twin cardiomyopathy resolved on postoperative day #12. She was then allowed to travel to her referring maternal fetal medicine specialist for continued surveillance. She ultimately delivered at 27 weeks and 6 days by cesarean delivery due to precipitous labor in the setting of cerclage with dual survival and infants weighing 2 lb 2 oz and 1 lb 7 oz. There were no reports of myometrial defects at the time of cesarean.

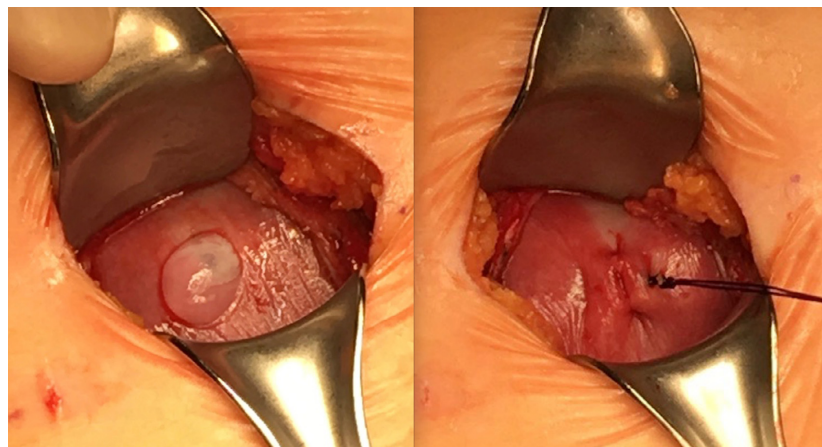


Figure 2. Myometrial defect with protruding fetal membranes and appearance of the surgical repair after tying the purse-string suture.

Discussion

Intraperitoneal amniotic fluid leakage is a less commonly reported complication of invasive fetal procedures. It has been reported as early as 1991 after bilateral thoracoamniotic shunting by Ronderos-Dumit and colleagues [7]. Amniotic fluid re-accumulation after the myometrium seals are almost uniformly observed. The feature common to both the Ronderos-Dumit case and ours appears to be a markedly elevated DVP prior to instrumentation which is associated with thinning of the myometrium. In the Eurofetus randomized trial of amnioreduction versus laser ablation by Senat and colleagues, there were two cases of 72 where there was a peritoneal leak [5]. Both of the cases were managed expectantly and resolved spontaneously. In two series by Habli and Rustico and colleagues after 149 and 150 fetoscopic procedures, respectively, for TTTS, each reported an incidence of intraperitoneal leak of 1.3% [6, 8]. Yammamoto and colleagues reported on a series of 175 cases of fetoscopy with an incidence of 7.4% [9]. In a personal series of over 1000 cases, transient peritoneal leakage following fetoscopic surgery complicates 8% of cases with a DVP ≥ 13 cm and an anterior placenta [10]. In a series of 64 cases by Morris *et al.*, there were three cases of presumed peritoneal leak with maternal abdominal pain postprocedure [11]. However, they did not see development of oligohydramnios in these cases. Persistent amniotic fluid leak as described in our case has not been reported.

In one remarkable case report, Cooper and colleagues completed a fetoscopic laser photocoagulation at nearly 17 weeks after which the recipient twin developed oligohydramnios [12]. An extrauterine cystic collection of fluid developed at the site of trocar insertion reaching a maximum diameter of 10 cm. With expectant management, the DVP normalized in the recipient sac, and the extrauterine cystic area remained stable. The pregnancy was delivered at nearly 34 weeks by cesarean section where it was revealed that the cystic area was membrane that had torsed on its pedicle as it herniated through a myometrial defect.

The frequency of peritoneal leak in the setting of different fetoscopic equipment has not been established. Specifically whether the utilization of a smaller caliber sheath or whether a direct or Seldinger entry impacts this complication frequency is unknown. It would seem feasible, however, that smaller instrumentation and less fetoscope manipulation would result in fewer membrane complications.

The particular entry sites in this case were neither in a thin nor in a more vulnerable area of the uterus such as the cornua. More manipulation of the fetoscope can result in stretching or injury to the myometrium

especially when trying to visualize anastomoses in an anterior placenta. In this case, the placenta was posterior. The patient's DVP was 14 cm and increased amniotic fluid pressure alone or in the setting of contractions may be the mechanism which increases the chance of peritoneal leak. It is not known whether tocolysis may reduce the risk of peritoneal leak. Nearly all of our patients receive nifedipine 20 mg every six hours to treat TTTS cardiomyopathy and therefore are receiving tocolysis during fetoscopy.

It is our practice to abandon the fetoscopic procedure when there is an acute decompression of amniotic fluid into the peritoneal cavity along the track created by fetoscope insertion. Even with the use of a level I rapid infusion device to instill fluid into the amniotic cavity, visualization is compromised resulting in the inability to successfully complete the procedure. Patients are then seen twice weekly to await amniotic fluid accumulation in the recipient sac. Once an adequate DVP has been established, the patient is taken back for a second procedure. This is the first case where an adequate fluid level was never re-established. The progression in severity of TTTS and risk of single or double fetal demise necessitated a solution to continued intraperitoneal leak and to allow successful completion of laser ablation of the surface anastomoses. Radiofrequency ablation of one twin was an alternative that was offered and declined by the family.

Because of this unique presentation of the combination of cervical incompetence and myometrial windows resulting from each fetoscope insertion, we suspected a maternal collagen vascular disease due to lack of resolution of intraperitoneal leak. In a series of 565 patients, Murray and colleagues determined a 14.5% rate of life-threatening pregnancy complications and specifically a 2.6% uterine rupture rate with Ehlers-Danlos type IV [13]. Although we ruled out a mutation in the *COL3A1* gene for Ehlers-Danlos type IV, we have not excluded other connective tissue disorders or abnormalities specific to the myometrium, and we remain concerned about this possibility in this patient. We discussed more extensive testing with the patient, and she elected against further evaluation.

In summary, this is the first reported case of persistent postfetoscopic intraperitoneal amniotic fluid leakage necessitating operative repair to allow for the adequate treatment of TTTS. The failure of the myometrial window to close prompted consideration of an underlying collagen vascular disorder.

Authorship

MVZ: is the corresponding author and responsible for the final conception, design, and drafting of the manuscript. DKM, HLG, NJB, AIM, KWL, and TMC: provided

substantial contributions to the conception and design, critical revisions and gave final approval of the submitted version.

Conflict of Interest

The authors would like to acknowledge that there are no conflicts of interest.

References

- Bornick, P. W., P. K. Johnson, M. Kruger, Society for Maternal-Fetal Medicine Publications Committee. 2013. Twin-twin transfusion syndrome. *Am. J. Obstet. Gynecol.* 208:3–18.
- Quintero, R. A., W. J. Morales, M. H. Allen, PW. Bornick, PK. Johnson, and M. Kruger 1999. Staging of twin-twin transfusion syndrome. *J. Perinatol.* 19:550–555.
- Fieni, S., D. Gramellini, G. Piantelli, C. Verrotti, and D. Cavallotti 2004. Twin-twin transfusion syndrome: a review of treatment option. *Acta. Biomed.* 75:34–39.
- Lopriore, E., E. Ortibus, R. Acosta-Rojas, JM. Middeldorp, and D. Oepkes. 2009. Risk factors for neurodevelopment impairment in twin-twin transfusion syndrome treated with fetoscopic laser surgery. *Obstet. Gynecol.* 113:361–366.
- Senat, M. V., J. Deprest, M. Boulvain, A. Paupe, N. Winer, and Y. Ville 2004. Endoscopic laser surgery versus serial amnioreduction for severe twin-to-twin transfusion syndrome. *N. Engl. J. Med.* 351:136–144.
- Habli, M., A. Bombrys, D. Lewis, F. Y. Lim, W. Polzin, R. Maxwell, et al. 2009. Incidence of complications in twin-twin transfusion syndrome after selective fetoscopic laser photocoagulation: a single-center experience. *Am. J. Obstet. Gynecol.* 201:417. e1–7.
- Ronderos-Dumit, D., U. Nicolini, J. Vaughan, N. M. Fisk, P. F. Chamberlain, and C. H. Rodeck 1991. Uterine-peritoneal amniotic fluid leakage: an unusual complication of intrauterine shunting. *Obstet. Gynecol.* 78:913–915.
- Rustico, M. A., M. M. Lanna, S. Faiola, V. Schena, M. Dell'avanzo, V. Mantegazza, et al. 2012. Fetal and maternal complications after selective fetoscopic laser photocoagulation for twin-to-twin transfusion syndrome. *Fetal Diagn. Ther.* 31:170–178.
- Yamamoto, M., L. El Murr, R. Robyr, F. Leleu, Y. Takahashi, and Y. Ville 2005. Incidence and impact of perioperative complications in 175 fetoscopy-guided laser coagulations of chorionic plate anastomoses in fetofetal transfusion syndrome before 26 weeks of gestation. *Am. J. Obstet. Gynecol.* 193:1110–1116.
- Cromblehome, T. M.. 2016. Personal communication, unpublished observation.
- Morris, R., T. Selman, A. Harbidge, W. I. Martin, and M. D. Kilby 2010. Fetoscopic laser coagulation for severe twin-to-twin transfusion syndrome: factors influencing perinatal outcome, learning curve of the procedure and lessons for new centres. *BJOG* 117:1350–1357.
- Cooper, S. L., S. Spence, D. Somerset, R. Windrim, and G. Ryan 2016. Iatrogenic Myometrial defect following fetoscopic laser therapy for twin-twin transfusion syndrome (TTTS). *Obstet. Gynecol. Cases Rev.* 3:069.
- Murray, M. L., M. Pepin, S. Peterson, and P. H. Byers 2014. Pregnancy-related deaths and complications in women with vascular Ehlers-Danlos syndrome. *Genet. Med.* 16:874–880.