

Case Report

Association of Ultrapure Citicoline, Homotaurine and Vitamin E in the Management of Normotensive Glaucoma: A Case Report

Tommaso Verdina^{a, b} Nicola Passarelli^b Alessandra Carlini^b
Francesca Chemello^c Rodolfo Mastropasqua^a Gian Maria Cavallini^a

^aInstitute of Ophthalmology, University of Modena and Reggio Emilia, Modena, Italy;

^bCentro Oculistico Diagnostico Chirurgico, Firenze, Italy; ^cOphthalmology Unit
Department of Neurological, Neuropsychological, Morphological and Movement
Sciences, University of Verona, Verona, Italy

Keywords

Normotensive glaucoma · Visual field · Citicoline · Homotaurine · Neuroprotection

Abstract

Normal tension glaucoma (NTG) remains a therapeutic challenge for the ophthalmologist since there are no effective therapies as the main therapeutic target, i.e., the intraocular pressure (IOP) increase, is missed. We report on the effectiveness of two neuroprotective molecules (ultrapure citicoline plus homotaurine), in combination with a topical hypotensive approach, in the management of NTG in a long-term follow-up (30 months). A 38-year-old Caucasian woman with no significant medical history and a diagnosis of NTG, after an extensive 30-month treatment with oral dietary supplement containing ultrapure citicoline 500 mg, homotaurine 50 mg and vitamin E once per day and topical glaucoma medication (brimonidine + brinzolamide drops twice per day), presented a significantly improved automated 24-2 visual field with a controlled tonometric measurement associated with a stabilization of retinal fiber layer and ganglion cells at OCT examination with patient satisfaction. This finding suggests that ultrapure citicoline together with homotaurine and vitamin E, through a synergistic neuroprotective effect, could be a promising approach in the management of NTG.

© 2020 The Author(s)
Published by S. Karger AG, Basel

Introduction

Normal tension glaucoma (NTG) is a form of open-angle glaucoma (OAG), which presents with typical alterations of the optic nerve head and functional visual field loss but normal intraocular pressure (IOP) findings [1].

The incidence is 30–40% of all patients diagnosed with a glaucomatous visual field defect; the etiology has not been well defined yet, however, it seems to be multifactorial and it is often associated with vascular dysregulation, nocturnal hypotension and abnormal optic nerve perfusion [2].

The treatment of NTG is somehow discussed since it misses the major therapeutic target, i.e., the elevated IOP. The Collaborative Normal Tension Glaucoma Study showed that patients in whom 30% or more reduction of IOP is achieved have a slowed disease progression [3]. Topical brimonidine-treated patients seem to have less likely visual field progression compared to timolol-treated patients [4]; however, the current gold standard in medical therapy for NTG is the use of topical prostaglandin analogues [5, 6]. In recent years, attention has shifted towards systemic neuroprotection in OAG with specific nutritional supplementations; however, their use in NTG is still discussed [7, 8].

Ultrapure citicoline or cytidine-5-diphosphochilone (CDP-choline, Cognizin®) is an endogenous molecule crucial in the processes of formation and restoration of the neuron cells interacting with the synthesis of phospholipids of membrane cells [9]; moreover, this molecule is important for the formation of acetylcholine, which is an essential neurotransmitter for nerve impulses in brain tissue. Its neuroprotective action has been proven in many neurodegenerative disorders such as Alzheimer disease, Parkinson disease and glaucoma [10]. Ultrapure citicoline has also shown to improve attentional performances in healthy adult women and to improve psychomotor speed in adolescent males [11, 12].

Homotaurine (3-aminopeopanesulfonate) is an amino acid derivative that can help to improve the propagation of nervous impulse in the central nervous system. A recent study demonstrated that the co-treatment with citicoline and homotaurine has a positive and synergistic effect on cell survival in retinal cultures simulating retinal neurodegeneration in experimental conditions. [13].

Vitamin E (alpha-tocopherol) is an antioxidant molecule that promotes cellular protection [14].

We report a case of a young female treated with ultrapure citicoline, homotaurine and vitamin E in the management of NTG.

Case Report

A 38-year-old woman was referred to our service for a general ophthalmological visit (baseline visit). No significant general diseases were encountered. She referred frequent migraine episodes. No family history for ocular diseases was registered. Best corrected visual acuity was 20/20 with refraction of -0.75 and -1.75 (170) in the right eye (RE) and 20/20 with -2.00 (160) in the left eye (LE). The IOP was 14 and 12 mm Hg for the RE and LE, respectively. The anterior segment biomicroscopy was unremarkable bilaterally. The iridocorneal angle was opened within normality with all angle's structures well visible. During the ophthalmoscopy, an abnormal excavation of the optic nerve head was found bilaterally. A Humphrey visual field (HVF, Carl Zeiss Meditech, Dublin, CA, USA) 24-2 SITA standard testing and a retinal nerve fiber layer (RNFL), ganglion cells (GC) and corneal pachymetry examination at the

OCT (Cirrus 4000 HD-OCT, Carl Zeiss Meditec, Dublin, CA, USA) were performed (Fig. 1, Fig. 2, Fig. 3).

In particular, the mean deviation (MD) in RE was -11.70 and in LE -5.45 . False negative errors were 26% in RE and 0% in LE. The mean RNFL was $76\ \mu\text{m}$ in both eyes, while GC was $76\ \mu\text{m}$ in RE and $66\ \mu\text{m}$ in LE. Cup-to-disc ratio (C/D) was 0.83 in both eyes. The corneal pachymetry resulted in $512\ \mu\text{m}$ and $516\ \mu\text{m}$ for RE and LE, respectively.

We requested orbital and encephalic magnetic resonance imaging (MRI). Topical therapy with brimatoprost drops 0.1 mg/mL once per day was started.

At the 1-month follow-up, the IOP was 11 mm Hg in RE and 9 mm Hg in LE. However, due to conjunctival redness and discomfort reported by the patient, we modified topical therapy prescribing brimonidine + brinzolamide drops twice per day and we started oral supplementation with ultrapure citicoline 500 mg, homotaurine 50 mg and vitamin E (Neuprozin tablets, FB Vision, 63100 Ascoli Piceno, Italy) once per day for 3 months followed by a break of 1 month. She was asked to continue therapy until further notice.

MRI, performed within 2 weeks, showed no significant alterations.

At the 3-month follow-up, HVF improved (MD RE from -11.70 to -7.87 , LE from -5.45 to -3.47), false negative errors were 8% in RE and 10% in LE. RNFL and GC were stable. The IOP was 11 mm Hg in RE and 10 mm Hg in LE. We requested a 24-h Holter pressure monitoring.

The 24-h Holter pressure monitoring showed a day mean systolic pressure of 114 mm Hg and a diastolic pressure of 73 mm Hg; in the night, the mean systolic pressure was 107 mm Hg and the mean diastolic pressure was 56 mm Hg. The patient was diagnosed with a mild lower blood pressure.

At the 8-month follow-up, the IOP was 11 mm Hg bilaterally. Topical drops and oral therapy were continued. At the 10-month follow-up, the IOP was 10 mm Hg.

At the 12-month follow-up, HVF was improved (MD RE -6.71 , LE -1.20 ; false negative errors were 7% in RE and 0% in LE) and RNFL and GC at OCT were stable. The IOP was 11 mm Hg bilaterally. She continued with the prescribed therapy.

The patient did not attend regular checks for 1 year for personal reasons.

She came back to our clinic for control after 24 months. She reported to have continued the same therapy (oral and topical). The IOP was 11 mm Hg bilaterally. HVF improved, particularly on the right side (MD RE -1.92 , LE -2.15). False negative errors were 6% in RE and 1% in LE, RNFL and GC remained stable. The C/D ratio was 0.84 bilaterally.

At the 30-month follow-up visit, the IOP was 11 mm Hg in RE and 10 mm Hg in LE. HVF presented further improvements (MD RE -0.92 , LE -0.70). False negative errors were 1% in RE and 0% in LE; RNFL and GC remained stable.

The follow-up data are shown in Figures 4 and 5.

Discussion / Conclusion

In this case report, we speculate about the utility of using nutritional supplements based on ultrapure citicoline associated with homotaurine and vitamin E in the management of NTG.

Neuroenhancement of neural conduction is a relatively new field in glaucoma management. Synergistic multitarget approach with a combination of neuroprotective compounds may be a promising strategy to slow down the progression of glaucoma. NTG remains a therapeutic challenge for the ophthalmologist since there are no effective therapies as the main therapeutic target, the IOP increase, is missed.

A recent study demonstrated that the combination of citicoline and homotaurine has a synergistic neuroprotective effect on experimental neuroretinal degeneration reducing apoptosis of primary retinal cells thus being a potential new strategy for the prevention and treatment of neurodegenerative diseases [10].

Moreover, the combination with vitamin E, which is an antioxidant molecule, can improve the neuroenhancement promoting cellular protection [14].

In our report, we describe an improvement in the visual field defect in a young female affected by NTG treated with ultrapure citicoline, homotaurine and vitamin E supplementation in a 30-month follow-up. We did not have any change of the OCT parameters during the follow-up and this could be considered a positive effect for the stabilization of RNFL and GC during the treatment.

This report has some limitations to be considered. Firstly, HVF is a subjective psychophysical test that could be influenced by many factors (such as a patient who is tired or worried, minor differences in room illumination, etc.). An electrophysiological examination could be more reliable giving more objective data. We also cannot exclude a learning effect in HVF performance in a young patient especially for the first exam in the RE at baseline. Finally, the concomitant use of brimonidine topical drops could have added a neuroprotective effect that could have caused a synergistic effect.

In conclusion, our finding suggests that the use of ultrapure citicoline together with homotaurine and vitamin E through a synergistic neuroprotective effect could be a promising approach in the management of NTG. Controlled clinical trials will be needed in the future to confirm these data.

Statement of Ethics

The research was conducted ethically in accordance with the World Medical Association Declaration of Helsinki. The patient has given a written informed consent to publish the case (including publication of images).

Disclosure Statement

The authors have no conflicts of interest to declare.

Funding Sources

No funds were received.

Author Contributions

T.V. contributed to the manuscript conception, design and data collection. A.C. contributed to acquisition of the data. T.V. and N.P. contributed to data interpretation, writing/drafting of the article. F.C., R.M. and G.M.C. contributed to critical review of the article. All authors approve the final version of the manuscript to be published.

References

- Lee BL, Bathija R, Weinreb RN. The definition of normal-tension glaucoma. *J Glaucoma*. 1998 Dec;7(6):366–71.
- Trivli A, Koliarakis I, Terzidou C, Goulielmos GN, Siganos CS, Spandidos DA, et al. Normal-tension glaucoma: pathogenesis and genetics. *Exp Ther Med*. 2019 Jan;17(1):563–74.
- The effectiveness of intraocular pressure reduction in the treatment of normal-tension glaucoma. Collaborative Normal-Tension Glaucoma Study Group. *Am J Ophthalmol*. 1998 Oct;126(4):498–505.
- Krupin T, Liebmann JM, Greenfield DS, Rosenberg LF, Ritch R, Yang JW; Low-Pressure Glaucoma Study Group. The Low-pressure Glaucoma Treatment Study (LoGTS) study design and baseline characteristics of enrolled patients. *Ophthalmology*. 2005 Mar;112(3):376–85.
- Sena DF, Lindsley K. Neuroprotection for treatment of glaucoma in adults. *Cochrane Database Syst Rev*. 2017 Jan;1:CD006539.
- Song BJ, Caprioli J. New directions in the treatment of normal tension glaucoma. *Indian J Ophthalmol*. 2014 May;62(5):529–37.
- Iulia C, Ruxandra T, Costin LB, Liliana-Mary V. Citicoline - a neuroprotector with proven effects on glaucomatous disease. *Rom J Ophthalmol*. 2017 Jul-Sep;61(3):152–8.
- Symes RJ, Mikelberg FS. Normal tension glaucoma management: a survey of contemporary practice. *Can J Ophthalmol*. 2017 Aug;52(4):361–5.
- Fioravanti M, Buckley AE. Citicoline (Cognizin) in the treatment of cognitive impairment. *Clin Interv Aging*. 2006;1(3):247–51.
- Roberti G, Tanga L, Michelessi M, Quaranta L, Parisi V, Manni G, et al. Cytidine 5'-Diphosphocholine (Citicoline) in Glaucoma: rationale of its use, current evidence and future perspectives. *Int J Mol Sci*. 2015 Nov;16(12):28401–17.
- McGlade E, Locatelli A, Hardy J, Kamiya T, Morita M, Morishita K, et al. Improved Attentional Performance following citicoline administration in healthy adult women. *Food Nutr Sci*. 2012;3(6):769–73.
- McGlade E, Agoston AM, DiMuzio J, Kizaki M, Nakazaki E, Kamiya T, et al. The effect of citicoline supplementation on motor speed and attention in adolescent males. *J Atten Disord*. 2019 Jan;23(2):121–34.
- Davinelli S, Chiosi F, Di Marco R, Costagliola C, Scapagnini G. Cytoprotective effects of citicoline and homotaurine against glutamate and high glucose neurotoxicity in primary cultured retinal cells. *Oxid Med Cell Longev*. 2017;2017:2825703.
- Pascoe GA, Fariss MW, Olafsdottir K, Reed DJ. A role of vitamin E in protection against cell injury. Maintenance of intracellular glutathione precursors and biosynthesis. *Eur J Biochem*. 1987 Jul;166(1):241–7.

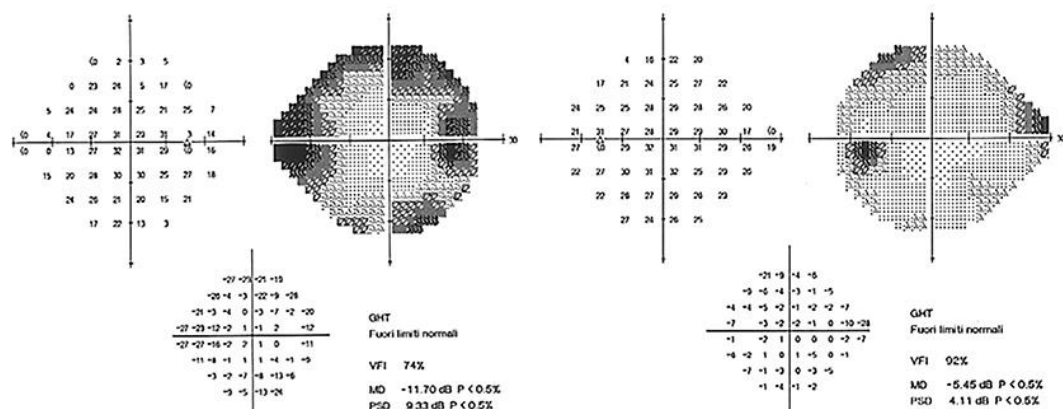


Fig. 1. Visual field 24-2 (RE on the left and LE on the right) at baseline.

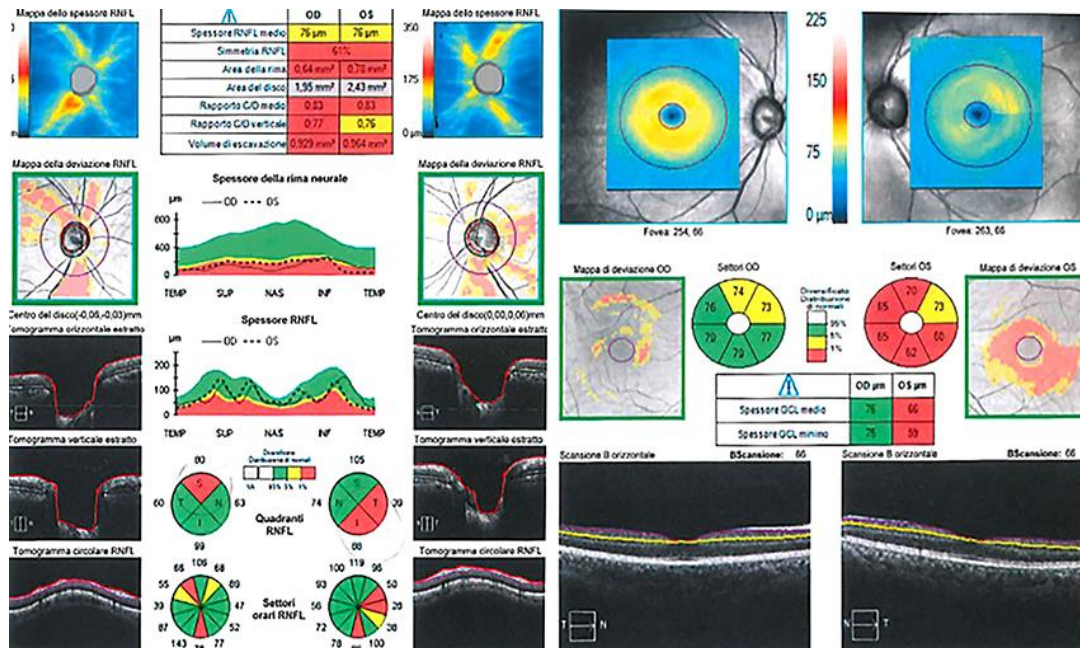


Fig. 2. OCT analysis (RNFL on the left, ganglion cells on the right) at baseline in both eyes.

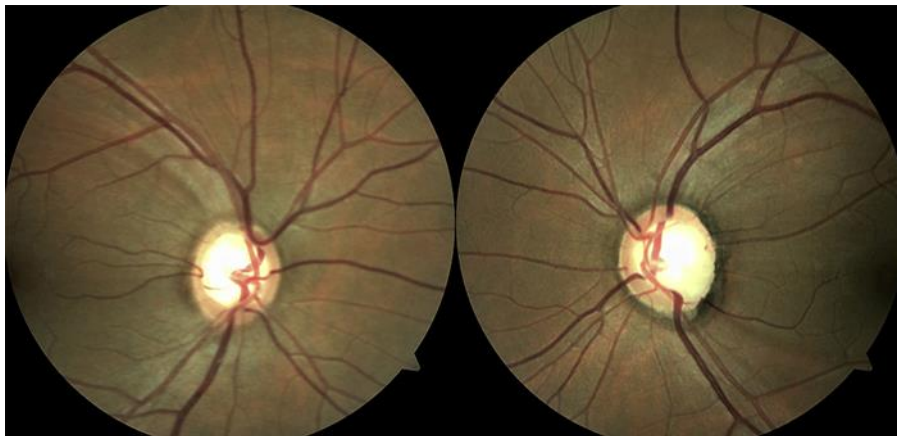


Fig. 3. Optic disc retinography at baseline.

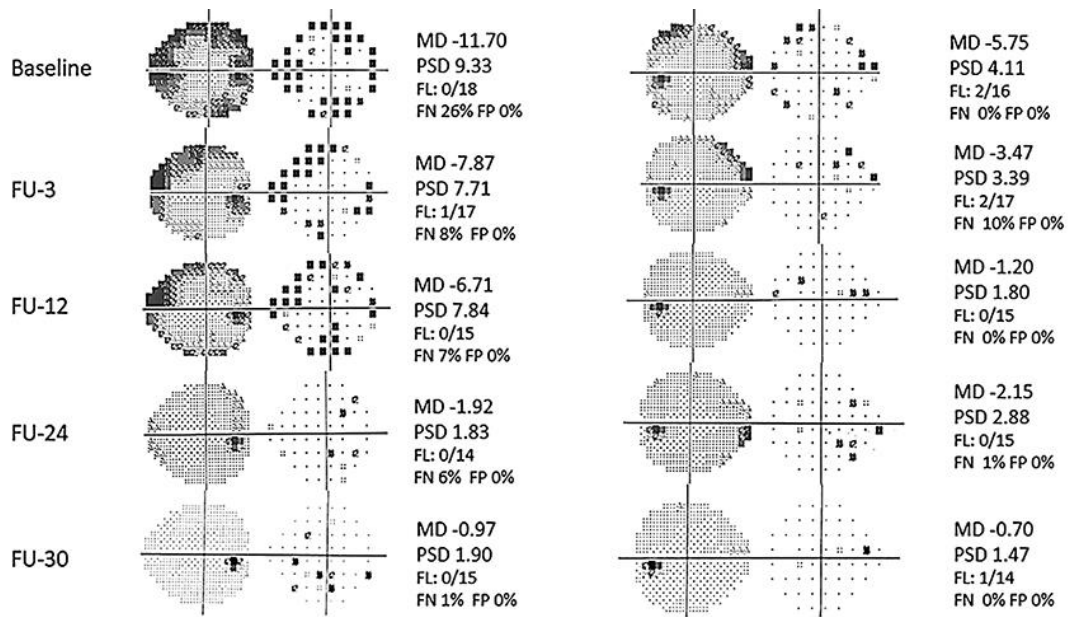


Fig. 4. Progression of the VF during the follow-up for both eyes. MD, mean deviation; PSD, pattern standard deviation; FL, fixation loss; FN, false negative; FP, false positive; FU-X, X-months follow-up.

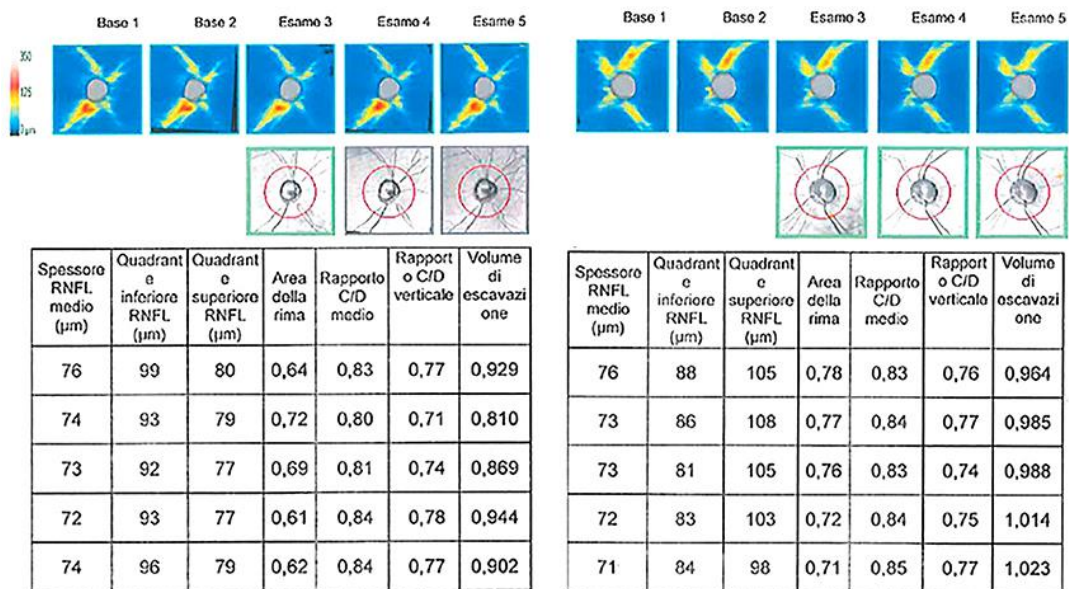


Fig. 5. Guided progression analysis (GPA) during the 2-year follow-up for both eyes. RNFL and C/D ratio remained stable.