



## Case Report

## An unusual case of non-typhi pleuropulmonary salmonellosis

Abigayle Sullivan<sup>a, \*</sup>, Shilla Zachariah<sup>b</sup>, Pallak Agarwal<sup>a</sup>, David Young<sup>a</sup><sup>a</sup> Department of Pulmonary and Critical Care, Reading Hospital, Tower Health System, PA, United States<sup>b</sup> Department of Cardiology, Reading Hospital, Tower Health System, PA, United States

## ARTICLE INFO

## Keywords:

Non-typhi salmonella  
Salmonella group D  
Loculated pleural effusion  
Empyema  
Tumor necrosis factor inhibitor

## ABSTRACT

A middle-aged man with rheumatoid arthritis, without pulmonary involvement, on disease-modifying antirheumatic drugs (DMARD) presented with right sided pleuritic chest pain due to recurrent, right sided, loculated pleural effusion. *Non-typhi Salmonella* was isolated from pleural fluid sampling and the patient was successfully treated with open thoracotomy with decortication and six weeks of antibiotic therapy. Pulmonary salmonellosis is a rare infection typically found in immunocompromised patients that typically presents abruptly and requires prolonged antibiotic therapy.

## 1. Background

*Salmonella* is a gram-negative non-spore forming anaerobic motile bacilli belonging to the Enterobacteriaceae family. The clinical presentation of a *Salmonella* infection depends on the serotype and infection ranges from sepsis to gastroenteritis. Non-typhi *salmonella* organisms often produce a localized reaction and most commonly cause intestinal infections [1,2]. Pleuropulmonary infections are rare and present abruptly with symptoms mimicking pneumonia; incidence is highest in immunosuppressed patients [2–4].

## 2. Case details

57-year-old man with pertinent past medical history of rheumatoid arthritis, without pulmonary involvement, on DMARD and primary hypertension presented with abrupt onset of dyspnea and right sided pleuritic chest pain. Home medications included adalimumab, methotrexate, amlodipine, and folic acid supplementation.

The patient was hospitalized 14 months prior with pleuritic chest pain and a new right pleural effusion. Pleural fluid studies were consistent with an exudative effusion and its development was attributed to rheumatoid arthritis. Infectious workup, including pleural fluid cultures were negative. Unfortunately, two months later computed tomography (CT) chest demonstrated interval development of partially loculated right pleural effusion. At that time, cardiothoracic surgery recommended routine surveillance without surgical intervention and outpatient follow up, as the patient was asymptomatic.

On admission, the patient was afebrile, tachypneic, and tachycardic. Physical exam notable for inspiratory and expiratory crackles and diminished breath sounds right middle and lower lung zones. A leukocytosis of 15.8 10E3/μL was notable on laboratory results.

CT chest demonstrated similar sized loculated right pleural effusion, similar in appearance to prior CT chest (Fig. 1). An ultrasound guided thoracentesis performed on day of admission removed 650 cc bloody fluid. Pleural fluid analysis revealed a glucose <10 [ref. <60 mg/dL], pH 6.83 [ref.7.60–7.66 pH], lactate dehydrogenase 1175 IU/L. Gram stain was positive for gram negative rods. The patient was diagnosed with right sided empyema and a 14 French chest tube was inserted. Intrapleural thrombolytic therapy with tissue plasminogen activator and deoxyribonuclease was initiated on hospital day 2 and the patient was empirically started

\* Corresponding author.

E-mail address: [Abigayle.Sullivan@towerhealth.org](mailto:Abigayle.Sullivan@towerhealth.org) (A. Sullivan).

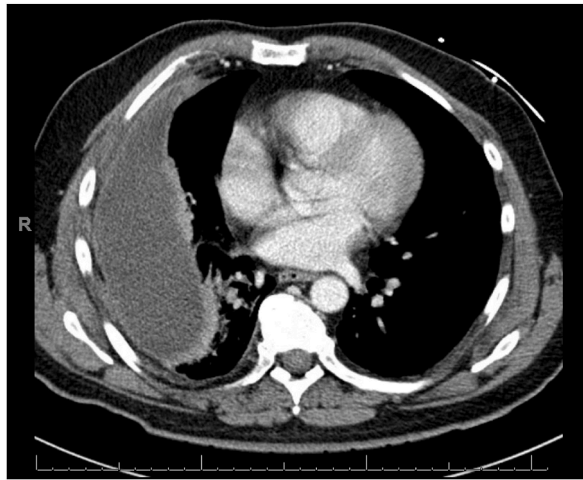


Fig. 1. CT chest on admission illustrating chronic loculated right pleural effusion of similar size to previous imaging.

on cefepime and metronidazole. On hospital day 6, the patient underwent right thoracotomy and decortication for longstanding pleural effusion and trapped lung. Notable operative findings included extensive adhesions and trapped right middle and right lower lobes. Infectious workup was negative, including blood cultures and right lung tissue culture, which was negative for acid fast bacilli.

Pleural effusion fluid culture speciated to *Salmonella group D* and antibiotics were narrowed to ceftriaxone and later ciprofloxacin. The patient was successfully treated with a 51-day antibiotic course. Recovery was complicated by recurrent right sided loculated hydropneumothorax and extensive subcutaneous emphysema and pneumomediastinum with concern for pleural cutaneous fistula along tract of prior chest tube (Figs. 2–3). Repeat right pleural effusion culture was negative for bacterial growth. The patient underwent prolonged course of chest tube placement and had a small, persistent hydropneumothorax without further complication.

### 3. Discussion

Pleuropulmonary non-typhi *Salmonella* infections are very rare, with less than 50 cases reported during the last 100 years. Non-typhi *Salmonella* infections usually present as a localized reaction involving the gastrointestinal system [1,2]. Additional extra-gastrointestinal infections include urinary tract infections, bacteremia, osteomyelitis, endocarditis, meningitis, and septic arthritis. Notably, 38% of pleuropulmonary infections, as was the case with our patient, have been reported in the setting of established lung disease, as *Salmonella* preferentially adheres to damaged tissue [5–7].

Transmission of non-typhi *Salmonella* is most often attributed to oral consumption of contaminated food products. However, seeding from nearby infections of the reticuloendothelial system, such as the spleen, via transdiaphragmatic or hematogenous spread, has also been reported [4,5]. Dormant *Salmonella*, both typhi and non-typhi, within the reticuloendothelial system may re-activate and cause infection of pleural space [2,4,5]. Therefore, one notable mechanism for *Salmonella* induced lung injury involves the activation of the intrinsic pathway of coagulation by fimbriated *Salmonella*, by which there is adherence or infiltration of red blood cells and fibrin deposition in lung tissue [6,8]. *Salmonella* clearance is dependent upon macrophage phagocytosis, and in particular tumor necrosis factor inhibitors prevent activation and proliferation of macrophages. Consequently, this diminished activation of an inflamma-

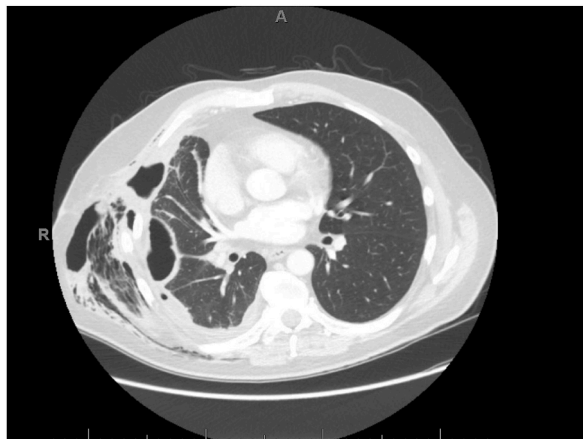


Fig. 2. Post-operative CT chest demonstrating large right empyema with pleurocutaneous fistula along prior chest tube tract with extensive subcutaneous emphysema.

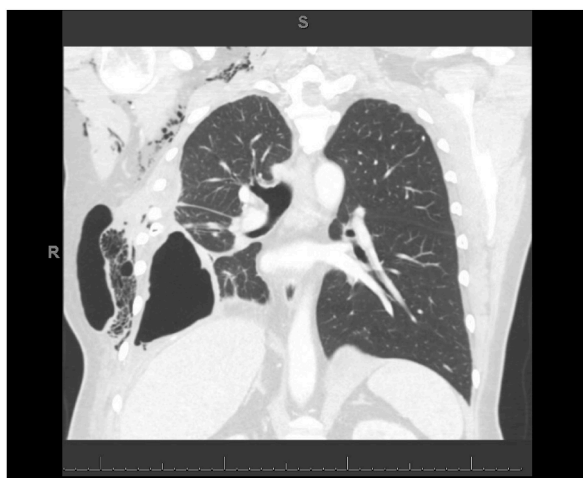

Fig. 3. Post-operative CT chest illustrating large right empyema with pleurocutaneous fistula resulting in large second collection in right chest wall and extensive subcutaneous emphysema.

tory response leads to increased risk of disseminated Salmonellosis [6,9]. The identification of this patient's DMARD therapy including tumor necrosis factor, adalimumab, as a key contributing factor for his pleuropulmonary salmonellosis was crucial.

One distinguishing feature of pleuropulmonary salmonellosis, in comparison to other extra-intestinal infections, is timing of symptom onset. Pulmonary infections commonly present abruptly, with nonspecific respiratory symptoms occurring for less than 1 week before diagnosis [10]. Frequent reported symptoms include dry cough, dyspnea, and associated pleuritic chest pain. A high clinical index of suspicion is crucial, as about half of reported cases do not have an associated leukocytosis [2,3].

Due to *Salmonella* organisms' propensity for prolonged infection a 4 to 12-week course of antibiotics should be anticipated and should include a third-generation cephalosporin or fluoroquinolone. Antibiotic course duration varies depending on clinical response and presence of antibiotic resistance. In patients with relapsing infections, drainage of empyema is likely necessary with thoracotomy and possibly decortication. Surgical evaluation and intervention should be timely in the setting of unresolving pulmonary infections, especially when immunocompromised. One uncommon complication following a thoracotomy is a pleurocutaneous fistula, which has been reported in a few case reports [11].

In the setting of an immunocompromised patient, especially one receiving DMARD therapy including tumor necrosis factor inhibitors, with exudative pleural effusions or empyema, non-typhi *Salmonella* should be considered as a causative agent and investigated as early as possible [2,4,6].

#### 4. Conclusion

Pleuropulmonary salmonellosis due to non-typhi *Salmonella* is an unusual infection that has been infrequently reported over the last century. This diagnosis should be considered in immunocompromised patients with symptoms of pneumonia or empyema, especially in the setting of pre-existing pulmonary disease and tumor necrosis factor inhibitor DMARD therapy. Timely diagnosis and treatment are crucial, as there is significant morbidity and mortality associated.

#### Declaration of competing interest

There are **NO financial Disclosures NOR any Conflict of Interest**. There is no preferred/potential reviewers for this manuscript.

#### References

- [1] S. Abuhasna, A. Al Jundi, M. Rahman, W. Said, Non-typhoidal *Salmonella* group D bacteremia and urosepsis in a patient diagnosed with HIV Infection, *J. Global Infect. Dis.* 4 (4) (2012) 218.
- [2] N. Crum, Non-typhi *Salmonella* empyema: case report and review of the literature, *Scand. J. Infect. Dis.* 37 (11–12) (2005) 852–857.
- [3] J. Aguado, Pleuropulmonary infections due to nontyphoid strains of *Salmonella*, *Arch. Intern. Med.* 150 (1) (1990) 54–56.
- [4] J. Kam, V. Doraiswamy, S. Jawad, Y. Abdeen, C. Modi, R. Spira, et al., A rare case of a pleural empyema due to *Salmonella* group D infection, *Chest* 142 (4) (2012) 245A.
- [5] Shivanshan Pathmanathan, et al., *Salmonella* empyema: a case report, *Pneumonia* 6 (1) (2015) 120–124.
- [6] N. Saeed, *Salmonella* pneumonia complicated with encysted empyema in an immunocompromised youth: case report and literature Review, *J. Infect. Dev. Ctries.* 10 (x) (2016) 437–444 04.
- [7] S.T. Bobra, Chronic empyema due to *Salmonella* oranienburg: complication of an old chest wound, *Can. Med. Assoc. J.* 78 (8) (1958) 599.
- [8] Kristin Persson, et al., Severe lung lesions caused by *Salmonella* are prevented by inhibition of the contact system, *J. Exp. Med.* 192 (10) (2000) 1415–1424.
- [9] Joshua Dower, et al., The risk of immunosuppression: a case of salmonella meningitis, *Case Rep. Infect. Dis.* 2018 (2018), <https://doi.org/10.1155/2018/4874575>.
- [10] Jeffery I. Cohen, John A. Bartlett, G. Ralph Corey, Extra-intestinal manifestations of salmonella infections, *Medicine* 66 (5) (1987) 349–388.
- [11] Emeka B. Kesieme, et al., Tube thoracostomy: complications and its management, *Pulm. Med.* 2012 (2012), <https://doi.org/10.1155/2012/256878>.