

# Catheter ablation of ventricular tachycardia in the setting of electrical storm after revascularization of a chronic total occlusion of the right coronary artery: An uncommon presentation of reperfusion arrhythmia



Sebastian Koenig, MD, Arash Arya, MD, FHRS, Gerhard Hindricks, MD, FHRS, Borislav Dinov, MD

From the Department of Cardiac Electrophysiology, Heart Center, University of Leipzig, Leipzig, Germany.

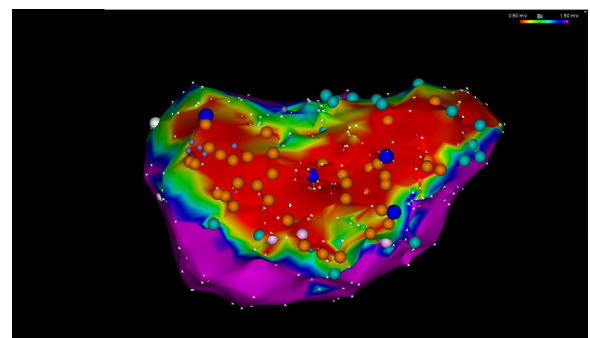
## Introduction

Reperfusion arrhythmias are common findings in patients with acute ST elevation myocardial infarction after reestablishment of the coronary artery flow. Accelerated idioventricular rhythm or complex ventricular ectopy are the most typical presentation. Patients with chronic total occlusion (CTO) are known to be at high risk for ventricular arrhythmias and sudden cardiac death. During a complete literature review, we found no data of reperfusion arrhythmias associated with the opening of a CTO. The purpose of this report is to present a case of recurrent monomorphic ventricular tachycardia (VT) after reperfusion of CTO successfully treated with catheter ablation.

## Case report

A 78-year-old male patient with stable angina and a history of an old inferior myocardial infarction with depressed left ventricular function was scheduled for elective revascularization of a CTO of the right coronary artery. CTO had been angiographically described more than 1 year prior. An implantable cardioverter-defibrillator (ICD) had been implanted in 1999 owing to syncope and VT within electrophysiological study. During the regular ICD interrogations only 2 VT episodes had been documented within the prior 7 years. The CTO opening was performed anterogradely, with an excellent angiographic outcome TIMI 3 flow. Ten hours after revascularization the patient experienced 5 ICD shocks due to recurrent monomorphic VT with a cycle length from 310 to 340 ms. All VTs were triggered by premature ventricular contractions. Immediately performed cardiac

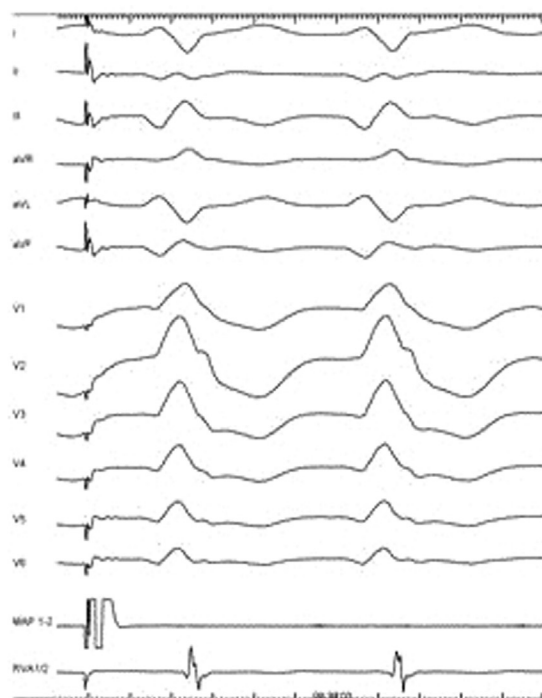
catheterization revealed patent right coronary artery. All electrolyte levels were within the normal ranges; the patient was initially in euthyroid metabolic state. Stabilization of rhythm and hemodynamics was achieved through intravenous administration of amiodarone, which had to be subsequently discontinued owing to clinically overt hyperthyroidism that required a thyrostatic therapy. After recurrence of symptomatic nonsustained VTs, the patient was referred for catheter ablation. Initially performed left ventricular voltage mapping showed a large scar area (total scar 87 cm<sup>2</sup>, dense scar 25 cm<sup>2</sup>) at the inferior left ventricular wall (Figure 1). Four distinct monomorphic VTs were induced using programmed ventricular stimulation (Figure 2). Two hemodynamically stable VTs were mapped using entrainment mapping; in the other 2 VTs the reentry circuits were defined using pace mapping and ablation lines transecting the scar area were performed as shown (Figure 3). The ablation rendered all VTs noninducible. A predischarge ICD interrogation 12 days after ablation did not document new



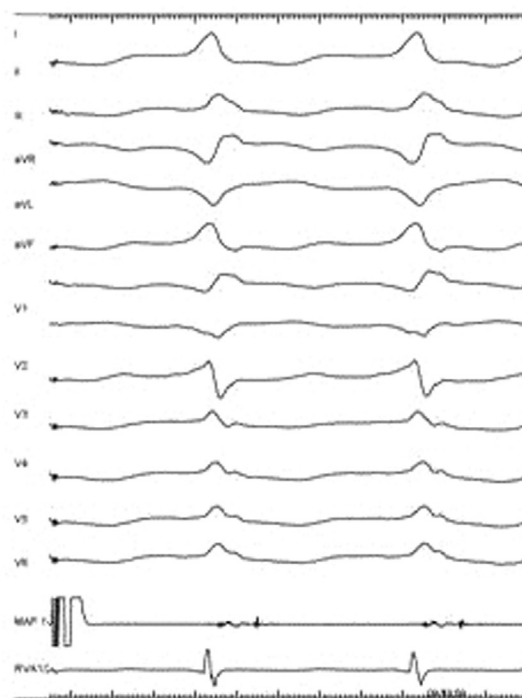
**Figure 1** Endocardial voltage mapping of the left ventricle (LV). A transseptal puncture and a steerable sheath were used to access the LV cavity. There is an inferior wall low-voltage area (< 1.5 mV) with a total size of 86 cm<sup>2</sup> (36% of the LV surface). The dense scar (< 0.5 mV) highlighted in red is surrounded by a broad penumbra zone (0.5–1.5 mV) with most of the late potentials (orange dots) localized at the border between both zones. Double potentials within electrophysiological study are represented by the light blue dots.

**KEYWORDS** Ventricular arrhythmia; Ventricular tachycardia; Ablation; Chronic ischemic heart disease; Chronic total occlusion of a coronary artery; Catheter-based coronary interventions  
(Heart Rhythm Case Reports 2016;2:462–464)

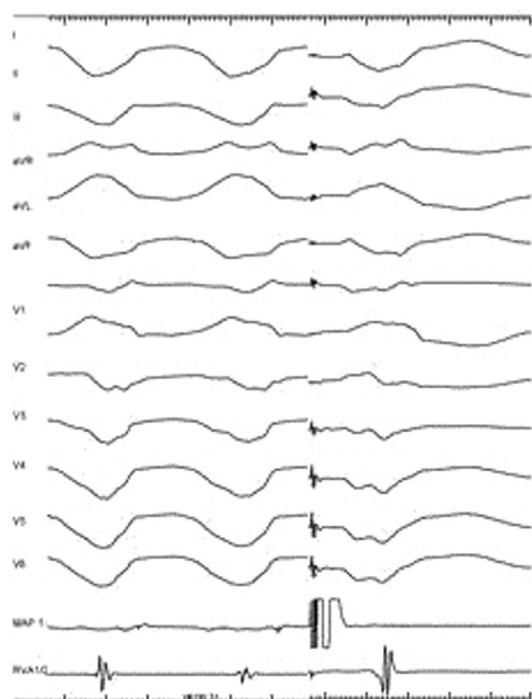
**Address reprint requests and correspondence:** Dr Sebastian Koenig, University of Leipzig – Heart Center, Department of Electrophysiology, Struempellstrasse 39, 04289 Leipzig, Germany. E-mail address: sebastiankoenig1989@gmail.com.



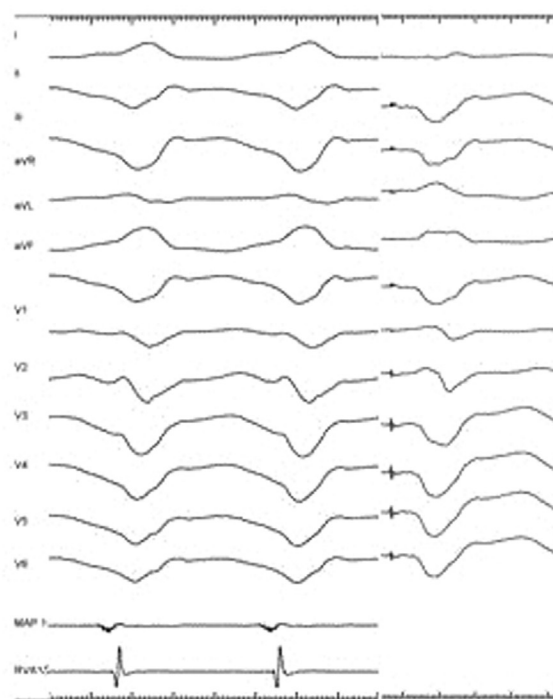
VT 1, CL 480 ms  
Entrainment-mapping (first beat)



VT 2, CL 490 ms  
Entrainment-mapping (first beat)



VT 3, CL 335 ms, clinical VT  
Pace-mapping (last beat)



VT 4, CL 390 ms  
Pace-mapping (last beat)

**Figure 2** Twelve-lead electrocardiograms of the 4 monomorphic ventricular tachycardias (VTs) being induced during electrophysiological study. VT1 (cycle length [CL] 480 ms) and VT2 (CL 490 ms) were hemodynamically stable and therefore able to be mapped using concealed entrainment. VT3 (clinical VT, CL 335 ms) and VT4 (CL 390 ms) were mapped using pace mapping owing to hemodynamic impairment.

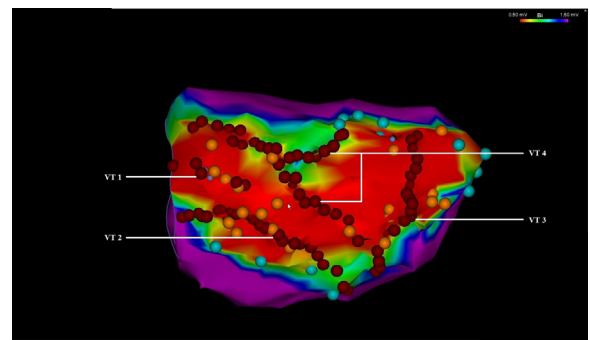
## KEY TEACHING POINTS

- Ventricular tachycardia should be recognized as a possible complication after coronary artery intervention of an infarct-related chronic total occlusion and a closer monitoring of these patients afterward can be advocated.
- After restoration of the blood flow in the areas of hibernated myocardium, alternative mechanisms of arrhythmogenesis can be assumed.
- Catheter ablation was confirmed as a safe and effective treatment option in a patient with ventricular tachycardia after revascularization of a chronic total occlusion of a coronary artery.

VTs and the patient left the hospital without any antiarrhythmic drug therapy.

## Discussion

The number of percutaneous coronary artery interventions (PCIs) of CTOs is increasing steadily because of better techniques and clinical evidence for improved long-term survival and reduced adequate shocks in case of an existing ICD after successful treatment.<sup>1</sup> Meta-analyses of patients undergoing CTO-PCI reported 3%–4% major adverse cardiac events.<sup>2</sup> However, no periprocedural VTs after revascularization of CTO have been previously described. Respectively, there are no recommendations regarding the therapy of such VTs. The occurrence of “VT storm” shortly after PCI in an electrically stable patient in the absence of other acute causes implies that reperfusion injury may play a role in the pathogenesis of VTs in CTO. Therefore, “watch and wait” or early intervention can both be appropriate strategies, depending on the clinical presentation. Different mechanisms of reperfusion arrhythmias have been studied in cases of acute myocardial infarction. Those arrhythmias, mostly caused by abnormal cellular automaticity, are generally slow and occur within minutes to 5–6 hours after reestablishment of coronary blood flow.<sup>3</sup> In the present case both the later presentation and the fast monomorphic nature of the VTs were untypical features, suggesting different mechanisms of arrhythmogenesis. An enhanced vulnerability of hibernating myocardium has been reported and may play a role in VT initiation. Moreover, a larger penumbra zone (0.5–1.5 mV) in electroanatomical voltage maps of patients with CTO and VTs was observed, indicating a



**Figure 3** Endocardial voltage mapping of the left ventricle with ablation lines illustrated as red dots. Ventricular tachycardias (VTs) VT1 and VT2 were ablated successfully via short lines from the VT’s “critical isthmus” to the mitral annulus. Ablation lines transecting the scar area including the reentry circuits of VT3 and VT4 lead to noninducibility of all VTs.

widespread myocardial heterogeneity in those patients.<sup>4</sup> We assume that restoration of the coronary flow in a CTO could change the electrophysiological properties of the chronically hibernated myocardium in such a way that previously mechanically and electrically “silent” areas may exhibit sudden recovery of electrical activity. Possibly, typical reperfusion ventricular arrhythmias can also trigger monomorphic VT in the setting of a preexisting chronic scar.

## Conclusion

Recurrent rapid monomorphic VTs can occur as a complication after opening of a CTO of a coronary artery. The complex interplay between acute blood flow restoration and preexisting inhomogeneous scar may be relevant in the pathogenesis of VTs. Radiofrequency catheter ablation can be a safe and effective treatment strategy for achievement of electrical and clinical stability.

## References

1. Nombela-Franco L, Mitroi CD, Fernandez-Lozano I, et al. Ventricular arrhythmias among implantable cardioverter-defibrillator recipients for primary prevention: impact of chronic total coronary occlusion (VACTO Primary Study). *Circ Arrhythm Electrophysiol* 2012;5:147–154.
2. Patel VG, Brayton KM, Tamayo A, et al. Angiographic success and procedural complications in patients undergoing percutaneous coronary chronic total occlusion interventions: a weighted meta-analysis of 18,061 patients from 65 studies. *JACC Cardiovasc Interv* 2013;6:128–136.
3. Majidi M, Kosinski AS, Al-Khatib SM, et al. Implications of ventricular arrhythmia “bursts” with normal epicardial flow, myocardial blush, and ST-segment recovery in anterior ST-elevation myocardial infarction reperfusion: a biosignature of direct myocellular injury “downstream of downstream.” *Eur Heart J Acute Cardiovasc Care* 2015;4:51–59.
4. Di Marco A, Paglino G, Oloriz T, et al. Impact of a chronic total occlusion in an infarct-related artery on the long-term outcome of ventricular tachycardia ablation. *J Cardiovasc Electrophysiol* 2015;26:532–539.