

Single Case

Secondary Adrenal Insufficiency in a Patient with Metastatic Melanoma Treated with Nivolumab

Wataru Omata^a Satoko Nakamura^a Chie Urasaki^a Hiromichi Morita^a
Hiroki Funaishi^a Kazuki Kobayashi^b Hisashi Koide^c Arata Tsutsumida^d
Hiroyuki Matsue^e

^aDepartment of Dermatology, Asahi General Hospital, Chiba, Japan; ^bDepartment of Diabetes and Metabolism, Asahi General Hospital, Chiba, Japan; ^cDepartment of Endocrinology, Hematology and Gerontology, Chiba University Graduate School of Medicine, Chiba, Japan; ^dDepartment of Dermatologic Oncology, Dermatology, Cancer Institute Hospital of JFCR, Tokyo, Japan; ^eDepartment of Dermatology, Chiba University Graduate School of Medicine, Chiba, Japan

Keywords

Advanced melanoma · Hypophysitis · Isolated adrenocorticotrophic hormone deficiency · Nivolumab · Corticotropin-releasing hormone loading test

Abstract

We report a case of secondary adrenal insufficiency due to nivolumab. An 83-year-old man with acral lentiginous types of melanoma on the right sole visited our department in March 2017. He received primary surgery at referred hospital in June 2017, and pathological stage was IIIc (pT3bN3M0) according to AJCC (American Joint Committee on Cancer) 7th edition criteria. During the follow-up period, a lot of in-transit metastases appeared on the right leg. While we were resecting in-transit metastases, we concurrently started nivolumab in September 2018. After 17 cycles of nivolumab treatment, he developed severe nausea and anorexia. At baseline, his cortisol and adrenocorticotrophic hormone levels were both at normal range, but corticotropin-releasing hormone loading test revealed secondary adrenal insufficiency. We diagnosed isolated adrenal insufficiency due to nivolumab. Treatment by hydrocortisone immediately relieved nausea and anorexia, and we could have continued treatment of nivolumab.

© 2022 The Author(s).

Published by S. Karger AG, Basel

Introduction

Nivolumab is a fully humanized IgG4 programmed death 1 (PD-1) immune checkpoint inhibitor antibody with a good safety profile, higher response rate, and durable efficacy for malignant melanoma [1]. Objective response rate was 35% and the 3-year survival rate was 43.5% in previously untreated Japanese patients with stage IV or recurrent malignant melanoma [2]. Among immune-related adverse events due to immune checkpoint blockades, endocrine side reactions were reported in cases of 7–24% [3–5].

Of endocrine-related complications, “hypophysitis” due to anti-PD-1 antibodies has been reported. “Hypophysitis” refers to the inflammation of the pituitary gland that can result in primary dysfunction of the gland, particularly the anterior pituitary, leading to deficiency in one or more hormones secreted by the anterior pituitary gland [6]. Secondary adrenal insufficiency is one of the clinical manifestations due to “hypophysitis” [6]. The incidence of “hypophysitis” with ipilimumab was reported to be 4–11% [4, 5], and that with nivolumab was 0.5–2% [3, 4], suggesting that there is a difference. Here, we will present a patient who was treated with nivolumab and suffered from secondary adrenal insufficiency as endocrine side effects.

Case Presentation

An 83-year-old man with acral lentiginous melanoma on the right sole visited our hospital in March 2017. The primary site was excised, and inguinal lymph node dissection was performed in June 2017 in the department of dermatology in another hospital. He was followed up at our hospital from November 2017. During the follow-up, one subcutaneous nodule (7 × 7 mm) on the right knee that appeared in July 2018 was resected. Pathologically, it was diagnosed as in-transit metastasis of malignant melanoma. Genetic analysis of dissected specimen revealed no BRAF V600 mutation.

We started nivolumab 3 mg/kg every 2 weeks from September 2018 as adjuvant therapy. In April 2019, after 17 cycles of nivolumab (33 weeks after the initiation of nivolumab), he suddenly developed severe anorexia, nausea, and vomiting. The patient visited the emergency department due to continued anorexia and nausea. He was admitted to our hospital in May 2019 (day X).

Since the abdominal ultrasound and upper gastrointestinal endoscopy were normal, we suspected a non-gastrointestinal disease. We suspected adrenal insufficiency due to nivolumab and consulted an endocrinologist. The levels of cortisol (9.16 µg/dL; normal range, 6.24–18 µg/dL) and adrenocorticotropic hormone (ACTH) (15.7 pg/mL; normal range, 7.2–63.3 pg/mL) were within normal ranges (Table 1). As we did not get a definitive diagnosis, corticotrophin-releasing hormone loading test was performed (day X+6) (Fig. 1).

Cortisol levels before loading test were below the normal range and loading response was impaired (Fig. 1). Though ACTH responded, both ACTH levels before loading test and peak levels of ACTH were low (Fig. 1). Therefore, we thought that the pituitary gland was impaired partially. We diagnosed partial isolated ACTH deficiency.

We took a brain MRI, and no enlargement of the pituitary gland was noted (day X+8) (Fig. 2). Hydrocortisone of 30 mg per day was started from day X+8. On the following day, nausea disappeared, and he was able to eat. We decreased to 20 mg from day X+19, and 15 mg from day X+26, and he was discharged. At this time, radiation therapy was performed for in-transit metastases on the front of the right side of the femoral region for 14 days from day X+12 to X+25.

Table 1. Laboratory findings on admission on May 2019

Complete blood count			Biochemistry			Endocrinological		
WBC	6,600	/ μ L	TP	7.5	g/dL	GH	3.85	ng/mL
RBC	480	$\times 10^4$ / μ L	ALB	4.2	g/dL	TSH	2.1	μ U/mL
Hb	15.1	g/dL	LDH	217	U/L	Free T3	2.45	pg/mL
Ht	44.5	%	CPK	152	U/L	Free T4	1.36	ng/dL
Plt	25.4	$\times 10^4$ / μ L	BUN	31	mg/dL	Cortisol	9.16	μ g/dL
			Cre	1.82	mg/dL	ACTH	15.7	pg/mL
Coagulation and fibrinolytic system			Na	138	mEq/L	Prolactin	9.4	ng/mL
PT	18.3	min	K	3.6	mmol/L	LH	3.57	mU/mL
APTT	42.3	min	Cl	97	mmol/L	FSH	6.56	mU/mL
D-dimer	0.7	μ g/mL	BS	122	mg/dL			
			HbA1c	5.8	%	Anti-AcR- antibody	<0.2	nmol/L
			CRP	1.29	mg/dL			

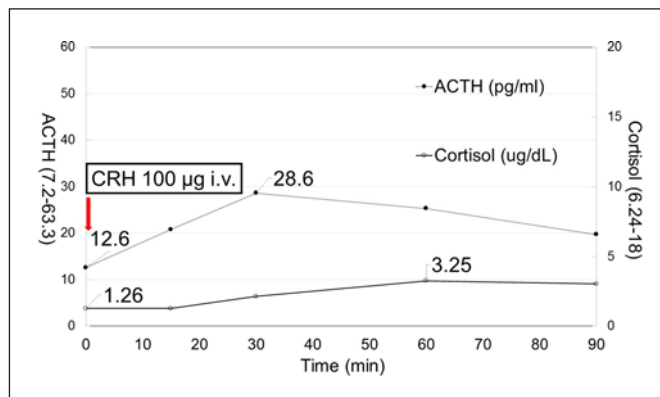


Fig. 1. Results of CRH loading test in May 2019. Six days after hospital admission, we performed CRH loading test. Cortisol levels before loading test were below the normal range (1.26 μ g/dL) and loading response was impaired. Though ACTH responded, both ACTH levels before loading test and peak levels of ACTH were low. Therefore, the pituitary gland might have been impaired partially. Normal range of cortisol: 6.24–18 μ g/dL. Normal range of ACTH: 7.2–63.3 pg/mL. Solid line: cortisol. Dotted line: ACTH. CRH, corticotropin-releasing hormone.

After discharge, in-transit metastases on the right lower leg developed and we resected them twice. Radiation therapy was performed for in-transit metastases on the back of the right side of the femoral region in July 2019. Nivolumab was resumed after 11 weeks from the absence of nivolumab administration. However, in August 2019, liver, pancreatic, and right peritoneal metastases were newly pointed out by CT scan. We decided to change from nivolumab monotherapy to combination therapy of nivolumab plus ipilimumab every 3 weeks from September to October 2019.

For diarrhoea due to nivolumab plus ipilimumab, the patient required hospitalization for approximately 1 month. Because of diarrhoea, we stopped nivolumab plus ipilimumab. Response to the combination treatment of nivolumab plus ipilimumab was poor and metastatic lesions had grown. The patient entered the hospital for palliative care and died in August 2020.

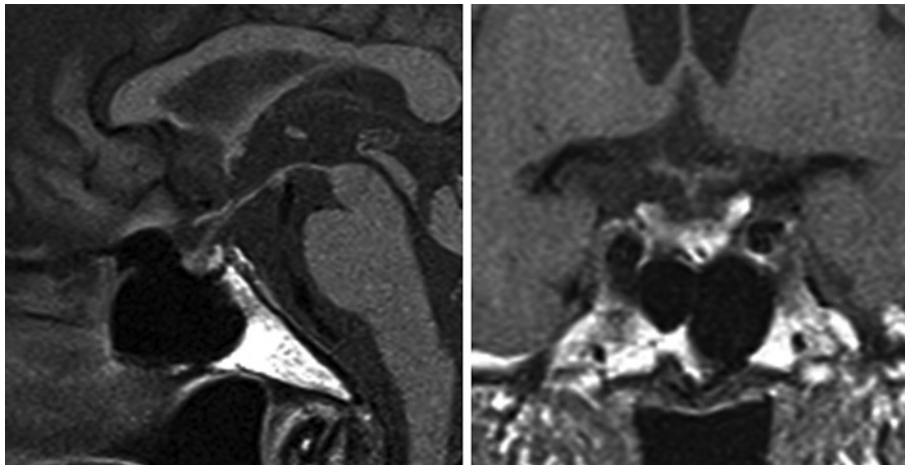


Fig. 2. Sagittal and coronal sections of T1-weighted MRI taken 8 days after hospital admission. The pituitary gland was not enlarged (height, 5.8 mm; length, 9.7 mm; width, 9.3 mm).

Discussion

In our country, nivolumab has been used for patients with unresectable malignant melanoma since September 2014 and patients with adjuvant therapy since August 2018. It is well known that nivolumab induces side effects different from conventional cytotoxic agents. Among immune-related adverse events, endocrine side reactions were reported in cases of 7–24% [3–5]. The incidence of “hypophysitis” with ipilimumab was reported to be 4–11% [4, 5], and that with nivolumab was 0.5–2% [3, 4], suggesting that there is a difference.

Nine studies including Japanese patients with secondary adrenal insufficiency due to nivolumab reported several features (Table 2) [7–14]. There were more male than female patients who suffered from this complication (7 vs. 2). The most common symptoms were fatigue and anorexia, seen in 5 of 9 cases. Adrenal insufficiency with hypothyroidism was seen in 3 of 9 cases [7, 12, 14].

Of interest was that there could be differences in the frequency of endocrinological side effects, especially secondary adrenal insufficiency due to anti-PD-1 antibody (nivolumab or pembrolizumab) and anti-CTLA-4 antibody (ipilimumab) [15].

Our main findings were as follows. First, it is difficult to diagnose secondary adrenal insufficiency due to immune checkpoint blockades because symptoms of “hypophysitis” are typically nonspecific [6]. In emergency department, the diagnosis was not established although anorexia and nausea had persisted before hospital admission.

Second, initial cortisol and ACTH levels were within the normal range when symptoms appeared. This had made our correct diagnosis delayed slightly and delayed start of treatment. With the help of endocrinologists, corticotropin-releasing hormone loading test after admission established secondary adrenal insufficiency in this case (Fig. 1).

Third, our patient developed adrenal insufficiency after 17 cycles of treatment from the initiation of nivolumab (33 weeks after the initiation of nivolumab). In a previous study, a difference on the timing of onset from administration was revealed to be longer in anti-PD-1 antibody group than in ipilimumab group (median time is 25.8 weeks vs. 9.3 weeks) [15]. In other reports, onset time from the start of treatment was reported between 3 and 15 months [7–14]. Adrenal insufficiency in our case developed late from the start of nivolumab.

Fourth, treatment with hydrocortisone improved immediately clinical symptoms. Since it is said that the adrenal functional impairment is irreversible, administration of hydrocortisone is needed for life.

Table 2. Summary of 9 malignant melanoma patients with secondary adrenal insufficiency due to nivolumab from our country

Sex		Symptoms	
Male	7	Fatigue	5
Female	2	Anorexia	5
		Malaise	3
Age		Vomiting	2
Range, years	39–85	Myalgia	2
Median	68	Nausea	1
Mean	63	Dizziness	1
Primary site		Onset time from start of treatment	
Cutaneous	3	Range, months	3–15
Mucosal	2		
Acral	1	Other endocrine irAEs	
Ocular	1	Hypothyroidism	3
Unknown primary	1		
ND	1		
Pituitary gland			
Enlargement	1		
Not enlargement	5		
ND	3		

ND, not described; irAEs, immune-related adverse events.

Fifth, the pituitary gland was not enlarged on MRI at the time of diagnosis (Fig. 2). Faje et al. [15] reported that among 22 patients with “hypophysitis” who received anti-PD-1 antibodies, 13 of 18 patients who had MRI did not show enlarged pituitary gland, while among 64 patients who received ipilimumab, 60 of 61 patients who had MRI showed enlarged pituitary gland. Our case reflects entity of previous reports.

In conclusion, since adrenal insufficiency develops suddenly, and characteristics of clinical symptoms are nonspecific, we should alert to monitor symptoms and signs. If needed, immediate consultation to subspecialties is crucial.

Acknowledgments

We would like to thank the patient’s family members, nurses, and staff members of the department of dermatology in Asahi General Hospital.

Statement of Ethics

Study approval statement was not required for this study in accordance with local/national guidelines. Written informed consent was obtained from the parent/legal guardian of the patient for publication of the details of their medical case and any accompanying images.

Conflict of Interest Statement

The authors have no conflicts of interest to declare.

Funding Sources

This study did not receive any funding.

Author Contributions

Wataru Omata: investigation, writing – original draft. Satoko Nakamura, Chie Urasaki, Hiromichi Morita, and Hiroki Funaishi: writing – review and editing. Kazuki Kobayashi and Hisashi Koide: writing – review and editing, and supervision. Arata Tsutsumida and Hiroyuki Matsue: supervision.

Data Availability Statement

All data generated or analysed during this study are included in this article. Further enquiries can be directed to the corresponding author.

References

- 1 Topalian SL, Sznol M, McDermott DF, Kluger HM, Carvajal RD, Sharfman WH, et al. Survival, durable tumor remission, and long-term safety in patients with advanced melanoma receiving nivolumab. *J Clin Oncol*. 2014 Apr;32(10):1020–30.
- 2 Yamazaki N, Kiyohara Y, Uhara H, Uehara J, Fujisawa Y, Takenouchi T, et al. Long-term follow up of nivolumab in previously untreated Japanese patients with advanced or recurrent malignant melanoma. *Cancer Sci*. 2019 Jun;110(6):1995–2003.
- 3 Robert C, Long GV, Brady B, Dutriaux C, Maio M, Mortier L, et al. Nivolumab in previously untreated melanoma without BRAF mutation. *N Eng J Med*. 2015 Jan;372(4):320–30.
- 4 Weber J, Mandala M, Del Vecchio M, Gogas HJ, Arane AM, Cowey CL, et al. Adjuvant nivolumab versus ipilimumab in resected stage III or IV melanoma. *N Eng J Med*. 2017 Nov;377(19):1824–35.
- 5 Larkin J, Chiarion-Sileni V, Gonzalez R, Grob JJ, Rutkowski P, Lao CD, et al. Five-year survival with combined nivolumab and ipilimumab in advanced melanoma. *N Eng J Med*. 2019 Oct;381(16):1535–46.
- 6 Chang LS, Barroso-Sousa R, Tolaney SM, Hodi FS, Kaiser UB, Min L. Endocrine toxicity of cancer immunotherapy targeting immune checkpoints. *Endocr Rev*. 2019 Feb;40(1):17–65.
- 7 Okano Y, Satoh T, Horiguchi K, Toyoda M, Osaki A, Matsumoto S, et al. Nivolumab-induced hypophysitis in a patient with advanced malignant melanoma. *Endocr J*. 2016 Oct;63(10):905–12.
- 8 Ishikawa M, Oashi K. Case of hypophysitis caused by nivolumab. *J Dermatol*. 2017 Jan;44(1):109–10.
- 9 Kitajima K, Ashida K, Wada N, Suetsugu R, Takeichi Y, Sakamoto S, et al. Isolated ACTH deficiency induced by autoimmune-related mechanism evoked with nivolumab. *Jpn J Clin Oncol*. 2017 May;47(5):463–6.
- 10 Fujimura T, Kambayashi Y, Furudate S, Kakizaki A, Hidaka T, Haga T, et al. Isolated adrenocorticotropic hormone deficiency caused by nivolumab in a metastatic melanoma patient. *J Dermatol*. 2017 Mar;44(3):e13–4.
- 11 Narahira A, Yanagi T, Cho KY, Nakamura A, Miyoshi H, Hata H, et al. Isolated adrenocorticotropic hormone deficiency associated with nivolumab therapy. *J Dermatol*. 2017 Apr;44(4):e70.
- 12 Oda T, Sawada Y, Okada E, Yamaguchi T, Ohmori S, Haruyama S, et al. Hypopituitarism and hypothyroidism following atrioventricular block during nivolumab treatment. *J Dermatol*. 2017 Jun;44(6):e144–5.
- 13 Kitano S, Tatsuno K, Ishibe J, Shimauchi T, Fujiyama T, Ito T, et al. Isolated adrenocorticotropic hormone deficiency in melanoma patients treated with nivolumab. *Acta Derm Venereol*. 2018 Jul;98(7):704–5.
- 14 Takeno A, Yamamoto M, Morita M, Tanaka S, Kanazawa I, Yamauchi M, et al. Late-onset isolated adrenocorticotropic hormone deficiency caused by nivolumab: a case report. *BMC Endocr Disord*. 2019 Feb;19(1):25.
- 15 Faje A, Reynolds K, Zubiri L, Lawrence D, Cohen JV, Sullivan RJ, et al. Hypophysitis secondary to nivolumab and pembrolizumab is a clinical entity distinct from ipilimumab-associated hypophysitis. *Eur J Endocrinol*. 2019 Sep;181(3):211–9.