

ORIGINAL ARTICLE

Detection and localization of atypical porcine pestivirus in the testicles of naturally infected, congenital tremor affected piglets

Lilla Dénes¹  | Inés Ruedas-Torres² | Anna Szilasi¹  | Gyula Balka¹ 

¹ Department of Pathology, University of Veterinary Medicine, Budapest, Hungary

² Department of Anatomy and Comparative Pathology and Toxicology, Faculty of Veterinary Medicine, University of Córdoba, Córdoba, Spain

Correspondence

Gyula Balka, Department of Pathology, University of Veterinary Medicine, 1078 Budapest, István Str. 2., Hungary.
Email: balka.gyula@univet.hu

Funding information

National Research, Development and Innovation Fund of Hungary, Grant/Award Number: 2020-4.1.1-TKP2020; János Bolyai Research Scholarship of the Hungarian Academy of Sciences; the Bolyai + Fellowship, Grant/Award Number: ÚNKP-20-5-ÁTE-2; the ÚNKP-4 New National Excellence Program of the Ministry of Human Capacities European Union and European Social Fund, Grant/Award Number: EFOP-3.6.1-16-2016-00024

Abstract

Atypical porcine pestivirus (APPV) belongs to the genus *Pestivirus* within the family *Flaviviridae*. Recently, APPV has been identified as the causative agent of congenital tremor (CT) type All. The disease is a neurological disorder that affects newborn piglets and is characterized by generalized trembling of the animals and often splay legs. CT is well known worldwide, and the virus seems to be highly prevalent in major swine producing areas. However, little is known about the epidemiology of the infection, transmission and spread of the virus between herds. Here, we show the high prevalence of APPV in processing fluid samples collected from Hungarian pig herds which led us to investigate the cellular targets of the virus in the testicles of newborn piglets affected by CT. By the development of an RNA in situ hybridization assay and the use of immunohistochemistry on consecutive slides, we identified the target cells of APPV in the testicle: interstitial Leydig cells, peritubular myoid cells and smooth muscle cells of medium-sized arteries. Previous studies have shown that APPV can be found in the semen of sexually mature boars suggesting the role of infected boars and their semen in the transmission of the virus similar to many other members of the *Flaviviridae* family. As in our case, the virus has not been identified in cells beyond the Sertoli cell barrier, further studies on infected adult boars' testicles and other reproductive glands are needed to analyze the possible changes in the cell tropism of APPV that might contribute to its prolonged extraction by the semen beyond the period of viraemia.

KEYWORDS

Pestivirus K, congenital tremor, viral tropism, immunohistochemistry, RNA ISH

1 | INTRODUCTION

Atypical porcine pestivirus (APPV) (species *Pestivirus K*) belongs to the genus *Pestivirus* within the family of *Flaviviridae* and includes highly variable RNA viruses capable of infecting cloven-hoofed animals as well as bats (Wu et al., 2012) and rats (Firth et al., 2014). They are often characterized by their detrimental effects on the embryo or foetus, causing neuronal degeneration and subsequent neurological dys-

function and developmental anomalies such as cerebellar hypoplasia, demyelination or even stillbirth. The neurological dysfunction may result in congenital tremor (CT), also known as myoclonia congenita, which is characterized by tremors of the head and limbs of newborn piglets (Done et al., 1986). The *Pestivirus* genus comprises 11 species: *Pestivirus A* (bovine viral diarrhoea virus 1), *Pestivirus B* (bovine viral diarrhoea virus 2), *Pestivirus C* (classical swine fever virus), *Pestivirus D* (border disease virus), *Pestivirus E* (pronghorn pestivirus), *Pestivirus*

This is an open access article under the terms of the [Creative Commons Attribution-NonCommercial](https://creativecommons.org/licenses/by-nc/4.0/) License, which permits use, distribution and reproduction in any medium, provided the original work is properly cited and is not used for commercial purposes.

© 2021 The Authors. *Transboundary and Emerging Diseases* published by Wiley-VCH GmbH

F (Bungowannah virus), *Pestivirus G* (giraffe pestivirus), *Pestivirus H* (Hobi-like pestivirus), *Pestivirus I* (Aydin-like pestivirus), *Pestivirus J* (rat pestivirus) and *Pestivirus K* (atypical porcine pestivirus) (Smith et al., 2017).

APPV was discovered in the United States in 2015, by metagenomic sequencing of a sample, which was real-time quantitative reverse transcription PCR (qRT-PCR) positive for porcine reproductive and respiratory syndrome virus (PRRSV) (Hause et al., 2015). To date, APPV has been identified in Germany (Beer et al., 2017; Postel et al., 2016), Sweden (Blomström et al., 2016), the Netherlands (de Groof et al., 2016), Austria (Schwarz et al., 2017), Spain (Muñoz-González et al., 2017), China (Yuan et al., 2017), Great Britain, Italy (Postel et al., 2017), Brazil (Gatto, Harmon, et al., 2018), Hungary (Dénes et al., 2018), Canada (Dessureault et al., 2018), Switzerland (Kaufmann et al., 2019), Japan (Kasahara-kamiie et al., 2021) and most recently in Denmark (Pedersen et al., 2021). APPV was also detected in wild boars in Germany and Serbia (Cagatay et al., 2018), suggesting that, similar to classical swine fever, wild boars may serve as a virus reservoir (Vilček & Nettleton, 2006).

CT is characterized by tremors of the head and limbs, and it is often complicated with splayed legs (Arruda et al., 2016; de Groof et al., 2016; Schwarz et al., 2017). It has been historically classified according to the absence (type B) or presence of lesions in the central nervous system and knowledge of the etiology (type A) (Dall Agnol et al., 2020; Done et al., 1986). Type A has been divided into different subtypes from I to V, based on the causal factor (Done et al., 1986). CT caused by APPV has been associated with hypomyelination in the cerebellum and spinal cord (Dessureault et al., 2018; Mósená et al., 2018; Schwarz et al., 2017). Experimental studies were carried out to prove the connection between type AII CT and APPV infection and to fulfil Koch's postulates. In an experiment carried out by de Groof et al. (2016), CT was successfully induced in piglets of pregnant gilts that were inoculated intramuscularly with APPV-positive serum at 28 days of gestation. CT was successfully reproduced in another experiment as well, where pregnant sows were inoculated by intravenous and intranasal routes simultaneously with direct inoculation of fetal amniotic vesicles at either 45 or 62 days of gestation. The prevalence of CT and splay leg among piglets of APPV-infected litters ranged from 57% to 100% and from 0% to 40%, respectively (Arruda et al., 2016). At its first discovery, the isolation of the virus was attempted on MARC-145, Vero, Vero 76, HCT-8, BT, MDBK, ST, PK15 and MDCK cell lines, but after two passages on cells, all samples were qRT-PCR negative. No cytopathic effect (CPE) was discernible in any cell line (Hause et al., 2015). Since then, similar approaches have been undertaken by other research groups with partial success (Arruda et al., 2016; de Groof et al., 2016; Lamp et al., 2017; Sozzi et al., 2019).

Severe CT outbreaks were recorded in Austria in 2013, and 4 years later APPV was proven to be the causative agent. Malnutrition was observed in numerous piglets, overall piglet mortality was increased and the number of weaned piglets per sow decreased by 10% (Schwarz et al., 2017).

Other viral agents have been also proposed as possible causative agents of type AII CT. First, astroviruses and porcine circovirus type 2 (PCV2) seemed to be potential candidates, but later studies could not

support these theories (Blomström et al., 2014; Gustafson & Kaintz, 1974; Stevenson et al., 2001). In a recent challenge study, pregnant gilts were inoculated with bovine viral diarrhoea virus-2 (BVDV-2), but the piglets showed no signs of CT, they were PCR-negative for the presence of BVDV-2 in their serum and organ samples, and the characteristic histomorphological lesions of type AII CT were absent in the central nervous system (CNS) (Mechler et al., 2018). Linda virus, another novel porcine pestivirus, was described in Austria (Lamp et al., 2017).

In addition to the CNS, APPV has been detected in various other tissues such as lymphoid organs (thymus, lymph node, tonsil and spleen), digestive tract (small and large intestines, pancreas and liver), lungs and hearts (Arruda et al., 2016; Postel et al., 2016). The virus was previously described in endothelial cells in the lymph nodes, spleen, liver and kidney (Liu et al., 2019) and recently within endothelial cells, vascular tunics, fibroblasts and the fibromuscular stroma the liver, kidney, colon, lung, lymph nodes, tonsil, thymus and thyroid. The tunica albuginea and the lumen of the seminiferous tubules also proved to be positive for the viral RNA (Buckley et al., 2021). The presence of APPV in preputial fluids and semen of boars has been confirmed (de Groof et al., 2016; Gatto, Arruda, et al., 2018; Schwarz et al., 2017), suggesting a potential role of insemination in virus transmission. In this sense, the male reproductive tract might serve as a virus reservoir, which has already been described for other pestiviruses such as classical swine fever virus (CSFV) (Choi & Chae, 2002) and BVDV (Voges et al., 1998) contributing to the persistence and transmission of the virus.

The porcine male reproductive tract is known for being highly susceptible to numerous viral infections (Maes et al., 2016; Phillips et al., 1972). The mammalian testis consists of two main compartments: (i) the interstitium, which includes the interstitial endocrine cells (Leydig cells) responsible for testosterone production, macrophages, fibroblasts and blood vessels and (ii) the seminiferous tubules, which are bordered by the peritubular myoid cells and composed of germ cells in different stages that are associated with the somatic Sertoli cells. Viruses have been found in both compartments in humans and other mammals as well (Dejucq & Jégou, 2001). The first line of testicular defence against viruses arriving from the bloodstream is the Leydig cells and testicular macrophages, whereas the second line involves the myoid cells and the Sertoli cells (Dejucq & Jégou, 2001).

As the presence of APPV in the testicles of naturally infected, CT-affected newborn piglets has not been reported so far, our research aimed to (i) identify the presence of the virus in the testicle by molecular methods, (ii) visualize the viral RNA by in situ hybridization (RNAscope) and (iii) identify the infected cell type(s) in the testis of newborn piglets by the use of immunohistochemistry on consecutive slides.

2 | MATERIALS AND METHODS

2.1 | Samples

Altogether 79 batches of processing fluid (the serosanguinous fluid recovered from the testicles after castration) were collected from 13 Hungarian large scale pig farms in 2018–2020 originally for PRRSV

screening (Lopez et al., 2018). Each batch contained the testicles of piglets from 10 to 15 litters. The filtered processing fluid samples were kept at -80°C and further analyzed for the presence of APPV.

Six 1-day-old intact male piglets from two different farms (three from Farm 1 and three from Farm 2) (the CT-affected animals were littermates, whereas the healthy ones were selected from elsewhere) were humanely euthanized according to the current Hungarian animal welfare regulations (Ethical permission number: PE/EA/544-5/2018). Two animals from each farm were affected by CT, whereas two other clinically healthy piglets served as controls. Tissue samples (cerebellum, brainstem, cerebrum, tonsil, kidney, tracheobronchial lymph node, spleen, thymus, colon and mesenteric lymph node) were collected for PCR analysis, and one of the testicles was fixed in 10% neutral buffered formalin for 24 h, then after dehydration embedded in paraffin.

2.2 | RNA extraction and qPCR

The fluid fraction was collected from the bags containing the testicles as described earlier (Lopez et al., 2018), whereas the organ samples collected during the necropsies were homogenized by the use of Tissuelyzer II (Qiagen, Hilden, Germany) and centrifuged at 3000 rpm for 3 min. RNA was extracted from the processing fluid and the tissue homogenate supernatants by Indispin/Cador Pathogen Mini Kit (Qiagen) according to the manufacturer's instructions in a QIAcube instrument (Qiagen). RNA was eluted in $60\ \mu\text{l}$ RNase free distilled water (Qiagen) and directly used for qRT-PCR analysis or archived at -80°C for further analysis.

qRT-PCR analysis was implemented by QuantiNova SYBR RT-PCR Kit (Qiagen) according to the manufacturer's recommendations using primers previously designed by Kaufmann et al. (2019) for the UTR 5' region of APPV. We added $2\ \mu\text{l}$ template RNA to $10\ \mu\text{l}$ $2\times$ QuantiNova SYBR Green RT-PCR Master Mix, $0.4\ \mu\text{M}$ of the forward and reverse primer, $0.2\ \mu\text{l}$ QN SYBR Green RT-Mix in a final volume of $25\ \mu\text{l}$. Measurements and analysis were performed in a Rotor-Gene Q instrument (Qiagen) using the following thermal profile: 50°C for 5 min, 95°C for 20 s and 45 cycles of 95°C for 3 s, followed by 60°C for 30 s. The mean Cq values were compared by one-way analysis of variance (ANOVA) with Tukey–Kramer post hoc tests using GraphPad Prism version 8.0.1 for Windows (GraphPad Software, n.d.) and the statistical significance was set at $p < .05$.

2.3 | APPV in situ hybridization (RNAscope)

RNA in situ hybridization (ISH) for the APPV genome in the testicles was performed manually using RNAscope 2.5 HD Detection Kit (RED) (Advanced Cell Diagnostics, Newark, CA, USA) according to the manufacturer's instructions using a probe (catalog number: 503381) that were designed to bind to the sequence region of nucleotides 1–2816 of the genes encoding the NS2–NS3 proteins. Briefly, $5\ \mu\text{m}$ thin sections were cut from formalin-fixed, paraffin-embedded (FFPE) blocks and were pre-treated with heat and protease before hybridization with the target oligonucleotide probes. Pre-amplifier, amplifier and AP-labelled

oligos were then hybridized sequentially, followed by chromogenic precipitate development. The integrity of the RNA and the specificity of the reaction was tested with a positive control probe specific to Ss-PPIB RNA (*Sus scrofa* peptidylprolyl isomerase B) and with a negative control probe specific to bacterial dapB RNA (*Bacillus subtilis* dihydrodipicolinate reductase), respectively. Testicles obtained from the healthy piglets served as virus-negative control.

2.4 | Immunohistochemistry

The immunohistochemical (IHC) antibodies for the identification of different cell types were anti-von Willebrand Factor (vWF, polyclonal rabbit anti-human, diluted 1:500, DAKO, Glostrup, Denmark) for the endothelial cells; anti-c-kit (diluted 1:200, polyclonal rabbit anti-human, DAKO) for the Leydig cells and germ cells, anti-alpha smooth muscle actin (α -SMA, diluted 1:100, monoclonal mouse anti-human clone1A4, DAKO) for the detection of contractile smooth muscle elements in various cell types.

For the IHC investigations, consecutive 3–4 μm thin sections were cut from the FFPE blocks of the testicles. The slides were deparaffinized in xylene (2×10 min) and 96% alcohol (2×5 min). The deparaffinized sections were treated with peroxidase-blocking reagent (EnVision FLEX, Agilent, Santa Clara, CA, USA) for 5 min after treatment with appropriate target retrieval (Target Retrieval Solution, DAKO) pH = 9, in a microwave oven at 800 W, for 25 min in case of the vWF and c-kit and 10 min in the case of α -SMA. Sections were treated with the given primary antibody for 30 min at room temperature. Antigen-bound primary antibody was detected using standard avidin-biotin immunoperoxidase complex (EnVision FLEX HRP kit, Agilent), using 3, 3'-diaminobenzidine tetrahydrochloride (DAB substrate-chromogen, DAKO) as chromogen substrate. Counterstaining was performed with Haematoxylin GILL II (Merck, Darmstadt, Germany) for 30 s. Finally, before mounting, the sections were treated with graded ethanol (2×5 min) and xylene (2×5 min). The slides were mounted with DPX non-aqueous mounting medium (Sigma Aldrich, Darmstadt, Germany). For both ISH and IHC, reactions were carried out parallelly on the testicles of every six animals.

Both ISH and IHC treated slides were scanned with a Panoramic Midi slide scanner instrument (3DHitech; Budapest, Hungary), the digital slides were analyzed and the representative pictures were taken with the CaseViewer software (3DHitech). The MultiView Toolbox function of the Case Viewer software was used to align the digital version of the consecutive slides to each other.

3 | RESULTS

3.1 | Real-time quantitative reverse transcription PCR

We detected APPV in 10 out of the 13 investigated farms in the processing fluid samples. Only two of these farms have ever experienced CT among newborn piglets. APPV was also detected in the testicles

TABLE 1 Atypical porcine pestivirus (APPV) detection in the testicles of the animals included in the study by real-time quantitative reverse transcription PCR (qRT-PCR) and RNAscope

Animal ID	Congenital tremor	Testicle qRT-PCR (Cq value)	RNAscope (testicle)
I	-	-	-
II	+	22.94	+
III	+	23.72	+
IV	-	-	-
V	+	34.15	+
VI	+	27.09	+

of all four CT-affected animals by qRT-PCR (and RNAscope), while the testicles of unaffected animals showed no viral presence (Table 1).

By qRT-PCR assay every organ sample collected during the necropsies (cerebellum, brainstem, cerebrum, tonsil, kidney, tracheobronchial lymph node, spleen, thymus, colon and mesenteric lymph node samples) of the CT-affected animals showed positivity (except the mesenteric lymph node of Animal V). Interestingly, APPV was also detected in the cerebellum (Cq value 30.14) and the tonsil (Cq value 26.53) of the clinically healthy Animal I.

There was no significant difference between the mean Cq values of tissue types (Figure 1).

3.2 | RNA in situ hybridization and immunohistochemistry

RNA integrity and tissue fixation/pre-treatment conditions proved to be adequate as no red signal was detected in the slides treated with

the negative control probe (Figure 2a), while an intense red signal was apparent in the case of the housekeeping positive control probe (Figure 2b).

APPV infected cells in the testicular slides of CT-affected newborn piglets were successfully identified by RNAscope in all four cases (II, III, V and VI) as an intracytoplasmatic red signal. The positive cells were found in three distinct compartments of the testis: among cells of the otherwise prominent testicular interstitium, in fusiform cells around the primitive, non-functional seminiferous tubules and also in the wall of medium-sized (non-capillary) arteries (Figure 3).

For the identification of these cells, we used multiple immunohistochemistry stainings on consecutive slides. Endothelial cells of the blood vessels were labelled with anti-vWF antibody (Figure 4b). Interstitial Leydig cells and germ cells were identified by anti-c-kit antibody (Figure 4c), and smooth muscle containing cells around the seminiferous tubules were labelled with anti- α -SMA antibody (Figure 4a), whereas the same area stained by RNAscope ISH is also shown in Figure 4d.

In some areas, the distribution of vWF positive cells was similar to the ones labelled with α -SMA due to the double positivity of the blood vessels. However, intense cytoplasmic positivity of the peritubular fusiform cells was only observed in the case of α -SMA labelling, indicating the presence of smooth muscle fibres in their cytoplasm without being related to blood vessels. These cells are the peritubular myoid cells in the testicle. The results obtained by the different immunohistochemical and RNAscope staining of the consecutive slides suggest that APPV is predominantly localized in the Leydig cells of the interstitium as well as in the peritubular myoid cells located around the seminiferous tubules (Figure 3). No viral genome was detected in the germ cells and the Sertoli cells or the negative control animals, and similar distribution of the ISH positivity was observed in the testicles of every CT-affected animal.

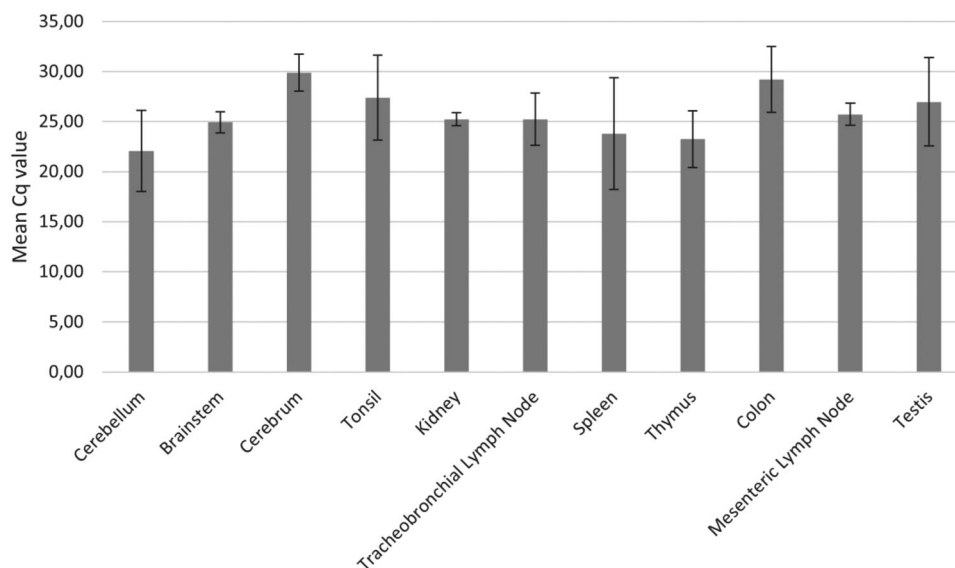


FIGURE 1 Tissue tropism of atypical porcine pestivirus (APPV). Average real-time quantitative reverse transcription PCR (qRT-PCR) Cq values by sample type of the four congenital tremor (CT)-affected piglets are shown, with ± 1 SD as error bars

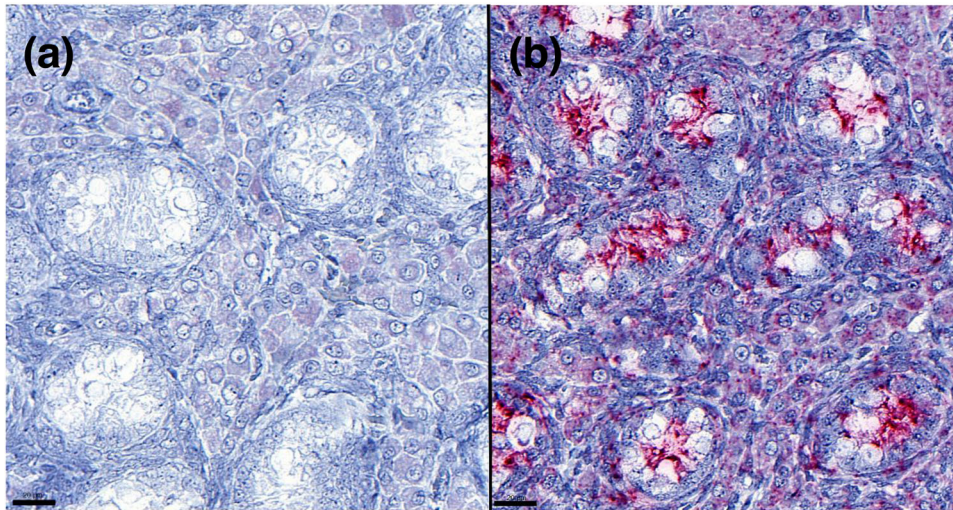


FIGURE 2 A negative control probe (dapB, a) and a positive control probe (Ss-PPIB, b) were used for RNAscope, testing the integrity of RNA

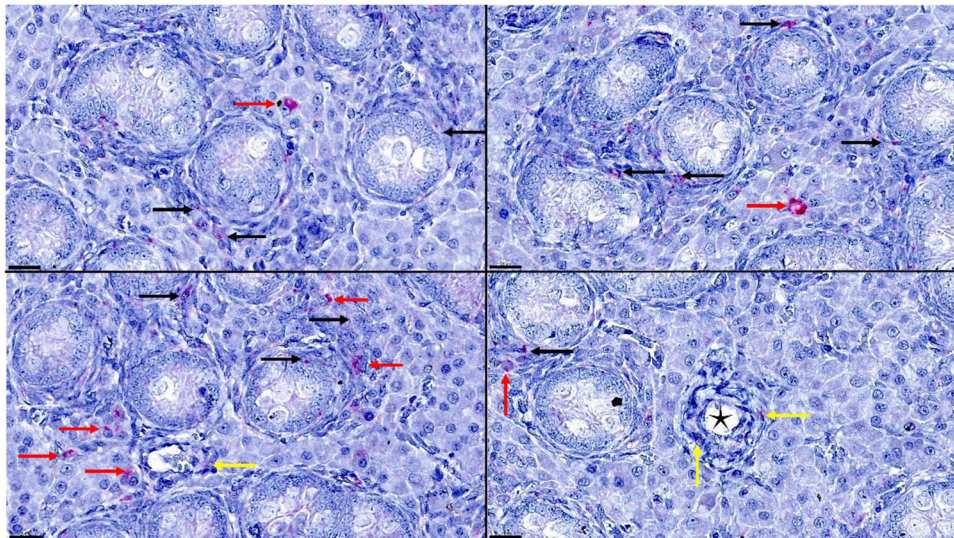


FIGURE 3 Representative pictures of atypical porcine pestivirus (APPV) RNA scope in situ hybridization (ISH) genome on the testicle samples. Black arrows point at positive peritubular myoid cells, and red arrows show the signal in the interstitial Leydig cells, whereas the yellow arrows indicate positive endothelial cells in the wall of medium-sized arteries marked by black stars. 600 \times , bar = 20 μ m

4 | DISCUSSION

During the screening of testicular processing fluid samples obtained for PRRSV monitoring of newborns, we found an unexpectedly high prevalence of APPV in this sample type even in farms that never experienced CT outbreaks. Processing fluid is primarily used for PRRSV screening in newborn animals, as the presence of the virus in this age group refers to active virus circulation in the breeding herd (Lopez et al., 2018). To our knowledge, this is the first report on the use of processing fluid to detect APPV in piglets. The high rate of detection suggests widespread congenital infection of the newborn piglets even in the absence of CT. This finding and the testicular tropism of other members of the *Pestivirus* genus led us to further investigate the organs

of naturally infected newborn piglets with special emphasis on the testicles.

We obtained 2–2 CT-affected newborn male piglets and 1–1 control animals from large scale swine farms and collected organ samples to verify the presence of APPV in them. Real-time qPCR analysis revealed APPV positivity in every tested organ of the CT-affected animals with no significant differences in the viral loads. One of the two healthy age-matched control animals was negative for the presence of the virus, while we identified it in the cerebellum and the tonsil of Animal I.

There are only a few reports in the literature that describe the target cells in testicular pestivirus infections (Choi & Chae, 2002; Read et al., 2020; Storino et al., 2020; Voges et al., 1998). A closely related pestivirus, BVDV was identified in the testes of a post-puberty bull,

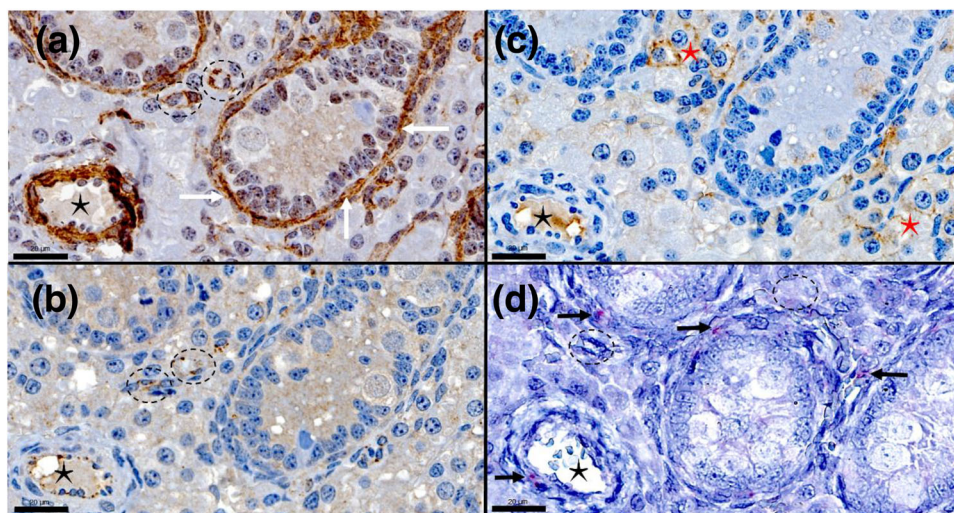


FIGURE 4 Representative pictures of alpha smooth muscle actin (α -SMA) (a), von Willebrand Factor (vWF) (b), c-kit (c) immunohistochemical (IHC) stainings and the RNAscope ISH (d) on consecutive slides. Black asterisks in the left bottom corner indicate the same artery, dashed circles in (b) and (d) indicate capillaries in the interstitial compartment. White arrows point at α -SMA positive peritubular myoid cells in (a), red asterisks show the c-kit positive interstitial Leydig cells in (c), whereas the black arrows point at atypical porcine pestivirus (APPV) genome labelled as red ISH signal in (d). 300 \times , bar = 50 μ m

persistently shedding the virus in the semen for almost a year. The authors found that the virus was sequestered in the testes; therefore, it was hypothesized, that the bull was infected after puberty, as the virus was protected in the testes from the bull's immune response by the Sertoli cell barrier, which only becomes functional after puberty when the tight junctions between the Sertoli cells are formed (Voges et al., 1998).

More recent research analyzed the testicles of bulls that had persistent BVDV infection confined to their reproductive tract shedding the virus through semen for a prolonged period. The authors showed that the virus was localized in the seminiferous tubules, resulting in a reduced or collapsed lumen diameter lined by a Sertoli cell layer or near-total loss of Sertoli cells, leading to the increased prominence of Leydig cells. Furthermore, BVDV was also detected in still-existing germinal cell stages (Read et al., 2020). Another study concerning BVDV showed no virus shedding through the reproductive route, although the duration of the study was shorter (Storino et al., 2020). On the other hand, classical swine fever virus, another closely related pestivirus of pigs, was not detected in Sertoli, Leydig or endothelial cells of the testicle, but it was identified in monocytes and macrophages with large oval nuclei and abundant cytoplasm (Choi & Chae, 2002).

In our study, APPV genome was successfully identified by the RNA-based ISH method (RNAscope) in the interstitial Leydig cells and in the smooth muscle cells of medium-sized arteries and spindle-shaped mesenchymal cells around the seminiferous tubules. On consecutive sections, the latter cells showed intense cytoplasmic positivity for α -SMA and were negative for vWF, suggesting that they are smooth muscle fibre bearing cells that are not related to blood vessels. These cells can be identified as the peritubular myoid cells of the testicle. Interestingly, we could not identify a positive signal in the endothelial cells of

capillaries even though the infection of these cells has been already confirmed for other organs in previous studies (Hu et al., 2019; Liu et al., 2019; Postel et al., 2016). Peritubular myoid cells are smooth muscle cells surrounding the seminiferous tubules. They provide the tubular structural integrity, play a role in the regulation of spermatogenesis and with their muscle fibres they take part in the contractions of the seminiferous tubule to aid the transport of spermatozoa in the tubular lumen (Maekawa et al., 1996). Leydig cells are also located in the intertubular compartment and are responsible for testosterone hormone production, which is important to maintain spermatogenesis and the male secondary sex characteristics (Mital et al., 2011).

In a recent study, Buckley et al. (2021) found a broad and systemic distribution of viral RNA including endothelial cells, fibroblasts and smooth muscle, whereas in the testicle they observed strong positivity in the tunica albuginea and moderate labelling in the lumen of the seminiferous tubules. Even though pictures were not included of the testicles, they did not report positivity in any of the cells we did in this organ. However, the involvement of vascular tunics, fibroblasts and muscle bearing mesenchymal cells in other organs suggests the involvement of similar target cells as we have observed in our study and as it has been reported for Phocoena pestivirus and other members of the *Pestivirus* genus (Jo et al., 2019). The involvement of smooth muscle cells of blood vessels was observed occasionally in the case of CSFV and BVDV (Liebler-Tenorio et al., 1997; Narita et al., 2000).

In our study, testicles of newborn animals were tested, in which the relative volume of the intertubular compartment – predominantly composed of Leydig cells and blood vessels – is significantly higher than in adults and is gradually decreasing till sexual maturity. As expected, an opposite trend can be observed for the volume of the tubular compartment (Avelar et al., 2010).

Schwarz et al. (2017) followed the course of viraemia of CT-affected piglets for 6 months and found high levels of APPV genome (2.1×10^9 GE/ml) in the semen of a boar that reached sexual maturity by that time. Even though the authors did not perform further investigations on their reproductive organs, for such a prolonged infection the virus must establish persistent infection either in the seminiferous tubules, an immune-privileged site in the testis protected by the Sertoli cell barrier, or in other parts of the male reproductive tract that contribute to semen production. The involvement of the seminiferous tubules has been observed in bulls with prolonged testicular infection of BVDV (Read et al., 2020) and also in the case of Zika virus, another flavivirus of human beings (Siemann et al., 2017), both of which are known for being transmitted via semen. In our case, the viral genome was not observed in cells beyond the Sertoli cell barrier (germ cells or Sertoli cells).

Based on our results and the study by Schwarz et al. (2017), it can be speculated that APPV infects different cells in the testicles of newborns compared to adult animals. In the case of prolonged testicular APPV infection, the virus could be able to gain access to cells beyond the Sertoli cell barrier to infect Sertoli cells and germ cells, enabling the virus to be excreted into the semen, as it has already been described for BVDV in bulls (Read et al., 2020). It cannot be excluded though that other cells of the male reproductive glands are infected as well that also release their content along with APPV in the semen. The latter cells, however, are not that well protected from the immune system of the animal.

An important observation of our study is that piglets born in APPV-infected farms with or without CT can be a source of infection for other age groups, and the testicles should be collected and discarded after castration preventing sows or other piglets to get in contact with them, considering that other viral diseases are also frequently detected in processing fluids (PRRS, PCV2 and others) (Lopez & Linhares, 2017; Trevisan et al., 2019). Moreover, male piglets that are born with symptoms of CT – even though they might recover from shaking and become clinically healthy – should not be kept for breeding purposes as they might be shedding the virus in their semen for a longer period. We have also proved that processing fluid is a cheap and useful diagnostic sample for the detection of APPV in a given farm that does not require additional stressful/painful handling of the animals.

Our future aim is to screen boar studs in our country for the presence of APPV in semen, estimate the prevalence of the infection/virus excretion, identify positive animals and in the case of culling, we will perform the same investigations on their testicles. Those results can reveal the actual role of insemination and semen transport in the transmission and epidemiology of APPV and identify the cellular sources of virus shedding in the semen.

To the best of our knowledge, our study is the first to analyze the cellular targets of APPV in the testicles of CT-affected newborn piglets. Consecutive slides prepared from the testicles of newborn male piglets and labelled with anti-vWF, anti-c-kit, and anti- α SMA antibodies by IHC and RNAscope ISH showed that the virus was localized in the intertubular compartment and the peritubular myoid cells of the testis without the involvement of the germ cells and Sertoli cells beyond the Sertoli cell barrier.

ACKNOWLEDGEMENTS

Project no. TKP2020-NKA-01 has been performed with the support provided from the National Research, Development and Innovation Fund of Hungary, financed under the Tématerületi Kiválósági Program 2020 (2020-4.1.1-TKP2020) funding scheme. Gyula Balka was supported by the János Bolyai Research Scholarship of the Hungarian Academy of Sciences and by the Bolyai + Fellowship (ÚNKP-20-5-ÁTE-2) of the New National Excellence Program of the Hungarian Ministry of Innovation and Technology. The Project is supported by the European Union and co-financed by the European Social Fund (grant agreement no. EFOP-3.6.1-16-2016-00024, project title: Institutional developments for intelligent specialization in cooperation between University of Veterinary Medicine and Faculty of Agricultural and Food Sciences of Széchenyi István University). Lilla Dénes was supported by the ÚNKP-4 New National Excellence Program of the Ministry of Human Capacities. The funding sources had no role in study design, data collection and analysis or the decision to publish the work.

CONFLICT OF INTEREST

The authors declare no conflict of interest.

ETHICS STATEMENT

The experiment was approved by the National Scientific Ethical Committee on Animal Experimentation. Ethical permission number: PE/EA/544-5/2018.

DATA AVAILABILITY STATEMENT

The data that support the findings of this study are available from the corresponding author upon reasonable request.

ORCID

Lilla Dénes  <https://orcid.org/0000-0003-0069-4914>

Anna Szilasi  <https://orcid.org/0000-0002-1634-6730>

Gyula Balka  <https://orcid.org/0000-0003-2742-173X>

REFERENCES

- Arruda, B. L., Arruda, P. H., Magstadt, D. R., Schwartz, K. J., Dohman, T., Schleining, J. A., Patterson, A. R., Visek, C. A., & Victoria, J. G. (2016). Identification of a divergent lineage porcine pestivirus in nursing piglets with congenital tremors and reproduction of disease following experimental inoculation, isolation and characterization of viruses from semen and the reproductive tract of male swine. *Plos One*, 11, e0150104. <https://doi.org/10.1371/journal.pone.0150104>
- Avelar, G. F., Oliveira, C. F.A., Soares, J. M., Silva, I. J., Dobrinski, I., Hess, R. A., & França, L. R. (2010). Postnatal somatic cell proliferation and seminiferous tubule maturation in pigs: A non-random event. *Theriogenology*, 74, 11–23. <https://doi.org/10.1016/j.theriogenology.2009.12.014>
- Beer, M., Wernike, K., Dräger, C., Höper, D., Pohlmann, A., Bergemann, C., Schröder, C., Klinkhammer, S., Blome, S., & Hoffmann, B. (2017). High prevalence of highly variable atypical porcine pestiviruses found in Germany. *Transboundary and Emerging Diseases*, 64, e22–e26. <https://doi.org/10.1111/tbed.12532>
- Blomström, A.-L., Fossum, C., Wallgren, P., & Berg, M. (2016). Viral metagenomic analysis displays the Co-infection situation in healthy and PMWS affected pigs. *Plos One*, 11, 1–11. <https://doi.org/10.1371/journal.pone.0166863>

- Blomström, A.-L., Ley, C., & Jacobson, M. (2014). Astrovirus as a possible cause of congenital tremor type All in piglets? *Acta Veterinaria Scandinavica*, 56, 82. <https://doi.org/10.1186/s13028-014-0082-y>
- Buckley, A. C., Falkenberg, S. M., Palmer, M. V., Arruda, P. H., Magstadt, D. R., Schwartz, K. J., Gatto, I. R., Neill, J. D., & Arruda, B. L. (2021). Distribution and persistence of atypical porcine pestivirus in experimentally inoculated pigs. *Journal of Veterinary Diagnostic Investigation*, 33, 952–955. <https://doi.org/10.1177/10406387211022683>
- Cagatay, G. N., Antos, A., Meyer, D., Maistrelli, C., Keuling, O., Becher, P., & Postel, A. (2018). Frequent infection of wild boar with atypical porcine pestivirus (APPV). *Transboundary and Emerging Diseases*, 65, 1087–1093. <https://doi.org/10.1111/tbed.12854>
- Choi, C., & Chae, C. (2002). Localization of classical swine fever virus in male gonads during subclinical infection. *Journal of General Virology*, 83, 2717–2721. <https://doi.org/10.1099/0022-1317-83-11-2717>
- Dall Agnol, A. M., Alfieri, A. F., & Alfieri, A. A. (2020). Pestivirus K (atypical porcine pestivirus): Update on the virus, viral infection, and the association with congenital tremor in newborn piglets. *Viruses*, 12, 903. <https://doi.org/10.3390/v12080903>
- De Groof, A., Deijs, M., Guelen, L., Van Grinsven, L., Van Os-Galdos, L., Vogels, W., Derks, C., Cruijnsen, T., Geurts, V., Vrijenhoek, M., Suijskens, J., Van Doorn, P., Van Leengoed, L., Schrier, C., & Hoek, L. (2016). Atypical porcine pestivirus: A possible cause of congenital tremor type A-II in newborn piglets. *Viruses*, 8, 271. <https://doi.org/10.3390/v8100271>
- Dejucq, N., & Jégou, B. (2001). Viruses in the mammalian male genital tract and their effects on the reproductive system. *Microbiol. Microbiology and Molecular Biology Reviews*, 65, 208–231. <https://doi.org/10.1128/membr.65.2.208-231.2001>
- Dénes, L., Biksi, I., Albert, M., Szeredi, L., Knapp, D. G., Szilasi, A., Bálint, Á., & Balka, G. (2018). Detection and phylogenetic characterization of atypical porcine pestivirus strains in Hungary. *Transboundary and Emerging Diseases*, 65, 2039–2042. <https://doi.org/10.1111/tbed.12981>
- Dessureault, F., Choinière, M., Provost, C., & Gagnon, C. (2018). First report of atypical porcine pestivirus in piglets with congenital tremor in Canada. *Canadian Veterinary Journal*, 59, 429–432.
- Done, J. T., Woolley, J., Upcott, D. H., & Hebert, C. N. (1986). Porcine congenital tremor type All: Spinal cord morphometry. *British Veterinary Journal*, 142, 145–150. [https://doi.org/10.1016/0007-1935\(86\)90090-4](https://doi.org/10.1016/0007-1935(86)90090-4)
- Firth, C., Bhat, M., Firth, M. A., Williams, S. H., Frye, M. J., Simmonds, P., Conte, J. M., Ng, J., Garcia, J., Bhuvu, N. P., Lee, B., Che, X., Quan, P.-L., & Lipkin, W. I. (2014). Detection of zoonotic pathogens and characterization of novel viruses carried by commensal *Rattus norvegicus* in New York city. *mBio*, 5, 1–16. <https://doi.org/10.1128/mBio.01933-14>
- Gatto, I. R. H., Arruda, P. H., Visek, C. A., Victoria, J. G., Patterson, A. R., Krull, A. C., Schwartz, K. J., De Oliveira, L. G., & Arruda, B. L. (2018). Detection of atypical porcine pestivirus in semen from commercial boar studs in the United States. *Transboundary and Emerging Diseases*, 65, e339–e343. <https://doi.org/10.1111/tbed.12759>
- Gatto, I. R. H., Harmon, K., Bradner, L., Silva, P., Linhares, D. C. L., Arruda, P. H., De Oliveira, L. G., & Arruda, B. L. (2018). Detection of atypical porcine pestivirus in Brazil in the central nervous system of suckling piglets with congenital tremor. *Transboundary and Emerging Diseases*, 65, 375–380. <https://doi.org/10.1111/tbed.12824>
- Gustafson, D. P., & Kaintz, C. L. (1974). Experimental transmission of congenital tremors in swine. *Proceedings of the United States Animal Health Association*, 338–345.
- Hause, B. M., Collin, E. A., Peddireddi, L., Yuan, F., Chen, Z., Hesse, R. A., Gauger, P. C., Clement, T., Fang, Y., & Anderson, G. (2015). Discovery of a novel putative atypical porcine pestivirus in pigs in the USA. *Journal of General Virology*, 96, 2994–2998. <https://doi.org/10.1099/jgv.0.000251>
- Hu, H. Z. W., Liu, J. L. T., & Xiao, T. O. C. (2019). Novel circovirus species identified in farmed pigs designated as Porcine circovirus 4, Hunan province, China. *Transboundary and Emerging Diseases*, 67, 1057–1061. <https://doi.org/10.1111/tbed.13446>
- Jo, W. K., Van Elk, C., Van De Bildt, M., Van Run, P., Petry, M., Jesse, S. T., Jung, K., Ludlow, M., Kuiken, T., & Osterhaus, A. (2019). An evolutionary divergent pestivirus lacking the N pro gene systemically infects a whale species. *Emerging Microbes & Infections*, 8, 1383–1392. <https://doi.org/10.1080/22221751.2019.1664940>
- Kasahara-kamiie, M., Kagawa, M., Shiokawa, M., Sunaga, F., Aihara, N., Shiga, T., Kamiie, J., & Aoki, H. (2021). Detection and genetic analysis of a novel atypical porcine pestivirus from piglets with congenital tremor in Japan. *Transboundary and Emerging Diseases*.
- Kaufmann, C., Stalder, H., Sidler, X., Renzullo, S., Gurtner, C., Grahofner, A., & Schweizer, M. (2019). Long-term circulation of atypical porcine pestivirus (APPV) within Switzerland. *Viruses*, 11, 1–14. <https://doi.org/10.3390/v11070653>
- Lamp, B., Schwarz, L., Högler, S., Riedel, C., Sinn, L., Rebel-Bauder, B., Weisenböck, H., Ladinig, A., & Rumenapf, T. (2017). Novel pestivirus species in pigs, Austria, 2015. *Emerging Infectious Diseases*, 23, 1176–1179. <https://doi.org/10.3201/eid2307.170163>
- Liebler-Tenorio, E. M., Greiser-Wilke, I., & Pohlenz, J. F. (1997). Organ and tissue distribution of the antigen of the cytopathogenic bovine virus diarrhoea virus in the early and advanced phase of experimental mucosal disease. *Archives of Virology*, 142, 1613–1634. <https://doi.org/10.1007/s007050050184>
- Liu, J., Li, Z., Ren, X., Li, H., Lu, R., Zhang, Y., & Ning, Z. (2019). Viral load and histological distribution of atypical porcine pestivirus in different tissues of naturally infected piglets. *Archives of Virology*, 164, 2519–2523. <https://doi.org/10.1007/s00705-019-04345-3>
- Lopez, W., Angulo, J., & Zimmerman, J. (2018). Porcine reproductive and respiratory syndrome monitoring in breeding herds using processing fluids. *Journal of Swine Health and Production*, 26, 146–150.
- Lopez, W., & Linhares, D. (2017). Processing fluids, blood serum, and tail blood swabs to detect PRRSV RNA and PCV2 DNA by PCR-based assays. In ISU James D. McKean Swine Disease Conference. (p. 69).
- Maekawa, M., Kamimura, K., & Nagano, T. (1996). Peritubular myoid cells in the testis: Their structure and function. *Archives of Histology and Cytology*, 59, 1–13. <https://doi.org/10.1679/aohc.59.1>
- Maes, D., Van Soom, A., Appeltant, R., Arsenakis, I., & Nauwynck, H. (2016). Porcine semen as a vector for transmission of viral pathogens. *Theriogenology*, 85, 27–38. <https://doi.org/10.1016/j.theriogenology.2015.09.046>
- Mechler, M. L., Gomes, F. D. S., Nascimento, K. A., Souza-Pollo, A. D., Pires, F. F. B., Samara, S. I., Pituco, E. M., & De Oliveira, L. G. (2018). Congenital tremor in piglets: Is bovine viral diarrhoea virus an etiological cause? *Veterinary Microbiology*, 220, 107–112. <https://doi.org/10.1016/j.vetmic.2018.05.009>
- Mital, P., Hinton, B. T., & Dufour, J. M. (2011). The blood-testis and blood-epididymis barriers are more than just their tight junctions. *Biology of Reproduction*, 84, 851–858. <https://doi.org/10.1095/biolreprod.110.087452>
- Mósená, A. C. S., Weber, M. N., Da Cruz, R. A. S., Cibulski, S. P., Da Silva, M. S., Puhl, D. E., Hammerschmitt, M. E., Takeuti, K. L., Driemeier, D., De Barcellos, D. E. S. N., & Canal, C. W. (2018). Presence of atypical porcine pestivirus (APPV) in Brazilian pigs. *Transboundary and Emerging Diseases*, 65, 22–26. <https://doi.org/10.1111/tbed.12753>
- Muñoz-González, S., Canturri, A., Pérez-Simó, M., Bohórquez, J. A., Rosell, R., Cabezón, O., Segalés, J., Domingo, M., & Ganges, L. (2017). First report of the novel atypical porcine pestivirus in Spain and a retrospective study. *Transboundary and Emerging Diseases*, 64, 1645–1649. <https://doi.org/10.1111/tbed.12699>
- Narita, M., Kawashima, K., Kimura, K., Mikami, O., Shibahara, T., Yamada, S., & Sakoda, Y. (2000). Comparative immunohistopathology in pigs infected with highly virulent or less virulent strains of hog cholera virus. *Veterinary Pathology*, 37, 402–408. <https://doi.org/10.1354/vp.37-5-402>
- Pedersen, K., Kristensen, C. S., Strandbygaard, B., Bøtner, A., & Rasmussen, T. B. (2021). Detection of atypical porcine pestivirus in piglets from Danish sow herds. *Viruses*, 13, 1–7. <https://doi.org/10.3390/v13050717>

- Phillips, R., Foley, C., & Lukert, P. (1972). Isolation and characterization of viruses from semen and the reproductive tract of male swine. *Journal of the American Veterinary Medical Association*, 161, 1306–1316.
- Postel, A., Hansmann, F., Baechlein, C., Fischer, N., Alawi, M., Grundhoff, A., Derking, S., Tenhüdfeld, J., Pfankuche, V. M., Herder, V., Baumgärtner, W., Wendt, M., & Becher, P. (2016). Presence of atypical porcine pestivirus (APPV) genomes in newborn piglets correlates with congenital tremor. *Scientific Reports*, 6, 27735. <https://doi.org/10.1038/srep27735>
- Postel, A., Meyer, D., Gagatay, G. N., Feliziani, F., De Mia, G. M., Fischer, N., Grundhoff, A., Milićević, V., Deng, M.-C., Chang, C.-Y., Qiu, H.-J., Sun, Y., Wendt, M., & Becher, P. (2017). High abundance and genetic variability of atypical porcine pestivirus in pigs from Europe and Asia. *Emerging Infectious Diseases*, 23, 2104–2107. <https://doi.org/10.3201/eid2312.170951>
- Read, A. J., Gestier, S., Parrish, K., Finlaison, D. S., Gu, X., O'connor, T. W., & Kirkland, P. D. (2020). Prolonged detection of bovine viral diarrhoea virus infection in the semen of bulls. *Viruses*, 12, 674. <https://doi.org/10.3390/v12060674>
- Schwarz, L., Riedel, C., Högl, S., Sinn, L. J., Voglmayr, T., Wöchtel, B., Dinhopf, N., Rebel-Bauder, B., Weissenböck, H., Ladinig, A., Rumenapf, T., & Lamp, B. (2017). Congenital infection with atypical porcine pestivirus (APPV) is associated with disease and viral persistence. *Veterinary Research*, 48, 1. <https://doi.org/10.1186/s13567-016-0406-1>
- Siemann, D. N., Strange, D. P., Maharaj, P. N., Shi, P.-Y., & Verma, S. (2017). Zika virus infects human Sertoli cells and modulates the integrity of the in vitro blood-testis barrier model. *Journal of Virology*, 91, 1570–1580. <https://doi.org/10.1128/JVI.00623-17>
- Smith, D. B., Meyers, G., Bukh, J., Gould, E. A., Monath, T., Scott Muerhoff, A., Pletnev, A., Rico-Hesse, R., Stapleton, J. T., Simmonds, P., & Becher, P. (2017). Proposed revision to the taxonomy of the genus Pestivirus, family Flaviviridae. *Journal of General Virology*, 98, 2106–2112. <https://doi.org/10.1099/jgv.0.000873>
- Sozzi, E., Salogni, C., Lelli, D., Barbieri, I., Moreno, A., Alborali, G. L., & Lavazza, A. (2019). Molecular survey and phylogenetic analysis of atypical porcine pestivirus (APPV) identified in swine and wild boar from Northern Italy. *Viruses*, 11, 1142. <https://doi.org/10.3390/v11121142>
- Stevenson, G. W., Kiupel, M., Mittal, S. K., Choi, J., Latimer, K. S., & Kanitz, C. L. (2001). Tissue distribution and genetic typing of porcine circoviruses in pigs with naturally occurring congenital tremors. *Journal of Veterinary Diagnostic Investigation*, 13, 57–62. <https://doi.org/10.1177/104063870101300111>
- Storino, G. Y., Xavier, E. B., Mechler-Dreibi, M. L., Simonatto, A., Gatto, I. R. H., Oliveira, M. E. F., Pituco, E. M., & De Oliveira, L. G. (2020). No effects of noncytopathic bovine viral diarrhoea virus type 2 on the reproductive tract of experimentally inoculated boars. *Veterinary Microbiology*, 240, 108512. <https://doi.org/10.1016/j.vetmic.2019.108512>
- Trevisan, G., Jablonski, E., Angulo, J., Lopez, W. A., & Linhares, D. C. L. (2019). Use of processing fluid samples for longitudinal monitoring of PRRS virus in herds undergoing virus elimination. *Porcine Health Management*, 5, 18. <https://doi.org/10.1186/s40813-019-0125-x>
- Vilček, Š., & Nettleton, P. F. (2006). Pestiviruses in wild animals. *Veterinary Microbiology*, 116, 1–12. <https://doi.org/10.1016/j.vetmic.2006.06.003>
- Voges, H., Horner, G. W., Rowe, S., & Wellenberg, G. J. (1998). Persistent bovine pestivirus infection localized in the testes of an immunocompetent, non-viraemic bull. *Veterinary Microbiology*, 61, 165–175. [https://doi.org/10.1016/S0378-1135\(98\)00177-1](https://doi.org/10.1016/S0378-1135(98)00177-1)
- Wu, Z., Ren, X., Yang, L., Hu, Y., Yang, J., He, G., Zhang, J., Dong, J., Sun, L., Du, J., Liu, L., Xue, Y., Wang, J., Yang, F., Zhang, S., & Jin, Q. (2012). Virome analysis for identification of novel mammalian viruses in bat species from Chinese provinces. *Journal of Virology*, 86, 10999–11012. <https://doi.org/10.1128/JVI.01394-12>
- Yuan, J., Han, Z., Li, J., Huang, Y., Yang, J., Ding, H., Zhang, J., Zhu, M., Zhang, Y., Liao, J., Zhao, M., & Chen, J. (2017). Atypical porcine pestivirus as a novel type of pestivirus in pigs in China. *Frontiers in Microbiology*, 8, 1–6. <https://doi.org/10.3389/fmicb.2017.00862>
- N.d.: GraphPad Software [Online]. www.graphpad.com.

How to cite this article: Dénes, L., Ruedas-Torres, I., Szilasi, A., & Balka, G. (2022). Detection and localization of atypical porcine pestivirus in the testicles of naturally infected, congenital tremor affected piglets. *Transboundary and Emerging Diseases*, 69, e621–e629. <https://doi.org/10.1111/tbed.14355>