

# Correction of Lobule-type Microtia: Part 2: The Stage of Ear Elevation

Takatoshi Yotsuyanagi, MD,  
PhD  
Makoto Yamauchi, MD, PhD  
Ken Yamashita, MD  
Tetsuo Yamada, MD  
Shinji Kato, MD  
Akiyo Suzuki, MD  
Tamotsu Saito, MD, PhD

**Background:** Here, we introduce our recent operative technique for ear elevation that results in (1) minimal morbidity for patients, (2) symmetric appearance, (3) clearer 3-dimensional structure with a deep concha, (4) good aesthetic appearance by hiding the grafted area behind the ear, and (5) maintenance of deep temporoauricular sulcus and angle.

**Methods:** After a skin incision, the ear is elevated with temporoparietal fascia underlying the cartilage. On the conchal area, undermining is performed just below the skin so that the deep concavity can be maintained. Scalp and neck skin behind the ear is undermined subcutaneously and lifted up cranially to hide the entire area of grafted skin behind the ear. The postauricular surface is covered by full-thickness skin from the lower abdomen. A protective splint is applied for 3 months while sleeping.

**Results:** A total of 137 ears in 121 patients were corrected with our technique and followed up for at least 3 years. All of the scar tissue could be hidden behind the ear, an aesthetically excellent result.

**Conclusions:** Our technique made it possible to acquire an excellent and symmetrical shape of the ear. The important points in our procedure are as follows: (1) subcutaneous posterior undermining to enlarge the conchal cavity, (2) careful arrangement of the temporoauricular angle and auriculo-earlobe angle, (3) reduction in the area of temporally grafted skin to hide all scars behind the ear, and (4) protection of the ear to maintain the shape using a postoperative splint. (*Plast Reconstr Surg Glob Open* 2014;2:e208; doi: 10.1097/GOX.000000000000136; Published online 5 September 2014.)

Ear elevation in microtia patients is not simply a procedure for creating a sulcus so patients can wear glasses or a mask but should also be considered as an important procedure for acquiring a 3-dimensional shape of the ear with a deep concha. This

procedure is also important to obtain a symmetrically accurate position, size and angle of the ear, and appropriate temporoauricular angle.<sup>1,2</sup> Here, we introduce our recent technique that results in (1) minimal morbidity for patients, (2) symmetric appearance, (3) more clearly pronounced 3-dimensional structure with a deep concha, (4) good aesthetic appearance by hiding the grafted area behind the ear, and (5) maintenance of a deep temporoauricular sulcus and angle.

*From the Department of Plastic and Reconstructive Surgery, Sapporo Medical University school of Medicine, Sapporo, Hokkaido, Japan.*

*Received for publication April 23, 2013; accepted May 29, 2014.*

*Copyright © 2014 The Authors. Published by Lippincott Williams & Wilkins on behalf of The American Society of Plastic Surgeons. PRS Global Open is a publication of the American Society of Plastic Surgeons. This is an open-access article distributed under the terms of the Creative Commons Attribution-NonCommercial-NoDerivatives 3.0 License, where it is permissible to download and share the work provided it is properly cited. The work cannot be changed in any way or used commercially.*

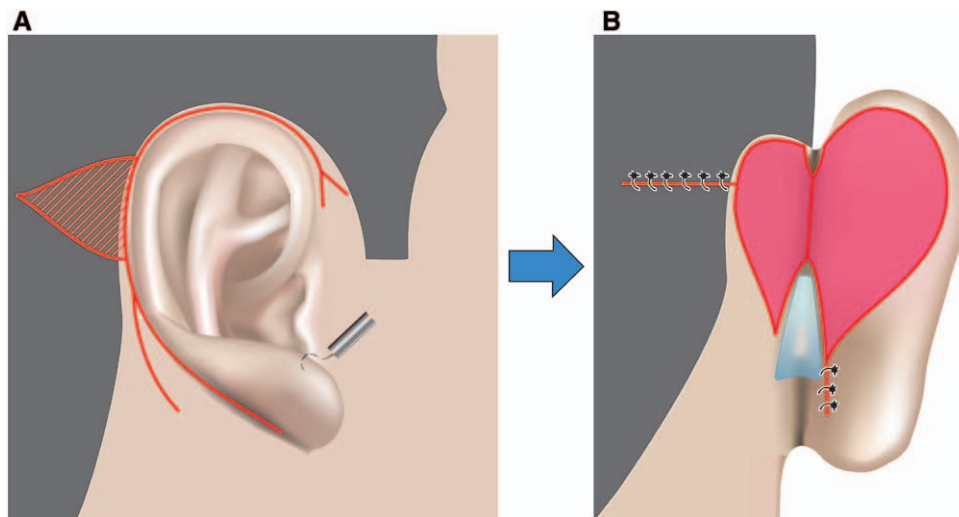
DOI: 10.1097/GOX.000000000000136

## TECHNIQUES AND METHODS

### Preoperative Preparation

It is important to fully comprehend the shape, axis, and position of the contralateral normal ear

**Disclosure:** *The authors have no financial interest to declare in relation to the content of this article. The Article Processing Charge was paid for by the authors.*



**Fig. 1.** Scheme of the technique for ear elevation. A, Design of the skin incision. Shaded, V-shaped area indicates the area of skin removal. Two triangular flaps are also designed cranially and caudally along the ear. B, Final appearance after the operation. Grafted cartilage is covered by the caudal triangular flap. The remaining temporal skin defect is covered by a split-thickness scalp skin graft from the excised V-shaped skin, and the postauricular defect is covered by abdominal skin.

because these aspects of the reconstructed ear can be finely controlled in the stage of ear elevation. Furthermore, attention should be paid to not only the temporoauricular angle but also the symmetry of earlobe shape and auriculo-earlobe angle. As the basic concept, the elevation angle of the ear should be accommodated to the contralateral ear. However, if the contralateral ear has a high elevation angle, the reduction of an elevation angle of the contralateral ear should be taken into consideration.

The film pattern copied on the basis of the contralateral ear is prepared as in the first stage of costal cartilage grafting.<sup>3</sup> Hair around the ear is shaved off to 1 or 2 cm in width. Both ears should be exposed in the operative field.

## Operation

### *Design of Skin Incision*

An incision in the skin is made along the grafted cartilage frame and on the line cap; 2 triangular flaps are made on the cranial and caudal sides. A V-shaped incision is made in the skin on the scalp, the area of which will be removed and directly sutured later (Fig. 1, Fig. 7B).

### *Elevation of the Ear*

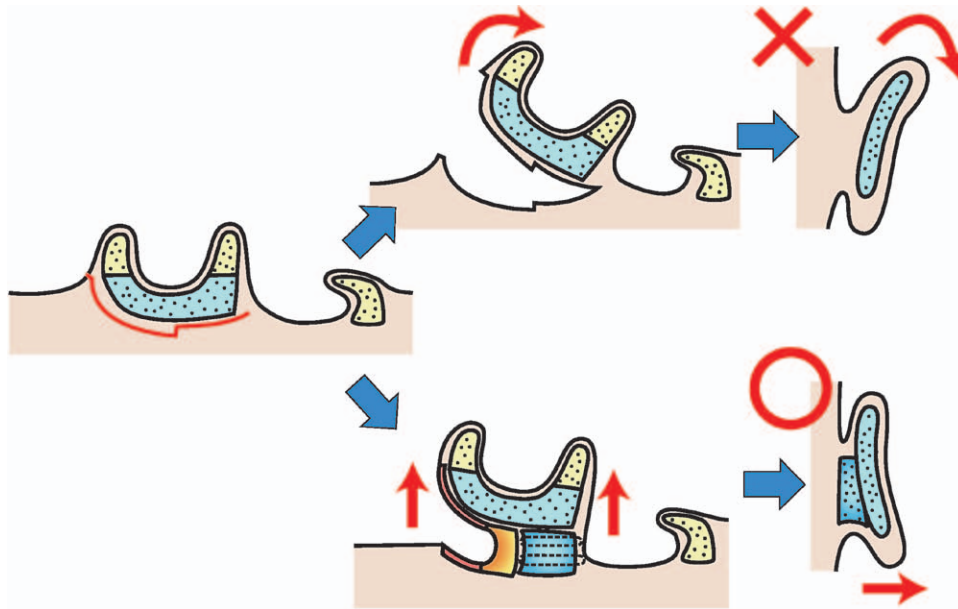
The ear is elevated along with the temporoparietal fascia underlying the cartilage from the helical margin toward the concha. When undermining comes to the posterior conchal area, the undermining is performed just below the skin of the area surrounding the concha. This makes the conchal cavity easily enlarged posteriorly and deeply. The impression for this procedure is that the ear is not elevated

and falls forward to the preauricular side, but the whole part of the ear is raised anteriorly and separated from the temporal plane (Fig. 2). It is particularly important for the earlobe part to be fully raised. The earlobe is separated from the cartilage, moved posteriorly, and sutured down as needed to fit with the auriculo-earlobe angle of the contralateral ear. The scalp and neck skin behind the ear is undermined subcutaneously and lifted up cranially. The resulting excess triangular skin (V-shaped incision area) in the scalp is removed and directly sutured. This procedure makes the temporal raw surface smaller, and the entire area of the grafted skin is completely hidden behind the ear (Fig. 1). A Penrose drain should be placed into the temporally undermined area, and some bolster sutures should be applied to prevent hematoma.

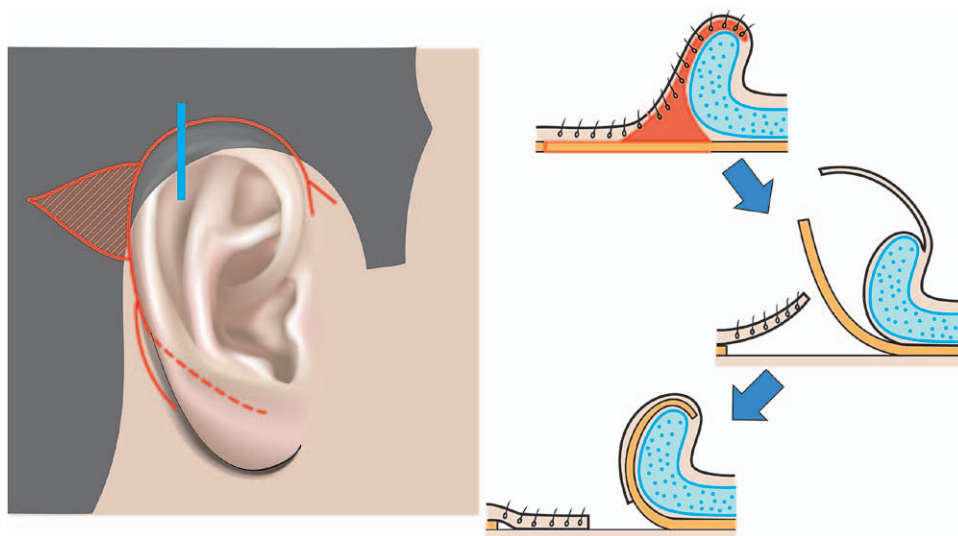
For cases in which hair-bearing skin is in part of the helix, the hair is removed simultaneously (Fig. 3). That is, after elevation of the ear, the hair-bearing skin is undermined in the superficial layer without hair follicles, hair follicles with underlying soft tissues on the cartilage frame are removed, and the frame is covered again by superficial skin. In these cases, it is recommended that the surrounding temporoparietal fascia be widely elevated and attached to the cartilage frame, turned over, and inserted under the undermining skin (Fig. 4). Thus, even if necrosis occurs in the undermined skin, exposure of the cartilage can be prevented.

### *Costal Cartilage Grafting*

The cartilage block banked in the first stage of the operation is removed from the chest and ar-



**Fig. 2.** Scheme of the image of ear elevation. Upper, The ear is not elevated but falls forward to the preauricular side. Lower, The whole part of the ear should be raised anteriorly and separated from the temporal plane.



**Fig. 3.** Scheme of the technique for low hairline cases. Right side shows the procedure in cross section of the left blue-lined area.

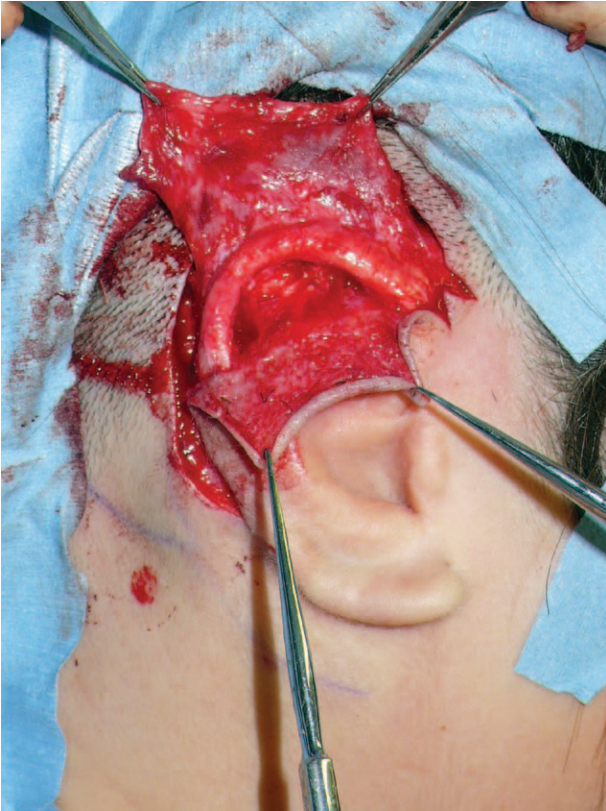ranged into an L-shape that thickens in proportion toward the caudal side. It is grafted on the posterior side of the concha to obtain a symmetrical position and temporoauricular angle. The rigid L-shaped structure prevents deformation due to falling down, and the thickness in the caudal side keeps a certain elevation of the earlobe and a deep conchal cavity (Fig. 7C). The inserted cartilage is firmly sutured down on the dermis of the concha and periosteum of the temporal bone (Fig. 7D).

The 2 triangular flaps on the cranial and caudal sides of the ear are raised and inserted into the tem-

poroauricular sulcus. The cranial flap is made small but works for keeping a space for wearing glasses and to prevent late ulcer formation. The caudal flap is made long and wide enough to cover the L-shaped cartilage (Fig. 1). These 2 flaps are also useful for dividing the grafted skin into temporal and postauricular surface areas and for preventing scar contracture.

#### *Skin Grafting*

The formerly removed V-shaped scalp skin is sliced, and the dermis and hair follicles are replaced and grafted as a split-thickness skin on the tempo-



**Fig. 4.** Surgical procedure for the low hairline cases. First, the hair-bearing skin is undermined at the superficial layer. Then, the layer including hair follicles is removed. Surrounding pedicled temporoparietal fascia is elevated for covering the cartilage frame.

ral skin defect. The postauricular surface is covered by full-thickness skin from the lower abdomen (Figs. 7E, F). Full-thickness skin is excellent for preventing scar contracture and protecting the underlying cartilage. It is harvested not from the inguinal area or pubic area but the area just inside the iliac crest to prevent pigmentation and hair growth in the grafted site in the future.

#### *Procedure for Earlobe Shape*

The base of the remnant of the ear is often positioned posteriorly from the normal earlobe position, and the earlobe created by the simple switch of the remnant ear at the first stage of the operation therefore does not always acquire the appropriate position and shape. Therefore, the earlobe is carefully treated using Z-plasty or a local flap to transpose the base of the earlobe and arrange its shape.

#### *Procedure for the Contralateral Ear*

Symmetry of the temporoauricular angle is very important, and a simultaneous procedure in this

stage is recommended for cases in which the contralateral ear has a high elevation angle such as that of a protruding ear. In such cases, the postauricular skin removed as a consequence for this procedure can be used as a skin graft for the microtia side. In addition, we should take into account that the remaining banked cartilage can also be used to treat any deformities of the contralateral ear.

#### *Dressing*

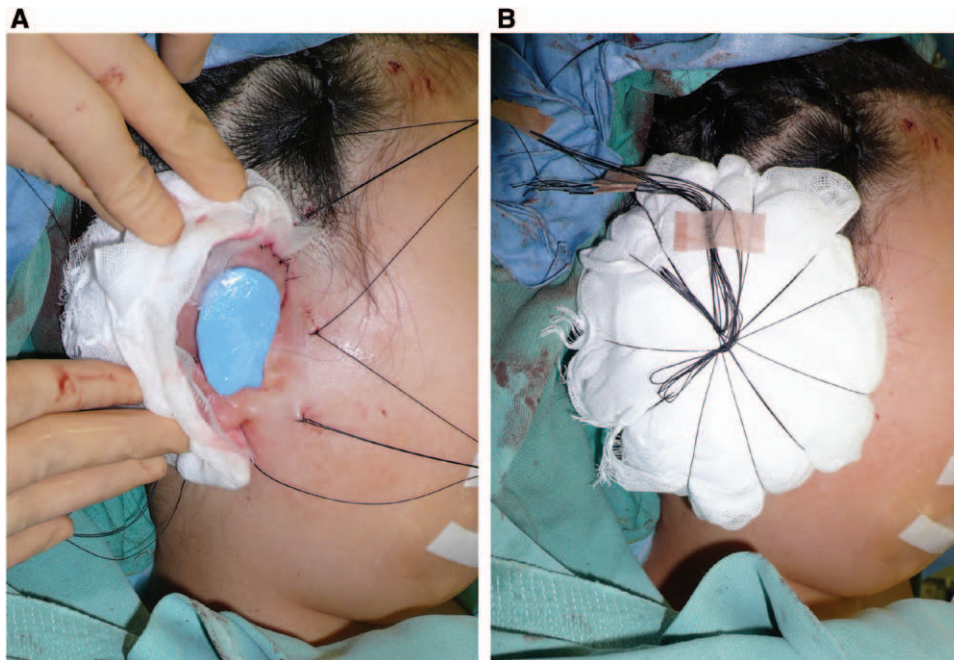
Eight pieces of long surgical sutures are placed in the skin at regular intervals around the auricle. After applying petrolatum gauze on the grafted skin and inserting absorbent gauze for the postauricular sulcus, a splint that was made from a dental impression material (Exafine, GC, Tokyo, Japan) preoperatively is applied to the anterior surface of the ear, and the entire ear is packed with additional absorbent gauze (Fig. 5A). Then, the sutures are fastened by the tie-over technique.<sup>3</sup> This procedure is useful not only for assurance of survival of the skin graft by equal pressure for the ear but also for preventing edema (Fig. 5B). They are removed within 7 days after the operation.

#### *Postoperative Care*

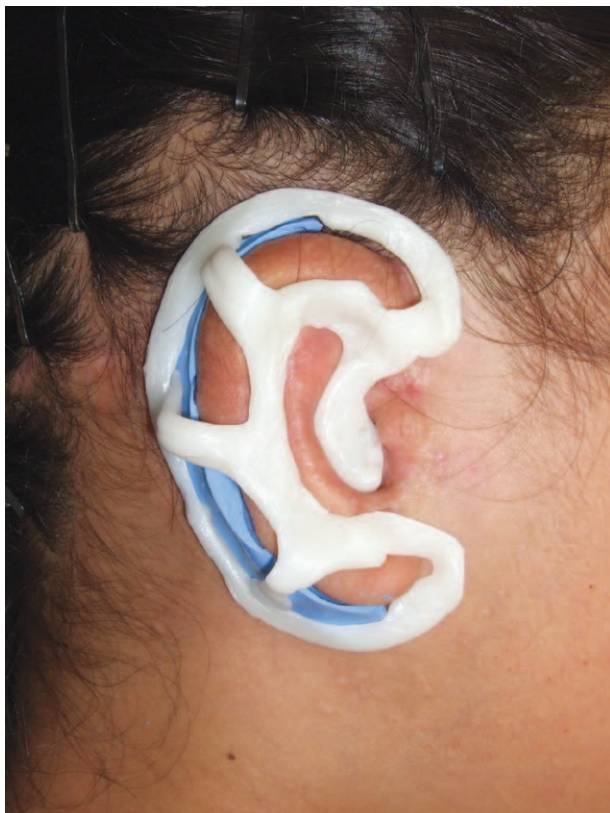From 2 weeks after the operation, 2 new types of splints are put together and applied. One splint is made from a dental impression material, which is molded for the shape of the temporoauricular sulcus, and the other is made from a thermoplastic material (Free Plastic, Daicel FineChem, Tokyo, Japan), which covers the entire ear including the former splint (Fig. 6). These splints are used for 3 months at nighttime. They are useful for preventing deformation of the ear due to compression while sleeping and for reduction of the temporoauricular sulcus due to contracture of the grafted skin. In addition, it is recommended to apply steroid-impregnated tape on the grafted skin for the periods in which the splints are used. This is because Asian people have a higher probability of developing keloids or having remarkable scar contracture than whites.

## RESULTS

We evaluated 137 ears in 121 patients with lobule-type microtia corrected by our technique who were followed up for at least 3 years. The results for all patients are the same as those reported for the first stage of the operation. The mean operation time was 3.3 hours, with a maximum time of 4.1 hours. The contralateral ear was treated simultaneously in 12 patients. There were 5 cases of prominent ear, 4 cases of minor helical deformity, and 3 cases of earlobe deformity. The prominent ears were treated by



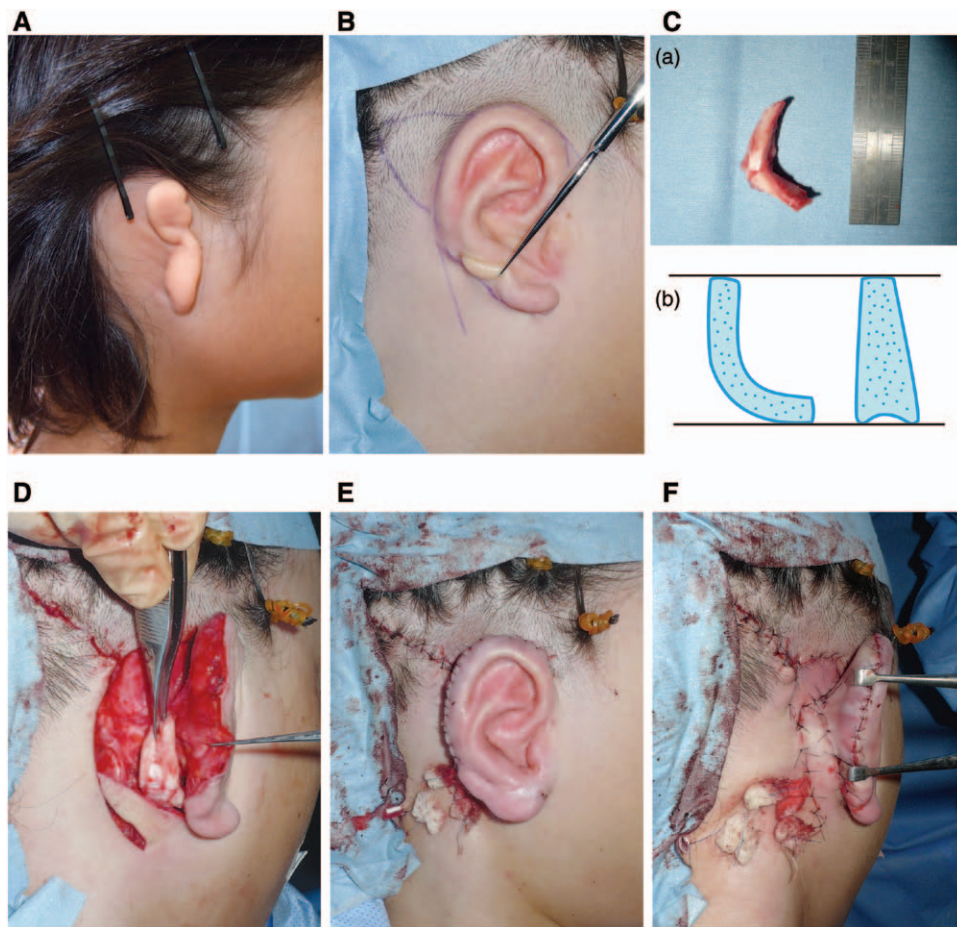
**Fig. 5.** Our dressing technique. A, After 8 pieces of surgical sutures have been placed around the auricle, the splint is placed anteriorly and absorbent gauze is inserted posteriorly for the ear. The splint prevents postoperative edema. B, The ear is packed with additional absorbent gauze, and the sutures are fastened with tie-over dressing.



**Fig. 6.** Splints are applied for 3 months postoperatively. The appearance when 2 types of splints are attached together.

removal of postauricular skin and antihelical plasty. The skin that was removed was used for coverage of the postauricular defect on the microtia side for all these patients. Two of the patients with minor helical deformity were treated with helical cartilage plasty alone, and the other 2 patients were treated by helical cartilage plasty with banking costal cartilage. Two patients with earlobe cleft were treated by Z-plasty, and 1 patient with different earlobe sizes underwent partial removal of the earlobe. For 7 patients who had hair in some part of the helical skin, we removed the hair follicles during the operation. Marginal skin necrosis occurred in 2 of the patients, but the underlying temporoparietal fascia prevented exposure of the cartilage and the wound healed with conservative treatment.

During the follow-up periods of more than 3 years, temporoauricular sulcus became shallow in 8 patients. Among them, 5 patients had a narrow elevated angle due to scar contracture of the grafted skin, and 3 patients were treated with another operation using an additional skin graft within 5 years after the second-stage operation. Six patients had keloids in the margin of the grafted skin, especially on the caudal side. The keloids healed naturally within 3 years in 4 patients, but they did not heal in 2 patients and these patients are still being treated with intral-



**Fig. 7.** Case 1. Eleven-year-old boy with right lobule-type microtia. A, Preoperative appearance before the first-stage operation. B, Design of skin incision at the second-stage operation. C, Banked cartilage is tailored to an L-shape (a). Scheme of the grafting cartilage (b). It has an L-shape and becomes thick toward the caudal side. D, The cartilage block is grafted. E, The appearance at the end of the operation. Skin-grafted area could be completely hidden behind the ear. F, The ear has a deep temporoauricular sulcus.

esional steroid injections. There were 4 patients with hemifacial hypertrophy who had asymmetry in ear position. No patient had severe damage causing deformity in the constructed ear from sports activities or trauma (Table 1).

**Report of Cases**

*Case 1*

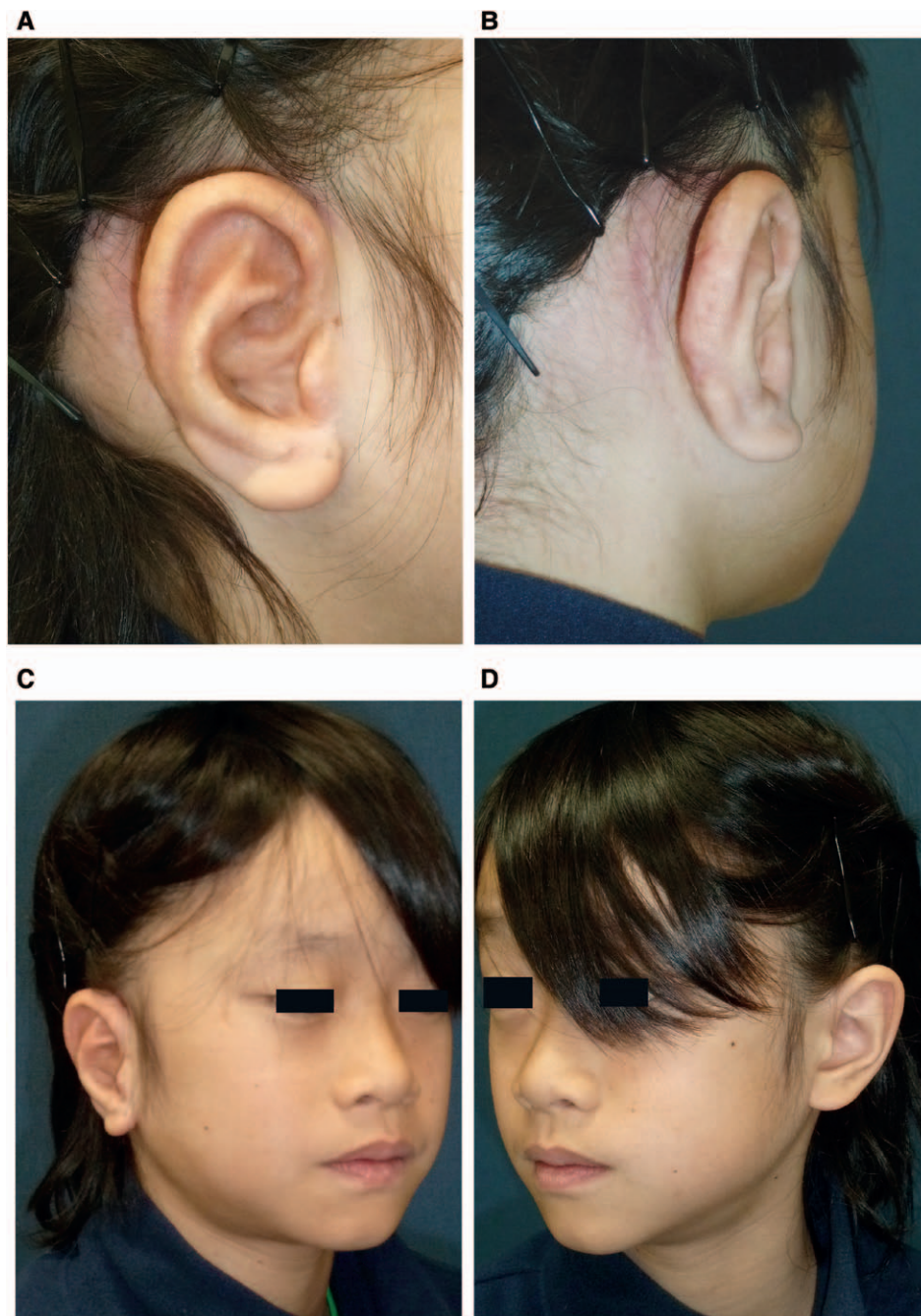
Case 1 was an 11-year-old boy with right lobule-type microtia (Figs. 7 and 8). Six months after the first-stage operation, we performed the second stage of ear elevation. The scalp and neck skin could be easily advanced near the grafted cartilage by removal of the V-shaped skin and subcutaneous undermining. Grafted cartilage was 12mm in height. There was no complication such as congestion or loss of grafted skin. A clearly refined 3-dimensional shape of the constructed ear and symmetrical appearance in terms of size, shape, position, and elevation angle were obtained in a 4-year follow-up period.

*Case 2*

Case 2 was an 11-year-old boy with left lobule-type microtia (Fig. 9). Six months after the first-stage operation, we performed the second stage of ear elevation. Because an area of a few millimeters in width in the outer margin of the helix included hair follicles, they were removed and the cartilage

**Table 1. Evaluation from Doctors During Follow-up for More Than 3 Years**

	No. Patients
Shallow temporoauricular sulcus	8
Narrow angle due to contracture	5
Other	3
Keloid formation in postauricular region	6
Conspicuous alopecia in the scalp	6
Asymmetry of the earlobe	4
Asymmetry in ear position	4
Asymmetry in ear size	2
Total	30/121 patients



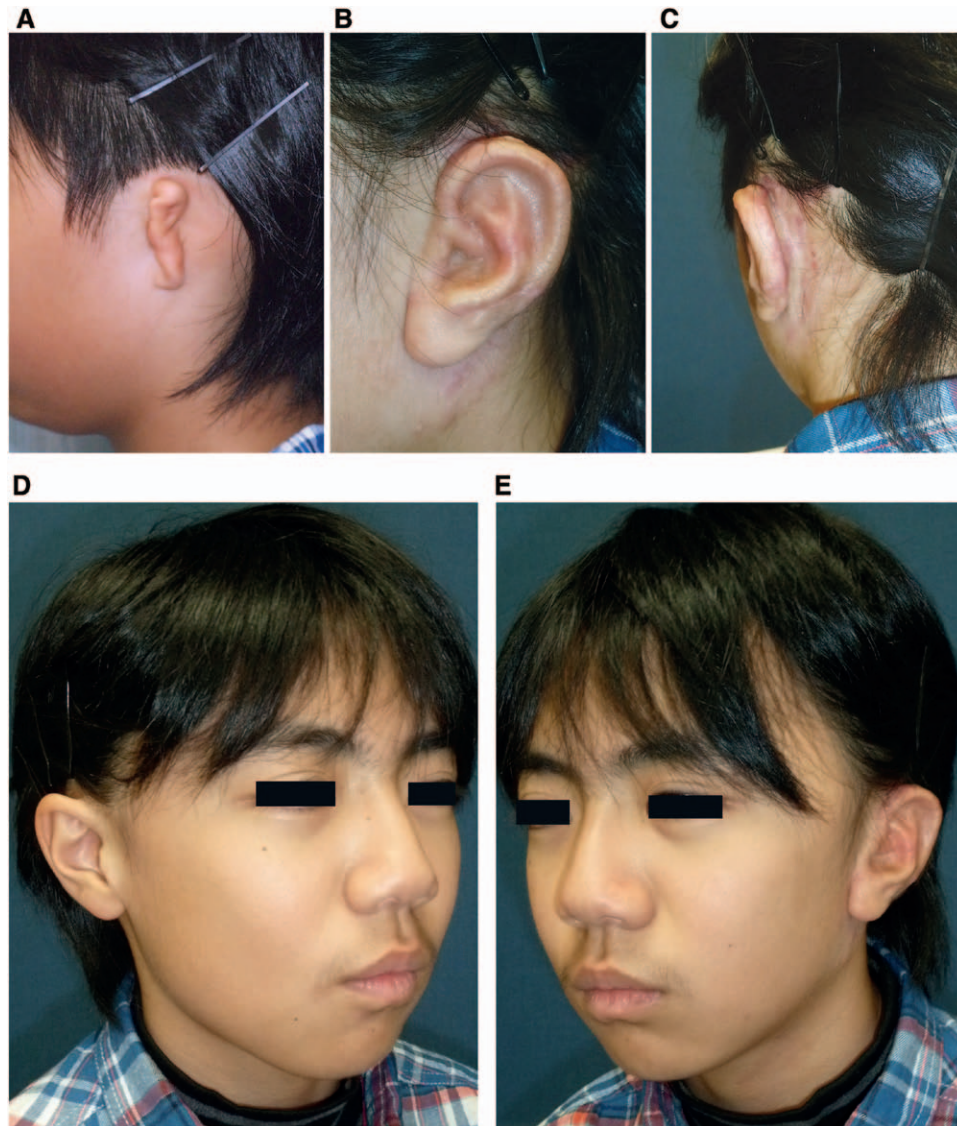**Fig. 8.** Case 1. Postoperative appearances 4 years after the operation. A, Well-contoured shape with deep concha was maintained. B, Scar was inconspicuous on the posterior side. C and D, Symmetrical balance of the ear was observed.

of this area was covered by surrounding temporoparietal fascia by wide elevation (Fig. 3). As the ear was located slightly lower than the contralateral ear, the ear was moved cranially. The resulting dog ear was resolved by an additional skin incision in the caudal triangular flap. The grafted cartilage was 11 mm in height. There was no complication, and a clearly refined 3-dimensional shape of the constructed ear and symmetrical appearance in terms of size, shape,

position, and elevation angle were obtained in a 3-year follow-up period.

### DISCUSSION

Many techniques for the second stage of ear elevation have been reported, the representative technique being that reported by Tanzer<sup>5</sup> or Brent,<sup>6</sup> but most of those techniques were performed only for acquiring the temporoauricular sulcus. Thereafter,



**Fig. 9.** Case 2. Eleven-year-old boy with left lobule-type microtia. A, Preoperative appearance before the first-stage operation. B, Postoperative appearances 3 years after the operation. Well-contoured shape with a deep concha was maintained. C, Scar was inconspicuous. D and E, Symmetrical appearance of the ear was observed.

the developed concept such as the costal cartilage grafting on the posterior surface of the ear had been reported.<sup>1,7</sup> Consequently, the ear could acquire a 3-dimensional structure.

Regarding techniques for covering the posterior surface of the ear including the grafted cartilage, Nagata<sup>1</sup> used the temporoparietal fascia and grafted split-thickness skin harvested from the scalp, and variations of this technique have also been reported.<sup>8</sup> The temporoparietal fascia could completely cover the grafted cartilage, and the use of scalp skin made it possible to make the donor site scar inconspicuous. Furthermore, Nagata<sup>1</sup> reported that advantages of his technique were that sufficient blood supply of the temporoparietal fascia may prevent absorption

of the grafted cartilage and that the combination of temporoparietal fascia and a split-thickness skin graft is effective for reducing scar contracture.<sup>4</sup>

On the contrary, some disadvantages of Nagata's technique have been reported.<sup>9</sup> Shaving a large area of scalp hair is unacceptable for many patients, and some of them even refuse the operation. For harvesting the temporoparietal fascia, it is inevitable to have a linear cicatrizing alopecia along the long incision line or disseminative alopecia on the undermined area. As another possible complication, the undermined area might lose its consciousness permanently. Although we could not find any articles that referred to the prevention of scar contracture by the combination of TPF and a split-thickness skin



graft, we had experienced contracture in some cases of various reconstruction.

Many factors are thought to be involved in the cartilage absorption, including the degree of maturation of the cartilage, protection by the perichondrium, healing process, tension of the skin, and blood supply. Such factors of the cartilage itself and of the surrounding environment are thought to be complexly involved in the absorption. Among those factors, we consider the degree of maturation of the cartilage and protection by the perichondrium to be the most significant clinical factors for cartilage absorption, as we mentioned in Part 1.<sup>3</sup> In addition, the most important parts for maintaining a clear contour of the ears are the helix and antihelix, the blood supply of which predominantly depends on the anterior skin of the ear. We could not evaluate the effect of TPF on blood supply of the anterior skin of the ear. TPF is covering the major area of the posterior ear even in our technique of ear elevation, it is only to ensure the survival of the grafted skin. Thus, we feel that the use of TPF in Nagata's technique is not indispensable but provides an excessive surgical morbidity for patients.

In our technique, the caudal skin flap can cover the cartilage block even with a thickness of 1.4 cm. However, if there is a case in which the cartilage block cannot be fully covered by the skin flap, we recommend the use of a combination of mastoid fascia and skin flap. Because we undermined the temporal skin in our technique, elevation of the mastoid fascia flap was very easy. Although it has been reported that a mastoid fascia is simply turned over and skin grafting is applied on it,<sup>9-11</sup> we think that the combination of a local skin flap is important. Two skin flaps can divide the grafted skin between the temporal and postauricular areas. This is useful for reducing scar contracture and maintaining deep temporoauricular sulcus, as the same reason that placing a skin flap is effective to create interdigital space for syndactyly.

It has been reported that cartilage was rigidly immobilized using artificial materials such as hydroxyapatite-tricalcium phosphate ceramic, an absorbable plate composed of polylactic and polyglycolic acid, or bone cement, without using autologous cartilage, to maintain the elevation angle of the ear.<sup>12-14</sup> However, we think that rigid fixation is not favorable because the mobility of the ear is important to parry external forces and prevent injury.

The main postoperative complications for microtia in Asians are pigmentation and scar contracture of the grafted skin and keloid formation of the margin at the grafted skin. We think that our technique, which reduces the size of the area of

the grafted skin in the temporal region and hides it behind the ear, is a proper treatment. Although there have been some reports of a local flap for coverage of posteriorly grafted cartilage being elevated from the neck, the donor site of the flap is very conspicuous if it becomes hypertrophic.<sup>12,15,16</sup> The use of a full-thickness skin graft harvested from the abdomen for posterior coverage of the ear is more effective for preventing contracture than is a split-thickness skin graft. Postoperative management is another important factor for maintenance of ear shape, temporoauricular sulcus, and elevation angle of the ear.

We have introduced our typical technique of ear elevation for lobule-type microtia. Our technique makes it possible to acquire an excellent and symmetrical shape of the ear with minimal invasion for patients.

### PATIENT CONSENT

*Parents or guardians provided written consent for the use of the patients' image.*

**Takatoshi Yotsuyanagi, MD, PhD**

Department of Plastic and  
Reconstructive Surgery, Sapporo  
Medical University school of Medicine  
S1W16, Chuo-ku, Sapporo  
Hokkaido 060-8543, Japan.  
E-mail: yotsuyanagi@sapmed.ac.jp

### REFERENCES

1. Nagata S. A new method of total reconstruction of the auricle for microtia. *Plast Reconstr Surg.* 1993;92:187-201.
2. Nagata S. Modification of the stages in total reconstruction of the auricle: Part IV. Ear elevation for the constructed auricle. *Plast Reconstr Surg.* 1994;93:254-266; discussion 267.
3. Yotsuyanagi T, Yamashita K, Yamauchi M, et al. Correction of lobule type microtia: I. The first stage of costal cartilage grafting. *Plast Reconstr Surg.* 2014;133:111-120.
4. Nagata S. Secondary reconstruction for unfavorable microtia results utilizing temporoparietal and innominate fascia flaps. *Plast Reconstr Surg.* 1994;94:254-265; discussion 266.
5. Tanzer RC. Total reconstruction of the auricle. The evolution of a plan of treatment. *Plast Reconstr Surg.* 1971;47:523-533.
6. Brent B. Auricular repair with autogenous rib cartilage grafts: two decades of experience with 600 cases. *Plast Reconstr Surg.* 1992;90:355-374; discussion 375.
7. Fukuda O. The microtic ear: survey of 180 cases in 180 cases in 10 years. *Plast Reconstr Surg.* 1974;53:458-463.
8. Chen ZC, Goh RC, Chen PK, et al. A new method for the second-stage auricular projection of the Nagata method: ultra-delicate split-thickness skin graft in continuity with full-thickness skin. *Plast Reconstr Surg.* 2009;124:1477-1485.
9. Ou LF, Yan RS, Tang YW. Firm elevation of the auricle in reconstruction of microtia with a retroauricular fascial

- flap wrapping an autogenous cartilage wedge. *Br J Plast Surg.* 2001;54:573–580.
10. Park C. Modification of two-flap method and framework construction for reconstruction of atypical congenital auricular deformities. *Plast Reconstr Surg.* 1997;99:1846–1857.
  11. Yoshimura K, Asato H, Nakatsuka T, et al. Elevation of a constructed auricle using the anteriorly based mastoid fascial flap. *Br J Plast Surg.* 1999;52:530–533.
  12. Tai Y, Tanaka S, Fukushima J, et al. Refinements in the elevation of reconstructed auricles in microtia. *Plast Reconstr Surg.* 2006;117:2414–2423.
  13. Lim SY, Mun GH, Hyon WS, et al. The elevation of the constructed auricle with a temporoparietal fascial flap wrapping a resorbable plate. *J Plast Reconstr Aesthet Surg.* 2006;59:505–509.
  14. Zhang Q, Zhang R, Xu F, et al. Firm elevation of the reconstructed auricle with a retroauricular fascial flap wrapping an EH (a mixture of epoxide acrylate maleic and hydroxyapatite) composite wedge. *J Plast Reconstr Aesthet Surg.* 2010;63:1452–1458.
  15. Isshiki N, Koyama H, Suzuki S, et al. Surgical techniques for a deep concha, a pseudomeatus, and high projection in congenital microtia. *Plast Reconstr Surg.* 1986;77:546–557.
  16. Cho BC, Kim JY, Byun JS. Two-stage reconstruction of the auricle in congenital microtia using autogenous costal cartilage. *J Plast Reconstr Aesthet Surg.* 2007;60:998–1006.