

Research Article

Aldo Rocca*, Enrico Andolfi, Anna Ginevra Immacolata Zamboli, Giuseppe Surfaro, Domenico Tafuri, Gianluca Costa, Barbara Frezza, Marta Scricciolo, Maurizio Amato, Paolo Bianco, Sergio Brongo, Graziano Ceccarelli, Antonio Giuliani, Bruno Amato

Management of complications of first instance of hepatic trauma in a liver surgery unit: Portal vein ligation as a conservative therapeutic strategy

<https://doi.org/10.1515/med-2019-0038>

received November 5, 2018; accepted March 15, 2019

Abstract: Background. According to the National Trauma Data Bank, the liver, after the spleen, is the first most injured organ in closed abdominal trauma.

Methods. From June 2010 to December 2015 we observed in our department of Hepato-biliary Surgery and Liver Transplant Unit of the A.O.R.N. A. Cardarelli of Naples 40

***Corresponding author: Aldo Rocca**, Department of Translational Medical Sciences, University of Naples “Federico II”, Naples, Italy. Via Sergio Pansini, 80131 Naples, Italy e-mail: aldorocca88@gmail.com
General Surgery Unit, Clinica Padre Pio, Mondragone (CE), Italy
Department of Abdominal Oncology, Fondazione Giovanni Pascale, IRCCS, Naples, Italy

Centre of Hepatobiliarypancreatic surgery, Pineta Grande Hospital, Castelvoturno (CE), Italy

Giuseppe Surfaro, General Surgery Unit, Ospedale del Mare, Naples, Italy

Domenico Tafuri, Department of Sport Sciences and Wellness, University of Naples “Parthenope”, Naples, Italy

Antonio Giuliani, Department of Transplantation, Unit of Hepatobiliary Surgery and Liver Transplant Center, ‘A. Cardarelli’ Hospital, Naples, Italy

Paolo Bianco, Centre of Hepatobiliarypancreatic surgery, Pineta Grande Hospital, Castelvoturno (CE), Italy

Enrico Andolfi, Barbara Frezza, Marta Scricciolo, Graziano Ceccarelli, Department of Surgery, Division of general Surgery, San Donato Hospital, via Pietro Nenni 20-22, 52100 Arezzo, Italy

Gianluca Costa, Surgical and Medical Department of Translational Medicine, Sapienza University of Rome, Sant’Andrea Hospital, Via di Grottarossa 1035-39, 00189 Rome, Italy

Anna Ginevra Immacolata Zamboli, General Surgery Unit, De Luca E Rossano Hospital, Vico Equense (NA), Italy

Bruno Amato, Maurizio Amato, Department of Clinical Medicine and Surgery, University Federico II of Naples. Naples, Italy.

Sergio Brongo, Plastic Surgery Unit, Department of Medicine, Surgery and Dentistry “Scuola Medica Salernitana”, San Giovanni di Dio e Ruggi D’Aragona University Hospital, University of Salerno, Salerno, Italy

patients affected by hepatic trauma. In our retrospective study, we review our experience and propose portal vein ligation (PVL) as a first – line strategy for damage control surgery (DCS) in liver trauma.

Results. 26/40 patients (65%) which received gauze-packing represented our study group. In 10 cases out of 26 patients (38,4%) the abdominal packing was enough to control the damage. In 7 cases (18,4%) we performed a liver resection. In 7 cases, after de-packing, we adopted PVL to achieve DCS. Trans Arterial Embolization was chosen in 6 patients. 2 of them were discharged 14 days later without performing any other procedure.

In 3 cases we had to perform a right epatectomy in second instance. Two hepatectomies were due to hemoperitoneum, and the other for coleperitoneum. Two patients were treated in first instance by only doing hemostasis on the bleeding site. We observed 6 patients in first instance. Five of them underwent surgery with hepatic resection and surgical hemostasis of the bleeding site. The other one underwent to conservative management. In summary we performed 15 hepatic resections, 8 of them were right hepatectomies, 1 left hepatectomy, 2 trisegmentectomies V-VI-VII. So in second instance we operated on 10 patients out of 34 (30%).

Conclusions. The improved knowledge of clinical pathophysiology and the improvement of diagnostic and instrumental techniques had a great impact on the prognosis of liver trauma. We think that a rigid diagnostic protocol should be applied as this allows timely pathological finding, and consists of three successive but perfectly integrated steps: 1) patient reception, in close collaboration with the resuscitator; 2) accurate but quick diagnostic framing 3) therapeutic decisional making. Selective portal vein ligation is a well-tolerated and safe manoeuvre, which could be effective, even if not definitive, in treating these

subjects. That is why we believe that it can be a choice to keep in mind especially in post-depacking bleeding.

Keywords: Portal vein ligation; Hepatic Trauma; Therapeutic choice; Liver surgery unit; Management of complications

1 Background

According to the National Trauma Data Bank, the liver, after the spleen, is the second most injured organ in closed abdominal trauma (78%), and one of the most injured organs like spleen, eye and others in penetrating wound [1-3].

Liver trauma is classified following the “Liver Injury Scale” edited by the American Association for the Surgery of Trauma (AAST) (Table 1) where the severity of the trauma is described in six progressive steps, where each

one is linked to the depth of the wound, the volume of the hematoma and the vascular hilum involvement [4].

Mortality rate is congruent with the severity of liver injury and could be 100% in V-VI degree. 20% of patients with a liver trauma need to go to the operating theatre in emergency for a life-saving operation.

Hepatic trauma is often accompanied by a significant physiological imbalance linked to a severe haemorrhagic shock that can cause the death of the patient despite repair of the damage [5-7].

The “damage control surgery” (DCS) was developed as a method to control the lesions. There are three key points of the DCS:

1. Short time surgery only to control bleedings and sepsis
2. Correction of metabolic imbalance, temperature, coagulation and hemodynamic in an intensive care unit (ICU)

Table 1: AAST – HEPATIC INJURY SCALE

Classification of liver trauma following the American Association for the Surgery of Trauma (AAST) and the Organ Injury Scale Committee (1989) (1994)

Grade*	Type of Injury	Description of injury	ICD-9	AIS-90
I	Hematoma	Subcapsular, <10% surface area	864.01 864.11	2
	Laceration	Capsular tear, <1cm parenchymal depth	864.02	
			864.12	
II	Hematoma	Subcapsular, 10% to 50% surface area intraparenchymal <10 cm in diameter	864.01 864.11	2
	Laceration	Capsular tear 1-3 parenchymal depth, <10 cm in length	864.03 864.13	
III	Hematoma	Subcapsular, >50% surface area of ruptured subcapsular or parenchymal hematoma; intraparenchymal hematoma > 10 cm or expanding		3
	Laceration	>3 cm parenchymal depth	864.04 864.14	
IV	Laceration	Parenchymal disruption involving 25% to 75% hepatic lobe or 1-3 Couinaud's segments	864.04 864.14	4
V	Laceration	Parenchymal disruption involving >75% of hepatic lobe or >3 Couinaud's segments within a single lobe		5
	Vascular	Juxtahepatic venous injuries; ie, retrohepatic vena cava/central major hepatic veins		
VI	Vascular	Hepatic avulsion		

3. Second-look to perform a definitive treatment of lesions

The principles of DCS are useful to treat other hepatic benign and malignant diseases [8-11] as well as other abdominal emergencies.

In our region, the first approach to liver trauma is held by the General and Emergency Surgery Unit team. Also patients who are in critical condition as result of long time hospitalization, infective diseases or bleedings not well managed during the first approach, are referred to our Unit of Hepato-biliary Surgery with a dedicated Intensive Liver Care Unit (ILCU) for a more professional care of the trauma.

Treatment of hepatic trauma should have different approaches since the best approach might depends on several factors like: medical (surgeon and anaesthesiologist) and team experience, technological resources, availability of an interventional radiologist [12,13].

We can resume the wide spectrum of complications of the first care approach in five physiopathological findings: acute re-bleeding after packing, liver hematoma, venous -arterial fistula, sepsis, biliary fistula/coleperitoneum. In a second step management we have in front of us a patient who is stressed, often hemodynamically unstable and weakened by previous treatments.

Our aim is to summarize the current strategies to manage a blunt liver trauma, and we also propose the portal vein ligation (PVL) as a possible conservative strategy.

2 Methods

This retrospective study is based on data of our personal experience. We collected data from June 2010 to December 2015. In that period we observed at our department of Hepato-biliary Surgery and Liver Transplant Unit of the A.O.R.N. A. Cardarelli of Naples 40 patients affected by hepatic trauma (Fig1-2). Each patient underwent a strict diagnostic and operative protocol described in results.

Clinical and pathologic characteristics, postoperative outcomes, hospital course, and postoperative morbidity and mortality are described. Demographic data, surgical procedures, postoperative course, and outpatient follow-up were reviewed. Complications were classified according to the Clavien-Dindo classification [14].

Ethics approval and consent to participate: All of the procedures in studies involving human participants were

performed in accordance with the ethical standards of the institution and were in accordance with the 1964 declaration of Helsinki and its later amendments or comparable ethical standards. Informed consent for the surgical procedures was obtained before treatment from each of the participants who were included in the study.

Consent for publication: Verbal consent was provided by each of the participants enrolled in our study.

3 Results

3.1 Our protocol

After hospitalization, the patient was subjected to a rigid diagnostic and therapeutic protocol, which provides:

- Accurate history, complete clinical examination, hospitalization in intensive care liver unit (ICLU)
- Complete blood exams, with particular attention to the coagulation pattern (PT, aPTT, fibrinogen, AT III, Rotem)
- Microbiology, swabs and echocardiographic drawings of pleural and peritoneal spills or collections for the determination of septic states
- Total TC scan/ Angio Colangio RMN to determine parenchymal and biliary lesions
- Vascular radiology to perform an embolization treatment or the positioning of a pig-tail drainage
- Observation in a protected and dedicated ICLU environment
- Programme de-packing or resective surgery

Compared to the first approach of the traumatized patient, it is very important the research of germs that may be the cause of sepsis and the possible turbulence of the coagulation. Secondly, MRI is used identify biliary lesions, which we can often find in such patients. In any case, we always pay attention to the possible presence of any associated injuries, especially of orthopaedic interest unknown in the first instance.

3.2 Portal vein ligation as strategy for DCS

Portal vein ligation is a quite easy manoeuvre to manage a liver bleeding also in non-referral centres for HPB-surgery. Portal vein ligation may offer several advantages in the management of a liver trauma when it is difficult to control bleeding with standard techniques and it might be dangerous to perform a first instance resection. PVL is

safer than selective arterial ligation from the point of view of biliary fistula, biliary necrosis and parenchymal necrosis risk. PVL has a double advantage: providing hemostasis, and preparing the liver for a staged extended hepatectomy. If the patient shows huge damage of the lobe or if the surgeon is not skilled in HPB surgery we suggest an extra-hepatic ligation of the right or left portal vein. In specialized centers, if possible, a selective ligation of the segmental portal branch should be performed.

3.3 Patient distribution

The male female ratio was 2,25:1, with a mean age of 34 years (range 12-94). 37 patients had a closed abdominal trauma; only three patients had a penetrating wound.

In 26 cases, patients underwent liver gauze packing in first instance, 3 of them underwent trans-arterial embolization after gauze packing.

In 14 cases we chose a non-operative management: 6 patients underwent trans-arterial embolization (TAE), 2 patients underwent drainage placement, 6 patients with minor stable lesions were only observed for 10-14 days.

3.4 Gauze-packing

In 26 patients representing the study group, gauze-packing was performed. 3 of them underwent TAE after the depacking to control the bleeding.

In 10 cases of 26 patients (38,4%) the abdominal packing was enough to control the damage, so we did not perform any other procedure after de-packing.

The de-packing was performed on the 2nd or 3rd post-operative day, depending on patients' conditions, and other surgical emergency activities of the department. After depacking patients were observed for 10-16 days. The first post-operative days were spent in ICLU, blood tests were performed every day for five days then in PO on days 7, 10 and the day before discharge, if the recovery did not show any complication. A CT scan with mdc was made on days 2 and 8 to control bleeding and eventual other organ injury which might be missed during the first days. An abdominal ultrasound was always performed the day before discharge.

In 7 cases of 26 treated with gauze-packing (18,4%) we performed a liver resection. 3 of them needed a right epatectomy, and 4 patients only needed segmentectomies. Right hepatic resections were associated in one case to a plastic repair of oesophageal hiatus hernia and in an other case to a right surrenalectomy.

3.5 PVL

In 7 cases, after de-packing, we propose as a novel technique to apply the DCS with a portal vein ligation. Six of these patients had a right liver trauma; only one of them had a left one.

In the left liver trauma and in four right liver traumas an extra-hepatic ligation of the left or right portal branch was performed. All patients who underwent right PVL had lesions in right posterior segments. In the other two cases there was a tear injury of the VI segment, treated with a selective PVL for segment six.

This technique was sufficient in 3 (43%) cases to stop the bleeding: in the left liver trauma, in one of the VI segment traumas and in one case affected by posterior liver injury.

In the other 3 cases we needed to perform a hepatic resection at the same time: two right hepatic resections and a resection of segment VI. All resections were very well tolerated. Only in one case for a huge lesion of right liver we performed a vein ligation combined with the ligation of the artery to stop the bleeding. As a result we had to perform a necrosectomy of segment VI-VII, preserving the V-VIII segments. Also in this case the resection was well tolerated, the patient spent 5 days in ICU, with a transient elevation of ALT and AST, but after 20 days performance status and blood test were good and the patient was discharged. After PVL no mortality was observed, only one patient who underwent right hepatectomy had a IV degree Clavien Dindo complication and required a revision of hemostasis after resection.

We performed with success the portal vein ligation also in one case of broken HCC post radio frequency ablation without complications.

3.6 Trans-arterial embolization

Trans Arterial Embolization was chosen in 6 patients.

2 of them were discharged 14 days later without performing any other procedure. The postoperative care protocol was the same as described above for patients who underwent de-packing.

In 3 cases we had to perform a right epatectomy in the second instance. Two epatectomies were due to hemoperitoneum, the other for coleperitoneum. One of these patients underwent TAE in first instance due to elderly age, and we had to perform a right hepatectomy to control the bleeding, but he died 45 days after intervention due to liver imbalance and MOFS.

The last patient undergoing to TAE, who was gun wounded, had an hepatic minor resection to solve the pleural-bilious fistula due to the gunshot.

3.7 Patient treated in first instance

We observed 6 patients in first instance. Five of them underwent surgery with hepatic resection and surgical hemostasis of the bleeding site. The other one underwent conservative management.

In one case, in second instance, we made a right hepatic resection, in the other case a huge vascular damage was made doing hemostasis, so we performed a reconstruction of the vein with a vascular venous graft. The venous graft was strictly observed by color Doppler ultrasound and CT scan to evaluate bleeding, patency and blood flow in the graft. The patient was discharged on 60th PO day.

In our hospital there is an Emergency Dept. which usually perform the first packing, so we see in first instance only the worst cases AAST >4. Two of them died due to the huge liver injury at 30 and 50 days after intervention, for liver imbalance and non-controllable bleeding with coagulation impairment.

3.8 Summary of our resections

2 of right hepatectomies were first treated with arterial embolization, in one case for hemoperitoneum, in the other case coleperitoneum.

Minor liver resections were 4, 2 bisegmentectomies VI-VII, and 1 segmentectomy of segment VI and another of segment VII.

In summary we performed 15 hepatic resections, 8 of them were right hepatectomies, 1 left hepatectomy, 2 trisegmentectomies V-VI-VII. So in the second instance we operated on 10 patients out of 34 (30%).

The hospital mean stay was 25 days (range from 10 to 60).

The Clavien Dindo complication rate was under grade III in 74 % of cases. Only six patients underwent surgery again with a Clavien-Dindo III-IV for 16% of patients [8]. Clavien-Dindo V with exitus was observed in 10% (4) of the patients. 75% of cases were over 65 years old. Exitus was associated with IV-V degree of the AAST scale in 75% of cases, only one case was AAST III.

4 Discussion

In the last 30 years blunt liver trauma managing has completely changed. Once almost all cases of liver trauma were addressed by surgery, while today surgical indication is selective and follows the rules of DCS.

Choosing a non operative management of liver trauma, some statements, as told by Mayer in 1985 [15] are mandatory:

- 1 – hemodynamic stability (no fever, control of blood pressure, response to filling fluid therapy, diuresis 0.5ml/kg/h)
- 2 – absence of peritonism
- 3 – good quality of CT images, presence of an expert radiologist
- 4 – possibility of patient management in an intensive care unit
- 5 – ready availability of an urgent laparotomy
- 6 – simple parenchymal tear or an intrahepatic hematoma with less than 125 ml of free blood in peritoneum
- 7– the absence of other significant abdominal lesions.

Subsequently Feliciano suggested that any hepatic trauma, regardless of its size, should be treated conservatively if the patient is hemodynamically stable and has a hemoperitoneum quantified in less than 500 ml [16]. However, it is currently believed that the most important decision-making factor in favor of treatment against observation alone should be the patient's haemodynamic stability at the presentation or in any case obtained by the minimal infusion of liquids, without considering the extent of the damage demonstrated by the CT scan or entity of the hemoperitoneum. All these characteristics are summarized in Tab 2, Fig 1. If these criteria are applied

Table 2: Most important decision-making factor in favor of treatment against observation

1.	Hemodynamic stability (Response to fluid therapy)
2.	No signs of peritonism
3.	Neurological integrity
4.	Quantification of the damage by CT scan (Grade I to III)
5.	No association of other intra-abdominal lesions
6.	Transfusion of <4 red blood cells units in 24 h
7.	Contrast spreading at TC scan → angiography with arterial embolization

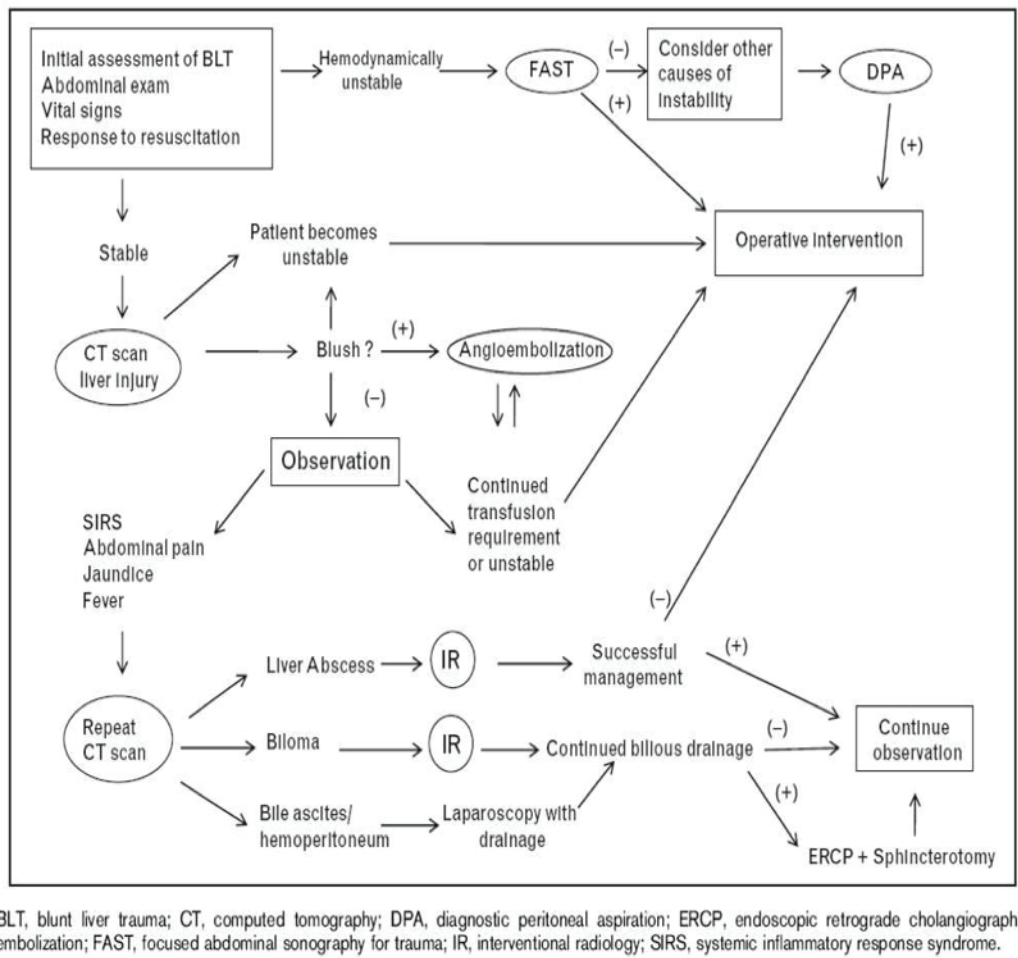


Figure 1: Algorithm for non operative management in blunt liver trauma

correctly, 50-80% of patients with closed hepatic trauma could be managed in a non-operative way, with success rates of over 95%. Angiography can increase these percentages by being able to treat by embolization those lesions with persistent bleeding from a deep laceration or inside an expanding intrahepatic hematoma. The potential negative results of a conservative choice derive mainly from the difference between the CT scan and the intraoperative finding, since CT scan can not identify other intra-abdominal lesions. Moreover there is the transfusion related risk, the possible persistent bleeding, hemobilia, biliary fistula and subsequent sepsis. The risk of any other unrecognized abdominal injuries can be reduced by the use of diagnostic peritoneal lavage (DPL) in doubtful cases, or, even better, diagnostic laparoscopy, thus increasing the accuracy of the CT scan.

For liver trauma it is necessary to pay attention to some aspects which emerged from our experience according to international literature [17-18].

Considering age, the young and adults are the most affected by traumas, and have also the best therapeutic performance. The male female ratio favours men, in particular for wound traumas. In our experience abdominal traumas are linked to road accidents, with the majority being closed traumas.

The right lobe is the most affected, and frequently is associated to lesions to other organs. The severe pathological presentation of patients at our Centre required more often a major hepatic resection. This confirms the importance of a Liver Unit in this kind of traumas. We observed 40 cases and performed 15 resections, 11 of them were major resections.

Hepatic resection was the treatment of choice in the case of coleperitoneum, and in the case of Hematoma after surgery or packing. Hepatic resection, in such defeated patients, in experienced hands, is the fastest way to give the patient a treatment which is definitive, and which can restore body balance without a second step of surgery.

Moreover, in case of huge right lobe injuries in small left liver, we performed 2 trisegmentectomies V-VI-VII to spare the VIII lobe to avoid a smaller liver for size.

In two cases of severe right lobe post-packing bruises, we made a right portal vein ligation. In one of this type of case we had to perform the arterial ligation as well for ceaseless bleeding, and after two weeks a necrosectomy (VI-VII) was necessary. This approach saved the patient's life according to DCS and spared a huge quantity of parenchyma.

This new procedure, which was learned from our experience in oncological liver surgery, is easy to perform, and it gave us unexpected good results both in terms of bleeding control and less necrosis and cytolysis associated with arterial ligation. Moreover, a PVL can prepare the liver for a staged major hepatectomy if necessary, especially in frail and defeated patients with a small liver remnant. In experienced hands, a selective PVL might be performed, to achieve both bleeding control and parenchymal sparing.

After performing a PVL, reasons that justify a liver resection are bleeding caused by vascular lesions, parenchyma collapse, parenchymal necrosis, and intraparenchymal biliary fistula. Liver resection can be performed immediately or after a period of intensive surveillance.

5 Limits of the study

This paper is only a report of the experience of a HPB Unit dedicated also to emergency in one of the referral centre for emergency of the Southern Italy. Due to the low number of cases it is not possible to perform a statistical analysis, and despite the surgical strategy being standardized the surgical team was often different; either for age or experience.

6 Conclusion

The improved knowledge of clinical physiopathology and the availability of better diagnostic and instrumental tools has had a great impact on the prognosis of liver trauma [19-23]. Different factors have resulted in an epochal shift towards non-operative treatment of liver trauma, and today 85-90% of closed liver trauma is successfully treated with conservative treatment [25-27]. These results are also derived from the use of laparoscopy in urgency, which might be a bridge between diagnosis and open treatment [21-23]. A variable rate between 5 and 10% of patients

needs a 2-step treatment. These are complex patients due to the associated physiopathologic imbalance related to a major trauma, and may not always need a surgical treatment as the first instance [15, 24, 25]. They must be thoroughly studied by imaging and at the same time require intensive treatment and long-acting surgical decision. For this reason, the ideal is to be entrusted to Surgical-Resurgent Complex Units dedicated to Hepato-Biliary patients [27-31]. We think that a rigid diagnostic protocol should be applied to allow a framing of pathological finding as soon as possible and consists of three successive but perfectly integrated moments that are 1) patient reception, in close collaboration with the resuscitator; 2) accurate but quick diagnostic workup 3) therapeutic decision - making.

In these cases, hepatic resection (segmental or greater) is a lifesaving procedure that can be carried out with an acceptable mortality and morbidity rate. However, we must bear in mind that these patients are frail and unstable, usually with associated coagulation disorders, who therefore cannot sustain a liver resection that is most often a major one. In selected cases the ligation of the portal vein afferents of the haemorrhagic segments could resolve or stabilize an hemodynamically unstable patient not suitable for arterial embolization. The selective portal vein ligation is a well-tolerated safe manoeuvre, which could be effective if not definitive in treating these subjects. That is why we believe that it can be a choice to keep in mind especially in post-depacking bleeding.

Availability of data and materials: The dataset supporting the conclusions of this article is included within the tables.

Funding: There are no funding sources to declare.

Author contribution: All authors designed the study and contributed to acquire data. All authors read and approved the final manuscript.

Competing interest: The authors declare no competing of interest in association with this manuscript.

References

- [1] Kozar R.A.: Western Trauma/Critical decision in Trauma: Operative Management of Adult Blunt Hepatic Trauma. *The journal of trauma Injury, Infection and Critical Care*-July 2011, Vol 71,n.1
- [2] Sánchez Bueno F: Cambios en el manejo diagnóstico-terapéutico del traumatismo hepático. *Estudio retrospectivo*

- comparando 2 series de casos en periodos diferentesvs (1997-1984 vs 2001-2008). *Cir Esp.* 2011, 89(7):439-447
- [3] Ambrosone L, Guerra G, Cinelli M, Filippelli M, Mosca M, Vizzarri F, Giorgio D, Costagliola C. Corneal epithelial wound healing promoted by verbascoside-based liposomal eyedrops. *Biomed Res Int.* 2014;2014:471642
- [4] Badger SA: Management of liver trauma. *World J Surg* 2009; 33:2522-37
- [5] Rotondo MF, Schwab CW, McGonigal MD, et al.: "Damage control": An approach for improved survival in exsanguinating penetrating abdominal injury. *J Trauma* 1993; 35: 375-383
- [6] Shapiro MB, Jenkins DH, Schwab CW, et al.: Damage control: Collective review. *J Trauma* 2000; 49: 969-
- [7] Wyrzykowski AM, Feliciano DV: Trauma damage control. In *Trauma* (Feliciano DV, Mattox KL, Moore EE, eds), Sixth edition. 2008; pp 851–870, McGraw-Hill, New York.
- [8] Kushimoto S: Damage Control Surgery and Open Abdominal Management: Recent Advances and Our Approach. *J Nippon Med Sch* 2007; 78(6)
- [9] 6: Giuliani A, Bianco P, Guerra G, Rocca A, Calise F: Totally laparoscopic liver resection for colorectal metastasis located in Segment 7 in a patient with situs inversus totalis. *J Surg Case Rep.* 2017 Jan 17;2017(1). pii: rjw243. doi:10.1093/jscr/rjw243
- [10] Rocca A, Calise F, Marino G, Montagnani S, Cinelli M, Amato B, Guerra G. Primary giant hepatic neuroendocrine carcinoma: a case report. *Int J Surg.* 2014;12 Suppl 1:S218-21. doi: 10.1016/j.ijssu.2014.05.056
- [11] Loffredo D, Marvaso A, Ceraso S, Cinelli N, Rocca A, Vitale M, Rossi M, Genovese E, Amato B, Cinelli M. Minimal invasive surgery in treatment of liver metastases from colorectal carcinomas: case studies and survival rates. *BMC Surg.* 2013;13 Suppl 2:S45. doi: 10.1186/1471-2482-13-S2-S45
- [12] Ceccarelli G, Andolfi E, Biancafarina A, Rocca A, Amato M, Milone M, Scricciolo M, Frezza B, Miranda E, De Prizio M, Fontani A. Robot-assisted surgery in elderly and very elderly population: our experience in oncologic and general surgery with literature review. *Aging Clin Exp Res.* 2017 Feb;29(Suppl 1):55-63
- [13] Calise F, Giuliani A, Sodano L, Crolla E, Bianco P, Rocca A, Ceriello A. Segmentectomy: is minimally invasive surgery going to change a liver dogma? *Updates Surg.* 2015 Jun;67(2):111-5. doi: 10.1007/s13304-015-0318-z
- [14] Dindo D, Demartines N, Clavien PA; Classification of surgical complications. *Ann Surg.* 2004; 244: 931-937
- [15] Meyer AA, Crass RA, Lim RC Jr, Jeffrey RB, Federle MP, Trunkey DD. Selective nonoperative management of blunt liver injury using computed tomography. *Arch Surg.* 1985 May;120(5):550-554
- [16] Feliciano DV, Mattox KL, Jordan GL et al. Management of 1000 consecutive cases of hepatic trauma. *Ann Surg* 204: 438-45, 1986
- [17] Richardson JD, Franklin GA, Lukan JK, Carrillo EH, Spain DA, Miller FB, Wilson MA, Polk HC Jr., and Flint LM: Evolution in the Management of Hepatic Trauma: A 25-Year Perspective From the Department of Surgery, University of Louisville School of Medicine, Louisville, Kentucky *ANNALS OF SURGERY* Vol. 232, No. 3, 324–330 © 2000 Lippincott Williams & Wilkins)
- [18] Rotondo MF, Schwab CW, McGonigal MD, et al.: "Damage control": An approach for improved survival in exsanguinating penetrating abdominal injury. *J Trauma* 1993; 35: 375-383
- [19] Shapiro MB, Jenkins DH, Schwab CW, et al.: Damage control: Collective review. *J Trauma* 2000; 49: 969
- [20] Stone H: management of major coagulopathy with onset during laparotomy. *Ann Surg* 1983; 197: 532.535
- [21] Jurkovich GJ1, Greiser WB, Luterman A, Curreri PW: Hypothermia in trauma victims: an ominous predictor of survival. *J Trauma.* 1987 Sep;27(9):1019-1024
- [22] Reed: hypothermia and blood coagulation: dissociation between enzyme and clotting factors levels. *Circ Shock.* 1990;32: 141-152
- [23] Luna GK: Incidence and effect of hypothermia in seriously injured patients. *J Trauma* 1987; 27: 1014-1107
- [24] Blunt hepatic injury: a paradigm shift from operative to non-operative management in the 1990s. *Ann Surg.* 2000 June
- [25] Karp MP, Cooney DR, Pros GA, Newman BM, Jewett TC Jr: The nonoperative management of pediatric hepatic trauma. *J Pediatr Surg.* 1983 Aug;18(4):512-518
- [26] Feliciano DV, Mattox KL, Jordan GL et al. Management of 1000 consecutive cases of hepatic trauma. *Ann Surg* 204: 438-45, 1986
- [27] Parks RW, Chryso E, Diamond T. Management of liver trauma. *Br J Surg.* 1999 Sep;86(9):1121-1135
- [28] Fulvio Calise, Piero Atelli, Antonio Giuliani, Vincenzo Scuderi and Aldo Rocca Left Hepatectomy: Laparoscopic Approach. *Updates Surgery Chapter · January 2013 DOI: 10.1007/978-88-470-2664-3_38*
- [29] Gazzaniga AB: Laparoscopy in the diagnosis of blunt and penetrating injuries to the abdomen. *Am J Surg* (1976) 131:315-318
- [30] Ivatury RR: A critical evaluation of laparoscopy in penetrating abdominal trauma. *J Trauma* 1993; 34: 822-828
- [31] Uranüs: Minimally invasive surgery in trauma and emergencies. *Eur J Trauma Emerg Surg* 2010; 36: 1
- [32] Giuliani A, Migliaccio C, Ceriello A, Aragiusto G, La Manna G, Calise F. Laparoscopic vs. open surgery for benign liver lesions: assessing quality of life in the first year after surgery. *Updates*