

Pilot feasibility study of a simple regenerative peripheral nerve interface designed to diminish cutaneous dysesthesia after supraclavicular operations

Alexander Yang, MD, PhD,^{a,b} and Robert W. Thompson, MD,^{a,c} St. Louis, MO

ABSTRACT

Supraclavicular operations can be associated with postoperative cutaneous dysesthesia and hypersensitivity. Regenerative peripheral nerve interfaces, created by attaching the proximal end of a divided peripheral nerve into a viable muscle target, can promote neurite regrowth and neuromuscular connections to help suppress painful nerve hyperactivity. During 40 consecutive operations for neurogenic thoracic outlet syndrome, we demonstrated that division of at least one of the superficial supraclavicular cutaneous sensory nerve branches was necessary in 98% of cases. We subsequently developed a novel regenerative peripheral nerve interface for supraclavicular operations using the adjacent omohyoid muscle and have described the technical steps involved in this procedure. (*J Vasc Surg Cases Innov Tech* 2022;8:287-92.)

Keywords: Cutaneous dysesthesia; Omohyoid muscle; Regenerative peripheral nerve interface; Supraclavicular nerve; Surgical technique; Thoracic outlet syndrome

Supraclavicular operations are commonly performed for arterial reconstruction, open repair of clavicle fractures, and thoracic outlet syndrome (TOS).^{1,2} These operations often require division of the supraclavicular sensory nerves to provide sufficient operative exposure and can, therefore, be associated with postoperative cutaneous dysesthesia, hypersensitivity, neuralgia, or painful neuromas in the distribution of the supraclavicular nerves.³⁻⁶

Regenerative peripheral nerve interfaces (RPNI) involve attachment of the proximal end of a divided peripheral nerve into a viable muscle target to promote neurite regrowth and neuromuscular connections. This

technique has emerged as a useful approach to help suppress painful nerve hyperactivity and phantom pain associated with neuromas, limb amputations, and other surgical settings.⁷⁻⁹ We have described the frequency with which division of the supraclavicular nerves was necessary during operations for neurogenic TOS and the development of a novel RPNI that takes advantage of the adjacent omohyoid muscle.

METHODS

A total of 40 consecutive patients had undergone primary surgery of neurogenic TOS between February 15 and August 15, 2021, consisting of supraclavicular anterior and middle scalenectomy, first rib resection, and brachial plexus neurolysis, as previously described.^{1,2} During the initial development of subplatysmal flaps, each of the three supraclavicular cutaneous nerve branches was identified over the upper surface of the clavicle, and intraoperative measurements were taken of the distance between the sternal notch and each nerve branch (Fig 1, A). The frequency with which division of each nerve branch was necessary to allow for satisfactory exposure for supraclavicular decompression was determined. A method was then developed for creation of a supraclavicular nerve RPNI using the omohyoid muscle as a viable target for nerve implantation (Fig 1, B). The feasibility of this technique was subsequently evaluated in a subset of patients during supraclavicular decompression. All the patients provided written informed consent for study participation with approval by the institutional review board at our medical center.

RESULTS

In a retrospective review of 46 patients who had undergone primary supraclavicular decompression for

From the Center for Thoracic Outlet Syndrome,^a Division of Plastic and Reconstructive Surgery,^b and Section of Vascular Surgery,^c Department of Surgery, Washington University School of Medicine.

The present study was supported in part by the Thoracic Outlet Syndrome Research and Education Fund of the Foundation for Barnes-Jewish Hospital, BJC Healthcare, St. Louis, MO. The Foundation for Barnes Jewish Hospital had no involvement in the study design; collection, analysis, or interpretation of the data; manuscript writing; or the decision to submit the report for publication.

Author conflict of interest: none.

The current address for A.Y. is Division of Neurosurgery, Department of Surgery, Creighton University, CHI Health Clinic Neurosurgery, 7710 Mercy Rd, Suite 224, Omaha, NE 68124.

Correspondence: Robert W. Thompson, MD, Center for Thoracic Outlet Syndrome, Section of Vascular Surgery, Department of Surgery, Washington University School of Medicine, 660 S Euclid Ave, Campus Box 8109, St. Louis, MO 63110 (e-mail: rwthompson@wustl.edu).

The editors and reviewers of this article have no relevant financial relationships to disclose per the Journal policy that requires reviewers to decline review of any manuscript for which they may have a conflict of interest.

2468-4287

© 2022 The Author(s). Published by Elsevier Inc. on behalf of Society for Vascular Surgery. This is an open access article under the CC BY-NC-ND license (<http://creativecommons.org/licenses/by-nc-nd/4.0/>).

<https://doi.org/10.1016/j.jvscit.2022.03.013>

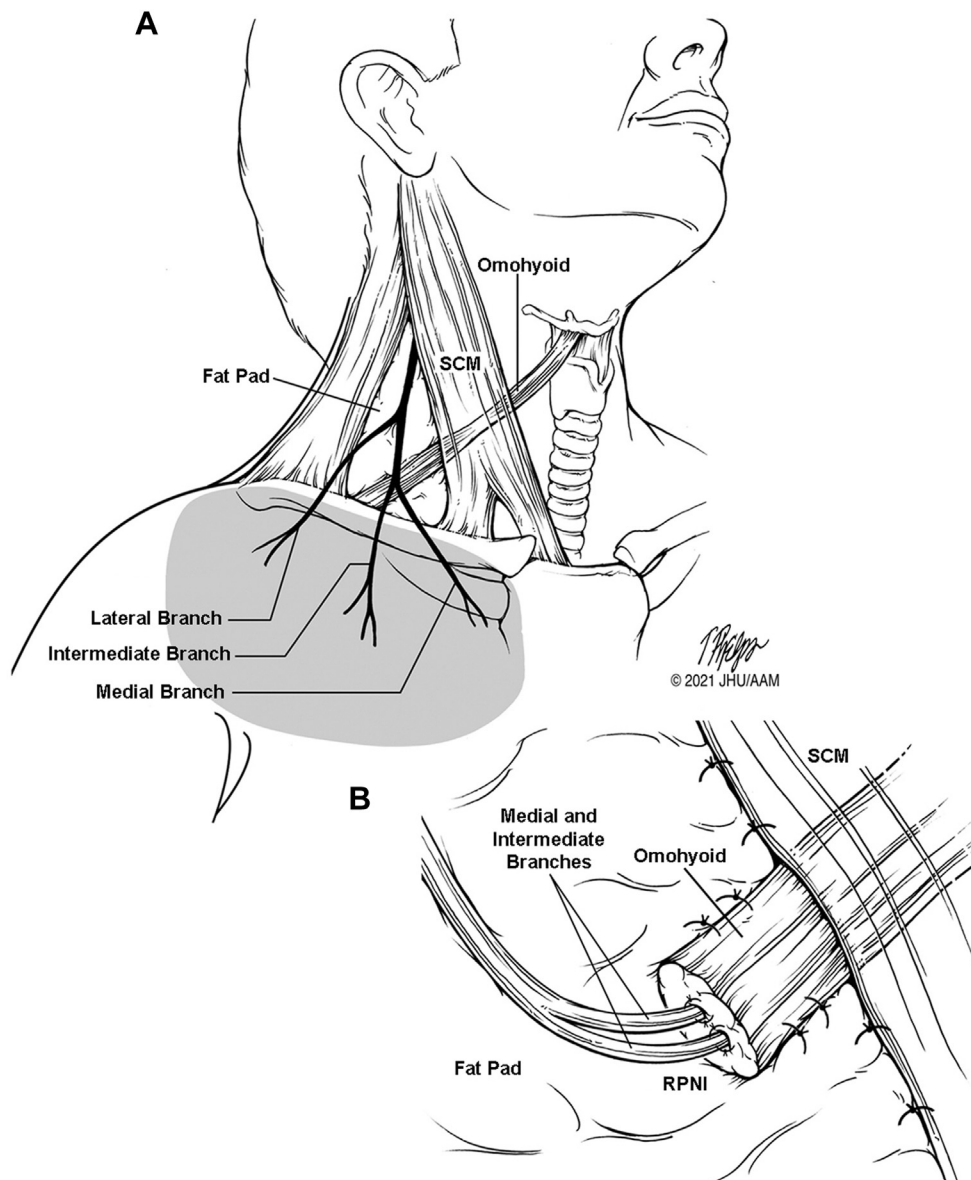


Fig 1. Drawings depicting the supraclavicular nerves and omohyoid muscle. **A,** The course of the three branches of the supraclavicular cutaneous nerve is shown as they pass over the clavicle, with the sensory distribution denoted by the *shaded area*. **B,** Illustration of a regenerative peripheral nerve interface (RPNI) created by attachment of the supraclavicular nerve (intermediate and medial branches) to the free medial end of the divided omohyoid muscle. *SCM*, Sternocleidomastoid muscle.

neurogenic TOS during the 6-month period before the present study (August 2020 to February 2021), we found the incidence of peri-incisional cutaneous hypersensitivity was 34% (mild, 30%; moderate, 4%) at the 1-month

follow-up office visit. The incidence of peri-incisional hypersensitivity had declined to 16% (mild, 6%; moderate, 6%; substantial, 4%) at 3 months and to 12% (mild, 4%; moderate, 2%; substantial, 6%) at 6 months. These

Table I. Supraclavicular nerve measurements^a

Distance measured	Mean ± SE, mm	Median, mm	Range, mm
SN to SCM edge	61.0 ± 1.7	60.0	37-80
SN to medial branch SCN	66.3 ± 2.1	64.5	41-100
SN to intermediate branch SCN	81.6 ± 2.4	82.0	45-120
SN to lateral branch SCN	99.8 ± 3.0	100.0	64-155
Medial branch to intermediate branch SCN	5.3 ± 1.2	5.0	0-25
Intermediate branch to lateral branch SCN	15.3 ± 1.5	15.0	2-35

SCM, Sternocleidomastoid muscle; SCN, supraclavicular nerve; SE, standard error; SN, sternal notch.
^aIntraoperative measurements were obtained in 40 consecutive patients undergoing supraclavicular decompression for neurogenic thoracic outlet syndrome.

Table II. Division of supraclavicular nerves

Nerves divided	Patients, No. (%)
Medial branch	33 (82)
Intermediate branch	38 (95)
Lateral branch	9 (23)
Medial branch alone	1 (2)
Intermediate branch alone	4 (10)
Lateral branch alone	0 (0)
Medial and intermediate branches	32 (80)
Intermediate and lateral branches	2 (5)
Medial, intermediate, and lateral branches	7 (17)
None	1 (2)

findings reinforce the potential value of a novel method to reduce cutaneous hypersensitivity after supraclavicular operations.

We initially assessed the frequency with which RPNI might be applicable to supraclavicular operations in a series of patients undergoing treatment of neurogenic TOS by obtaining intraoperative measurements of the location of the supraclavicular nerve branches. Using the middle of the sternal notch as an anchor, the distance between the sternal notch and each nerve branch was measured as it passed over the upper surface of the clavicle (Table I). We subsequently found that to obtain satisfactory exposure for thoracic outlet decompression, it was necessary to divide one or more of the supraclavicular nerve branches in 98% of the patients (Table II).

Because the omohyoid muscle traverses the supraclavicular space and is normally divided during supraclavicular decompression, we considered using the medial portion of this muscle as a potential target for creation of a supraclavicular nerve RPNI (Fig 2). The technique developed is performed as follows. First, during the initial creation of the subplatysmal flaps, the three supraclavicular cutaneous nerves passing over the top of the clavicle are identified and the upper end of the nerves to be divided are marked with silk ligatures until the end of the procedure. Second, during lateral mobilization of the scalene fat pad, the lateral portion of the omohyoid muscle is divided while preserving the viable medial portion. Third, on completion of the procedure, the scalene fat pad is reattached to the

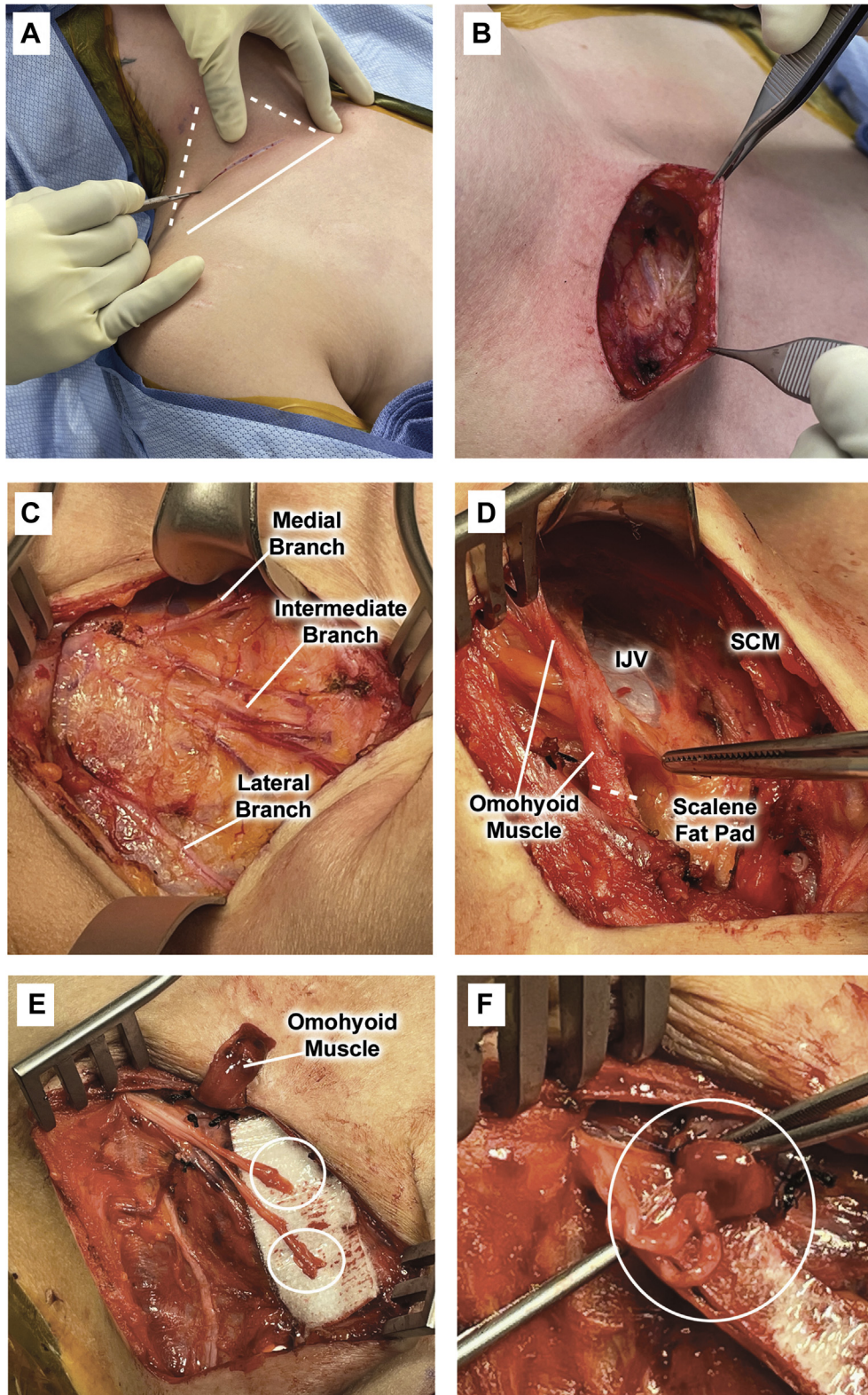


Fig 2. Operative photographs depicting a right-sided procedure, viewed from the right side of the patient. **A**, A supraclavicular incision is created from the lateral border of the sternocleidomastoid muscle to the edge of the trapezius muscle (*dashed white lines*), approximately one fingerbreadth above the clavicle (*solid white line*). **B**, Subplatysmal flaps are created above and below the incision line. **C**, The three branches of the supraclavicular sensory nerve are shown as they pass vertically from the neck across the clavicle, superficial to the scalene fat pad. Nerves that need to be divided to obtain surgical exposure (typically the medial and intermediate

edge of the sternocleidomastoid muscle, and the viable medial portion of the omohyoid muscle is secured to an appropriate site on the surface of the scalene fat pad with 5-0 polypropylene sutures. Fourth, the divided supraclavicular cutaneous nerves are traced and mobilized superiorly to divide the nerves at a level suitable for muscle attachment. Finally, a tension-free attachment is created between the epineurium of the free proximal end of the divided supraclavicular cutaneous nerves and the center of the viable medial end of the omohyoid muscle, using several 6-0 polypropylene sutures.

This RPNI technique was assessed in a pilot study of 20 patients and found to be uniformly feasible. In each case, lateral division of the omohyoid muscle during the initial mobilization of the scalene fat pad provided an ample length of viable muscle 5 to 20 mm in diameter for secure and tension-free attachment to the scalene fat pad, adjacent to the edge of the sternocleidomastoid muscle. The divided supraclavicular nerves were easily dissected to a more proximal level, with a diameter of 2 to 4 mm and sufficient flexibility to attach to the omohyoid muscle without tension. When the medial and intermediate branches were both divided, proximal dissection to their common nerve origin provided a nerve of more suitable size for muscle attachment. Finally, this technique added no more than 10 to 15 minutes to the operating time at the end of the procedure, just before wound closure, making it easily adaptable to thoracic outlet decompression operations.

DISCUSSION

In the present study, we found that some degree of cutaneous hypersensitivity occurred in ~35% of patients at some point during follow-up after supraclavicular decompression for neurogenic TOS. We also confirmed that division of one or more of the supraclavicular nerve branches will be necessary in almost all cases, indicating that applicability of an RPNI to help prevent cutaneous dysesthesia in these operations

would be wide. This technique would also potentially apply to other supraclavicular procedures, such as arterial reconstruction.

Because the omohyoid muscle has only a minor functional role, it is considered expendable and is usually divided in anterior neck operations.¹⁰ Thus, it can provide an ideal target for use as a vascularized muscle flap in the creation of an RPNI. In the simple technique we have developed, the medial end of the divided omohyoid muscle is preserved, with any devascularized muscle easily excised at the end of the procedure to ensure that only viable muscle is used for nerve attachment.

The supraclavicular RPNI we have described was performed in a pilot study with uniform technical success, demonstrating the simplicity, ease, and feasibility of this technique in supraclavicular operations. We found an ample length of viable omohyoid muscle in all cases, with no cases in which the length of the nerve was insufficient to comfortably reach the omohyoid muscle edge. We found that creation of the RPNI does not require an operating microscope, although 2× to 3× loupe magnification is helpful. Also, this technique only added ~10 minutes to the operative time. Although we were unable to assess efficacy in this pilot study, the approach we developed will subsequently allow for further evaluation in a prospective controlled study with adequate follow-up, in which we can assess the effectiveness of this technique in preventing postoperative dysesthesia.

CONCLUSIONS

We have described a novel technique to create an RPNI during supraclavicular operations using the adjacent omohyoid muscle that is simple, uniformly feasible, and efficient and could help to diminish periclavicular skin hypersensitivity following these procedures.

The authors are grateful to Timothy H. Phelps, MS, FAMI (Johns Hopkins University School of Medicine, Baltimore, MD), for preparing the drawings for our study.

supraclavicular nerve branches) are tagged with ligatures for later identification. **D**, The omohyoid muscle is identified during detachment and rotation of the scalene fat pad to expose the underlying scalene triangle. The line of division of the omohyoid muscle is shown (*dashed white line*). **E**, Once the decompression procedure has been completed, the scalene fat pad is rotated back to its native position to cover the brachial plexus and reattached to the edge of the sternocleidomastoid muscle, maintaining the omohyoid muscle in view. The previously divided supraclavicular nerve branches (*white circles*) are cleared of adherent tissue and traced proximally. **F**, The omohyoid muscle is attached to the surface of the scalene fat pad to prevent retraction, preserving the viable free end of the muscle. Avoiding tension, fine polypropylene sutures are used to attach the epineurium of the free divided end of the supraclavicular nerves to the midportion of the viable divided end of the omohyoid muscle to create the regenerative peripheral nerve interface (RPNI; *white circle*). *IJV*, Internal jugular vein; *SCM*, sternocleidomastoid muscle.

REFERENCES

1. Duwayri YM, Thompson RW. Supraclavicular approach for surgical treatment of thoracic outlet syndrome. In: Chaikof EL, Cambria RP, editors. Atlas of vascular surgery and endovascular therapy. Elsevier Saunders; 2014. p. 172-92.
2. Thompson RW, Ohman JW. Surgical techniques: operative decompression using the supraclavicular approach for neurogenic thoracic outlet syndrome. In: Illig KA, Thompson RW, Freischlag JA, Donahue DM, Jordan SE, Lum YW et al., editors. Thoracic outlet syndrome (TOS). Second edition. Springer Nature; 2021. p. 265-85.
3. Elliot D. Surgical management of painful peripheral nerves. Clin Plast Surg 2014;41:589-613.
4. Brown DL, Dellon AL. Surgical approach to injuries of the cervical plexus and its peripheral nerve branches. Plast Reconstr Surg 2018;141:1021-5.
5. Nathe T, Tseng S, Yoo B. The anatomy of the supraclavicular nerve during surgical approach to the clavicular shaft. Clin Orthop Relat Res 2011;469:890-4.
6. Ou L, Yang L, Zhao J, Su W. Cutaneous paresthesia after internal plate fixation of clavicle fractures and underlying anatomical observations. Medicine (Baltimore) 2018;97:e12729.
7. Santosa KB, Oliver JD, Cederna PS, Kung TA. Regenerative peripheral nerve interfaces for the prevention and management of neuromas. Clin Plast Surg 2020;47:311-21.
8. Ganesh Kumar N, Kung TA. Regenerative peripheral nerve interfaces for the treatment and prevention of neuromas and neuroma pain. Hand Clin 2021;37:361-71.
9. Kubiak CA, Adidharma W, Kung TA, Kemp SWP, Cederna PS, Vemuri C. Decreasing postamputation pain with the regenerative peripheral nerve interface. Ann Vasc Surg 2022;79:421-6.
10. Rai R, Ranade A, Navak S, Vadgaonkar R, Mangala P, Krishnamurthy A. A study of anatomical variability of the omohyoid muscle and its clinical relevance. Clinics 2008;63:521-4.

Submitted Dec 8, 2021; accepted Mar 31, 2022.