

Dental Operating Microscope-guided Retrieval of Broken Instrument from a Deciduous Molar Using Ultrasonics

Rahul Kaul¹, Rohan Gupta², Sanjay Chhabra³, Rishu Koul⁴

ABSTRACT

Endodontic procedures are associated with various mishaps, one of which is instrument breakage. It can act as an obstruction to mechanical and chemical cleaning of an infected root canal, thereby hampering the prognosis of treatment. Instrument retrieval must be performed with minimum damage to a tooth and surrounding tissues, minimal loss of radicular dentine and simultaneously maintaining the original canal shape as much as possible. This case report represents successful retrieval of a separated K file fragment from the distobuccal canal of the right mandibular primary second molar 85 with ultrasonic energy application under the dental operating microscope.

Keywords: Deciduous molar, Instrument retrieval, Instrument separation, Magnification, Ultrasonic.

International Journal of Clinical Pediatric Dentistry (2022): 10.5005/jp-journals-10005-1892

INTRODUCTION

Any endodontic procedure involving either primary or permanent tooth carries a procedural risk of accidental instrument breakage or fracture. Such a debacle brings with it feelings of despair, anxiety, and then the hope that non-surgical retreatment techniques exist to liberate the instrument from the canal.

The term "Broken instruments" is not simply limited to separated files, but also can be applied to a sectioned silverpoint, gates glidden drill, a portion of a carrier-based obturator, or any other dental material left inside the canal.^{1,2} With the advent of rotary NiTi files, there has been an unfortunate increase in the occurrence of broken instruments.³ Excessive torque and multiple usages of files by a dentist have been held responsible for the failure of stainless steel and NiTi instruments.⁴

The removal of the broken fragments with traditional methods is time-consuming, risky, and has limited success. The consequences of leaving vs retrieving broken instruments from the canal have been discussed in the literature and various approaches for managing these obstructions have been presented.^{5,6} The likelihood of achieving success is governed by various factors like pulp vitality status, the position and type of separated instrument, the root canal anatomy, the amount of damage expected to be caused to the remaining tooth structure during the process of retrieval, and the experience and skill of the operator, success rates reported being 55–79%.^{7,8}

Instrument retrieval techniques require preparation of tooth in such a way that causes excessive removal of radicular dentine. Ideally, the instrument retrieval must be performed with minimum damage to a tooth and surrounding tissues, minimal loss of radicular dentine and simultaneously maintaining the original canal shape as much as possible.⁹

In primary teeth, the feasibility of these options seems constrained owing to inherently thinner radicular dentin and requires the use of a non-invasive or minimally invasive technique for the removal of the separated instrument. In primary teeth, extraction followed by space maintenance is often considered the treatment of choice as a separated instrument may interfere with the physiological root resorption.^{10,11}

¹Department of Paediatric Dentistry, Field Hospital, Manipur, India

²Department of Dentistry, Master of Dental Surgery (Conservative Dentistry and Endodontics), Rajouri, Jammu and Kashmir, India

³Department of Dentistry, Master of Dental Surgery (Conservative Dentistry and Endodontics), Dimapur, Nagaland, India

⁴Department of Dentistry, MDC Gopalpur, Odisha, India

Corresponding Author: Rahul Kaul, Department of Paediatric Dentistry, Field Hospital, Manipur, India, Phone: +91 9469280800, e-mail: dr.rahulkaul@gmail.com

How to cite this article: Kaul R, Gupta R, Chhabra S, et al. Dental Operating Microscope-guided Retrieval of Broken Instrument from a Deciduous Molar Using Ultrasonics. *Int J Clin Pediatr Dent* 2022;15(S-1):S114–S118.

Source of support: Nil

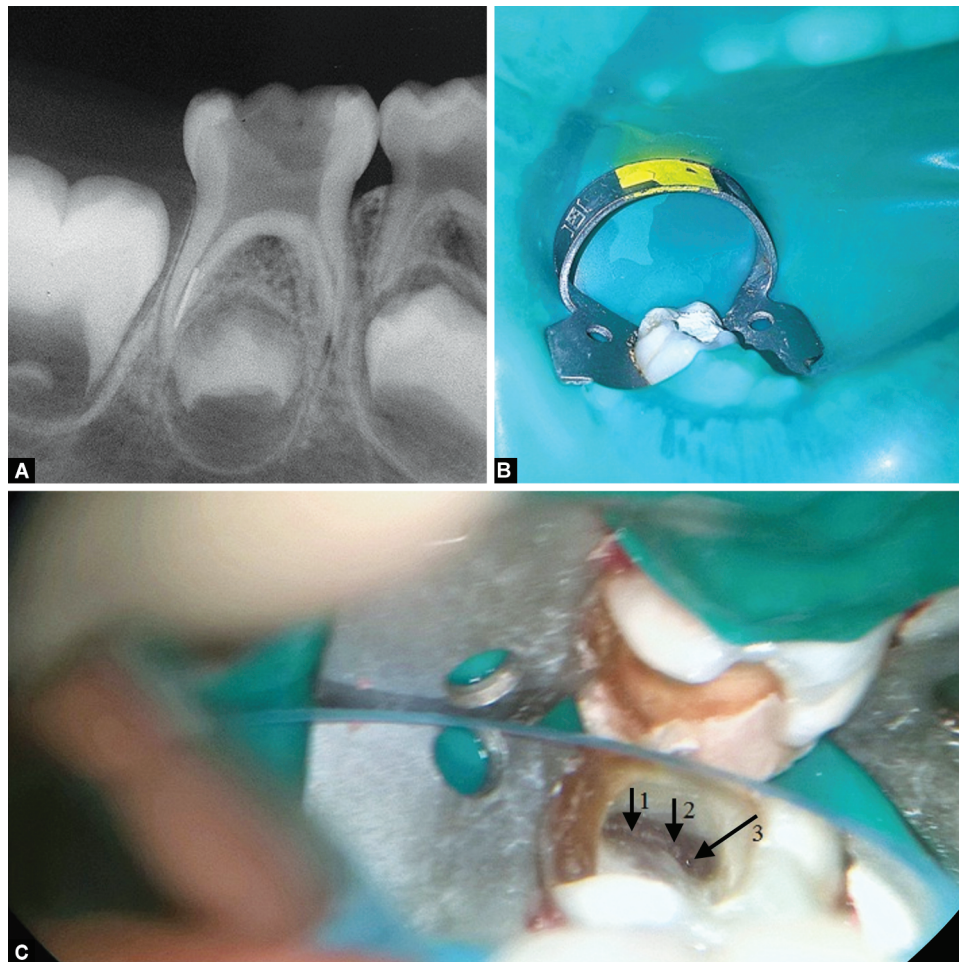
Conflict of interest: None

This case report represents successful retrieval of a separated K file fragment from the distobuccal canal of the right mandibular primary second molar (85) with ultrasonic energy application under the operating microscope.

CASE DESCRIPTION

A 6-year-old female patient reported to the Department of Pedodontics and Preventive Dentistry with a complaint of pain in the lower right back region of the mouth. Her medical history was non-contributory. Dental history suggested root canal treatment in the right mandibular primary second molar (85) by a general dentist 1 week ago.

On clinical examination, a temporarily restored mandibular right primary second molar was observed. Radiographic examination revealed the presence of a fractured instrument in the apical one-third of the distal canal (Fig. 1A). While discussing various treatment options, the parent of the child insisted that the tooth be saved rather than extracted. We planned a two-stage pulpectomy to retrieve the separated file in the first stage with intermediate calcium hydroxide dressing followed by root canal obturation and a preformed stainless steel crown placement in the second stage.



Figs 1A to C: Preoperative radiograph and clinical photographs

Informed consent was obtained from the parents before the clinical procedure. After application of benzocaine 20% w/v topical anesthetic gel (Mucopain, ICPA, India) at the injection site, the inferior alveolar nerve block was given using lignocaine 2% with adrenaline 1:80,000 (Lignox, Indoco Warren, Mumbai). The primary mandibular second molar was isolated with the rubber dam (Fig. 1B). The temporary restoration was removed. Canal orifices were located using DG16 Endodontic explorer (GDC, Hoshiarpur, Punjab). The mesiobuccal, mesiolingual, and distolingual canals were explored using No. 10 K file (Mani Inc, Japan) and no interferences in negotiating these canals were encountered. On the other hand, the distobuccal canal was completely blocked beyond the length of 5 mm and an attempt to negotiate had failed. An obstruction to penetration was observed each with No. 8, 10, and 15 K-file in the distobuccal canal.

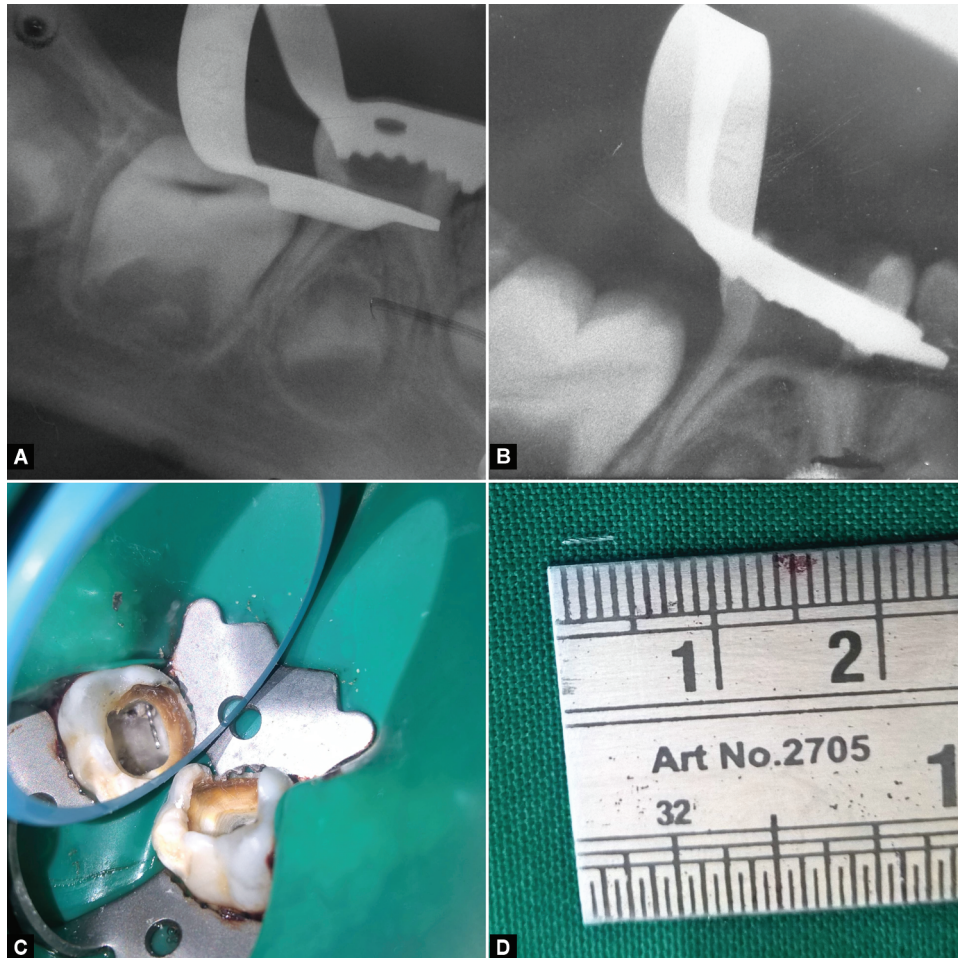
The mesiolingual, mesiobuccal, and distolingual canals were prepared using No. 15, 20, and 25 K-files. Irrigation was performed using 1% sodium hypochlorite solution followed by normal saline after each file use. These canals were then blocked with cotton pellets to prevent accidental spillage of the retrieved instrument into any of the other canals. The coronal third of the distobuccal canal was slightly modified using an Ultrasonic Endodontic ET 20 D tip (Aceton, Satelac, France) using an ultrasonic handpiece (Satelac, Suprasson P 5 Booster). This was done to obtain straight-line access to the fractured fragment. Sterile normal saline was used intermittently for cooling irrigation. The separated instrument was visualized with

the help of a dental operating microscope (DOM) (HS-Moller-Wedel International, Germany) at 8× magnification (Fig. 1C). DG-16 explorer was again used to confirm the straight-line access to the instrument. 17% EDTA solution (Prevest Denpro, India) was placed in the canal using a 30-gauge syringe and aspirated to allow only a minimum amount of EDTA to be leftover around the fractured instrument so that it did not compromise visualization of the fragment as well as to prevent extrusion beyond the apex. The staging was performed using an Ultrasonic Endodontic ET40 tip (Aceton, Satelac, France) by placing and activating it alongside the instrument circumferentially at a power setting of 4 under the DOM at 16× magnification. Following staging, using the same tip at a power setting of 5, the ultrasonic tip was placed in contact with the instrument and activated moving it gently in a counterclockwise direction, which led to the loosening of file fragment and popping out into the pulp chamber (Fig. 2C). Steiglitz forceps (Hu-Friedy, IL, USA) was used to retrieve the fragment from the pulp chamber. Cotton pellets were removed from the remaining canals following instrument retrieval.

The radiographic assessment confirmed the complete retrieval of the fractured fragment (Figs. 2A and B). The fractured instrument was found to be a K-file, approximately 4 mm in length (Fig. 2D).

An intracanal dressing of a thick water-soluble calcium hydroxide paste (RC Cal, Prime Dental, India) was placed in the canals, and temporization done using a cavity (3M ESPE, Germany).

The patient was recalled after 1 week, access cavity was re-entered following isolation of the tooth using a rubber dam, and root canals



Figs 2A to D: Intraoperative radiographs and clinical photographs showing retrieved instrument

were irrigated with sterile normal saline to flush out any calcium hydroxide and dried with absorbent paper points. The obturation was carried out with Metapex, calcium hydroxide paste with iodoform (Meta Biomed, Korea), by injecting into each canal gradually until they were filled (Fig. 3A). After ensuring complete obturation radiographically, the access cavity was restored with Type IX Glass Ionomer cement (GC Corporation, Tokyo Japan). The tooth was further prepared and restored with a preformed SS crown (Hu-Friedy, IL, USA) (Fig. 3B).

The patient was recalled again after 2 weeks, 3 months, and 6 months intervals (Figs. 3C and D). Clinically, the patient was found to be asymptomatic. On radiographic examination at these recall visits, there was no evidence of any furcal radiolucency, suggestive of successful treatment outcome.

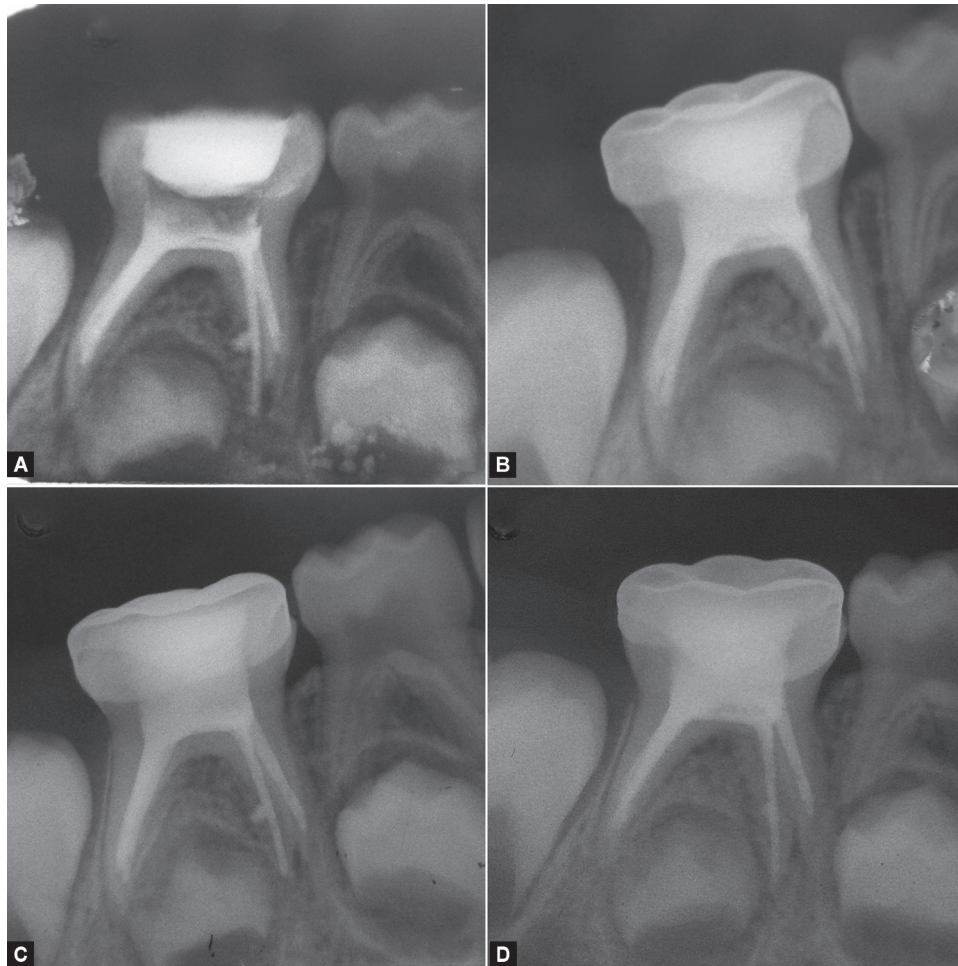
DISCUSSION

Retrieval of a broken instrument is based on the same principle as fundamental principles and objectives of root canal treatment.¹² A broken/fractured instrument can be an obstruction to mechanical and chemical cleaning of an infected root canal. Bacteria and pulp tissue present in the root canal due to inadequate cleaning may adversely affect the treatment outcome.¹³ Prognosis in such cases is dependent on the stage and degree of root canal preparation, debridement, and disinfection at the time of instrument fracture and, ultimately on the extent to which microbial control is compromised. The decisive prognostic factor in these cases is the

prior existence or non-existence of any preoperative periradicular pathosis.^{4,14}

Instrument retrieval, depending on the technique used can lead to perforation of the root, ledge formation and transportation of the original canal may occur, as well as weakening of the affected root in case of excessive removal of dentine or fracture of an additional instrument. Therefore, treatment planning should include a risk assessment, as the chance of successfully removing a fractured instrument from the root canal depends on various factors, such as angle and radius of the curvature of the affected root and additionally limited by root morphology, that includes thickness of dentin and depth of external concavities site of the broken instrument in relation to the curvature, type of the fractured instrument and its length.¹⁵ The type of material causing an obstruction is another important factor to be considered. Stainless steel files do not fracture further during the removal process and they tend to easier removal. Nickel-titanium separated instruments may break again, go deeper into the canal, due to heat build-up during the use of ultrasonics.¹⁶

It is also important to know whether the file was rotating clockwise or anticlockwise before separation as it influences the proper ultrasonic removal technique. The ultrasonic tip is placed between the exposed end of the file and canal wall and it is vibrated around the obstruction in a counterclockwise direction that applies an unscrewing force to the file as it is being vibrated. This technique will help in removing instruments that have a clockwise



Figs 3A to D: Postoperative and follow-up radiographs

cutting action. If the file has a counterclockwise cutting action, then a clockwise rotation will be needed. Also if the operator is not cautious and excessive pressure is applied, the vibrations may push the fragment further apically, or cause the ultrasonic tip breakage, landing the operator into a more troublesome scenario. Moreover, to prevent separation of the ultrasonic tip, it is necessary to avoid undue stress, by activating it only when the tip is in contact with root tissue.¹⁷

The prognosis of a tooth can be seriously hampered if the efforts to remove a separated instrument lead to iatrogenic events, such as a ledged canal or root perforation. When retrieval efforts of the separated instruments are not successful, biomechanical preparation and obturation procedures are compromised and the ultimate prognosis will be in doubt. In such cases, surgery or extraction will be needed at times in presence of adverse signs and symptoms.

Manual retrieval of a broken instrument, though time-consuming, is convenient in deciduous teeth because of inherently wider and straighter root canals. However, it requires the use of a non-invasive or minimally invasive technique for removal of the separated instrument.¹⁸

The ultrasonic technique is a minimally invasive technique that involves generating ultrasonic vibrations which are transmitted to the fractured fragment to loosen it and then move it out of the canal.¹⁹ It has been shown by various studies that the combination of ultrasonics with magnification provided by a DOM has made retrieval of fractured instruments more predictable.^{11,12,17} An important factor contributing to the high success rate of fragment

removal was found to be the use of magnification provided by a dental microscope.¹² Moreover, a higher removal success rate (85.3%) was obtained when the fragments were visualized with a dental microscope compared to when the fragments were not visible, in which case the success rate was a low 47.7%.²⁰

In the present case, the broken instrument was retrieved using a combination of ultrasonics with magnification provided by a DOM without much removal of coronal dentin, thereby preserving root canal anatomy. Moreover, no complications were observed as associated with instrument retrieval procedures during the procedure and even after completion of the procedure, which was evident from radiological as well as clinical examination.

CONCLUSION

The ultrasonic endodontic device along with improved visualization by virtue of a DOM, balanced with favorable prognosis is the treatment option of choice for broken instrument retrieval. A combination of early intervention in retrieving the broken instrument and disinfection of the root canal and periradicular tissues along with antimicrobials led to a favorable outcome.

REFERENCES

1. Fors UG, Berg JO. Endodontic treatment of root canals obstructed by foreign objects. *Int Endod J* 1986;19(1):2-10. DOI: 10.1111/j.1365-2591.1986.tb00884.x

2. Chenail BL, Teplitsky PE. Orthograde ultrasonic retrieval of root canal obstructions. *J Endod* 1987;13(4):186–190. DOI: 10.1016/S0099-2399(87)80138-3
3. Ruddle CJ. Finishing the apical one third: endodontic considerations. *Dent Today* 2002;21(5):66–73.
4. Cheung Gary SP. Instrument fracture: mechanisms, removal of fragments, and clinical outcomes. *Endod Topics* 2009;16(1):1–26. DOI: 10.1111/j.1601-1546.2009.00239.x
5. Nagai O, Tani N, Kayaba Y, et al. Ultrasonic removal of broken instruments in root canals. *Int Endod J* 1986;19(6):298–304. DOI: 10.1111/j.1365-2591.1986.tb00493.x
6. Hülsmann M. Removal of fractured instruments using a combined automated/ultrasonic technique. *J Endod* 1994;20(3):144–147. DOI: 10.1016/S0099-2399(06)80062-2
7. Gencoglu N, Helvacioğlu D. Comparison of the different techniques to remove fractured endodontic instruments. *Eur J Dent* 2009;3(3):90–95. DOI: 10.1055/s-0039-1697413
8. Kunhappan S, Kunhappan N, Patil S, et al. Retrieval of separated instrument with instrument removal system. *J Int Clin Dent Res Organ* 2012;4(1):21–24. DOI: 10.4103/2231-0754.131394
9. Fors UGH, Berg JO. A method for the removal of separated endodontic instruments from root canals. *J Endod* 1983;9(4):156–159. DOI: 10.1016/S0099-2399(83)80038-7
10. Kuo CI, Wang YL, Chang HH, et al. Application of Ni-Ti rotary files for pulpectomy in primary molars. *J Dent Sci* 2006;1:10–15.
11. Musale PK, Kataria SC, Soni AS. Broken instrument retrieval with indirect ultrasonics in a primary molar. *Eur Arch Paediatr Dent* 2016;17(1):71–74. DOI: 10.1007/s40368-015-0203-y
12. Cujé J, Bargholz C, Hülsmann M. The outcome of retained instrument removal in a specialist practice. *Int Endod J* 2010;43(7):545–554. DOI: 10.1111/j.1365-2591.2009.01652.x
13. Sjogren U, Hagglund B, Sundqvist G, et al. Factors affecting the long term results of endodontic treatment. *J Endod* 1990;16(10):498–504. DOI: 10.1016/S0099-2399(07)80180-4
14. Spili P, Parashos P, Messer HH. The impact of instrument fracture on outcome of endodontic treatment. *J Endod* 2005;31(12):845–850. DOI: 10.1097/01.don.0000164127.62864.7c
15. Suter B, Lussi A, Sequeira P. Probability of removing fractured instruments from root canals. *Int Endod J* 2005;38(2):112–123. DOI: 10.1111/j.1365-2591.2004.00916.x
16. Weine FS. *Endodontic therapy: Endodontic emergency treatment*. 5th ed., St Louis, Miss, USA: Mosby-Yearbook; 1996. pp. 203–230.
17. Fu M, Zhang Z. Removal of broken files from root canals by using ultrasonic techniques combined with dental microscope: a retrospective analysis of treatment outcome. *J Endod* 2011;37(5):619–622. DOI: 10.1016/j.joen.2011.02.016
18. Taneja S, Kumari M, Parkash H. Nonsurgical healing of large periradicular lesions using a triple antibiotic paste: a case series. *J Cont Clin Dent* 2010;1(1):31–35. DOI: 10.4103/0976-237X.62519
19. Gaffney JL, Lehman JW, Miles MJ. Expanded use of the ultrasonic scaler. *J Endod* 1981;7(5):228–229. DOI: 10.1016/S0099-2399(81)80180-X
20. Nevares G, Cunha RS, Zuolo ML, et al. Success rates for removing or bypassing fractured instruments: a prospective clinical study. *J Endod* 2012;38(4):442–444. DOI: 10.1016/j.joen.2011.12.009