

Access this article online
Quick Response Code:

Website: http://journals.lww.com/TJOP
DOI: 10.4103/tjo.TJO-D-23-00161

# Large-diameter deep anterior lamellar keratoplasty: A narrative review

Angeli Christy Yu<sup>1,2,3</sup>, Andrea Sollazzo<sup>1,2,3</sup>, Cristina Bovone<sup>1,2,3</sup>, Massimo Busin<sup>1,2,3\*</sup>

## Abstract:

Deep anterior lamellar keratoplasty (DALK) involves the selective replacement of diseased corneal stroma while preserving healthy unaffected endothelium. While DALK has failed to gain widespread popularity, improved visual and refractive outcomes of large-diameter grafts, which patients directly perceive following suture removal, may represent a compelling reason to shift toward DALK. Since the unaffected host endothelium is retained, DALK offers the opportunity to use large-diameter grafts, which reliably achieves maximum visual potential without an increased risk of immune-mediated stromal rejection. In this narrative review, we evaluate the current evidence on large-diameter DALK including surgical technique and clinical outcomes.

## Keywords:

Anterior lamellar keratoplasty, big-bubble deep anterior lamellar keratoplasty, deep anterior lamellar keratoplasty, large-diameter keratoplasty, stromal disease

## Introduction

Despite its established benefits of deep anterior lamellar keratoplasty (DALK) over penetrating keratoplasty (PK), DALK has failed to gain popularity among corneal surgeons. According to the 2022 statistical report of the Eye Bank Association of America, penetrating keratoplasty (PK) accounts for 38% of all corneal transplantation procedures performed, whereas DALK represents only <2% of the total.<sup>[1]</sup> In a recent survey of 100 corneal specialists, 89% of surgeons reported performing DALK.<sup>[2]</sup>

The evident discrepancy between the annual number of DALK surgeries and the number of surgeons who reportedly perform DALK underscores the reluctance of corneal surgeons to incorporate DALK in routine clinical practice.<sup>[3]</sup> Common misconceptions such as the rarity of complications of PK, lack of standardization of the DALK technique, and limited substantial benefit in

visual and refractive outcomes have likely prevented widespread adoption of DALK.<sup>[4]</sup> Moreover, because the safety advantages of DALK, such as the elimination of the risk of immune endothelial rejection and lower endothelial cell loss, become fully apparent only several years after the surgery, many surgeons may not find a strong enough motivation to overcome the learning curve required to perform this procedure.<sup>[5]</sup>

As in endothelial keratoplasty, which has been widely embraced despite its inherent technical difficulties, corneal surgeons may be more motivated to overcome the learning curve of DALK surgery if clinical outcomes are significantly better compared with that of traditional PK.<sup>[6]</sup> Consequently, it is crucial to take into account the visual and refractive results when enhancing the DALK technique. Since the unaffected host endothelium is retained, DALK confers the opportunity to use large-diameter grafts, which reliably achieves maximum visual potential without an increased risk of immune rejection and graft failure.<sup>[7]</sup> In this narrative review, we evaluate the current

This is an open access journal, and articles are distributed under the terms of the Creative Commons Attribution-NonCommercial-ShareAlike 4.0 License, which allows others to remix, tweak, and build upon the work non-commercially, as long as appropriate credit is given and the new creations are licensed under the identical terms.

For reprints contact: WKHLRPMedknow\_reprints@wolterskluwer.com

**How to cite this article:** Yu AC, Sollazzo A, Bovone C, Busin M. Large-diameter deep anterior lamellar keratoplasty: A narrative review. Taiwan J Ophthalmol 2024;14:27-33.

<sup>1</sup>Department of Translational Medicine, University of Ferrara, Ferrara, <sup>2</sup>Department of Ophthalmology, Ospedali Privati Forlì "Villa Igea", <sup>3</sup>Istituto Internazionale per la Ricerca e Formazione in Oftalmologia (IRFO), Forlì, Italy

### \*Address for correspondence:

Prof. Massimo Busin,  
Department of Ophthalmology, Ospedali Privati Forlì "Villa Igea"  
Forlì 47122, Italy.  
E-mail: mbusin@yahoo.com

Submission: 23-10-2023  
Accepted: 01-01-2024  
Published: 23-02-2024

evidence on large-diameter DALK including surgical technique and clinical outcomes.

### Advantages of Deep Anterior Lamellar Keratoplasty over Penetrating Keratoplasty

Currently, there is increasing evidence that refutes widely held misconceptions regarding DALK. DALK addresses the major safety issues associated with PK. As an extraocular procedure, DALK eliminates the risk of open-sky surgery and maintains the tectonic integrity of the globe.<sup>[8]</sup> In addition, DALK does not require long-term topical corticosteroid therapy, which in turn reduces the risk of secondary glaucoma.<sup>[9]</sup> More importantly, DALK eliminates the risk of immune endothelial rejection and resultant graft failure.<sup>[10]</sup> Long-term longitudinal studies have demonstrated excellent cumulative survival probabilities and higher predicted endothelial cell densities after DALK compared with PK.<sup>[8-10]</sup>

Despite the fact that larger diameter DALK places grafts in closer proximity to the limbal blood vessels, research has shown that increasing graft size does not increase the risk of corneal neovascularization or immune rejection.<sup>[11,12]</sup> Furthermore, in cases where rejection did occur, it was effectively managed through medical means. In addition, while larger grafts theoretically carry a higher risk of suture-related complications due to faster wound healing near the limbus, both groups in the study did not experience issues such as suture loosening or breakage. Consequently, because the primary target for graft rejection, which is the host endothelium, remains intact, DALK offers the possibility of utilizing larger grafts without an increased risk of postoperative complications.

### Standardizing the Technique for Large-diameter Deep Anterior Lamellar Keratoplasty

Because of the steep learning curve associated with DALK, various surgical techniques have been proposed including pneumatic dissection by Archila,<sup>[13]</sup> the big-bubble technique by Anwar and Teichmann,<sup>[14]</sup> hydrodelamination by Sugita and Kondo,<sup>[15]</sup> and viscoelastic-assisted dissection by Manche *et al.*<sup>[16]</sup> Currently, the big-bubble technique is the most widely used approach.<sup>[14]</sup>

As originally described by Anwar and Teichmann in 2002,<sup>[15]</sup> the big-bubble technique involved partial thickness corneal trephination, angled insertion of a disposable needle into the paracentral corneal stroma, and injection of air to obtain the so-called “big bubble.” Pneumatic dissection may be attempted before or after

removal of the anterior stroma.<sup>[3,17]</sup> One of the main challenges with the big-bubble technique is the need to subjectively assess the proper depth of the needle or cannula within the paracentral corneal stroma before injection of air. However, what is essential to achieve successful pneumatic dissection is not the radial distance of the tip of the cannula to the center of the cornea but rather the depth at which 1–2 mL of air is injected intrastromally.<sup>[18,19]</sup> Even with minimal advancement of the cannula into the central cornea, the likelihood of big-bubble formation can surpass 90% when the tip of the cannula is positioned within 100  $\mu$ m from the posterior corneal surface.<sup>[20]</sup> The speed of air injection has not been found to influence the success of big-bubble formation. At the end of the procedure, the anterior chamber can be simply filled with balanced salt solution.

Advances in corneal imaging and surgical instrumentation have also driven improvements in the traditional big-bubble technique. Specifically, accurate pachymetry measurements can be obtained through anterior segment optical coherence tomography (OCT).<sup>[21]</sup>

To eliminate the need for subjective judgment of the depth reached while advancing the cannula/needle up to the central cornea, adjustable guarded trephines can be calibrated based on pachymetry values such that the depth of the corneal trephination can be used to guide subsequent insertion of the cannula for pneumatic dissection.<sup>[22]</sup> Instead of trying to reach the proper depth during the advancement of the cannula toward the center of the cornea, the insertion of the cannula can be initiated at the base of a deep trephination with minimal centripetal advancement to avoid air reflux.<sup>[21]</sup> This minimizes the risk of perforating the Descemet membrane or injecting air into the superficial stroma alone.

In highly irregular corneas with significant asymmetry in peripheral corneal thickness, peripheral intrastromal hydration with balanced salt solution can be performed in zones with relative thinning to ensure safe, deep trephination.<sup>[22]</sup>

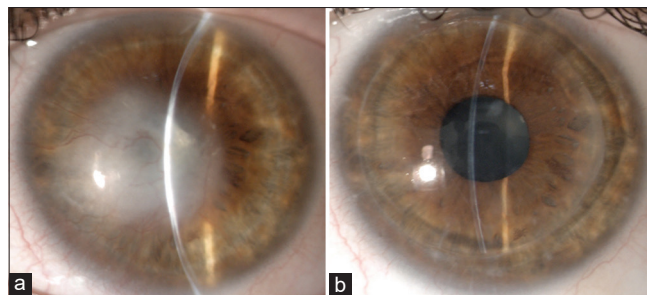
The development of the big-bubble technique has allowed deep lamellar dissection along a smooth regular plane, thereby achieving outcomes more comparable to PK. However, because both the sutures required to fixate the donor graft into the recipient bed and the graft size used for DALK are essentially identical to those routinely used for PK, it is not surprising that conventional DALK has failed to provide superior visual outcomes. In an attempt to maximize the refractive advantage of DALK, the use of grafts larger than the usual range between 7.5 mm and 8.5 mm has been proposed.<sup>[6]</sup>

However, since type 1 bubble formation is often limited within 7–8-mm optical zone, we prefer to combine large-diameter keratoplasty with limited stromal clearance within the central 6 mm.<sup>[23]</sup> Several investigators have likewise adopted limited stromal clearance for femtosecond laser-assisted DALK [Figure 1].<sup>[24,25]</sup>

When a perforation occurs during trephination, the site can be initially sutured before attempting pneumatic dissection. The sutured wound allows completion of the procedure because bubble formation typically does not extend as far as the 9-mm site of trephination. By considering the anatomy of the pre-Descemet layer,<sup>[26,27]</sup> restricting deep dissection to the central cornea reduces the risk of Descemet membrane perforation and conversion to PK.<sup>[28-30]</sup> If a microperforation occurs during lamellar dissection, the anterior chamber is filled with air to complete the DALK procedure. In cases in which there is either unsatisfactory clearance of the optical zone of a full-thickness opacity or a macroperforation of the DM, the procedure is converted to 2-piece microkeratome-assisted mushroom-shaped PK instead of full-thickness PK, according to the authors' previously described technique [Figure 2].<sup>[31]</sup> Briefly, after a 9-mm diameter anterior keratectomy is performed, the central 6-mm optical zone is excised, leaving a 1.5-mm posterior corneal crown of approximately 100- to 150-µm thickness. Using the automated lamellar keratoplasty system with a 350-µm microkeratome head, the donor cornea is split into anterior and posterior lamellae which are punched to the corresponding diameters of the recipient beds of 9 and 6 mm, respectively. The posterior lamellar graft is placed into the central hole of the recipient bed and attached without sutures onto the anterior lamellar graft which in turn is sutured in place with double-running sutures. Cases of postoperative double-anterior chamber formation following DALK or posterior lamella detachment following MK are managed with rebubbling of the anterior chamber with a complete filling of air, which is partially released after 2 h. Minimal endothelial transplantation in mushroom PK combines excellent visual and survival outcomes with a lower risk of immune rejection related to less antigenic load.<sup>[32]</sup>

With the use of deep trephination during large-diameter DALK, the success rate of pneumatic dissection can approach up to 85%.<sup>[33]</sup> Studies evaluating the factors for successful big-bubble formation have found that both increased trephination diameter and depth positively influence successful big-bubble formation.<sup>[34,35]</sup>

Complications such as double anterior chamber formation following DALK and detachment of the posterior lamella following two-piece mushroom PK can be managed by completely filling the anterior chamber with air and subsequently removing the air 2 h after.



**Figure 1:** Preoperative (a) and postoperative (b) photograph of a patient who underwent large-diameter deep anterior lamellar keratoplasty for herpetic scarring

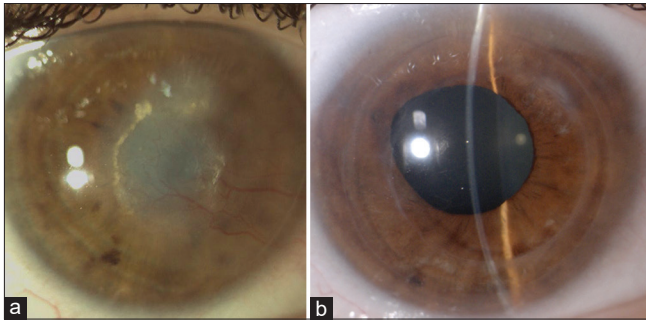
For patients with keratoconus, large lamellar grafts may have the additional advantage of extending more peripherally the excision of pathologic recipient stroma, thereby reducing the rate of the recurrence of ectasia.

The presence of a peripheral stromal shoulder also protects the recipient bed during suturing, which has been reported to cause up to 21% of intraoperative Descemet membrane perforations during conventional DALK surgery.<sup>[36]</sup> Remodeling of the peripheral stromal shoulder with loss of the step configuration at the 6.0-mm zone has been observed over time [Figure 3].<sup>[3,7]</sup>

Regardless of the disease severity or the presence of scarring and/or neovascularization, it is reasonable to attempt DALK than to have never given each patient with isolated anterior corneal pathology a fair chance to receive the better surgical option. In challenging cases including inflammatory corneal disease, herpetic keratitis,<sup>[37]</sup> intracorneal ring segments,<sup>[38]</sup> previous radial keratotomy,<sup>[39]</sup> anterior lamellar keratoplasty,<sup>[40,41]</sup> and even previous Descemet stripping automated endothelial keratoplasty (DSAEK) surgery,<sup>[42,43]</sup> large-diameter DALK can be performed to maximize the refractive benefit of a large-diameter graft while minimizing the risk of endothelial failure. In post-PK eyes with recurrence of stromal disease, large-diameter DALK can be performed through stromal peeling along a natural plane of separation.<sup>[44-46]</sup>

## Optimizing Visual Outcomes

In the past, surgical success following corneal transplantation was defined as the presence of a clear corneal graft.<sup>[47]</sup> Today, however, visual acuity is considered the primary criterion for surgical success. Based on some earlier comparative studies, it seemed that visual outcomes were less favorable following DALK. This was likely due to the inclusion of cases, which were not reflective of the contemporary surgical technique and cases with irregular or incomplete lamellar dissection.<sup>[48-50]</sup> Although randomized clinical trials are ideally required to make robust comparisons, designing trials that randomize patients to either PK



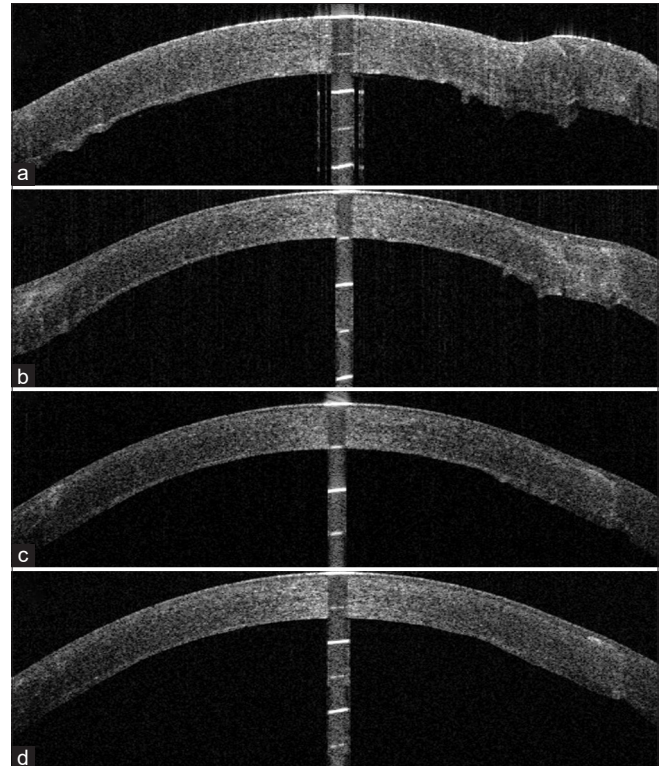
**Figure 2:** Preoperative (a) and postoperative (b) photograph of a patient who underwent two-piece mushroom keratoplasty following an unsuccessful deep anterior lamellar keratoplasty for herpetic scarring

or DALK can no longer be justified, especially in view of the disproportionately higher risk for potentially severe complications after PK. Nevertheless, empirical evidence from large interventional case series has thus far validated the clinical benefits of DALK.<sup>[6,9,11]</sup>

From a refractive standpoint, large-diameter DALK has been shown to provide superior visual outcomes with lower degrees of myopia and astigmatism.<sup>[6,23]</sup> In a series of 346 cases that underwent large-diameter DALK for keratoconus, 94% achieved Snellen vision  $\geq 20/40$  and up to 89% had a refractive astigmatism  $<4.5$  diopters postoperatively.<sup>[6]</sup>

In a retrospective interventional case series comparing 124 cases of large 9.0-mm DALK with 133 cases of conventional 8.0-mm DALK, the 9.0-mm DALK group had a significantly higher percentage of eyes achieving higher Snellen BSCVA levels of 20/20 or better (9.0-mm DALK: 44%, 8.0-mm DALK: 26%,  $P = 0.01$ ) and 20/25 or better (9.0-mm DALK: 74%, 8.0-mm DALK: 59%,  $P = 0.03$ ).<sup>[5]</sup> In the same comparative study, 9.0-mm DALK resulted in significantly lower degrees of astigmatism. The average postoperative refractive astigmatism in the 9.0 mm DALK group was 1 D lower than in the conventional 8.0-mm DALK group. High-degree astigmatism defined as refractive astigmatism  $>4.5$  D was observed in only 7% of cases.<sup>[5]</sup> These findings are consistent with a previous study by Huang *et al.* who demonstrated improved refractive outcomes when increasing the graft size of DALK from 8.0 mm to 8.5 mm.<sup>[36]</sup>

Postoperative refractive errors can be managed through corneal-based or lens-based interventions.<sup>[51]</sup> Incisional keratotomies, which can be performed manually or using the femtosecond laser, has been found to reduce astigmatism but with low refractive predictability.<sup>[52]</sup> An advantage to large-diameter DALK with limited central stromal clearance would be the ability to create deep arcuate blunt relaxing incisions within the graft–host interface which result in satisfactory



**Figure 3:** Anterior segment optical coherence tomography following large 9-mm diameter big-bubble deep anterior lamellar keratoplasty with limited stromal clearance of the optical zone showing the transition between the 6-mm central zone and the 9-mm outer zone with the residual recipient stroma. One day postoperatively, a peripheral stromal shoulder is clearly visible (a) but eventually disappears through spontaneous stromal thinning and remodeling of posterior corneal curvature 1 year (b), 2 years (c), and 4 years (d) after surgery

outcomes with minimal risk of perforation.<sup>[53]</sup> In the presence of a cataract, lens extraction with implantation of monofocal or even toric intraocular lenses can also be contemplated.<sup>[54,55]</sup>

### Leveraging Emerging Technologies

The use of anterior segment OCT has been explored to address the technical challenges associated with DALK.<sup>[56]</sup> Cross-sectional imaging can theoretically reduce the surgeon's dependence on subjective cues and influence intraoperative decision-making.<sup>[57]</sup> Whereas earlier external or microscope-mounted platforms necessitated the surgery to be interrupted for image acquisition, currently available microscope-integrated OCT platforms permit continuous real-time imaging of the anterior segment and allow instantaneous quantitative analysis of acquired OCT scans using a built-in caliper tool.<sup>[20,58]</sup> Quantitative analysis of intraoperative OCT scans can be used to assist decision-making on whether to proceed with pneumatic dissection or extend the trephination groove, thereby facilitating the insertion of the air injection cannula at the proper depth.<sup>[58]</sup> While intraoperative OCT theoretically provides improved visualization, further work is still needed to establish

and achieve the full potential of intraoperative OCT for intraoperative guidance of lamellar surgery.

Several investigators have also explored the use of femtosecond lasers for DALK surgery.<sup>[59-64]</sup> Customized trephination patterns can be created to theoretically provide superior wound strength, induce faster wound healing, and allow earlier suture removal.<sup>[59]</sup> The femtosecond laser system can also be used to create a deep intrastromal tunnel for the air injection cannula for pneumatic dissection.<sup>[60]</sup> However, one of the main drawbacks of femtosecond laser-assisted DALK is the poor laser penetration through opacified and neovascularized corneal tissue, which can result in incomplete or irregular dissection.<sup>[60]</sup> Although Li *et al.* demonstrated better visual outcomes after femtosecond laser-assisted DALK,<sup>[64]</sup> visual performance in the manual DALK group was poorer due to greater residual bed thickness obtained in diamond knife-assisted lamellar dissection. Moreover, all other published studies comparing manual and femtosecond laser-assisted DALK, thus far, consistently find no significant differences in the final visual acuity.<sup>[58-64]</sup> Randomized controlled trials based on sufficient sample size and standard protocol would be necessary to allow direct comparison and assessment of the true benefit of femtosecond laser technology for DALK.

## Conclusions

With its superior safety profile and favorable postoperative outcomes, current evidence supports that large-diameter DALK outperforms PK for the management of anterior corneal pathology sparing the endothelium. Large-diameter DALK with limited stromal clearance within the 6.0-mm optical zone optimizes visual and refractive outcomes while minimizing the risk of complications.

## Acknowledgments

Written consent was obtained from the patient for the surgery and participation in the study including the use of images.

## Data availability statement

Data sharing not applicable to this article as no datasets were generated or analyzed during the current study.

## Financial support and sponsorship

Nil.

## Conflicts of interest

The authors declare that there are no conflicts of interests of this paper.

## References

1. Eye Bank Association of America. 2019 Eye Banking Statistical Report. Available from: [https://restoresight.org/wp-content/](https://restoresight.org/wp-content/uploads/2020/04/2019-EBAA-Stat-Report-FINAL.pdf)

1. uploads/2020/04/2019-EBAA-Stat-Report-FINAL.pdf. [Last accessed on 2020 Nov 15].
2. Thanitcul C, Mathews P, Woreta FA, Akpek EK, Varadaraj V, Srikumaran D. Surgeon preference for keratoplasty techniques and barriers to performing deep anterior lamellar keratoplasty. *Cornea* 2021;40:1406-12.
3. Yu AC, Spena R, Pellegrini M, Bovone C, Busin M. Deep anterior lamellar keratoplasty: Current status and future directions. *Cornea* 2022;41:539-44.
4. Reinhart WJ, Musch DC, Jacobs DS, Lee WB, Kaufman SC, Shtein RM. Deep anterior lamellar keratoplasty as an alternative to penetrating keratoplasty a report by the American Academy of Ophthalmology. *Ophthalmology* 2011;118:209-18.
5. Lucisano A, Lionetti G, Yu AC, Giannaccare G, D'Angelo S, Busin M, *et al.* Outcomes of conventional 8.0-mm versus large 9.0-mm diameter deep anterior lamellar keratoplasty for keratoconus. *Cornea* 2023;42:815-20.
6. Myerscough J, Roberts H, Yu AC, Elkadim M, Bovone C, Busin M. Five-year outcomes of converted mushroom keratoplasty from intended deep anterior lamellar keratoplasty (DALK) mandate 9-mm diameter DALK as the optimal approach to keratoconus. *Am J Ophthalmol* 2020;220:9-18.
7. Pellegrini M, Yu AC, Busin M. Deep anterior lamellar keratoplasty for keratoconus: Elements for success. *Saudi J Ophthalmol* 2022;36:36-41.
8. Arundhati A, Chew MC, Lim L, Mehta JS, Lang SS, Htoon HM, *et al.* Comparative study of long-term graft survival between penetrating keratoplasty and deep anterior lamellar keratoplasty. *Am J Ophthalmol* 2021;224:207-16.
9. Borderie VM, Sandali O, Bullet J, Gaujoux T, Touzeau O, Laroche L. Long-term results of deep anterior lamellar versus penetrating keratoplasty. *Ophthalmology* 2012;119:249-55.
10. Ho D, Chai C, Lin H, Htoon HM, Tan AM, Manotosh R, *et al.* Optical and tectonic corneal transplant outcomes in a tertiary hospital in Singapore within the Singapore corneal transplant registry. *Ann Acad Med Singap* 2018;47:92-100.
11. Pellegrini M, Scorgia V, Giannaccare G, Lucisano A, Vaccaro S, Battaglia C, *et al.* Corneal neovascularisation following deep anterior lamellar keratoplasty for corneal ectasia: Incidence, timing and risk factors. *Br J Ophthalmol* 2022;106:1363-7.
12. Giannaccare G, Weiss JS, Sapiigni L, Bovone C, Mattioli L, Campos EC, *et al.* Immunologic stromal rejection after deep anterior lamellar keratoplasty with grafts of a larger size (9 mm) for various stromal diseases. *Cornea* 2018;37:967-72.
13. Archila EA. Deep lamellar keratoplasty dissection of host tissue with intrastromal air injection. *Cornea* 1984;3:217-8.
14. Anwar M, Teichmann KD. Big-bubble technique to bare Descemet's membrane in anterior lamellar keratoplasty. *J Cataract Refract Surg* 2002;28:398-403.
15. Sugita J, Kondo J. Deep lamellar keratoplasty with complete removal of pathological stroma for vision improvement. *Br J Ophthalmol* 1997;81:184-8.
16. Manche EE, Holland GN, Maloney RK. Deep lamellar keratoplasty using viscoelastic dissection. *Arch Ophthalmol* 1999;117:1561-5.
17. Nanavaty MA, Vijjan KS, Yvon C. Deep anterior lamellar keratoplasty: A surgeon's guide. *J Curr Ophthalmol* 2018;30:297-310.
18. Scorgia V, Lucisano A, Pietropaolo R, Savoca Corona V, Scorgia G, Busin M. Red reflex-guided big-bubble deep anterior lamellar keratoplasty: A simple technique to judge dissection depth. *Cornea* 2015;34:1035-8.
19. Busin M, Scorgia V, Leon P, Nahum Y. Outcomes of air injection within 2 mm inside a deep trephination for deep anterior lamellar keratoplasty in eyes with keratoconus. *Am J Ophthalmol* 2016;164:6-13.

20. Scorcio V, Busin M, Lucisano A, Beltz J, Carta A, Scorcio G. Anterior segment optical coherence tomography-guided big-bubble technique. *Ophthalmology* 2013;120:471-6.
21. Yu AC, Mattioli L, Busin M. Optimizing outcomes for keratoplasty in ectatic corneal disease. *Curr Opin Ophthalmol* 2020;31:268-75.
22. Bovone C, Myerscough J, Friehmann A, Elkadim M, Parmeggiani F, Busin M. Peripheral intrastromal hydration facilitates safe, deep trephination in corneas of irregular thickness. *Cornea* 2020;39:207-9.
23. Busin M, Leon P, Nahum Y, Scorcio V. Large (9 mm) deep anterior lamellar keratoplasty with clearance of a 6-mm optical zone optimizes outcomes of keratoconus surgery. *Ophthalmology* 2017;124:1072-80.
24. Shehadeh-Mashor R, Chan CC, Bahar I, Lichtinger A, Yeung SN, Rootman DS. Comparison between femtosecond laser mushroom configuration and manual trephine straight-edge configuration deep anterior lamellar keratoplasty. *Br J Ophthalmol* 2014;98:35-9.
25. Gadhvi KA, Romano V, Fernández-Vega Cueto L, Aiello F, Day AC, Gore DM, *et al.* Femtosecond laser-assisted deep anterior lamellar keratoplasty for keratoconus: Multi-surgeon results. *Am J Ophthalmol* 2020;220:191-202.
26. Dua HS, Faraj LA, Kenawy MB, AlTaan S, Elalfy MS, Katamish T, *et al.* Dynamics of big bubble formation in deep anterior lamellar keratoplasty by the big bubble technique: *in vitro* studies. *Acta Ophthalmol* 2018;96:69-76.
27. AlTaan SL, Mohammed I, Said DG, Dua HS. Air pressure changes in the creation and bursting of the type-1 big bubble in deep anterior lamellar keratoplasty: An *ex vivo* study. *Eye (Lond)* 2018;32:146-51.
28. Myerscough J, Friehmann A, Bovone C, Mimouni M, Busin M. Management of type 2 bubble formed during big-bubble deep anterior lamellar keratoplasty. *Cornea* 2019;38:e20.
29. Myerscough J, Friehmann A, Bovone C, Mimouni M, Busin M. Evaluation of the risk factors associated with conversion of intended deep anterior lamellar keratoplasty to penetrating keratoplasty. *Br J Ophthalmol* 2020;104:764-7.
30. Myerscough J, Bovone C, Mimouni M, Elkadim M, Rimondi E, Busin M. Factors predictive of double anterior chamber formation following deep anterior lamellar keratoplasty. *Am J Ophthalmol* 2019;205:11-6.
31. Yu AC, Friehmann A, Myerscough J, Socea S, Furioli L, Giannaccare G, *et al.* Initial high-dose prophylaxis and extended taper for mushroom keratoplasty in vascularized herpetic scars. *Am J Ophthalmol* 2020;217:212-23.
32. Yu AC, Spena R, Fusco F, Dondi R, Myerscough J, Fabbri F, *et al.* Long-term outcomes of two-piece mushroom keratoplasty for traumatic corneal scars. *Am J Ophthalmol* 2022;236:20-31.
33. Scorcio V, Giannaccare G, Lucisano A, Soda M, Scalzo GC, Myerscough J, *et al.* Predictors of bubble formation and type obtained with pneumatic dissection during deep anterior lamellar keratoplasty in keratoconus. *Am J Ophthalmol* 2020;212:127-33.
34. Borderie VM, Touhami S, Georgeon C, Sandali O. Predictive factors for successful type 1 big bubble during deep anterior lamellar keratoplasty. *J Ophthalmol* 2018;2018:4685406.
35. Feizi S, Javadi MA, Daryabari SH. Factors influencing big-bubble formation during deep anterior lamellar keratoplasty in keratoconus. *Br J Ophthalmol* 2016;100:622-5.
36. Huang OS, Htoon HM, Chan AM, Tan D, Mehta JS. Incidence and outcomes of intraoperative descemet membrane perforations during deep anterior lamellar keratoplasty. *Am J Ophthalmol* 2019;199:9-18.
37. Pellegrini M, Yu AC, Spena R, Bovone C, Zauli G, Busin M. Outcomes of large-diameter deep anterior lamellar keratoplasty and converted two-piece mushroom penetrating keratoplasty for herpetic corneal scars. *Eye (Lond)* 2023; [Online ahead of print]. [doi: 10.1038/s41433-023-02744-0].
38. Ravera V, Bovone C, Scorcio V, D'Angelo S, Busin M. Deep anterior lamellar keratoplasty in eyes with intrastromal corneal ring segments. *Cornea* 2019;38:642-4.
39. Pellegrini M, Yu AC, Busin M. Large-diameter modified big-bubble deep anterior lamellar keratoplasty in post-radial keratotomies. *Am J Ophthalmol* 2023;251:1-4.
40. Yu AC, Myerscough J, Galante G, Furioli L, Socea S, Bovone C, *et al.* Pneumatic dissection for large-diameter (9-mm) deep anterior lamellar keratoplasty in eyes with previous anterior lamellar keratoplasty. *Cornea* 2021;40:1098-103.
41. Panthagani J, Law EM, Chipeta C, Roberts H, Myerscough J. High astigmatism after conventional diameter deep anterior lamellar keratoplasty in keratoconus can be successfully managed with repeat wide diameter deep anterior lamellar keratoplasty. *Cornea* 2023;42:1057-61.
42. Gutfreund S, Leon P, Graffi S, Busin M. Deep anterior lamellar keratoplasty after descemet stripping automated endothelial keratoplasty. *Am J Ophthalmol* 2017;175:129-36.
43. Busin M, Beltz J. Deep anterior lamellar keratoplasty after descemet stripping automated endothelial keratoplasty. *Cornea* 2011;30:1048-50.
44. Bovone C, Nahum Y, Scorcio V, Giannaccare G, Spena R, Myerscough J, *et al.* Stromal peeling for deep anterior lamellar keratoplasty in post-penetrating keratoplasty eyes. *Br J Ophthalmol* 2022;106:336-40.
45. Busin M, Bovone C, Scorcio V, Rimondi E, Nahum Y, Myerscough J, *et al.* Ultrastructural alterations of grafted corneal buttons: The anatomic basis for stromal peeling along a natural plane of separation. *Am J Ophthalmol* 2021;231:144-53.
46. Scorcio V, Giannaccare G, Pellegrini M, Camposampiero D, Ponzin D, Yu AC, *et al.* Stromal peeling for deep anterior lamellar keratoplasty in a post-penetrating keratoplasty eye with hematoconus. *Am J Ophthalmol Case Rep* 2023;29:101808.
47. Cornea Donor Study Investigator Group, Gal RL, Dontchev M, Beck RW, Mannis MJ, Holland EJ, *et al.* The effect of donor age on corneal transplantation outcome results of the cornea donor study. *Ophthalmology* 2008;115:620-6.e6.
48. Shimazaki J, Shimmura S, Ishioka M, Tsubota K. Randomized clinical trial of deep lamellar keratoplasty versus penetrating keratoplasty. *Am J Ophthalmol* 2002;134:159-65.
49. Funnell CL, Ball J, Noble BA. Comparative cohort study of the outcomes of deep lamellar keratoplasty and penetrating keratoplasty for keratoconus. *Eye (Lond)* 2006;20:527-32.
50. Ardjomand N, Hau S, McAlister JC, Bunce C, Galaretta D, Tuft SJ, *et al.* Quality of vision and graft thickness in deep anterior lamellar and penetrating corneal allografts. *Am J Ophthalmol* 2007;143:228-35.
51. Alfonso-Bartolozzi B, Martínez-Alberquilla I, Baamonde B, Fernández-Vega-Cueto L, Alfonso JF, Madrid-Costa D. Refractive surgery after deep anterior lamellar keratoplasty: A review of the literature. *Int Ophthalmol* 2023;43:1413-35.
52. Kubaloglu A, Coskun E, Sari ES, Guneş AS, Cinar Y, Piñero DP, *et al.* Comparison of astigmatic keratotomy results in deep anterior lamellar keratoplasty and penetrating keratoplasty in keratoconus. *Am J Ophthalmol* 2011;151:637-43.e1.
53. Elkadim M, Myerscough J, Bovone C, Busin M. A novel blunt dissection technique to treat modified deep anterior lamellar keratoplasty (DALK)-associated high astigmatism. *Eye (Lond)* 2020;34:1432-7.
54. Pellegrini M, Furioli L, Yu AC, Giannaccare G, Scuteri G, Gardeli I, *et al.* Outcomes of cataract surgery with toric intraocular lens implantation after keratoplasty. *J Cataract Refract Surg* 2022;48:157-61.
55. Pellegrini M, Furioli L, Salgari N, D'Angelo S, Zauli G, Yu AC, *et al.* Accuracy of intraocular lens power calculation for cataract surgery after deep anterior lamellar keratoplasty. *Clin Exp Ophthalmol* 2022;50:17-22.
56. Ehlers JP, Dupps WJ, Kaiser PK, Goshe J, Singh RP, Petkovsek D, *et al.* The prospective intraoperative and perioperative ophthalmic

- Imaging with optical Coherence Tomography (PIONEER) study: 2-year results. *Am J Ophthalmol* 2014;158:999-1007.
57. De Benito-Llopis L, Mehta JS, Angunawela RL, Ang M, Tan DT. Intraoperative anterior segment optical coherence tomography: A novel assessment tool during deep anterior lamellar keratoplasty. *Am J Ophthalmol* 2014;157:334-41.e3.
  58. Santorum P, Yu AC, Bertelli E, Busin M. Microscope-integrated intraoperative optical coherence tomography-guided big-bubble deep anterior lamellar keratoplasty. *Cornea* 2022;41:125-9.
  59. Farid M, Steinert RF. Deep anterior lamellar keratoplasty performed with the femtosecond laser zigzag incision for the treatment of stromal corneal pathology and ectatic disease. *J Cataract Refract Surg* 2009;35:809-13.
  60. Lucisano A, Giannaccare G, Pellegrini M, Bernabei F, Yu AC, Carnevali A, *et al.* Preliminary results of a novel standardized technique of femtosecond laser-assisted deep anterior lamellar keratoplasty for keratoconus. *J Ophthalmol* 2020;2020:5496162.
  61. Salouti R, Zamani M, Ghoreyshi M, Dapena I, Melles GR, Nowroozzadeh MH. Comparison between manual trephination versus femtosecond laser-assisted deep anterior lamellar keratoplasty for keratoconus. *Br J Ophthalmol* 2019;103:1716-23.
  62. Blériot A, Martin E, Lebranchu P, Zimmerman K, Libeau L, Weber M, *et al.* Comparison of 12-month anatomic and functional results between Z6 femtosecond laser-assisted and manual trephination in deep anterior lamellar keratoplasty for advanced keratoconus. *J Fr Ophtalmol* 2017;40:e193-200.
  63. Alio JL, Abdelghany AA, Barraquer R, Hammouda LM, Sabry AM. Femtosecond laser assisted deep anterior lamellar keratoplasty outcomes and healing patterns compared to manual technique. *Biomed Res Int* 2015;2015:397891.
  64. Li S, Wang T, Bian J, Wang F, Han S, Shi W. Precisely controlled side cut in femtosecond laser-assisted deep lamellar keratoplasty for advanced keratoconus. *Cornea* 2016;35:1289-94.