

Optimizing the Aesthetic Result of Parotidectomy with a Facelift Incision and Temporoparietal Fascia Flap

Kiya Movassaghi, MD, DMD†
 Matthew Lewis, MD, MS*
 Farooq Shahzad, MBBS, FACS*‡
 James W. May, Jr., MD†

Summary: The 3 most common problems after a parotidectomy are cheek contour deformity, Frey syndrome (gustatory sweating), and a visible scar on the neck. These problems can potentially be prevented by (1) facelift type incisions, which eliminate the neck incision and (2) interposition of temporoparietal fascia at the parotidectomy site that fills the defect and provides a barrier to aberrant neuronal regeneration. We followed 11 patients who underwent parotidectomy (9 superficial and 2 total parotidectomies) for a variety of parotid tumors between December 2001 and January 2018. Facelift type incisions were used in all patients, and temporoparietal fascia flaps were used to fill the parotidectomy defects. The last 6 patients were tested for objective evidence of Frey syndrome with the Minor Starch Iodine test. Patients were then followed for up to 7 years (11 months to 7 years, average 3 years). All patients had well-hidden scars and good contour of the cheeks. None of the patients developed subjective or objective evidence of Frey syndrome. This small series suggests that the aesthetic result after parotidectomy can be improved by using a facelift incision and placement of a temporoparietal fascia flap into the parotidectomy defect. Additionally, the tissue barrier thus provided may also help to prevent Frey syndrome. (*Plast Reconstr Surg Glob Open* 2019;7:e2067; doi: 10.1097/GOX.0000000000002067; Published online 8 February 2019.)

Parotidectomy is used for the treatment of a variety of parotid and nonparotid pathologies. Three common complications associated with traditional parotidectomy are a visible neck scar, facial contour deformity, and Frey syndrome (gustatory sweating). Sialoceles and salivary fistula are also relatively common complications following parotidectomy, occurring in 4–14% of cases,^{1,2} but these complications were not a primary focus of our study, given that they are usually self-limited and can be treated conservatively.

The standard parotidectomy approach is via a preauricular incision with an extension into the neck (Blair incision). Although the preauricular part of the incision is inconspicuous, the neck incision is visible. Facelift inci-

sions have been shown to provide excellent parotidectomy access while obviating the need for a neck incision.^{3–11} Parotid gland resection results in cheek volume loss leading to facial asymmetry. Multiple methods have been described to fill the parotidectomy defect and restore this volume.^{12–14} These include the sternocleidomastoid flap, SMAS flap, temporoparietal fascia flap (TPFF), temporalis muscle flap, free abdominal fat transfer/fat grafting, to name a few. The TPFF is a good source of thin, pliable, durable, and well-vascularized tissue that can be elevated through the parotidectomy incision and is based on the superficial temporal vessels.

Frey syndrome is a condition in which the act of mastication causes sweating, erythema, and pain in the cheek at the parotidectomy site.¹⁵ In 1923, Frey described a case of gustatory sweating following a parotid gland bullet injury. The condition is thought to occur due to aberrant regeneration of transected neurons.¹⁶ The auriculotem-

From the*Department of Surgery, Division of Plastic Surgery, Oregon Health & Science University, Portland, Ore.; †Massachusetts General Hospital, Harvard Medical School, Boston, Mass.; and ‡Department of Surgery, Division of Plastic Surgery, Northwestern University, Chicago, Ill.

Received for publication September 11, 2018; accepted October 19, 2018.

Copyright © 2019 The Authors. Published by Wolters Kluwer Health, Inc. on behalf of The American Society of Plastic Surgeons. This is an open-access article distributed under the terms of the Creative Commons Attribution-Non Commercial-No Derivatives License 4.0 (CCBY-NC-ND), where it is permissible to download and share the work provided it is properly cited. The work cannot be changed in any way or used commercially without permission from the journal.

DOI: 10.1097/GOX.0000000000002067

Disclosure: Dr. Movassaghi is a clinical advisor/speaker for Allergan, consultant/speaker for Sientra, consultant for Cypris Medical, speaker for Bard, and speaker/advisor for Surgical Specialties. Dr. May is a scientific consultant with Integra and educational consultant for J&J / Mentor.

Supplemental digital content is available for this article. Clickable URL citations appear in the text.

Table 1. Patient Demographics, Diagnosis, and Treatment Data

Total study patients		11
Age (y)	39–78	
Sex	7 Female 4 Male	
Follow-up	Shortest—11 mo Longest—7 y Mean—3 y	
Parotid operation	Superficial—9 Total—2	
Adjuvant treatments	Radiation—2 Chemo—2	
Simultaneous operations	Rhytidectomy—3	
TPFF size (cm)	Smallest—6×3 Largest—10×8	
Pathology	Pleomorphic adenoma—5 Warthin’s tumor—2 Focal chronic sialoadenitis—1 Benign parotid cyst—1 Metastatic angiosarcoma—1 Acinic cell carcinoma - 1	

poral nerve carries both sympathetic nerve fibers to the sweat glands of the face and parasympathetic fibers to the parotid gland. During parotidectomy, both types of fibers are transected. As the nerves regenerate, the parasympathetic fibers join the distal transected ends of the sympathetic fibers. Thus, stimulation of the parasympathetic fibers of the parotid gland, as occurs during mastication, results in activation of sympathetic fibers of the facial skin causing gustatory sweating. Various methods have been described to treat Frey syndrome. Topical anticholinergics

like glycopyrolate¹⁷ and scopolamine¹⁸ control symptoms, but their use is limited by side effects and development of tolerance. Botox injected locally has also shown to be effective, but injections have to be repeated periodically.¹⁹ Surgical techniques aim to place a barrier between the parotid bed and overlying skin to prevent aberrant neuronal regeneration. Innumerable vascularized and nonvascularized tissues and biomaterials have been used for this purpose.^{20–28} These interposition techniques not only decrease the incidence of Frey syndrome, they also decrease the postparotidectomy contour deformity. We endeavored to study the effectiveness of using a TPF in conjunction with a facelift incision in reducing scar visibility, cheek contour deformity and the incidence of Frey syndrome following parotidectomy.

PATIENTS

Eleven consecutive patients underwent parotidectomy for various tumors (Table 1). Fine needle aspiration (FNA) was performed preoperatively in any patient in whom there was suspicion for carcinoma. Facelift incisions and TPFs were used in all patients. A concomitant facelift was performed in 3 patients. Postoperatively, patients were followed for up to 7 years. All patients gave written consent to be included in this study.

OPERATIVE TECHNIQUE

A facelift incision with temporal extension is made in the following manner: starting in the temporal

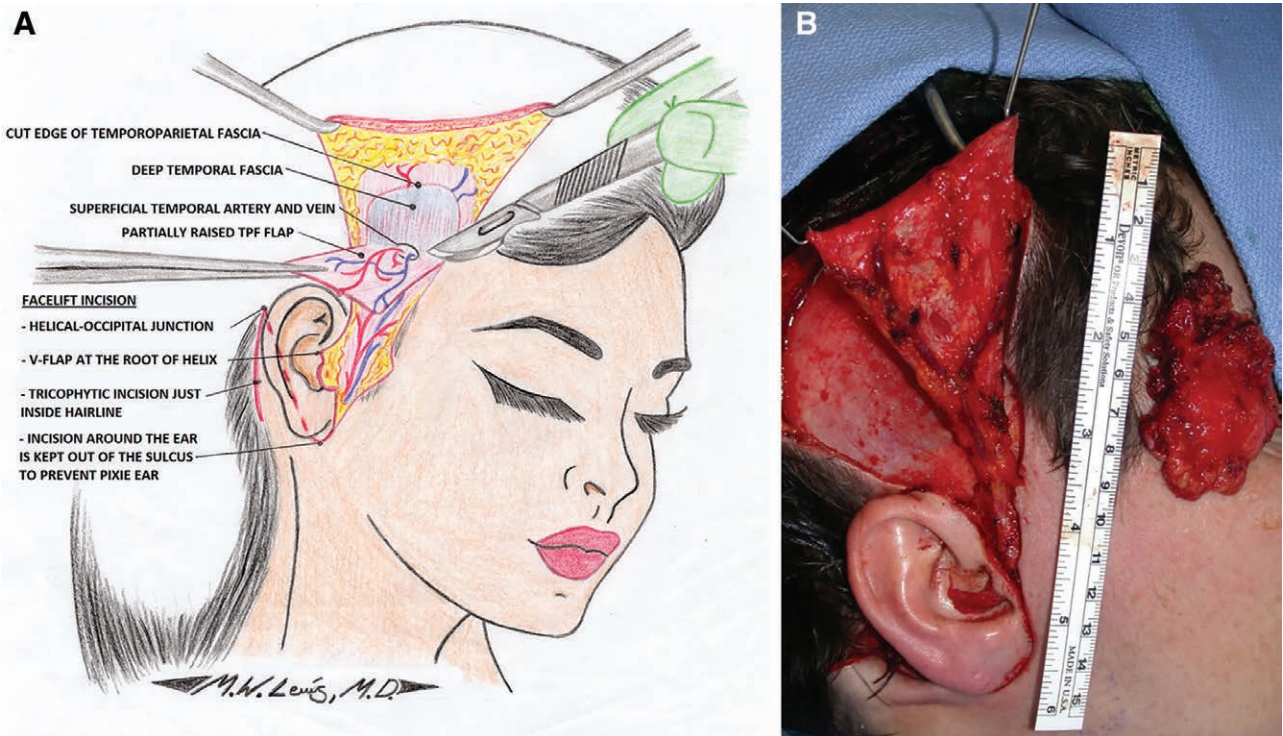


Fig. 1. A, Surgical marking for parotidectomy and temporoparietal fascia flap. TPF shown partially elevated. B, Intraoperative photograph demonstrating TPF elevated off the deep temporal fascia and superficial parotid specimen laying on patient’s temple (superficial temporal artery well demonstrated).

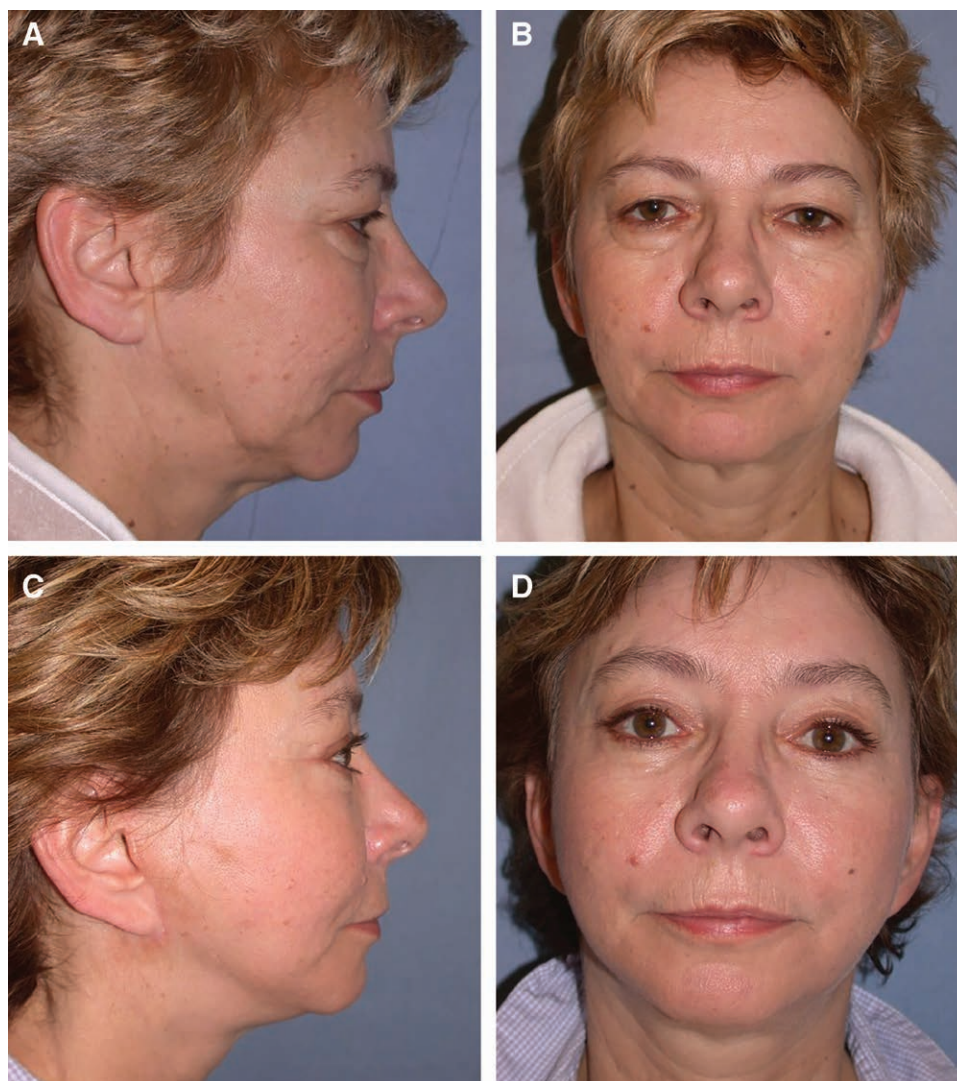

Fig. 2. A, B, Preoperative pictures of a 52-year-old patient with aging features and right Warthin's tumor. C, D, 7-year postoperative photographs following endoscopic brow lift, upper and lower blepharoplasty, right superficial parotidectomy with SMAS plication rhytidectomy and TPF, left SMASectomy rhytidectomy.

hair-bearing area extending down to the ear and then around the root of the helix before turning to form a small V-flap between the root of helix and tragus and then extending along the tragal edge to the lobule. The incision is then taken around the lobule staying 2mm below the lobule. The incision is then carried up behind the ear to the helical-occipital junction obliquely before making a right angle and coming back down just inside the occipital hairline. The incision along the occipital hairline is done in a sharply beveled "trichophytic" manner to allow hair to eventually grow through the scar. We used this incision technique in all patients without compromising surgical exposure (Fig. 1). Concomitant facelift was only performed in patients with proven benign tumors, and in these patients the operation was started on the side without parotid pathology and closed before switching sides to avoid contamination of the contralateral surgical field.

In the preauricular area, the skin flap was raised at the sub-SMAS level. The parotidectomy was done with standard technique, identifying all the facial nerve branches in an antegrade fashion.²⁹ In all the patients, the TPF was used to restore volume loss and help to prevent Frey syndrome. In the temporal region, a full-thickness flap was elevated anteriorly and posteriorly such that an adequately sized TPF was raised. If the contour requires increased volume, a larger flap can be taken and enfolded to increase volume correction. Care was taken to raise any hair-bearing skin just deep to the follicles to avoid alopecia. Flap dissection was limited anteriorly to 1 cm behind Pitanguy's line, which indicates the position of the frontal branch of the facial nerve.³⁰ In all cases, the flap easily covered the whole parotid bed including the retromandibular area where the postparotidectomy deformity commonly occurs.

TESTING FOR FREY SYNDROME

Six patients were tested for objective evidence of Frey syndrome with the Minor Starch Iodine test.³¹ In this method, iodine solution is applied to the parotidectomy-sided cheek and allowed to dry before being powdered with corn starch. The patient is then asked to chew on a lemon candy. A positive result occurs when the brown iodine color turns dark purple as an iodine-starch complex forms in the aqueous medium of sweat (see figure, **Supplemental Digital Content 1**, which displays the Positive Minor Starch Iodine test in a patient with traditional parotidectomy but no TPFF. (a) before sucking on lemon candy; (b) after sucking on lemon candy, <http://links.lww.com/PRSGO/A958>).

RESULTS

Good cheek contour and facial symmetry were achieved in 10 of the 11 patients. One patient underwent total parotidectomy and postoperative radiation therapy for acinic cell carcinoma. Although this patient had good cheek contour postoperatively, at long-term follow-up there was a slight depression. Patients who undergo larger resections or radiation therapy could benefit from a TPFF combined with other flaps. The skin incisions were inconspicuous in all patients. None of the patients complained of gustatory sweating or had objective evidence of subclinical Frey syndrome by Minor Starch Iodine test. None of the patients developed sialocele or salivary fistula. Three of our patients desired a formal facelift at the time of parotid surgery and all were extremely pleased with their result (Fig. 2). Combining a formal facelift is thus another way to improve facial symmetry and the aesthetic outcome in patients with proven benign parotid masses.

CONCLUSION

Patient satisfaction following parotidectomy can be improved by the use of facelift incisions and interposition of TPFFs.

Matthew Lewis, MD, MS
Lewis Plastic Surgery
10201 SE. Main Street
Suite 20
Portland, OR 97216
E-mail: matthewlewismd@gmail.com

REFERENCES

1. Wax M, Tarshis L. Post-parotidectomy fistula. *J Otolaryngol*. 1991;20:10–13.
2. Laskawi R, Schott T, Mirzaie-Petri M, et al. Surgical management of pleomorphic adenomas of the parotid gland: a follow-up study of three methods. *J Oral Maxillofac Surg*. 1996;54:1176–1179.
3. Chen W, Li J, Yang Z, et al. SMAS fold flap and ADM repair of the parotid bed following removal of parotid haemangiomas via pre- and retroauricular incisions to improve cosmetic outcome and prevent Frey's syndrome. *J Plast Reconstr Aesthet Surg*. 2008;61:894–899; discussion 899–900.
4. Amin A, Mustafa A, Nabawi A, et al. Parotidectomy for benign parotid tumors: an aesthetic approach. *Oral Oncology Suppl*. 2009;3:131.
5. Terris DJ, Tuffo KM, Fee WE Jr. Modified facelift incision for parotidectomy. *J Laryngol Otol*. 1994;108:574–578.
6. Nouraei SA, Al-Yaghchi C, Ahmed J, et al. An anatomical comparison of Blair and facelift incisions for parotid surgery. *Clin Otolaryngol*. 2006;31:531–534.
7. Grover N, D'Souza A. Facelift approach for parotidectomy: an evolving aesthetic technique. *Otolaryngol Head Neck Surg*. 2013;148:548–556.
8. Keqian Z, Wenhao R, Ling G, et al. Face-lift incision combined with a sternomastoid muscular flap in parotidectomy. *Aesthetic Plast Surg*. 2011;35:558–562.
9. Bianchi B, Ferri A, Ferrari S, et al. Improving esthetic results in benign parotid surgery: statistical evaluation of facelift approach, sternocleidomastoid flap, and superficial musculoaponeurotic system flap application. *J Oral Maxillofac Surg*. 2011;69:1235–1241.
10. Dabrowska-Bieñ J, Pietniczka-Zaleska M, Rowicki T. [Facelift incision parotidectomy: preliminary report]. *Otolaryngol Pol*. 2009;63:485–489.
11. Appiani E, Delfino MC. Plastic incisions for facial and neck tumors. *Ann Plast Surg*. 1984;13:335–352.
12. Curry JM, King N, Reiter D, et al. Meta-analysis of surgical techniques for preventing parotidectomy sequelae. *Arch Facial Plast Surg*. 2009;11:327–331.
13. Dell'aversana Orabona G, Salzano G, Petrocelli M, et al. Reconstructive techniques of the parotid region. *J Craniofac Surg*. 2014;25:998–1002.
14. Loyo M, Gourin CG. Free abdominal fat transfer for partial and total parotidectomy defect reconstruction. *Laryngoscope (United States)*. 2016;126:p2694–2698.
15. Nicolai J-PA. An early account of gustatory sweating (Frey syndrome): a chance observation 250 years ago. *Br J Plast Surg*. 1985;38:122.
16. Ford FR, Woodhall B. Phenomena due to misdirection of regenerating fibers of cranial, spinal and autonomic nerves; clinical observations. *Arch Surg*. 1938;36:480.
17. May JS, McGuirt WF. Frey's syndrome: treatment with topical glycopyrrolate. *Head Neck*. 1989;11:85–89.
18. Bednarek J, Reid W, Matsumoto T. Frey's syndrome. *Am J Surg*. 1976;131:592–594.
19. de Bree R, Duyndam JE, Kuik DJ, et al. Repeated botulinum toxin type A injections to treat patients with Frey syndrome. *Arch Otolaryngol Head Neck Surg*. 2009;135:287–290.
20. Wang S, Li L, Chen J, et al. Effects of free fat grafting on the prevention of Frey's syndrome and facial depression after parotidectomy: a prospective randomized trial. *Laryngoscope*. 2016;126:815–819.
21. Fasolis M, Zavatiero E, Iaguinta C, et al. Dermofat graft after superficial parotidectomy to prevent Frey syndrome and depressed deformity. *J Craniofac Surg*. 2013;24:1260–1262.
22. Yoo YM, Lee JS, Park MC, et al. Dermofat graft after superficial parotidectomy via a modified face-lift incision to prevent Frey syndrome and depressed deformity. *J Craniofac Surg*. 2011;22:1021–1023.
23. Ye WM, Zhu HG, Zheng JW, et al. Use of allogenic acellular dermal matrix in prevention of Frey's syndrome after parotidectomy. *Br J Oral Maxillofac Surg*. 2008;46:649–652.
24. Li C, Yang X, Pan J, et al. Graft for prevention of Frey syndrome after parotidectomy: a systematic review and meta-analysis of randomized controlled trials. *J Oral Maxillofac Surg*. 2013;71:419–427.
25. Barberá R, Castillo F, D'Oleo C, et al. Superficial musculoaponeurotic system flap in partial parotidectomy and clinical and subclinical Frey's syndrome. Cosmesis and quality of life. *Head Neck*. 2014;36:130–136.

26. Dai XM, Liu H, Li YS, et al. Prevention of Frey syndrome with temporal fascia flap in parotidectomy. *Ann Plast Surg.* 2015;75:610–614.
27. Sanabria A, Kowalski LP, Bradley PJ, et al. Sternocleidomastoid muscle flap in preventing Frey's syndrome after parotidectomy: a systematic review. *Head Neck.* 2012;34:589–598.
28. Okamura H, Sasaki H, Yanagihara N. Surgical treatment of Frey syndrome by implantation of lyophilized human dura. *Otolaryngol.* 1982;54:224.
29. Beahrs OH. The surgical anatomy and technique of parotidectomy. *Surg Clin North Am.* 1977;57:477–493.
30. Pitanguy I, Ramos AS. The frontal branch of the facial nerve: the importance of its variations in face lifting. *Plast Reconstr Surg.* 1966;38:352.
31. Minor V. Eines neues verfahren zu der klinsichen untersugung der scheissabsonderung. *Dtsch Z Nervenhe.* 1928;101:258–261.