



Contents lists available at ScienceDirect

International Journal of Surgery Case Reports

journal homepage: www.casereports.com

A case report of incarcerated inguinal hernia: Amyand's hernia with adenocarcinoma tumor

Michele Fiordaliso*, Shadi Ahmad, Sladana Simic, Hisham Zoubi, Mevlüt Karaorman

Department of Surgery, Erbach General Hospital, Germany

ARTICLE INFO

Article history:

Received 11 February 2021
 Received in revised form 28 February 2021
 Accepted 28 February 2021
 Available online 3 March 2021

Keywords:

Amyand's hernia
 Adenocarcinoma of the appendix
 Inguinal hernia
 Right hemicolectomy

ABSTRACT

INTRODUCTION: Inguinal hernia is one of the most common surgical problems, often posing technical challenges even to expert surgeons. Amyand's hernia (AH) is an inguinal hernia whose sac contains the vermiform appendix. Primary appendiceal neoplasms are rare. We report the case of an appendiceal adenocarcinoma within an Amyand's hernia, presenting as an incarcerated right inguinal hernia.

PRESENTATION OF CASE: A 87-year-old male presented in the emergency department due to a persistent right inguinal pain. Clinical examination revealed a tender right groin mass. Under the diagnosis of an right inguinal hernia, an operation was taken. Intraoperatively, an inflamed appendix and a part of the cecum were found in the hernia sac. The operation was completed with an ileocecal resection and a modified Bassini hernia repair. Histological examination revealed a adenocarcinoma of the appendix.

DISCUSSION: Amyand's hernia is an inguinal hernia that contains vermiform appendix in its sac. It consists 1% of all inguinal hernias while appendicitis in an Amyand's hernia accounts for 0.1% of all appendicitis cases. Adenocarcinomas of the appendix are even rarer, accounting for 0.2% to 0.5% of all intestinal malignancies, and 4%–6% of primary appendiceal neoplasms. Diagnosis is usually established intraoperatively.

CONCLUSION: A malignancy of the appendix should always be in the differential diagnosis of a right inguinal mass, in order to provide optimum surgical treatment.

© 2021 The Author(s). Published by Elsevier Ltd on behalf of IJS Publishing Group Ltd. This is an open access article under the CC BY-NC-ND license (<http://creativecommons.org/licenses/by-nc-nd/4.0/>).

1. Introduction

Primary appendiceal neoplasms are rare, and most (about 85%) are carcinoids [1]. These follow a benign course, but are considered malignant because they have the potential for invasion and metastases [2]. Adenocarcinomas of the appendix are even rarer, accounting for 0.2% to 0.5% of all intestinal malignancies, and 4%–6% of primary appendiceal neoplasms [3,4]. Most patients are asymptomatic, and that is why they are mostly found incidentally in appendectomy specimens.

Clinical manifestations often mimic those of an incarcerated right inguinal hernia, rendering the correct preoperative diagnosis very difficult. Diagnosis is, in the majority of cases, intrasurgical. A clinical diagnosis is made difficult by the fact that in asymptomatic cases, there is no indication that could lead to think of such positioning of the appendix.

The work has been reported in line with the SCARE 2020 checklist [5].

2. Case presentation

An 87 years old male patient presented in our surgical emergency department complaining from a 2 week protruding bulge accompanied with pain in the right groin. The patient denied any vomiting or nausea. Regarding the history of the patient, he had no problems with defecation or micturition. A colonoscopy was last done before 8 weeks and it was significant for a generalized diverticulosis within the whole colon. Due to atrial fibrillation the patient is on oral anticoagulant therapy. Clinical examination revealed a clear right sided inguinal hernia. The mass was tender by palpation. The leucocyte count was $14 \times 10^9/L$. The failure to reduce the hernie suggested an entrapment/incarceration with a high strangulation tendency. To prevent lasting damage to the affected tissue and after optimizing homeostasis, we arranged an hernioplasty operation within 24 h. During the operation it showed a pantaloon type of inguinal hernia. The hernial sac was found and opened, surprisingly the appendix was within the sac contents (Fig. 1). Beside that was detected a complete wall thickening of the Appendix including the base and proximal coecum as a result of inflammatory changes or dd Tumor. Based on this local finding we decided to perform an ileocecal resection followed by a modified Bassini repair of the posterior wall. Considering the possible contamination, a synthetic mesh was not applied. The following course of the patient in ward was without any complications. Few days later, showed the histo-

* Corresponding author at: Dreikoenigstraße 47, 60594, Frankfurt, Germany.

E-mail addresses: michele.fiordaliso@gmail.com (M. Fiordaliso), shadi.ahmad@gz-odw.de (S. Ahmad), sladana.simic-schloemp@gz-odw.de (S. Simic), houbi2010@hotmail.com (H. Zoubi), mevluet.karaorman@gz-odw.de (M. Karaorman).

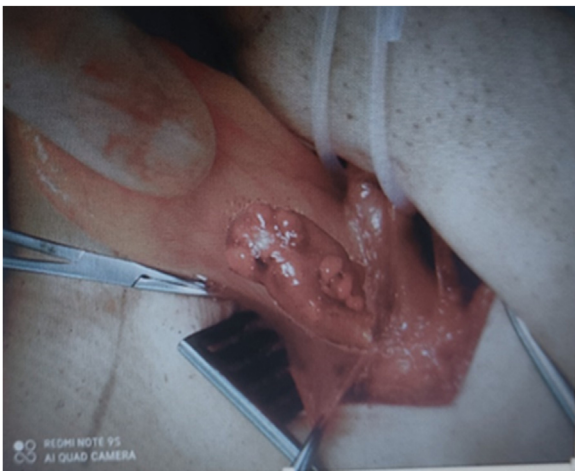

Fig. 1. Appendix inside the hernia sac.

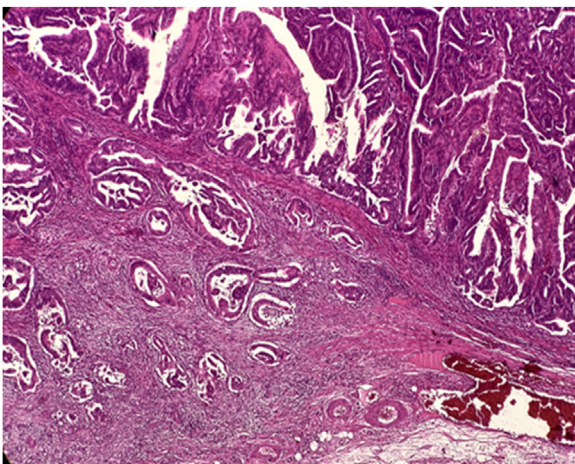


Fig. 2. Mucinous adenocarcinoma of the appendix (pT1, Pn0, L0, V0, R0) and low-grade mucinous neoplasm of appendix (pTis, pN0, L0, V0, R0).

logic finding at the appendix base a Mucinous adenocarcinoma of the appendix (pT1, Pn0, L0, V0, R0) and low-grade mucinous neoplasm of appendix (pTis, pN0, L0, V0, R0) combined with chronic appendicitis (Fig. 2). The resection margin of 1 cm was tumor free. After discussing the case of our patient with the colleagues of the oncology department, a follow up care due regarding the S3-guidelines in the republic state of Germany.

3. Discussion

Garengot, in 1731 [6], was the first to describe the occurrence of a non-inflamed vermiform appendix in a direct inguinal hernia sac. The name of the particular type of inguinal hernia described in this case study is derived from the French surgeon, Claudius Amyand (1680–1740). He earned a place in the history of surgery by successfully carrying out, in 1735, the first appendectomy on a 11-year old child who had an appendicular perforation located within a strangulated inguinal hernial sac. Amyand's name remained unknown during the 19th century, when the practice of appendectomy started taking hold. It was thanks to Deaver that the importance of Amyand's work in the history of appendicular surgery was finally recognized. According to the said author, Amyand performed appendectomy 144 years before the universally accepted Lawson Tate's appendectomy carried out in 1886, and 150 years before the one performed in the United States by

Hall – where the appendix was coincidentally located within a right strangulated inguinal hernia [7]. It is more common in childhood, given that inguinal hernia is, mainly, caused by a persistent patent processus vaginalis. Amyand's hernia cases have been recorded in every age, from neonates to elderly [8]. The incidence of Amyand's hernia is 1%. The association of Amyand's hernia with appendicitis is even more uncommon, having an incidence of 0,1%. The majority of cases are right-sided, which is understandable in view of the normal anatomy of the appendix. Additionally, right inguinal hernias are more common than the left ones. The suggested explanations for left-sided Amyand's hernia are situs inversus, malrotation, mobile caecum and excessively long appendix [9]. Nicola et al. and Mahajan et al. described cases, in which Amyand's hernia was accompanied with the bladder, ovarian, fallopian tube, omentum, Meckel diverticulum (Littre's hernia) [10], or a portion of the circumference of the intestine (Richter's hernia) [11] or Cecum is the organ that is most frequently contained within hernia sac [12,13]. The exact mechanism of appendicitis, within an inguinal hernia is not fully understood. After a thorough review of the existing literature, some opinions are reported below:

- Incarceration and subsequent inflammation of the appendix [14,15].
- The presence of the appendix within the hernial sac makes it more likely to develop adhesions between serous membranes and hernial sac, with subsequent irreducibility of the hernia, which would increase the risk of appendix inflammation [16,17]. Contractions of the abdominal muscles can cause intermittent compression of the appendix, which leads to ischemia of the appendix, infection and severe inflammation [18].
- Inflammatory swelling of the appendix can give rise to a vicious circle: it makes Amyand's hernia no longer reducible, thus exacerbating the swelling caused by venous stasis and bringing about a reduced microcirculatory blood flow in the appendix wall, with subsequent bacterial proliferation and translocation [19,20].

The major complications of Amyand's hernia include perforation of the appendix [21], necrotizing fasciitis of the anterior abdominal wall and secondary intestinal perforation. Primary appendiceal neoplasms are rare, and most (about 85%) are carcinoids. These follow a benign course, but are considered malignant because they have the potential for invasion and metastases [2]. Adenocarcinomas of the appendix are even rarer, accounting for 0.2% to 0.5% of all intestinal malignancies [1], and 4–6% of primary appendiceal neoplasms [3,4]. Primary appendiceal carcinoma was first described in 1882 by Berger [22], and since then only about 450 cases had been described by 1995 [23]. Appendiceal carcinoids are detected most commonly in patients in their 40 s, which is much younger than the average age compared with other primary malignant appendiceal neoplasms [24,25]. The majority of carcinoids is located in the distal one-third of the appendix, where they are unlikely to cause obstruction [26,27]. Most patients are asymptomatic, and that is why they are mostly found incidentally in appendectomy specimens. Diagnosis is, in the majority of cases, intrasurgical. A clinical diagnosis is made difficult by the fact that in asymptomatic cases, there is no indication that could lead to think of such positioning of the appendix. The slight local pain and tenderness are rather due to the symptoms given by the presence of the inguinal hernia. Similarly, in symptomatic cases characterized by a severe inflammatory reaction in the appendix, pain is attributed – though mistakenly, this time – to a supposed strangulation of the hernia. In many cases, symptoms are the ones typical of acute appendicitis (AA), with epigastric or periumbilical pain in the lower right portion of the abdomen. It has been suggested that the strangulated AA pain tends to be episodic and cramping, as opposed to the dull and constant pain which is usually associated with a strangulated

Table 1
Lossanoff-Basson classification.

Classification	Description	Surgical management
Type I	Normal appendix	Reduction or appendectomy (depending on age), mesh hernioplasty
Type II	Acute appendicitis localized in the sac	Appendectomy through hernia, followed by a hernioplasty without a mesh
Type III	Acute appendicitis, peritonitis	Appendectomy through laparotomy, followed by a hernioplasty without a mesh
Type IV	Acute appendicitis, other abdominal pathology	Appendectomy, diagnostic workup and other procedures as appropriate

bowel [28]. Leukocytosis and fever are not constantly present. A differential diagnosis would include strangulated hernia, strangulated omentocele, Richter's hernia, inguinal adenitis, diverticulitis of the perforated appendix, orchiepididymitis, hemorrhagic testicular cancer and acute hydrocele [22,28,29]. The literature reports cases of fortuitous pre-surgical diagnosis made by performing computed tomography on the abdomen. Celik et al. reported cases where the diagnosis of Amyand's hernia was made thanks to a pre-surgical echography, which revealed the presence of the appendix within the hernial sac [30]. Losanoff and Basson proposed a classification scheme to determine the surgical management of Amyand's hernia, depending on the status of the appendix (Table 1).

Regarding the treatment of Amyand's hernias, many authors suggest that prophylactic appendectomy is not necessary when the appendix is found without signs of inflammation [31,32]. By contrast, other authors suggest that all patients have an appendectomy because the appendix could reherniate or, especially in younger patients, cause appendicitis [33,34]. Whether appendectomy is carried out or not, the operation further requires to perform a hernial plastic surgery, with the possibility to use prostheses. In case the appendix shows clear signs of chronic appendicitis, there is less controversy regarding therapeutic practices: due to the tenacious adhesions developed with the hernial sac, the surgeon is forced to perform a convenience appendectomy. This being the case, authors still agree on the possibility to use prostheses for performing hernial plastic surgery. In the worst case, i.e. when the operation is carried out in an emergency situation and, instead of a strangulated hernia, the surgeon finds an inflamed appendix, it will be necessary to perform appendectomy through the hernial gate. Authors rarely report cases where a further access for surgery was needed, except for those cases which present concomitant complications such as the development of diffuse peritonitis or abscesses. In such situations videolaparoscopic surgery would be of help [34,35]. It is clear that in order to avoid septic, in such situations it would not be possible to use prostheses to repair the hernia. As for the use of videolaparoscopic surgery, the diagnostic importance of this tool is strongly underlined [34,36]. The evidence concerning hernial repair without mesh in the context of potential contamination is controversial. A systematic revision carried out by Hentati et al. and focusing on strangulated inguinal hernia repair techniques – with and without small bowel resection – shows a lower wound infection and relapse rate in repairs performed with mesh than in repairs performed without mesh [37]. Nonetheless, when it comes to Amyand's hernias, the majority of authors suggest that appendectomy and hernia repair without prosthesis implant be performed, due to the contamination of the operating field where appendix surgery is performed. The rarity of adenocarcinoma of the appendix has made it difficult to amass extensive data on which to base therapeutic decisions, and it accounts for the lack of controlled prospective studies. Andersson et al. [38] reported 51 patients with colonic type adenocarcinoma of the appendix:

the five year survival rate among 26 patients treated by appendectomy alone was 46%, compared with 60% in 25 patients who underwent right hemicolectomy. Like others, we think [1,38,41] that right hemicolectomy is the treatment of choice for all lesions that are invading beyond the mucosa, irrespective of histological type or degree of differentiation. In most patients right hemicolectomy would be done as a secondary procedure, the primary being emergency appendectomy. For lesions confined to the mucosa (carcinoma in situ) some suggest that there is no survival advantage in performing right hemicolectomy over appendectomy alone, while others recommend right hemicolectomy for all appendiceal adenocarcinomas [41]. The prognosis is unfavourable if cancer is perforated [39], and appendix adenocarcinoma, among all types of gastrointestinal tract carcinomas, is regarded as the most likely to perforate the abdominal cavity [39]. Appendix adenocarcinoma often metastasizes in the ovaries, so that some authors recommend that bilateral ovariectomy be performed in order to carry out cancer staging and to eliminate the metastatic diffusion from the ovaries [40].

4. Conclusion

Coexistence of a malignancy of the appendix with an Amyand's hernia is an unusual condition because neoplasms of the appendix are very rare. Clinical manifestations often mimic those of an incarcerated right inguinal hernia, rendering the correct preoperative diagnosis very difficult. Therefore, a malignancy of the appendix should always be in the differential diagnosis of a right inguinal mass, in order to provide optimum surgical treatment. Adenocarcinoma of the appendix is extremely rare neoplasm with varied presentations, and is usually advanced when diagnosed. Right hemicolectomy is the treatment of choice for such tumors.

SCARE checklist

The work has been reported in line with the SCARE 2020 checklist [5].

Declaration of Competing Interest

The authors declare that there is no conflict of interest regarding the publication of this article.

Sources of funding

No source of funding or sponsors.

Ethical approval

This is a Case Report for which the patient provided written informed consent.

Consent

Written informed consent was obtained from the patient for publication of this case report and accompanying images.

Author contribution

Michele Fiordaliso: Study design, data collection, writing.
Shadi Ahmad, Sladana Simic: Surgeons, who performed the operation.

Hisham Zoubi: Data collection, writing.
Mevlüt Karaorman: Data collection, writing.
All authors have approved the final article.

Registration of research studies

Not applicable.

Guarantor

Michele Fiordaliso.

Provenance and peer review

Not commissioned, externally peer-reviewed.

References

- [1] A.P. Lyss, Appendiceal malignancies, *Semin. Oncol.* 15 (1988) 129–137.
- [2] D.C. Collins, A study of 50,000 specimens of the human vermiform appendix, *Surg. Gynecol. Obstet.* 101 (1955) 437–445.
- [3] R.H. Rutledge, J.W. Alexander, Primary appendiceal malignancies, *Surgery* 111 (1992) 244–250.
- [4] H.A. Gamble, Adenocarcinoma of the appendix: an unusual case and review, *Dis. Colon Rectum* 19 (1976) 621–625.
- [5] R. Agha, T. Franchi, C. Sohrabi, G. Mathew, A. Kerwan, SCARE Group, The SCARE 2020 guideline: updating consensus Surgical CAse REport (SCARE) guidelines, *Int. J. Surg.* 84 (December) (2020) 226–230, <http://dx.doi.org/10.1016/j.ijsu.2020.10.034>, Epub 2020 Nov 9.
- [6] D. Sahu, S. Swain, M. Wani, P.K. Reddy, Amyand's hernia: our experience in the laparoscopic era, *J. Minim. Access Surg.* 11 (2) (2015) 151–153.
- [7] J.B. Deaver, *Appendicitis*, Blackiston's Son & Co., Philadelphia, 1905.
- [8] G. Ivashuk, A. Cesmebasi, E.P. Sorenson, C. Blaak, M. Loukas, S.R. Tubbs, Amyand's hernia: a review, *Med. Sci. Monit.* 28 (20) (2014) 140–146.
- [9] M. Ahmed, Maksoud Al, Ahmed Salah Ahmed, Left Amyand's hernia: an unexpected finding during inguinal hernia surgery, *Int. J. Surg. Case Rep.* 14 (2015) 7–9, <http://dx.doi.org/10.1016/j.ijscr.2015.06.029>.
- [10] A. Littre, Observation sur une nouvelle espèce de hernie, *Mémoires de mathématique et de physique de l'Académie royale des sciences* 3502 (1700) 300–311.
- [11] W.A. Tito, W.C. Allen, Richter and littre hernia, in: J.B. Nyhus, R.E. Condon (Eds.), *Hernia*, 3rd edn., Lippincott, Philadelphia, 1989, pp. 305–310.
- [12] S.M. Nikola, Hernia de Amyand, presentacion de un caso y revision de la literatura, *Rev. Chil. Cirugia* 59 (2) (2007) 142–144.
- [13] A. Mahajan, P. Pawar, A. Luther, P. Haque, Right sided Amyand's hernia: a rare case report, *Int. Surg. J.* 1 (1) (2014) 43–44.
- [14] R.V. Weber, Z.C. Hunt, J.C. Kral, Amyand's hernia. Etiologic and therapeutic implications of two complications, *Surg. Rounds* 22 (1999) 552–556.
- [15] L. Ash, S. Hatem, G.A. Ramirez, J. Veniero, Amyand's hernia: a case report of prospective ct diagnosis in the emergency department, *Emerg. Radiol.* 11 (4) (2005) 231–232.
- [16] J.R. Hiatt, N. Hiatt, Amyand's hernia, *N. Engl. J. Med.* 318 (21) (1988) 1402.
- [17] J. Abu-Dalu, I. Urca, Incarcerated inguinal hernia with a perforated appendix and periappendicular abscess: report of a case, *Dis. Colon Rectum* 15 (6) (1972) 464–465.
- [18] R. Solecki, A. Matyja, W. Milanowski, Amyand's hernia: a report of two cases, *Hernia* 7 (1) (2003) 50–51.
- [19] M.H. Okur, S. Karacay, I. Uygun, K. Topcu, et al., Amyand's hernias in childhood (a report on 21 patients): a single-centre experience, *Pediatr. Surg. Int.* 29 (6) (2013) 571–574.
- [20] S. Singhal, A. Singhal, S. Singh Negi, et al., Amyand's hernia: rare presentation of a common ailment, *Case Rep. Gastrointest. Med.* 2015 (2015), 629127.
- [21] S. Lyass, A. Kim, J. Bauer, Perforated appendicitis within an inguinal hernia: case report and review of the literature, *Am. J. Gastroenterol.* 92 (1997) 700–702.
- [22] A. Berger, Ein Fall von Krebs des Wurmfortsatzes, *Ber Klin Wochenschr* 19 (1882) 610.
- [23] R. Cortina, J. McCornik, P. Kolm, R. Perry, Management and prognosis of adenocarcinoma of the appendix, *Dis. Colon Rectum* 38 (1995) 848–852.
- [24] M.E. McCusker, T.R. Coté, L.X. Clegg, L.H. Sobin, Primary malignant neoplasms of the appendix: a population-based study from the surveillance, epidemiology and end-results program, 1973–1998, *Cancer* 94 (2002) 3307.
- [25] A. Sandor, I.M. Modlin, A retrospective analysis of 1570 appendiceal carcinoids, *Am. J. Gastroenterol.* 93 (1998) 422–428.
- [26] S.J. Connor, G.B. Hanna, F.A. Frizelle, Appendiceal tumors: retrospective clinicopathologic analysis of appendiceal tumors from 7,970 appendectomies, *Dis. Colon Rectum* 41 (1998) 75.
- [27] A. Roggo, W.C. Wood, L.W. Ottinger, Carcinoid tumors of the appendix, *Ann. Surg.* 217 (1993) 385.
- [28] M.T. Logan, J.M. Nottingham, Amyand's hernia: a case report of an incarcerated and perforated appendix within an inguinal hernia and review of the literature, *Am. Surg.* 67 (2001) 628.
- [29] M. Fiordaliso, A.F. De Marco, R. Costantini, A case of Type 2 appendiceal diverticulum perforated and a review of the literature, *Int. J. Surg. Case Rep.* 77 (2020) 450–453, <http://dx.doi.org/10.1016/j.ijscr.2020.10.114>, Epub 2020 Nov 10.
- [30] A. Celik, O. Ergün, S.S. Ozbek, Z. Dökümcü, E. Balik, Sliding appendiceal inguinal hernia: preoperative sonographic diagnosis, *J. Clin. Ultrasound* 31 (2003) 156–158.
- [31] L. Cankorkmaz, H. Ozer, C. Guney, M.H. Ataral, M.S. Arslan, G. Koyluoglu, Amyand's hernia in the children: a single center experience, *Surgery* 147 (2010) 140–143.
- [32] M.H. Okur, S. Karaçay, I. Uygun, K. Topcu, H. Ozturk, Amyand's hernias in childhood (a report on 21 patients): a single-centre experience, *Pediatr. Surg. Int.* 29 (2013) 571–574.
- [33] A. Gurer, M. Ozdogan, N. Ozlem, A. Yildirim, H. Kulacoglu, R. Aydin, Uncommon content in groin hernia sac, *Hernia J. Hernias Abdom. Wall Surg.* 10 (2006) 152–155.
- [34] K. Singh, R.R. Singh, S. Kaur, Amyand's hernia, *J. Indian Assoc. Pediatr. Surg.* 16 (2011) 171–172.
- [35] A.E. Paletto, *Nuovo trattato di tecnica chirurgica*, UTET, Torino, 2002.
- [36] M. Faccini, P. Caputo, C. D'Urbano, W. Zuccon, L. Bonandrini, Razionale dell'opzione videolaparoscopica nell'approccio alle appendicopatie e all'addome acuto: esperienza e considerazioni personali, *Rivista Generale Italiana di Chirurgia* 52 (14) (2001).
- [37] H. Hentati, W. Dougaz, C. Dziri, Mesh repair versus non-mesh repair for strangulated inguinal hernia: systemic review with meta-analysis, *World J. Surg.* 38 (2014), <http://dx.doi.org/10.1007/s00268-014-2710-0>, 2784–2784, [PubMed] [CrossRef] [Google Scholar].
- [38] A. Andersson, L. Bergdahl, L. Boquis, Primary carcinoma of the appendix, *Ann. Surg.* 183 (1976) 53–57.
- [39] M.A. Cerame, A 25 year review of adenocarcinoma of the appendix: a frequently perforating carcinoma, *Dis. Colon Rectum* 31 (1988) 145–150.
- [40] C.C. Conte, N.J. Petrelli, J. Stulc, L. Herrera, A. Mittelman, Adenocarcinoma of the appendix, *Surg. Gynecol. Obstet.* 166 (1988) 451–453.
- [41] G.T. Deans, R.A.J. Spence, Neoplastic lesions of the appendix, *Br. J. Surg.* 82 (1995) 299–306.

Open Access

This article is published Open Access at [sciencedirect.com](https://www.sciencedirect.com). It is distributed under the [IJSCR Supplemental terms and conditions](#), which permits unrestricted non commercial use, distribution, and reproduction in any medium, provided the original authors and source are credited.